



Original article

Functional outcome after arthroscopic repair of triple shoulder instability[☆]



Glaydson Gomes Godinho^{a,b,c}, Flávio de Oliveira França^{a,c,*},
 José Márcio Alves Freitas^{a,b,c}, Lander Braga Calais Correia Pinto^{a,b,c},
 Carolina Lima Simionatto^{a,b,c}, Pedro Paulo Gomes Viana Filho^{a,b,c}

^a Hospital Ortopédico, Belo Horizonte, MG, Brazil

^b Hospital Belo Horizonte, Belo Horizonte, MG, Brazil

^c Hospital Lifecenter, Belo Horizonte, MG, Brazil

ARTICLE INFO

Article history:

Received 25 April 2016

Accepted 30 May 2016

Available online 6 March 2017

Keywords:

Arthroscopy/methods

Shoulder

Rotator cuff

Patient satisfaction

Articular motion range

ABSTRACT

Objective: To evaluate the functional outcomes of patients submitted to arthroscopic repair of triple labral lesion.

Methods: This was an analytical retrospective study of patients who underwent arthroscopic treatment of triple labral lesion from March 2005 to December 2014. Patients with at least one year of postoperative follow-up were included. A total of nine patients were evaluated. The mean age was 32.3 years and the dominant side was affected in five patients. Patients were functionally assessed regarding the range of motion (ROM) in elevation, external rotation with the arm close to the body the arm in abduction of 90°, and internal rotation, and by the Carter-Rowe score. The degree of satisfaction was assessed at the end of the follow-up period.

Results: Three patients had less than five episodes of instability, four patients had between five and ten episodes, and two patients had more than ten episodes. Seven patients had positive O'Brien test for SLAP lesions and positive apprehension test in abduction and external rotation, and only one patient had apprehension in adduction and internal rotation. Three patients persisted with positive O'Brien test and one with apprehension in abduction and external rotation at the end of follow-up. The range of motion was complete in all cases. The median Carter-Rowe score increased from 40 preoperatively to 90 ($p = 0.008$).

Conclusion: The arthroscopic repair of triple labral lesions allows for the restoration of the stability of the glenohumeral joint, achieving excellent functional results.

© 2016 Sociedade Brasileira de Ortopedia e Traumatologia. Published by Elsevier Editora Ltda. This is an open access article under the CC BY-NC-ND license (<http://creativecommons.org/licenses/by-nc-nd/4.0/>).

[☆] Study conducted at Hospital Lifecenter, Hospital Belo Horizonte, and Hospital Ortopédico, Belo Horizonte, MG, Brazil.

* Corresponding author.

E-mail: flavio.franca29@gmail.com (F.O. França).

<http://dx.doi.org/10.1016/j.rboe.2017.02.004>

2255-4971/© 2016 Sociedade Brasileira de Ortopedia e Traumatologia. Published by Elsevier Editora Ltda. This is an open access article under the CC BY-NC-ND license (<http://creativecommons.org/licenses/by-nc-nd/4.0/>).

Resultado funcional após reparo artroscópico da trílice instabilidade do ombro

R E S U M O

Palavras-chave:

Artroscopia/métodos
Ombro
Bainha rotadora
Satisfação do paciente
Amplitude do movimento articular

Objetivo: Avaliar os resultados funcionais dos pacientes submetidos a reparo artroscópico da trílice lesão labral do ombro.

Métodos: Estudo analítico retrospectivo de pacientes com trílice lesão labral do ombro, submetidos a tratamento artroscópico de março de 2005 a dezembro de 2014. Foram incluídos pacientes com pelo menos um ano de seguimento pós-operatório. Nove pacientes foram avaliados. A média foi de 32,3 anos e o lado dominante foi afetado em cinco pacientes. Os pacientes foram avaliados funcionalmente por meio da amplitude de movimento em elevação, rotação externa com o braço junto ao corpo e com o braço em abdução de 90°, rotação interna e por meio do escore de Carter-Rowe. O grau de satisfação foi avaliado no fim do seguimento.

Resultados: Três pacientes tiveram menos de cinco episódios de instabilidade, quatro entre cinco e dez e dois mais de dez. Sete pacientes tiveram teste de O'Brien positivo para lesão do lábio superior de anterior para posterior (Slap, do inglês *superior labrum anterior to posterior lesion*) e apreensão em abdução e rotação externa positiva; apenas um apresentou apreensão em adução e rotação interna. Três pacientes persistiram com teste de O'Brien positivo e um com apreensão em abdução e rotação externa no fim do seguimento. A amplitude de movimento esteve completa em todos os casos na última avaliação. A média do escore de Carter-Rowe aumentou de 40 no pré-operatório para 90 ($p = 0,008$).

Conclusão: O reparo artroscópico da trílice lesão labral permite restaurar a estabilidade da articulação glenoumeral e alcança excelentes resultados funcionais.

© 2016 Sociedade Brasileira de Ortopedia e Traumatologia. Publicado por Elsevier Editora Ltda. Este é um artigo Open Access sob uma licença CC BY-NC-ND (<http://creativecommons.org/licenses/by-nc-nd/4.0/>).

Introduction

The stability of the glenohumeral joint depends on a complex combination of the static and dynamic stabilizers of the shoulder.¹ For anterior dislocation, there is an avulsion of the anterior-inferior labrum complex of the periosteum of the glenoid, which generates anterior instability, especially in the movements of abduction and external rotation.²

Symptoms of posterior instability are vague; it may present only as pain in certain movements, especially adduction and internal rotation. It can be caused by a single trauma or by repetitive microtraumas, throwing activities, or can result from convulsions and electric shocks.³

Superior labrum anterior to posterior (SLAP) lesions are still uncommon shoulder injuries, with an incidence of 6%, diagnosed during arthroscopic procedures, according to Snyder et al.⁴ Clinical and imaging diagnoses have low sensitivity and specificity,⁵ and this condition may contribute to a major functional deficit and shoulder pain.⁶

Lo and Burkhart⁷ defined the triple labral lesion as a condition that involves unusual lesions of the glenoid labrum: superiorly, a SLAP lesion type II; anteroinferiorly, Bankart lesions; and posteroinferiorly, lesions such as the reverse Bankart (Fig. 1).

Habermeyer et al.⁸ reported that the emergence of a triple labral lesion is related to the number of relapses in anterior dislocations, denoting the chronological and evolutionary character of these lesions. A very detailed clinical

examination should be performed, including the tests for anterior and posterior instability and SLAP. According to Lo and Burkhart,⁷ the incidence of triple labral lesion was 2.4% in a group of 297 patients with ligament and labral lesions of the glenoid.

This study aimed to evaluate the functional results of patients who underwent arthroscopic correction of triple labral lesions and to raise awareness of the diagnostic difficulty and underestimation of this condition.

Material and methods

This was a retrospective analytical study of patients submitted to the arthroscopic treatment of triple labral lesions from March 2005 to December 2014. During this period, 15 patients were diagnosed and treated for this condition by the Shoulder Group of this institution.

For the study, patients who had a triple labral lesion and a minimum follow-up of 1 year were selected. Exclusion criteria were: previous shoulder surgery, fracture sequelae in the region, advanced glenohumeral arthrosis, and less than one year of follow-up. Of all patients who underwent surgery during this period, 11 met the inclusion criteria. Two refused to participate in the study. Of the nine patients selected, seven were personally assessed and two by telephone due to the fact that they lived outside the city of origin of the study.

One patient was female (11.1%) and eight were male (88.9%). Mean age was 32.3 years (range: 22–43 years). Right

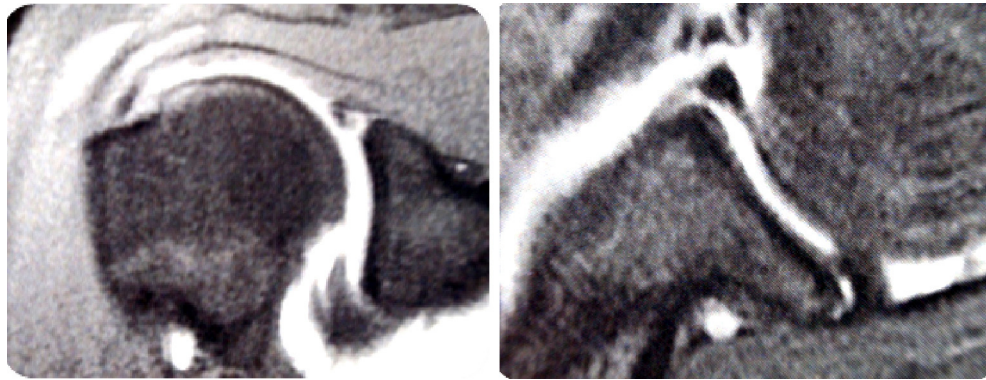


Fig. 1 – Arthrography MRI image of the right shoulder in the coronal and axial T2-weighted cuts showing the SLAP lesion (left) and the Bankart and posterior labral lesions (right).

side was affected in four patients (44.4%) and left side in five (55.6%). The dominant limb was affected in five patients (55.6%).

Four patients (44.4%) had a traumatic lesion; four (44.4%) lesions were caused by repetitive microtraumas in sports practice, two of which were professional athletes; and one patient (11.1%) had had a seizure.

The Carter-Rowe⁹ score, which takes into consideration the stability, range of motion (ROM), and function, was used for the functional assessment (Table 1).

ROM for anterior elevation, lateral rotation with arm in abduction and near the body, and medial rotation were compared. The degree of satisfaction of patients with surgical treatment was also assessed. At the end of follow-up period,

patients underwent radiography to assess presence of arthrosis.

At the last postoperative physical examination, the anterior apprehension test in 90° of abduction and external rotation, the O'Brien test, and the posterior apprehension test in adduction and internal rotation were assessed.

All patients filled out an informed consent form for disclosure of clinical data, and the study was approved by the Ethics Committee of the Orthopedic Hospital.

Surgical technique

The procedure was performed with patient in contralateral lateral decubitus, under general anesthesia and brachial plexus block. Initially, the arthroscope was inserted through the posterior portal located 2 cm distal and 2 cm medial to the posterolateral corner of the acromion.

Diagnosis of triple labral lesion was made by joint inspection, in the presence of Bankart lesion, reverse Bankart lesion, and SLAP lesion (II, III, or IV).⁷ A peel back maneuver and palpation of the superior labral lesion with a probe confirmed the presence of SLAP lesion¹⁰ (Figs. 2 and 3).

Table 1 – Carter-Rowe score.

Stability	Note
No recurrences, subluxations, or apprehension	50
Apprehension when the arm was placed in certain positions	30
Subluxations (with no need for reductions)	10
Recurrent dislocation	0
Movement	
100% of the movement	20
75% of normal movement	15
50% of the normal ER, 75% of the normal AE and IR	5
50% of the normal AE, IR, and ER	0
Function	
Without limitation to sport or work activities. Minimal or no discomfort	30
Small limitation and minimal discomfort	25
Moderate limitation and discomfort	10
Severe limitation and pain	0
Total possible points	100

AE, anterior elevation; ER, external rotation; IR, internal rotation.

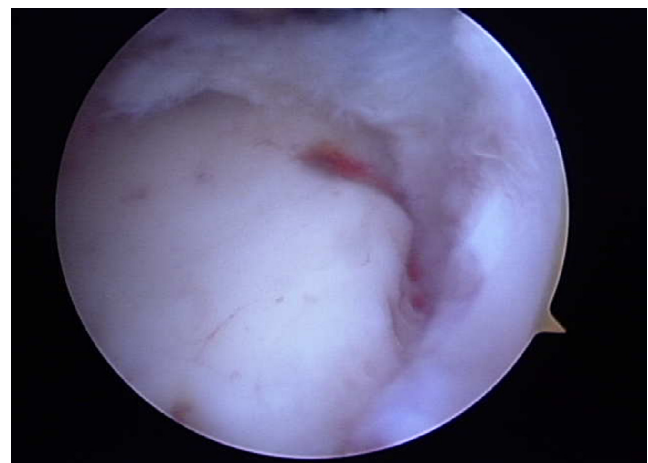


Fig. 2 – Arthroscopic image of the superior edge of the glenoid on the right shoulder indicating the presence of a SLAP lesion.

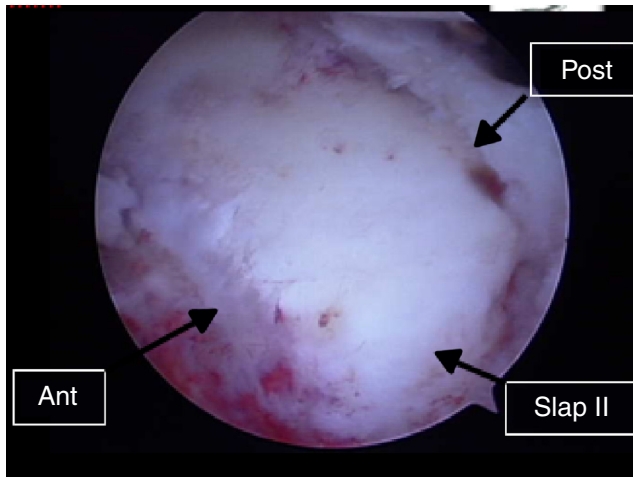


Fig. 3 – Arthroscopic image of the right shoulder, demonstrating the anterior, posterior, and superior labral lesions.

Through the anterosuperior, anteroinferior, and posterior portals, three cannulas were inserted. The anterosuperior portal was used for visualization through an arthroscope, and surgical instruments were passed through the anteroinferior and posterior portals.

The area of the lesions was then debrided and opened, with decortication of the edges of the glenoid and regularization of the glenoid labrum. The first lesion to be repaired was Bankart's reverse lesion. However, the posterior portal does not provide a suitable approach angle for inserting the mini-anchors at the posterior border of the glenoid. Therefore, a needle (Jelco No. 18) was used to determine a 45° angle with the glenoid surface, and mini-anchors were inserted percutaneously. Generally, one or two anchors are sufficient for the posterior repair. The wires were threaded and tied, and the posterior lesion was fixated.

Next step was the reinsertion of the anterior labrum, which corrects the Bankart lesion. Mini-anchors, spaced at a 1 cm distance, were inserted in the anterior border of the glenoid, also at a 45° angle in relation to the glenoid surface. The direction followed was inferior to superior. Wires were then threaded and tied.

Finally, the SLAP lesion was repaired, with the introduction of a mini-anchor on the superior edge of the glenoid; wires were passed with a needle of the surgeon's preference and a mattress suture was made. The fixation and stability of the glenoid labrum was assessed with a probe, in a panoramic view of the repairs (Fig. 4). The following steps were skin suture, dressing, and immobilization with a Velpeau sling for 21 days.

Statistical analysis

To assess the pre- and post-operative range of motion (ROM) and the Carter-Rowe scores, non-parametric Wilcoxon test was used.

Data were analyzed in the statistical program *Predictive Analytics Software* (PASW 18). In all statistical tests,

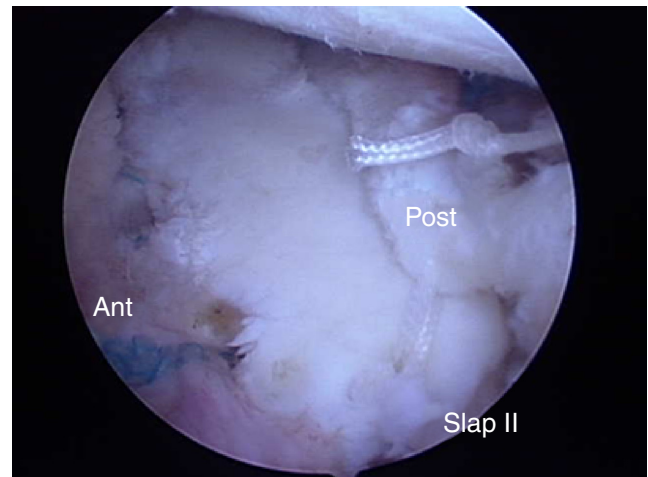


Fig. 4 – Arthroscopic image after the repair of lesions that comprise the triple labral lesion.

a 5% significance level was adopted. Thus, statistically significant associations are those whose *p*-value was lower than 0.05.

Results

Functional evaluation of patients is shown in Table 2.

The ROM of the assessed patients is presented in Table 3.

Data on number of episodes of instability are shown in Fig. 5.

Regarding physical evaluation, Table 4 presents a comparison between pre- and postoperative results of each patient in the O'Brien test, apprehension test in abduction and external rotation, and apprehension test in adduction and internal rotation.

Of the seven patients who agreed to undergo radiographic evaluation at the end of the follow-up period, only one

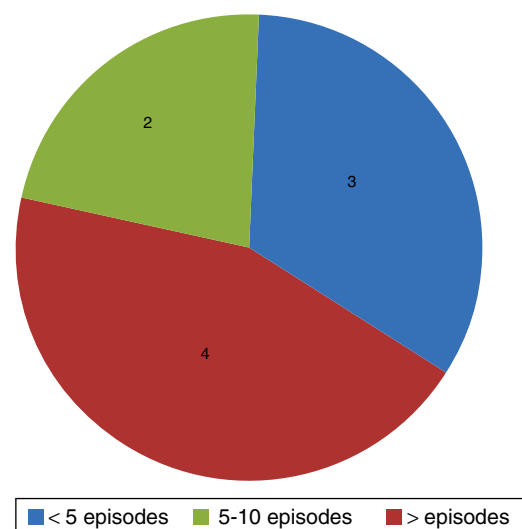


Fig. 5 – Patient distribution according to the number of episodes of instability.

Table 2 – Pre- and post-operative comparison of the Carter–Rowe score.

	Carter pre				Carter post				p-Value
	Stability	ROM	Function	Total	Stability	ROM	Function	Total	
DLAN	0	20	25	45	50	15	25	90	<0.05
GCV	0	20	10	30	30	20	25	75	<0.05
BL	0	15	25	40	50	15	30	95	<0.05
ECR	30	15	10	55	50	20	10	80	<0.05
FFS	0	15	10	25	30	20	10	60	<0.05
GNS	0	15	10	25	50	15	25	95	<0.05
YAC	30	20	10	60	50	15	25	90	<0.05
CFGS	30	20	10	60	50	20	30	100	<0.05
CJF	10	20	10	40	50	20	30	100	<0.05
MEAN				42.2				87.2	<0.05

Table 3 – Comparison of pre- and post-operative ROM.

	DLAN	GCV	BL	ECR	FFS	GNS	YAC	CFGS	CJF	Mean	p-Value
AE											
Pre-op	180	180	180	180	180	180	150	180	180	177	0.317
Post-op	180	180	180	180	180	180	180	180	180	180	
ER2											
Pre-op	90	90	90	90	100	90	60	90	120	91.1	0.357
Post-op	80	45	90	90	100	90	80	90	100	85	
ER1											
Pre-op	60	80	45	80	80	80	45	80	100	72.2	0.715
Post-op	60	50	80	80	80	80	70	80	90	74.4	
IR											
Pre-op	T9	T7	T8	T7	T7	T7	T12	T7	T7	T 7.8	<0.05
Post-op	T9	T7	T8	T8	T7	T7	T7	T7	T7	T 7.4	

AE, anterior elevation; IR, internal rotation; ER1, external rotation 1 (with the arm close to the body); ER2, external rotation 2 (with the arm at 90° of abduction).

Table 4 – Pre- and postoperative comparison of the O’Brien test, apprehension test in abduction and external rotation, and apprehension test in adduction and internal rotation.

	DLAN	GCV	BL	ECR	FFS	GNS	YAC	CFGS	CJF
O’Brien test									
Pre-op	Neg	+	+	+	+	Neg	+	+	+
Post-op	Neg	+	Neg	+	Neg	Neg	+	Neg	Neg
Apprehension in abduction and ER									
Pre-op	+	Neg	+	+	+	Neg	+	+	+
Post-op	Neg	+	Neg	Neg	+	Neg	Neg	Neg	Neg
Apprehension in adduction and IR									
Pre-op	Neg	Neg	Neg	Neg	Neg	Neg	Neg	+	Neg
Post-op	Neg	Neg	Neg	Neg	Neg	Neg	Neg	Neg	Neg

ER, external rotation; IR, internal rotation.

presented an initial degenerative condition compatible with Samilson and Prieto¹¹ type I arthrosis.

Regarding the degree of satisfaction, out of the nine patients assessed, only one was dissatisfied with the treatment.

Discussion

To define the triple labral shoulder lesion, Lo and Burkhart⁷ considered as anterior, posterior, and superior labral lesions those that affect at least two-thirds of the area comprised

in the 2–6 o’clock, 6–10 o’clock, and 2–10 o’clock positions, respectively (assuming a right shoulder).

In the present study, the criteria set forth by Lo and Burkhart⁷ was not used, since regardless of the degree of engagement in each region (anterior, posterior, and superior), the patients presented characteristic clinical signs, and diagnosis was confirmed during arthroscopy. Therefore, the clinical correlation of lesions was weighted more heavily than the isolated anatomical aspect.

In their series, Lo and Burkhart⁷ identified anterior instability as the main cause of triple labral lesion. They identified

posterior instability as the cause in only one case. Due to the recoil mechanism, anterior instabilities could lead to a posterior labral lesion. This theory is based on the concept of cyclic capsulolabral dysfunction reported by Warren et al.,¹² in which an isolated anterior labral lesion would not be sufficient to cause a dislocation unless the posterior stabilizing structures were also injured.

This fact was also observed in the present study, since 55.5% of the patients were involved in traumatic episodes with anterior instability. None of the patients had an initial traumatic episode of posterior instability.

In this series, a professional soccer player, after anterior traumatic dislocation and six recurrences, presented triple labral lesion. In this case, the origin of the posterior lesion can be justified by the recoil mechanism described by Lo and Burkhart.⁷ The upper labral lesion would derive from anterior traumatic instability itself, since the association between SLAP and Bankart lesions was described in 50% of the cases in the study by Godinho et al.,⁵ and reached 77.8% in the study by Warner et al.¹³

Another mechanism that would explain the origin of triple labral lesion of the shoulder is that observed in throwing athletes. In this group of athletes, the genesis of the posterior labral lesion and the SLAP lesion is through the peel back mechanism,¹⁴ associated with internal impact.¹⁵ If there is an anterior dislocation, a triple labral shoulder lesion is characterized, as long as the anterior labral lesion is present.

In this context, a volleyball athlete of this series, after an episode of traumatic anterior dislocation due to a seizure crisis, presented a triple labral lesion of the shoulder. The SLAP lesion may have been caused by the recoil mechanism described by Lo and Burkhart⁷ or by the combination of active forces during the seizure.

The triple labral lesion of the shoulder is not easily detected by the available imaging methods; it can be diagnosed in up to 32.3% of cases when MRI arthrogram is used and in 8.7% when MRI is used.¹⁶ This fact is probably due to the difficulty in diagnosing SLAP lesions, as demonstrated by Godinho et al.⁵

In the present study, alterations compatible with triple labral lesions were evidenced in only four patients (36.3%), which demonstrates how this diagnosis can be underestimated.

Treatment of glenoid labral lesions in athletes may lead to unsatisfactory results, especially regarding return to the pre-injury level. The success rate after isolated repair of SLAP lesions is around 80%.^{17,18} In turn, in anterior labral lesions, the success rate ranges from 68% to 77%.^{19,20} Therefore, it is expected that in the presence of the triple labral shoulder lesion the success rate is even lower, due to the association of injuries.

However, in the present study, a significant improvement was observed in the Carter-Rowe⁹ scores. Mean score was 42.2 points preoperatively and 87.2 postoperatively ($p < 0.05$). Two of the patients, one of whom was a wrestler and the other a volleyball player, are still able to perform professional sports activities. Regarding ROM, no statistically significant differences were observed between pre- and postoperative periods. Only one patient was dissatisfied at the end of treatment, due to the fact that he suffered an accident followed by a recurrence of the lesion. All patients who practiced sports, whether

professionally or recreationally, returned to those activities without deficit.

The literature is still very scarce regarding this type of lesion. New studies with more expressive sample size should be conducted in order to achieve a more accurate statistical assessment.

Conclusion

Arthroscopic treatment of triple shoulder lesion leads to a significant functional improvement, without loss of ROM and with satisfactory return to the practice of sport.

Conflicts of interest

The authors declare no conflicts of interest.

REFERENCES

- Kim SH, Ha KI, Kim SH. Bankart repair in traumatic anterior shoulder instability: open versus arthroscopic technique. *Arthroscopy*. 2002;18(7):755-63.
- Bankart AS. Recurrent or habitual dislocation of the shoulder-joint. *Br Med J*. 1923;2(3285):1132-3.
- DeLong JM, Jiang K, Bradley JP. Posterior instability of the shoulder: a systematic review and meta-analysis of clinical outcomes. *Am Sports Med*. 2015;43(7):1805-17.
- Snyder SJ, Banas MP, Karzel RP. An analysis of 140 injuries to the superior glenoid labrum. *J Shoulder Elbow Surg*. 1995;4(4):243-8.
- Godinho GG, Freitas JMA, Leite LMB, Pina ERM. Lesões Slap no ombro. *Rev Bras Ortop*. 1988;33(5):345-52.
- Nam EK, Snyder SJ. The diagnosis and treatment of superior labrum, anterior and posterior (Slap) lesions. *Am J Sports Med*. 2003;31(5):798-810.
- Lo IK, Burkhart SS. Triple labral lesions: pathology and surgical repair technique-report of seven cases. *Arthroscopy*. 2005;21(2):186-93.
- Habermeyer P, Gleyze P, Rickert M. Evolution of lesions of the labrum-ligament complex in posttraumatic anterior shoulder instability: a prospective study. *J Shoulder Elbow Surg*. 1999;8(1):66-74.
- Rowe CR, Patel D, Southmayd WW. The Bankart procedure: a long-term end-result study. *J Bone Joint Surg Am*. 1978;60(1):1-16.
- Burkhart SS, Morgan CD. The peel-back mechanism: its role in producing and extending posterior type II Slap lesions and its effect on Slap repair rehabilitation. *Arthroscopy*. 1998;14(6):637-40.
- Samilson RL, Prieto V. Dislocation arthropathy of the shoulder. *J Bone Joint Surg Am*. 1983;65(4):456-60.
- Warren RF, Kornblatt IB, Marchand R. Static factors affecting shoulder stability. *Orthop Trans*. 1984;8:89.
- Warner JJ, Kann S, Marks P. Arthroscopic repair of combined Bankart and superior labral detachment anterior and posterior lesions: technique and preliminary results. *Arthroscopy*. 1994;10(4):383-91.
- Burkhart SS, Morgan CD, Kibler WB. The disabled throwing shoulder: spectrum of pathology. Part I: pathoanatomy and biomechanics. *Arthroscopy*. 2003;19(4):404-20.
- Walch G, Boileau P, Noel E, Donell ST. Impingement of the deep surface of the supraspinatus tendon on the

- posterosuperior glenoid rim: an arthroscopic study. *J Shoulder Elbow Surg.* 1992;1(5):238-45.
16. Ricchetti ET, Ciccotti MC, Ciccotti MG, Williams GR Jr, Lazarus MD. Sensitivity of preoperative magnetic resonance imaging and magnetic resonance arthrography in detection of panlabral tears of the glenohumeral joint. *Arthroscopy.* 2013;29(2):274-9.
 17. Morgan CD, Burkhart SS, Palmeri M, Gillespie M. Type II Slap lesions: three subtypes and their relationships to superior instability and rotator cuff tears. *Arthroscopy.* 1998;14(6):553-65.
 18. Miyazaki AN, Fregoneze M, Santos PD, Silva LA, Sella GV, Soares AL, et al. Avaliação dos resultados e complicações da sutura artroscópica da lesão Slap. *Rev Bras Ortop.* 2011;46(1):51-6.
 19. Jobe FW, Giangarra CE, Kvitne RS, Glousman RE. Anterior capsulolabral reconstruction of the shoulder in athletes in overhand sports. *Am J Sports Med.* 1991;19(5):428-34.
 20. Rubenstein DL, Jobe FW, Glousman RE, Kvitne RS, Pink M, Giangarra CE. Anterior capsulolabral reconstruction of the shoulder in athletes. *J Shoulder Elbow Surg.* 1992;1(5): 229-37.