

Plexiform neurofibroma with neurofibromatosis type I/ von Recklinghausen's disease: A rare case report

Pooja Poswal^a, Namita Bhutani^{b,*}, Sunil Arora^a, Raj Kumar^a

^a Department of Pathology, SGT Medical College & University, Gurugram, Haryana, India

^b Department of Pathology, North DMC Medical College & Hindu Rao Hospital, Delhi, India

ARTICLE INFO

Keywords:

Café-au-lait macules
Cutaneous neurofibromas
Lentiginosities
Lisch nodules
Neurofibromin

ABSTRACT

Introduction: Plexiform neurofibroma with neurofibromatosis type 1 (NF1) or Von Recklinghausen's disease is a rare entity and occurs in approximately 5–15% patients. These are slow growing, painless and locally infiltrating tumors. The pattern of inheritance is autosomal dominant and its penetrance is almost complete by 5 years of age.

Presentation of case: We hereby report a case of 13 years old boy visited presenting with swelling of right eyelid and forehead. After surgical removal, the tissue was sent for histopathological evaluation. Microscopy revealed an unencapsulated tumor mass comprising of well organized mixture of multiple nerve bundles with interlacing neural tissue in background of spindle shaped cells along with myxoid areas and numerous blood vessels.

Discussion: The NF1 gene responsible for the disease is located on chromosome 17 at locus 17q11.2 that codes for the protein neurofibromin. The frequency of neomutations is particularly high and almost half of the cases are sporadic. NF1 is characterized by a wide variability of clinical expressions, even within a given family. Majority of patients can be diagnosed only after thorough physical examination.

Conclusion: The wide variation of the clinical expression, the tumor risk and the totally unpredictable evolution of the disease impose regular monitoring of NF1 patients. This surveillance is mainly clinical and has to be adapted to the patient's age in order to assure early management of complications.

1. Introduction

Plexiform neurofibroma is an irregular, thick and non circumscribed tumor of peripheral nerve sheath which can involve multiple nerve fascicles. This disease is a rare entity and occurs in approximately 5–15% patients with neurofibromatosis 1 (NF-1). These are slow growing, painless and locally infiltrating tumors. The consistency of the lesion is compared to 'bag of worms' [1]. The pattern of inheritance is autosomal dominant. The size of lesion can increase during pregnancy and puberty [2]. The disease is manifested by developmental changes in bone, skin and nervous system. Its incidence is estimated to be 1/2500 births per year and its penetrance is almost complete by 5 years of age. The NF1 gene responsible for the disease is located on chromosome 17 at locus 17q11.2 that codes for protein neurofibromin [3,4]. The frequency of neomutations is particularly high and almost half of the cases are sporadic. Neurofibromin acts as a tumour suppressor gene by down regulation of RAS gene product, its mutation results in proliferation of

multiple neurofibromas and other tumors [5]. It involves axilla, thigh, buttocks, orbit, mediastinum, retroperitoneum, tongue, deep soft tissues, gastrointestinal tract and many other organs. There are 50% chances of transmission of the disease from parents to their children, regardless of sex. Between 30 and 50% of the patients have neomutations: neither of their parents has NF1 [3]. The SCARE criteria were utilized for this case report [6]. The parents of the patient gave the consent for the study to be published.

2. Case report

A 13 years old boy visited outpatient department of Ophthalmology of SGT Hospital and Research institute, Gurugram, Haryana with complaints of swelling of right eyelid and forehead for 2 years (Fig. 1). Mass was painless and it was hanging down. The swelling was gradual in onset and progressive in nature. Local examination revealed trichiasis and entropion of lower lid. On palpation there was no tenderness and mass

* Corresponding author. Department of Pathology, North DMC Medical College & Hindu Rao Hospital, Delhi, India.

E-mail addresses: poojaposwal1996@gmail.com (P. Poswal), namitabhutani89@gmail.com (N. Bhutani), jugs.arora915@gmail.com (S. Arora), rkguptapath@gmail.com (R. Kumar).

<https://doi.org/10.1016/j.amsu.2020.08.015>

Received 31 May 2020; Received in revised form 4 August 2020; Accepted 5 August 2020

Available online 14 August 2020

2049-0801/© 2020 Published by Elsevier Ltd on behalf of IJS Publishing Group Ltd. This is an open access article under the CC BY license

(<http://creativecommons.org/licenses/by/4.0/>).

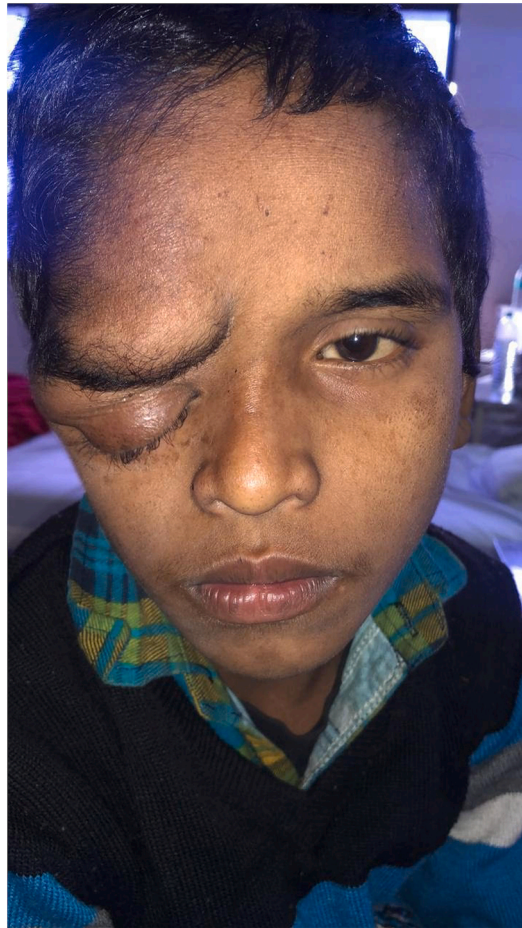

Fig. 1. On clinical examination, swelling of right eyelid and forehead.

was not well circumscribed. There was history of trauma. X-Ray revealed fracture in right lateral orbit wall and temporal part of frontal bone. Non contrast Computed Tomography (NCCT) scan of orbit was done which showed infiltrative soft tissue mass in right pre-orbital region along with right sphenoid wing dysplasia and fracture of right lateral orbit wall. MRI of orbit was suggestive of NF-1 with right orbital plexiform neurofibroma. Multiple café au lait spots were present on back

and abdomen (Fig. 2). There was no history of similar complaints in any family member or distant relatives. Lid reconstruction with lateral canthopexy was done along with forehead tumor debulking (Fig. 3). After surgical removal of the mass, the tissue was sent for histopathological evaluation. On gross examination, mass comprised of 3 soft tissue pieces (Fig. 4). Out of three, two pieces were partly skin covered measuring $6 \times 2.5 \times 1$ cm and $2 \times 1 \times 0.5$ cm respectively. Amongst

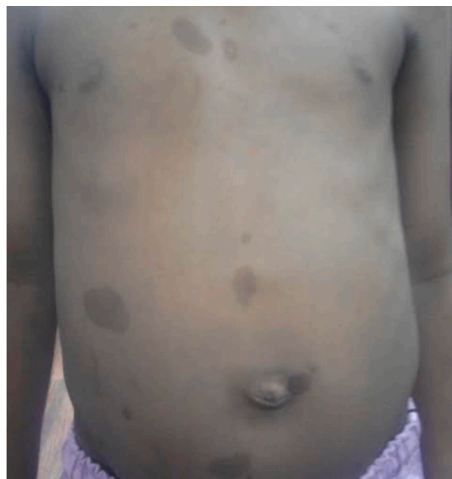

Fig. 2. Multiple café au lait spots were present on back and abdomen.

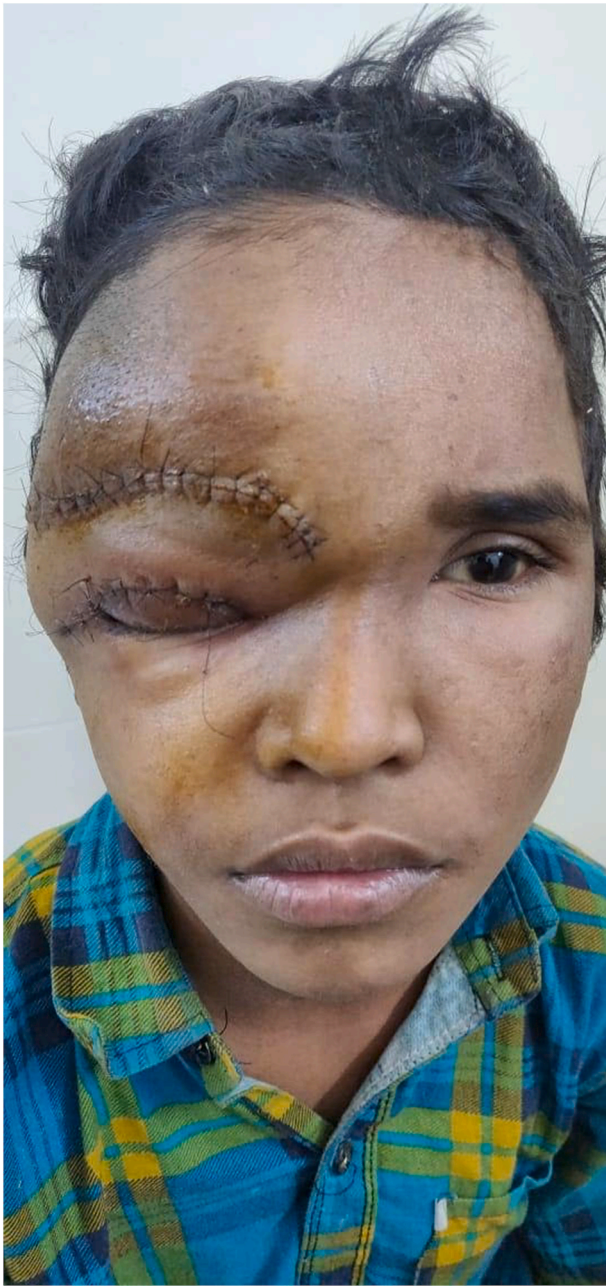

Fig. 3. Lid reconstruction with lateral canthopexy was done along with forehead tumor debulking.

largest soft tissue mass, there were multiple tubular structures. Microscopy of the tissue submitted revealed an unencapsulated tumor mass comprising of well organized mixture of multiple nerve bundles with interlacing neural tissue in background of spindle shaped cells along with myxoid areas and numerous blood vessels (Fig. 5A–D). Tumor was seen infiltrating into the surrounding adnexa, subcutaneous fat and muscles. Immunostain for S-100 was applied, which was found to be immunoreactive. Parents of patients have given the permission for publication of this case report.

3. Discussion

Neurofibromatosis (NF) is a group of disorders that spread either just under the skin or deeper in the body. It originates from nerve sheath

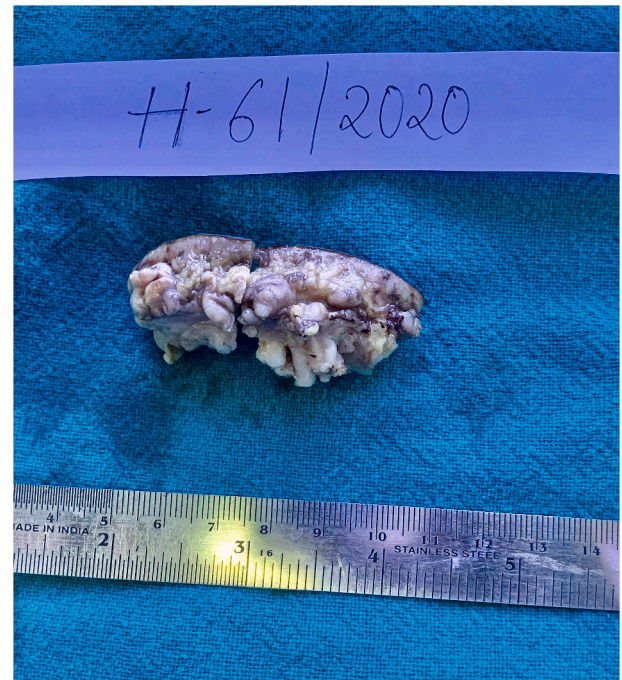


Fig. 4. Gross examination revealed tumor mass in multiple pieces, largest measuring 6x2.5x1 cm. Tumor was encapsulated.

cells, subcutaneous or visceral peripheral nerves and can involve multiple fascicles [4]. Plexiform neurofibromas are uncommon and occur in almost 5–15% patients with NF-1 [1]. These are slow growing, painless and locally infiltrating tumors. Most commonly involved cranial nerves are fifth, ninth and tenth [7]. These tumors can cause minor discomfort to extreme pain [8].

In 1988, the consensus conference of the National Institute of Health in Bethesda (MD, USA) defined 7 main criteria for the diagnosis of NF1. This entity, NF1, is diagnosed when 2 of these following features are present in the same individual (NIH, 1988): (a) First-degree relative afflicted (parent, sibling or child), (b) at least 6 café-au-lait macules: > 1.5 cm after puberty and >0.5 cm in prepubertal individuals, (c) freckling in the axillary or inguinal region (Crowe sign), (d) at least 2 neurofibromas of any type or at least 1 plexiform neurofibroma, (e) Optic nerve glioma, (f) at least 2 Lisch nodules (iris hamartoma) and (g) a characteristic bone lesion, which can be: pseudoarthrosis, sphenoid wing dysplasia and thinning of long bone cortex [3,7,8].

NF1 is a tumor-suppressor gene. The mutations affecting this type of gene are inherited by recessive transmission. Functional inactivation of the 2 alleles of the gene is necessary to cause the deregulation region [5]. The clinical picture includes: facial dysmorphism, the early appearance of numerous cutaneous neurofibromas, learning difficulties and/or mental retardation. In an adult, diagnosis of NF1 is usually made easily, based on physical examination. But in a child, café-au-lait macules can remain the only manifestation for a long time. They can be the most visible manifestation of the disease but usually these do not transform into malignant tumors.

Dysplasia of the long bones is present since birth but is detected when a deformation appears during growth. Optic chiasma or nerve gliomas become clinically symptomatic in young children around the age of 5 years. Asymptomatic forms can remain silent or regress in certain cases. Other clinical signs found in a high number of NF1 patients are: macrocephaly, hypopigmented spots, small stature and juvenile xanthogranulomas (rare).

Neurological complications include neuropsychological disorders

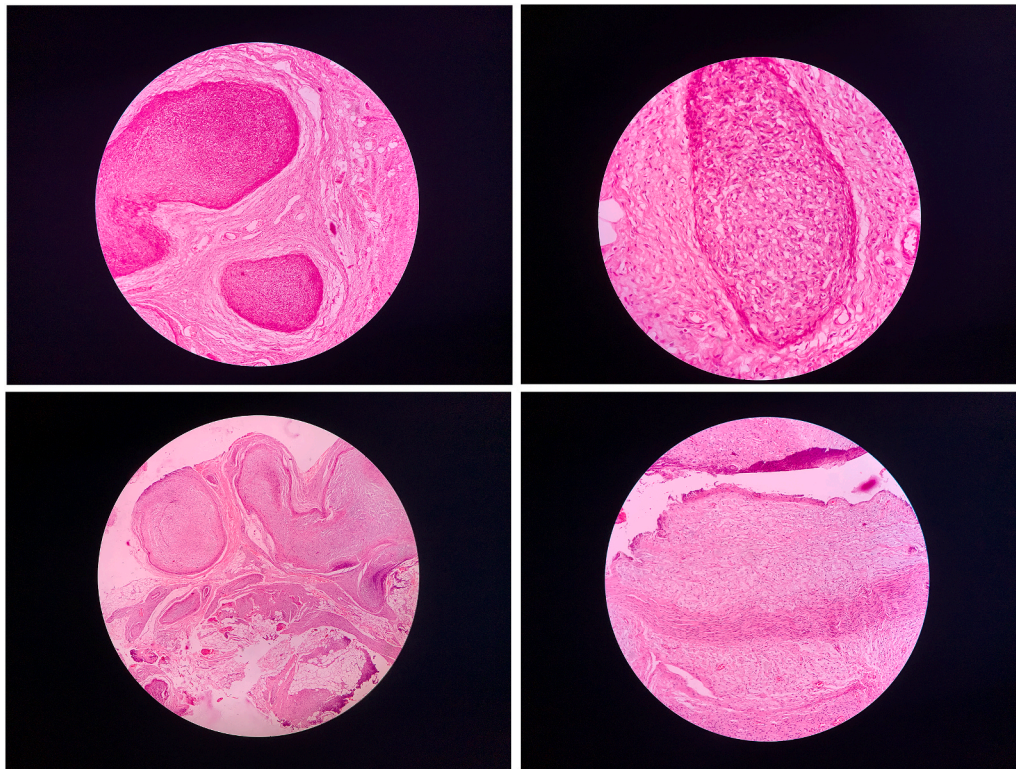


Fig. 5. A-D: Microscopy of the mass revealed an unencapsulated tumor comprising of well organized mixture of multiple nerve bundles with interlacing neural tissue in background of spindle shaped cells along with myxoid areas and numerous blood vessels (H&E-400X).

with cognitive deficits and learning difficulties. Approximately 6% of the patients present with arterial hypertension. Majority of tumors are benign (neurofibromas). Although, malignant transformation of these tumors is quite rare but is responsible for the severity of NF-1 [3].

The evolution of our knowledge has enabled the unambiguous differentiation between NF1 (localized to chromosome 17) and NF2 (localized to chromosome 22). The other differentials of the disease are segmental neurofibromatosis, autosomal dominant isolated café-au-lait macules (or NF6), Watson syndrome (pulmonic stenosis with café-au-lait macules), Noonan syndrome and McCune–Albright syndrome or LEOPARD (multiple lentiginos) syndrome [3].

The Treatment for NF depends on the patient's age, health, and medical history, symptoms, which nerves are affected and the expected progression of the disease. Although there is no known cure for NF, surgery and other treatments can help to relieve symptoms.

Surgery, radiation, and monitoring are the three main treatment approaches. The U.S. Food and Drug Administration (FDA) has approved selumetinib for use in patients with inoperable plexiform neurofibromas. In the clinical trials, over 70% of NF patients with inoperable plexiform neurofibromas saw tumor size reduction anywhere from 20 to 60% in size. In addition to both visible and actual tumor reduction, patients reported higher-quality physical function, reduced pain, improved mobility, and enhanced emotional and psychological status [9].

4. Conclusion

We hereby report a rare case of plexiform neurofibroma of right eye with neurofibromatosis 1 or von Recklinghausen's disease. The presentation of patients with NF-1 is extremely variable as the disorder can affect many organs, so it should be closely monitored. NF-1 is progressive in nature. Early diagnosis is crucial for patient to prevent further complications of the disease. Psychological counseling and long term follow up is mandatory to improve quality of life.

Source(s) of support in the form of grants, equipment, drugs, or all of these

None.

Declaration of competing interestCOI

None.

Author contribution

Please specify the contribution of each author to the paper, e.g. study concept or design, data collection, data analysis or interpretation, writing the paper, others, who have contributed in other ways should be listed as contributors.

Guarantor

The Guarantor is the one or more people who accept full responsibility for the work and/or the conduct of the study, had access to the data, and controlled the decision to publish.

Patient consent

Written informed consent was taken from the parents of patient.

Provenance and peer review

Not commissioned, externally peer reviewed.

Acknowledgement

None.

Appendix A. Supplementary data

Supplementary data to this article can be found online at <https://doi.org/10.1016/j.amsu.2020.08.015>.

References

- [1] K. Patil, V.G. Mahima, S.K. Shetty, K. Lahari, Facial plexiform neurofibroma in a child with neurofibromatosis type I: a case report, *J. Indian Soc. Pedod. Prev. Dent.* 25 (1) (2007) 30.
- [2] J.R. Kam, T.N. Helm, Neurofibromatosis. www.emedicine.medscape.com/article/1112001-overview.
- [3] S. Pinson, P. Wolkenstein, Neurofibromatosis type 1 or Von Recklinghausen's disease, *Rev. Med. Interne* 26 (3) (2005) 196–215.
- [4] Adil A, Singh AK. Neurofibromatosis Type 1 (Von Recklinghausen). europepmc.org/books/n/statpearls/article-25986. 2019 June.
- [5] V.C. Williams, J. Lucas, M.A. Babcock, D.H. Gutmann, B. Korf, B.L. Maria, Neurofibromatosis type 1 revisited, *Pediatrics* 123 (1) (2009) 124–133.
- [6] R.A. Agha, M.R. Borrelli, R. Farwana, K. Koshy, A. Fowler, D.P. Orgill, For the SCARE Group, The SCARE 2018 statement: updating consensus surgical CAse REport (SCARE) guidelines, *Int. J. Surg.* 60 (2018) 132–136.
- [7] K.S. Cunha, E.P. Barboza, E.P. Dias, F.M. Oliveira, Neurofibromatosis type I with periodontal manifestation. A case report and literature review, *Br. Dent. J.* 196 (8) (2004) 457–460.
- [8] J.R. Geist, D.L. Gander, S.J. Stefanac, Oral manifestations of neurofibromatosis type 1 and 2, *Oral Surg. Oral Med. Oral Pathol.* 73 (1992) 376–382.
- [9] R.E. Ferner, S.M. Huson, N. Thomas, et al., Guidelines for the diagnosis and management of individuals with neurofibromatosis 1, *J. Med. Genet.* 44 (2) (2007) 81–88.