



Contents lists available at ScienceDirect

International Journal of Surgery Case Reports

journal homepage: www.casereports.com

Jejunal diverticula with perforation in non steroidal anti inflammatory drug user: A case report

Shobhit Gupta^a, Naveen Kumar^{b,*}^a R.G. Kar Medical College and Hospital, 1, Kshudiram Bose Sarani, Kolkata, West Bengal, 700004, India^b PGIMER & DR. R.M.L. Hospital, New Delhi, 110001, India

ARTICLE INFO

Article history:

Received 26 January 2017

Received in revised form 10 July 2017

Accepted 15 July 2017

Available online 22 July 2017

Keywords:

Jejunum

Diverticula

NSAID

Perforation

Laparotomy

Segmental resection

Anastomosis

ABSTRACT

INTRODUCTION: Multiple diverticulosis of the jejunum constitutes an uncommon pathology of the small bowel. The disease is often asymptomatic and must be taken into consideration in cases of unexplained malabsorption, anemia, chronic abdominal pain and discomfort.

CASE PRESENTATION: We are thereby reporting a 50 yr patient on chronic NSAID ingestion presenting to us with acute abdomen. On exploration, there were multiple (14) jejunal diverticuli on both mesenteric and antimesenteric border from 10 cm to 90 cm distal to duodenojejunal junction with a perforation in one of the diverticulum, 80 cm distal to the ligament of Treitz. We performed a resection of a 80-cm jejunal segment involving the multiple diverticula and an end to end jejunojejunostomy.

DISCUSSION: Drug-induced jejunal perforation is known, but jejunal diverticular perforation related to steroid/treatment has been reported only once previously. Long-term NSAID therapy usually induces clinically silent enteropathy characterized by increased intestinal permeability and inflammation. Jejunal diverticulosis is a challenging disorder from a diagnostic perspective, with no truly reliable diagnostic tests. The current treatment of choice for perforated jejunal diverticula causing generalized peritonitis is prompt laparotomy with segmental intestinal resection and primary anastomosis.

CONCLUSION: Jejunal diverticula are rare lesions, and their perforation never features in the list of diagnoses for acute abdomen, especially in this part of the world. Further this unique case report opens the doors for further research to prove an association between NSAID use and diverticular perforation which itself is a very rare entity.

© 2017 Published by Elsevier Ltd on behalf of IJS Publishing Group Ltd. This is an open access article under the CC BY-NC-ND license (<http://creativecommons.org/licenses/by-nc-nd/4.0/>).

1. Introduction

Multiple diverticulosis of the jejunum constitutes an uncommon pathology of the small bowel [9]. The disease is often asymptomatic and must be taken into consideration in cases of unexplained malabsorption, anemia, chronic abdominal pain and discomfort [9]. Related complications such as diverticulitis, hemorrhage, obstruction and perforation present high mortality and morbidity rates. Drug-induced jejunal perforation is known, but jejunal diverticular perforation related to steroid/treatment has been reported only once previously [16]. Long-term NSAID therapy usually induces clinically silent enteropathy characterized by increased intestinal permeability and inflammation [17]. In patients with diverticular disease, NSAID use increases the risk of severe diverticular infection and perforation. Jejunal diverticulosis is a challenging disorder from

a diagnostic perspective, with no truly reliable diagnostic tests. We are thereby reporting a 50 yr patient on chronic NSAID ingestion presenting to us with acute abdomen, on exploration of which there was jejunal diverticular perforation.

2. Case report

A 50-year old male patient was admitted to our emergency department with an acute onset of abdominal pain and nausea over 24 h. He had a history of intermittent abdominal pain mostly localized to epigastrium for 5 years. He was suffering from a chronic pain on back of his neck (? Cervical spondylosis) for which he was on chronic treatment with diclofenac plus paracetamol combination for 15 years prescribed by some local doctor. On physical examination he was having average built with temperature of 39.8 °C and pulse was 106, BP 110/72. Examination of the abdomen revealed muscular guarding and rebound tenderness in all quadrants of the abdomen. There Bowel sounds were hypoactive. His white blood cell count was 16.500/mm³ and hemoglobin level was 13.2 gm/dL. Radiographic images showed no free gas under diaphragm and

Abbreviation: NSAID, non steroidal anti inflammatory drugs.

* Corresponding author.

E-mail address: pixelfinance2000@gmail.com (S. Gupta).

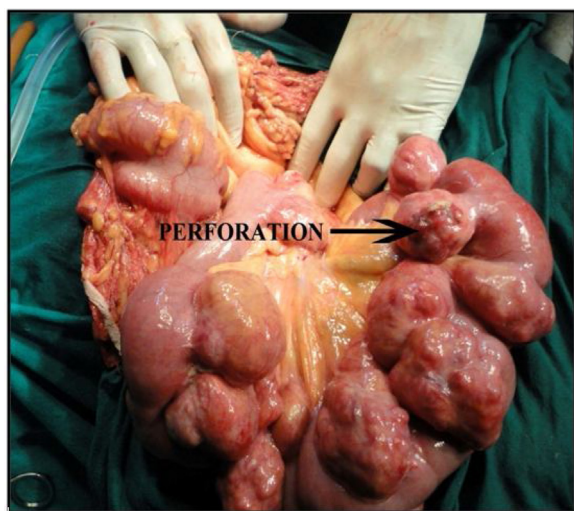


Fig. 1. Jejunal diverticula with perforation.

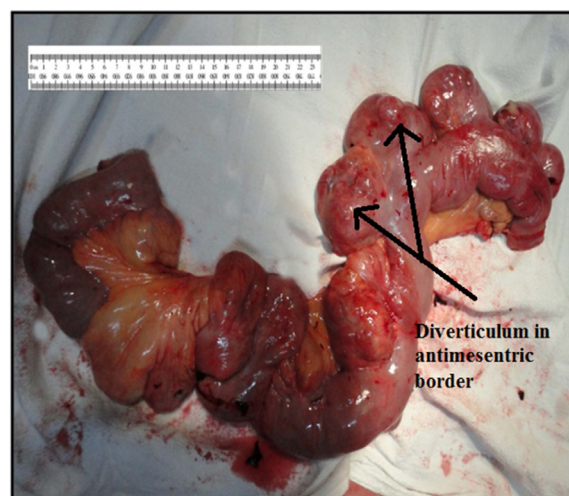


Fig. 2. Resected 80-cm Jejunal segment involving the multiple diverticula.

multiple air fluid levels suggestive of ileus were noted. The patient was initially resuscitated with intravenous fluids and intravenous third generation cephalosporins were administered. Patient kept nil per orally with nasogastric tube for aspiration. An emergent abdominal exploration was performed (Fig. 1).

At the time of surgery, there were flakes in the abdominal cavity, with multiple (14) jejunal diverticuli on both mesenteric and antimesenteric border from 10 cm to 90 cm distal to duodenojejunal junction, there were characteristically multiple secondary diverticular outpouchings in 10 diverticula with unhealthy wall with a perforation in one of the diverticulum, 80 cm distal to the ligament of Treitz. The perforated diverticulum was wrapped by the Omentum and sealed with flakes. Although the perforated diverticulum was sealed off but as described earlier there were multiple secondary diverticulas with unhealthy walls with peritonitis, patient could not be managed with conservative treatment. Hence, we performed a resection of a 80-cm jejunal segment involving the multiple

diverticula and an end to end jejunojejunojejunostomy. The patient's postoperative period was uneventful. He began oral intake on postoperative day 3. The abdominal drains were removed on day 4. Patient developed wound infection at suture site which was managed with dressings and antibiotics. Patient was discharged on postoperative day 8. Histological examination of the perforated diverticulum revealed nonspecific inflammatory changes.

3. Discussion

Jejunal diverticulosis was first described by Somerling in 1794 and by Sir Astley Cooper in 1807 [1]. Autopsy studies reveal an incidence between 1.3% and 4.6%, whereas radiologic studies show an incidence between 0.02% and 2.3% [1]. Over 80% of jejunal diverticula occur in patients 70 years and older [2]. But in our case patient age is 50 yrs. Jejunal diverticulosis may present acutely with complications in 10–30% of all patients [8].

The incidence has been found to be higher in men (58%) than women (42%) [3]. These false diverticula are acquired outpouchings of mucosa commonly found on the mesenteric border of the jejunum [1]. These pulsion-type false diverticula occur along the mesenteric border of the intestine, where blood vessels pierce the muscularis layer of the bowel wall, causing weak areas to develop. These weak areas lead to herniation of mucosa, submucosa, and serosa while excluding the muscularis layer. [2] The most common

part of the small bowel to be affected by diverticula is the proximal jejunum (75%), followed by the distal (20%) and then the ileum (5%), in our case also it was present from 10 cm to 90 cm distal to DJ flexure (Fig. 2).

Seventy seven percent of cases demonstrated multiple as opposed to solitary diverticula [4]

Jejunal and jejuno-ileal localizations are less frequent involved than duodenal, but more prone to develop complications [5].

Of these diverticula, 35% are associated with colonic diverticula, 26% with duodenal diverticula and 2% with oesophageal diverticula, respectively [6,7].

The commonest GI diverticulum is sigmoid colon diverticulum. NSAIDs have been implicated as a risk factor for perforation in diverticulitis [19]. NSAIDs inhibit the cyclo-oxygenase enzyme and cause topical mucosal damage, increasing colonic permeability. Besides, they reduce prostaglandin synthesis, which is important in maintaining an effective mucosal barrier [19].

The disease is often asymptomatic and must be taken into consideration in cases of unexplained malabsorption, anemia, chronic abdominal pain and discomfort [9]. In our case also, patient was complaining of recurrent epigastric pain for last 5 yrs.

Tsiotos et al. analysed 112 cases of jejunoileal diverticulosis and of these, 42% of cases were asymptomatic. The remaining patients had symptoms of diarrhoea (58%), chronic abdominal pain (51%) or bloating (44%). Interestingly Tsiotos et al. also found an association with Raynaud's phenomenon and systemic sclerosis [3].

Complication rates as high as 46% for jejunal diverticulosis have been reported and are known to be fatal at times [10]. More acute complications are perforation, peritonitis, bleeding, and fistula formation [2].

Largest study till date was review by Chendrasekhar et al [11] in 1995, they provided individual patient data for all case reports previously published, of 13 patients between 1971 and 1994 [11].

There seems to be a shift towards conservative treatment when properly diagnosed, a much higher percentage of accurate diagnosis, and small bowel resection is usually performed with lower mortality rates [12].

Perforation mostly occurs into the mesenteric leaves of the jejunum, leading to a mesenteric abscess. Although the perforation may be contained within the mesentery, preventing leakage into the peritoneal cavity and resultant peritonitis, it also leads to a delay in diagnosis because the classical physical examination findings of an acute abdomen are absent, which may prove disastrous when frail or elderly patients are involved [15].

Instigating factors for perforation were shown to be related to a necrotizing inflammatory reaction in 82% of cases, followed by blunt trauma (12%) and foreign body impaction (6%) [6]. Cocaine sniffing has also been noted as a risk factor [13]. Association with amyloid disease or malignancy such as lympho sarcoma, MEN-I or fibrous histiocytoma has also been stated [14].

In our case no such association was found, no family history of such malignancy was found. Based upon the clinical findings along with radiological findings and history of long term use of NSAIDS, patient was suspected of enteric perforation with peritonitis, though the suspicion of jejunal diverticular perforation could not be made with the mentioned radiological findings beforehand. As the patient came to us at emergency and imaging modality other than the X –Ray and ultrasound facilities were not available in emergency setting in our hospital and moreover patient was from economically very backward society thus further expensive tests could not be conducted. Patient used to take some oral analgesics (NSAIDS) for last 15 years which could be a contributing factor for the diverticular perforation, as it has been stated in previous study [16], but it was not proved histologically, as HPE report stated non specific inflammation, and no impacted tablets were found on HPE. As the patient came in emergency with features suggestive of perforation with peritonitis, we did not have much options such as of diagnostic laparoscopy available in emergency at our centre, we had to do emergent laprotomy of the patient.

Drug-induced jejunal perforation is known, but jejunal diverticular perforation related to steroid/NSAIDS treatment has been reported only once previously [16]. Long-term NSAID therapy usually induces clinically silent enteropathy characterized by increased intestinal permeability and inflammation [17]. In patients with diverticular disease, NSAID use increases the risk of severe diverticular infection and perforation [18].

Jejunal diverticulosis is a challenging disorder from a diagnostic perspective, with no truly reliable diagnostic tests.

However, the current treatment of choice for perforated jejunal diverticula causing generalized peritonitis is prompt laparotomy with segmental intestinal resection and primary anastomosis. Exploratory laparotomy and resection of affected intestinal segment with primary anastomosis is mandatory in case of perforation, abscesses and obstruction [9]. If diverticula are extensive, resection may have to be limited to include only the segment containing the perforated diverticulum and to leave a segment of small bowel that still contains non-perforated diverticula in order to avoid short bowel syndrome. A total laparoscopic treatment of sizable jejunal diverticulum has been recently reported. Laparoscopy in the setting of diffusely dilated small bowel loops is difficult because the working space provided by the pneumoperitoneum is reduced. Further, small bowel manipulation and retraction in this setting carries a higher risk of serosal tears or enterotomy. Furthermore laparoscopic facility is not available in emergency settings at many centres like in our case.

The complications related to the jejunal diverticula, when they arise, lead to a diagnostic dilemma since jejunal diverticula are not high on the list of differentials for acute abdomen, especially in India.

4. Conclusion

Jejunal diverticula are rare lesions, and their perforation never features in the list of diagnoses for acute abdomen, especially in this part of the world. No strong association between diverticulosis and NSAID could be proved with confirmation, but no other comorbidity except this suggests an association with it. Further this unique case report opens the doors for further research to prove an association between NSAID use and diverticular perforation which itself is a

very rare entity. Moreover in our case the age was 50 yrs, thus we should have this differential diagnosis in mind in such age group also and not just elderly as stated in previous case reports.

The work has been reported in line with the scare criteria [20].

Conflicts of interest

None.

Funding

None.

Ethical approval

None.

Consent

Duly informed written and signed consent was obtained from patient.

Author contribution

Dr. Shobhit Gupta – Who performed the surgery.

Dr. Naveen Kumar – Who has written the paper and collected the data.

Guarantor

Dr. Shobhit Gupta, Dr. Naveen Kumar.

References

- [1] R.A. Williams, D.D. Davidson, A.I. Serota, S.E. Wilson, Surgical problems of diverticula of the small intestine, *Surg. Gynecol. Obstet.* 152 (1981) 621–626.
- [2] C.B. Ross, W.O. Richards, K.W. Sharp, et al., Diverticular disease of the jejunum and its complications, *Am. Surg.* 56 (5) (1990) 319–324.
- [3] G.G. Tsiotos, M.B. Farnell, D.M. Ilstup, Non-Meckelian jejunal or ileal diverticulosis: an analysis of 112 cases, *Surgery* 116 (1994) 726–732.
- [4] M. Lempinen, K. Salmela, E. Kempainen, Jejunal diverticulosis: a potentially dangerous entity, *Scand. J. Gastroenterol.* 39 (2004) 905–909.
- [5] R.E. Miller, R.E. McCabe, P.F. Salomon, W.G. Knox, Surgical complications of small bowel diverticula exclusive of Meckel's, *Ann. Surg.* 171 (1970) 202–210.
- [6] R.H. Baskin Jr., MAYO CW: Jejunal diverticulosis; a clinical study of 87 cases, *Surg. Clin. North Am.* 152 (1952) 1185–1196.
- [7] R.E. Benson, C.F. Dixon, J.M. Waugh, Non-Meckelian diverticula of the jejunum and ileum, *Ann. Surg.* 118 (1943) 377–393.
- [8] R. Akhrass, M.B. Yaffe, C. Fischer, J. Ponsky, J.M. Shuck, Small bowel diverticulosis: perceptions and reality, *J. Am. Coll. Surg.* 184 (1997) 383–388.
- [9] Evangelos Falidas, Konstantinos Vlachos, Stavros Mathioulakis, Fotis Archontovasilis, Constantinos Villias, Multiple giant diverticula of the jejunum causing intestinal obstruction: report of a case and review of the literature, *World J. Emergency Surg.* 6 (2011) 8.
- [10] N.M. Davies, J.Y. Saleh, N.M. Skjodt, Detection and prevention of NSAID-induced enteropathy, *J. Pharm. Pharmaceut. Sci.* 3 (2000) 137–155.
- [11] A. Chendrasekhar, G.A. Timberlake, Perforated jejunal diverticula: an analysis of reported cases, *Am. Surg.* 61 (1995) 984–988.
- [12] Milan Spasojevic, Jens marius naesgaard, dejan ignjatovic, perforated midgut diverticulitis: revisited, *World J. Gastroenterol.* 18 (34) (2012) 4714–4720.
- [13] E. Albu, V. Parikh, S. Alankar, et al., Perforated solitary jejunal diverticulum, *South. Med. J.* 88 (5) (1995) 575–576.
- [14] A. Al-Samarrai, Perforation of jejunal diverticulum, *Saudi J. Gastroenterol.* 8 (2002) 62–63.
- [15] J.L. Herrington Jr., Perforation of acquired diverticula of the jejunum. Analysis of reported cases, *Surgery* 51 (4) (1962) 426–433.
- [16] C. Palanivelu, M. Rangarajan, S. Rajapandian, et al., Perforation of jejunal diverticula in steroids and nonsteroidal anti-inflammatory drug abusers: a case series, *World J. Surg.* 32 (2008) 1420, <http://dx.doi.org/10.1007/s00268-008-9469-0>.
- [17] H. Goh, R. Bourne, Non-steroidal anti-inflammatory drugs and perforated diverticular disease: a case-control study, *Ann. R. Coll. Surg. Engl.* 84 (March(2)) (2002) 93–96.

- [18] K. Piekarek, L.A. Israelsson, Perforated colonic diverticular disease: the importance of NSAIDs, opioids, corticosteroids, and calcium channel blockers, *Int. J. Colorectal Dis.* 23 (2008) 1193–1197.
- [19] J. Vermeulen, E. Ven der Harst, J.F. Lange, Pathophysiology and prevention of diverticulitis and perforation, *Neth. J. Med.* 68 (October(10)) (2010) 303.
- [20] R.A. Agha, A.J. Fowler, A. Saetta, I. Barai, S. Rajmohan, Orgill DP and the SCARE group: the SCARE statement: consensus-based surgical case report guidelines, *Int. J. Surg.* 34 (2016) 180–186.

Open Access

This article is published Open Access at scimedirect.com. It is distributed under the [IJSCR Supplemental terms and conditions](#), which permits unrestricted non commercial use, distribution, and reproduction in any medium, provided the original authors and source are credited.