

Received: 2019.09.09
Accepted: 2019.10.03
Published: 2020.01.21

Direct Anterior Approach Versus Posterolateral Approach for Hemiarthroplasty in the Treatment of Displaced Femoral Neck Fractures in Geriatric Patients

Authors' Contribution:
Study Design A
Data Collection B
Statistical Analysis C
Data Interpretation D
Manuscript Preparation E
Literature Search F
Funds Collection G

ABCDEF **Cagri Neyisci**
ABCDEF **Yusuf Erdem**
ABCDEF **Ahmet Burak Bilekli**
ABCDEF **Dogan Bek**

Department of Orthopedics and Traumatology, Gulhane Training and Research Hospital, Ankara, Turkey

Corresponding Author: Yusuf Erdem, e-mail: yerdem81@gmail.com
Source of support: Departmental sources

Background: In the present study, we aimed to evaluate early clinical and biochemical outcomes of direct anterior approach (DAA) versus posterolateral approach (PLA) for hemiarthroplasty in the treatment of displaced femoral neck fractures in geriatric patients.





Material/Methods: Between September 2012 and September 2017, a total of 110 patients who underwent hemiarthroplasty for displaced femoral neck fractures were retrospectively analyzed. The patients were divided into 2 groups according to the surgical technique PLA (Group 1, n=54) and DAA (Group 2, n=56). Clinical and biochemical results were compared.

Results: There was no significant difference in the demographic characteristics of the patients, fixation type, and follow-up ($P>0.05$). However, there was a significant difference in the duration of surgery, amount of blood transfusion, change from baseline in postoperative hemoglobin levels, amount of intraoperative gauze dressing, amount of drainage fluid from the surgical wound, postoperative VAS scores, incision length, length of hospital stay, and Barthel Index scores in favor of DAA group ($P<0.05$). There was no significant difference in the degree of mobilization ($P>0.05$). None of the patients had postoperative complications in Group 1, while 3 patients in Group 2 developed a lateral femoral cutaneous nerve lesion and one patient had a missed iatrogenic fracture of the greater trochanter.

Conclusions: Our study results suggest that early clinical and biochemical outcomes are better in DAA than PLA with early return to daily living activities in patients undergoing hemiarthroplasty for displaced femoral neck fractures.

MeSH Keywords: **Femoral Neck Fractures • Geriatrics • Hemiarthroplasty • Surgical Procedures, Minimally Invasive**

Full-text PDF: <https://www.medscimonit.com/abstract/index/idArt/919993>

 2871  3  1  30



Background

Femoral neck fractures are serious injuries in elderly due to the increasing number of advanced age population and comorbidities, which is associated with extremely morbidity and mortality rates [1–4]. Lung infections, deep vein thrombosis, muscular dystrophy, and pressure ulcers are the leading causes of comorbidities [2]. The need for a single or multiple operation also increases postoperative complications and mortality in this patient population [2]. Due to multiple comorbidities, the use of operation techniques with minimum stress and early mobilization to return them to their daily living activities as soon as possible are of utmost importance to prevent postoperative complications [5–8].

Treatment options of displaced femoral neck fractures include internal fixation and partial or total hip arthroplasty [9,10]. Partial hip arthroplasty is mostly preferred in patients with sedentary lifestyle, while total hip arthroplasty is recommended for physically active individuals. In a study, internal fixation was more frequently associated with need for revision surgery than hemiarthroplasty in patients with displaced femoral neck fractures [11]. As hemiarthroplasty offers early mobilization with reduced need for revision surgery, it has been used widely in elderly aged ≥ 65 years old with sedentary lifestyle [12–14].

In recent years, minimally invasive surgery has become widely adapted among surgeons for elderly patients, as it is associated with less tissue injury, early mobilization, rapid rehabilitation, and reduced postoperative mortality [15–17]. Minimally invasive total hip arthroplasty and hip hemiarthroplasty using direct anterior approach offers several advantages such as less tissue damage, early mobilization, rapid rehabilitation, and less postoperative pain, due to its true intermuscular and internervous nature [18]. However, there is a limited number of studies in the literature reporting early clinical and biochemical outcomes of hip hemiarthroplasty in patients with displaced femoral neck fractures [19,20].

In the present study, we aimed to evaluate early clinical and biochemical outcomes of direct anterior approach (DAA) versus posterolateral approach (PLA) for hemiarthroplasty in the treatment of displaced femoral neck fractures in geriatric patients.

Material and Methods

Between September 2012 and September 2017, a total of 110 patients who underwent hemiarthroplasty for intracapsular displaced femoral neck fractures were retrospectively analyzed. Only patients with the American Society of Anesthesiologists (ASA) Physical Function Class II–III were included in the study [9,14]. Exclusion criteria were as follows:

unable to mobilize without assistance before femoral neck fracture; having a pathological fracture or open fracture, an active systemic or local infection, history of infection in the surgical site, malignancy, immobility, rheumatoid arthritis, skin diseases in the surgical site, neurological disorders of the lower limb and/or multiple trauma. A written informed consent was obtained from each patient. The study protocol was approved by the Institutional Review Board. The study was conducted in accordance with the principles of the Declaration of Helsinki.

The patients were divided into 2 groups according to the surgical technique PLA (Group 1, $n=54$) and DAA (Group 2, $n=56$). Cemented hemiarthroplasty was performed in 53 patients (Group 1 $n=28$ and Group 2 $n=25$), while non-cemented hemiarthroplasty was performed in 57 patients (Group 1 $n=26$ and Group 2 $n=31$). Both groups received first-generation cephalosporin for prophylactic antibiotherapy, and a drainage tube was inserted postoperatively. Combined spinal and epidural anesthesia were performed for each patient thus none of the patients need analgesic usage at postoperative day 2. Then basic non-steroidal anti-inflammatory drugs (diclofenac sodium 75 mg oral per day) were used until discharge. Low-molecular-weight heparin (LMWH) was given to avoid deep vein thrombosis during hospitalization and acetylsalicylic acid 100 mg once daily was prescribed for 6 weeks after discharge. All patients were also instructed to wear anti-embolism stockings. All drainage tubes were removed on postoperative day 1 and patients with a hemoglobin level of < 8 g/L were administered blood transfusion. On postoperative day 1, hip and knee strengthening exercises were given and mobilization was attempted using a walker as long as the patient could tolerate pain. All patients were scheduled for follow-up visits at 3 weeks, 6 weeks, 3 months, and 12 months following discharge.

Data including baseline demographic and clinical characteristics of the patients, postoperative degree of mobilization, pre- and postoperative hemoglobin levels, the amount of intra- and postoperative need for blood products, the amount of intraoperative gauze dressing, postoperative pain severity, the amount of drainage fluid from the surgical wound, length of incision, length of hospital stay and medical and/or surgical complications were recorded. Radiological findings including position of the implant, femoral offset, and limb length were also noted. Postoperative pain severity was evaluated using the Visual Analog Scale (VAS) on the day of surgery and night (before 12 AM), on the night of surgery (after 12 AM), on days 1, 2, 3, and 4. The Barthel Index was used to measure activities of daily living [2].

Surgical technique

In Group 1, the Kocher-Langenbeck incision was used to expose the fracture site in lateral position. The gluteus maximus

Table 1. Demographic and clinical characteristics of patients.

	Group 1		Group 2		Total		P
	n	%	n	%	n	%	
Sex, n							
Male	29	54	30	54	59	54	>0.05*
Female	25	46	26	46	51	46	
Total	54	100	56	100	110	100	
Age, year							
<70	0	0	1	2	1	1	>0.05**
70–79	18	33	19	34	37	34	
80–89	26	48	24	43	50	45	
≥90	10	19	12	21	22	20	
Mean±SD	83±7.76		82±6.635		83±7.25		
Range (min–max)	70–99		66–96		66–99		
Fixation type							
Cemented	28	52	25	45	53	48	>0.05*
Non-cemented	26	48	31	55	57	52	
Follow-up, month							
Mean	15±1.7		16±2.3		16±2.1		>0.05**
Range (min–max)	12–18		12–19		12–19		
Comorbidities							
Hypertension	32	59	35	63	67	61	>0.05*
Diabetes mellitus	17	32	19	34	36	33	
Chronic obstructive pulmonary disease	13	24	12	21	25	23	

* Chi-square test; ** independent sample t-test. SD – standard deviation.

was split and the insertion of the short external rotators was cut and hanged through marking sutures. The capsule was opened, and the affected neck was removed. A prosthesis was implanted using an appropriate neck cut and posterior capsule was repaired [5,17,20]. In Group 2, the distal part of the Smith-Peterson incision was used in the supine position as DAA. The interval between the tensor fascia lata and sartorius muscles was passed without muscle incision. The capsule was opened in a manner of reverse L shaped and repaired after implantation. The affected neck was removed, and a prosthesis was implanted using an appropriate neck cut [2,18,21–24]. Group 2 patients were operated as first 56 cases of DAA by a single surgeon (DB) who changed the approach posterior to direct anterior after received training, cadaver and surgeon to surgeon courses for DAA. In both groups, we used intraoperative fluoroscopy to check the position and the size of the components.

Statistical analysis

Statistical analysis was performed using the SPSS version 15.0 software (SPSS Inc., Chicago, IL, USA). Descriptive data were expressed in mean±standard deviation (SD), median (min-max), or number and frequency. The chi-square test was used to compare categorical variables between the groups, while independent t-test was used to compare numerical variables

between the groups. A P value of <0.05 was considered statistically significant.

Results

Of the patients, 59 were males and 51 were females with a mean age of 83±7.25 years (range, 66 to 99 years). In Group 1, 29 patients were males and 25 patients were females with a mean age of 83±7.76 years (range, 70 to 99 years). In Group 2, 30 patients were males and 26 patients were females with a mean age of 82±6.635 years (range, 66 to 96 years). Major comorbidities in each group were hypertension, diabetes mellitus, and chronic obstructive pulmonary disease (Table 1). The mean follow-up was 16±2.1 months (range, 12 to 19 months). There was no significant difference in the demographic characteristics, fixation type, and follow-up duration between the groups. Demographic and clinical characteristics of the patients are shown in Table 1.

The mean duration of surgery was 110 minutes in Group 1 and 90 minutes in Group 2, indicating shorter duration with minimally invasive DAA (Table 2). In addition, there was a significant difference in the duration of surgery, amount of blood transfusion, change from baseline in postoperative hemoglobin levels, amount of intraoperative gauze dressing, amount

Table 2. Intra-operative and post-operative data.

	Group 1	Group 2	P
Duration of surgery (min)			
Mean±SD	110±10.81	90±20.94	<0.001*
Range (min–max)	90–120	45–120	
Amount of blood transfusion (U)			
Mean±SD	1.3±1.17	0.3±0.57	<0.001*
Range (min–max)	0–4	0–2	
Change from baseline in hemoglobin levels (g/L)			
Mean±SD	2.9±1.49	1.75±0.885	<0.001*
Range (min–max)	0.5–6.3	0.1–3.9	
Amount of gauze dressing (n)			
Mean±SD	32±6.32	23±5.88	<0.001*
Range (min–max)	20–40	10–30	
Amount of drainage fluid (mL)			
Mean±SD	188±67.07	162±59.96	<0.05*
Range (min–max)	70–300	50–250	
VAS scores on the night of surgery (until 12 AM)			
Mean±SD	58±18.02	46±16.78	<0.001*
Range (min–max)	20–80	10–70	
VAS scores on the first night			
Mean±SD	53±17.78	42±14.88	<0.05*
Range (min–max)	20–80	10–70	
VAS scores on Day 1			
Mean±SD	45±16.45	37±14.6	<0.05*
Minimum-maximum	10–70	10–60	
VAS scores on Day 2			
Mean±SD	43±16.11	34±13.63	<0.05*
Range (min–max)	10–70	10–60	
VAS scores on Day 3			
Mean±SD	34±14.86	23±8.28	<0.001*
Range (min–max)	10–60	10–40	
VAS scores on Day 4			
Mean±SD	27±14.09	19±5.67	<0.001*
Range (min–max)	10–60	10–30	
Total VAS scores			
Mean±SD	43±15.33	34±10.84	<0.001*
Range (min–max)	13–68	10–53	
Incision length (cm)			
Mean±SD	14±3.04	11.5±2.71	<0.001*
Range (min–max)	10–20	9–20	
Length of hospital stay (day)			
Mean±SD	11.3±2.3	8.2±2.15	<0.001*
Range (min–max)	8–15	5–12	
Barthel Index			
Mean±SD	55±12.9	65±13.5	<0.001*
Range (min–max)	35–75	40–85	
Postoperative complications	0	3 LFCN paresthesia + 1 missed iatrogenic fracture of greater trochanter	<0.05**

* Independent sample t-test; ** Chi-square test. SD – standard deviation; VAS – Visual Analog Scale.

Table 3. Degree of mobilization.

	Group 1		Group 2		P*
	n	%	n	%	
Non-assisted mobilization	30	55	36	64	>0.05
Mobilization with minimum assistance	19	35	18	32	
Mobilization with maximum assistance	3	6	2	4	
No mobilization	2	4	–	–	
Total	54	100	56	100	

* Chi-square test.

of drainage fluid from the surgical wound, postoperative VAS scores, length of incision, length of hospital stay, and Barthel Index scores in favor of DAA group ($P<0.05$) (Table 2). On the other hand, there was no significant difference in the degree of mobilization between the groups ($P>0.05$) (Table 3).

None of the patients had postoperative complications in Group 1, while 3 patients in Group 2 developed a lateral femoral cutaneous nerve (LFCN) lesion. Paresthesia symptoms resolved in 2 of these patients, but not in the remaining patient which required no intervention. In addition, 1 patient had a missed iatrogenic fracture of the greater trochanter at 3-week follow-up in Group 2 which was followed in the clinical setting (Figure 1).

Radiological imaging studies revealed no implant malposition (varus-valgus), collapse, dislocation or loosening and limb length discrepancy in any of the patients.

Discussion

In the present study, we evaluated early clinical and biochemical outcomes of DAA versus PLA for hemiarthroplasty in the treatment of displaced femoral neck fractures in geriatric patients. Our study results showed a statistically significant difference in favor of DAA. This finding indicates that DAA is less invasive than PLA in partial arthroplasty in elderly patients with displaced femoral neck fractures with less surgical stress.

In the literature, there are several studies reporting shorter duration of surgery with DAA, while some others have reported longer duration [2,16]. In our study, with increased experience according to the learning curve of DAA, DAA shortened duration of surgery about 45 minutes. Due to the straightforward nature of DAA, reaching the joint and postoperative closure is more simple and rapid. In addition, supine position offers more comfort and ease than lateral decubitus position. Based on these data, DAA shortens the duration of surgery and exposure to anesthetic agents in parallel with the learning curve.

There are several reports measuring intra- and postoperative blood loss [2,5,17], although they yield controversial results. We believe that comparison of blood loss among the studies is difficult. In a study, minimally invasive procedure offered more advantages in terms of intra- and postoperative blood loss [17]. In our study, we evaluated the amount of intraoperative gauze dressing, change from baseline in postoperative hemoglobin levels, amount of blood transfusion, and amount of drainage fluid from the surgical wound and we found a significant difference between the groups in favor of DAA ($P<0.05$). This finding indicates that minimally invasive nature of DAA is associated with less soft tissue injury and less amount of blood transfusion, which is vital for elderly population.

Reduced pain is one of the major factors which increases the patient satisfaction. In their study, Dorr et al. [17] reported that pain management was more favorable in patients undergoing minimally invasive surgery. In another study, however, Renken et al. [2] found no significant difference in the VAS scores between the patient groups undergoing minimally invasive surgery and conventional treatment [2]. Despite controversial results in the literature, DAA was associated with less postoperative pain and less need for opioids and non-opioid analgesics in patients undergoing total hip arthroplasty [15–18]. Consistent with the literature, a statistically significant improvement in the VAS scores was observed in the DAA group ($P<0.05$). This can be attributed to a shorter incision length, less soft tissue injury, and less inflammation with DAA. In addition, the rate of patient satisfaction is higher in DAA group than PLA group with a statistically significantly shorter incision length in the DAA group ($P<0.05$). This finding suggests that shorter incision length is associated with increased patient satisfaction. Moreover, the length of hospital stay was 3-day shorter in the DAA group ($P<0.05$). This is also associated with decreased health-related cost and increased patient satisfaction.

The most optimal surgical approach for dislocations has been long discussed and posterior approach has been more frequently

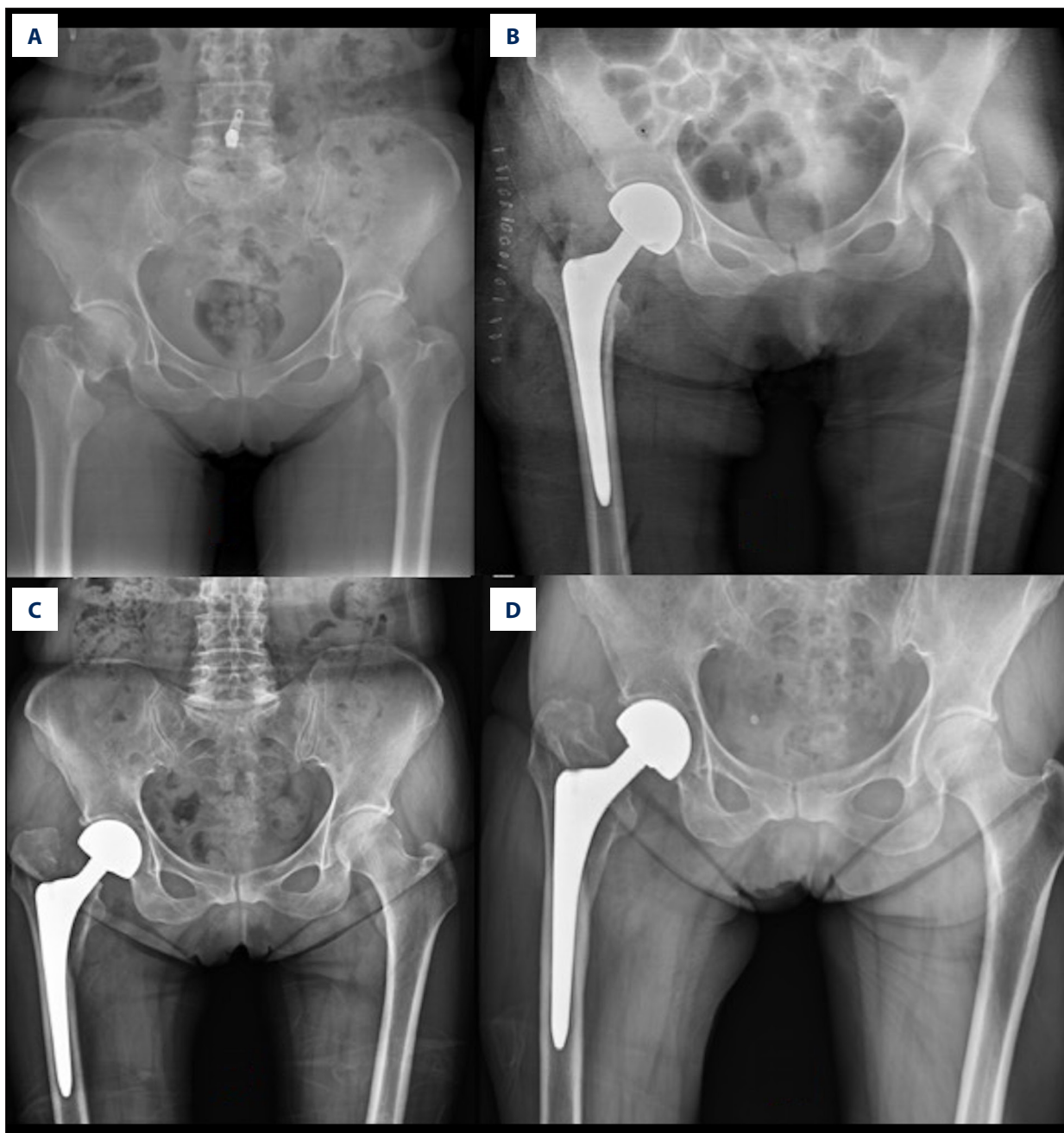


Figure 1. (A) X-ray of right femoral neck fracture of a 78-year-old patient in the DAA group; (B) immediate postoperative x-ray is normal; (C) a missed iatrogenic fracture of the greater trochanter extending below trochanter minor is observed on x-ray at postoperative third weeks; (D) union of fracture sites are observed at 3-month follow-up.

associated with dislocations [19,20,25]. Enocson et al. [20] reported that PLA was the major risk factor for dislocations, although age, sex, and surgical experience did not affect the dislocation rate. In the aforementioned study, dislocation rate was found in 6.9% of the patients without posterior capsular repair and in 3.9% of the patients with posterior capsular repair. In addition, the authors highlighted that the dislocation rate was higher even if the capsular repair was performed

through PLA, rather than anterior approach. In another study, Bush et al. [25] reported that none of the patients in the anterior approach group had dislocations, while 4.5% of the patients undergoing posterior approach had. In our study, none of the patients in either group developed dislocations. With the introduction of posterior soft tissue repair techniques, several reports have demonstrated no significant difference in the dislocation rate between the anterior and posterior approach [5].

Nonetheless, DAA seems to be more feasible in elderly patients particularly with cognitive impairment, as it is an intermuscular approach which offers side-to-side repair with a more anatomical capsular repair without bone fixation as in the posterior repair technique.

Lateral femoral cutaneous nerve injury is a DAA-specific complication. In a study, Lovell et al. [23] reported that less than 5% of the patients developed transient paresthesia caused by the distal lateral femur innervated by the LFCN and paresthesia occurred in lateral femur and distal to incision in almost all patients. In addition, true meralgia paresthetica was seen in less than 1% of the patients [23]. To preserve the LFCN, the tensor fascia lata muscle is longitudinally incised from the midline and the fascia is eliminated medially and the trunk is eliminated laterally. Through the surgical procedure, the nerve is better preserved without contact to the medial subcutaneous fat bed. The LFCN is at risk for entrapment by the suture and therefore, the fascia should be closed without much medialization. In case of any injury in the main trunk, meralgia paresthetica, which is an undesired complication, may occur [2,18,21–24]. Consistent with the literature, in our study, a LFCN lesion was observed in 3 patients (5%). Paresthesia symptoms resolved in 2 of these patients, but not in the remaining patient which required no intervention.

In their study, Unger et al. [1] showed that 88.3% of the patients were mobilized with the assistance of a walker or crutch at 4 weeks following surgery and that 3% of the patients who were mobilized preoperatively became confined to wheelchair following surgery. In another study, Renken et al. [2] suggested that bipolar hemiarthroplasty using DAA offered more favorable mobilization than conventional approach. In the literature, there is no specific valid test to evaluate mobilization following endoprosthetic implantation in elderly. The Harris Hip Score (HHS) or Western Ontario and McMaster Universities Arthritis Index (WOMAC) were originally developed for elective total hip replacement. Our study results for mobilization are consistent with previous reports [1,2]. Although no statistically significant difference between the groups in our study, we believe that DAA offers more rapid postoperative rehabilitation and early mobilization, leading to rapid return to daily living activities compatible with the literature. In addition, shorter hospital stay about 3 days in the DAA group indicates that patients are able to be discharged in a shorter period of time.

The main technical challenge for DAA is the release and elevation of the femur for implantation. To gain a better visualization, excessive force for the elevation of the greater trochanter may result in significant iatrogenic fractures in elderly patients who are mostly at risk for osteoporosis. Thus, following the neck cut, the capsule medial to the greater trochanter is released and the inferior leg of the capsular incision is extended till the lesser

trochanter. The retractor is inserted under the greater trochanter and elevation is ensured under controlled force [1,2,18,21–24]. In our study, a missed iatrogenic fracture of the greater trochanter was observed in one of the patients in the DAA group (Figure 1) at 3-week follow-up and managed through follow-up protocol. Such complications are frequently seen using DAA in studies without completed learning curve and, therefore, DAA seems to be associated with high complication rates. However, no statistically significant difference has been reported between the anterior and posterior approach when the learning curve is completed [1,2,18–26]. In addition, the use of downsized femoral components due to difficulties in femoral exposure and associated early femoral revisions with DAA have been reported in patients with total hip arthroplasty [15–18,21].

Review of the literature reveals a higher reoperation risk in hemiarthroplasty compared to total hip arthroplasty [27]. In long-term hemiarthroplasty cases, sedentary lifestyle, limb length, and proper restoration of the femoral offset to the biomechanics of the joint are critical factors to ensure durability [27–30]. In a study, Renken et al. [2] compared minimally invasive and conventional approaches for hemiarthroplasty in patients with femoral neck fractures and found no statistically significant difference in the radiological findings between the 2 groups. In our study, no significant difference in the limb length was found, consistent with the literature.

There are some limitations in this study. First, DAA is a procedure that takes a longer time in learning curve and these surgeries were performed by a single surgeon who used PLA initially. The patient selection of DAA group was not randomized, so this cohort was the set of consecutive weak patient's series treated by a single surgeon as first cases of DAA. Second the mean follow-up of the study is 16 months, which may be relatively short for an arthroplasty series, therefore further studies are needed to elucidate the long-term outcomes of these techniques. However, performing these procedures by the same surgeon may be considered as an advantage of the study.

Conclusions

In conclusion, our study results suggest that DAA is less invasive and early clinical and biochemical outcomes are better in DAA than PLA with early return to daily living activities in elderly patients with comorbidities undergoing hemiarthroplasty for displaced femoral neck fractures. We believe that DAA seems to be increasing every day in clinical practice.

Ethical approval

The study protocol was approved by the Institutional Review Board.

Conflict of interest

None.

References:

- Unger AC, Dirksen B, Renken FG et al: Treatment of femoral neck fracture with a minimal invasive surgical approach for hemiarthroplasty – clinical and radiological results in 180 geriatric patients. *Open Orthop J*, 2014; 8: 225–31
- Renken F, Renken S, Paech A et al: Early functional results after Hemiarthroplasty for femoral neck fracture: A randomized comparison between a minimal invasive and a conventional approach. *BMC Musculoskeletal Disord*, 2012; 13(1): 141–49
- Berggren M, Stenwall M, Englund U et al: Co-morbidities, complications and causes of death among people with femoral neck fracture – a three-year follow-up study. *BMC Geriatr*, 2016; 16(1): 120–29
- Grosso MG, Danoff JR, Padgett DE et al: The cemented unipolar prosthesis for the management of displaced femoral neck fractures in the dependent osteopenic elderly. *J Arthroplasty*, 2016; 31(5): 1040–46
- Zehir S, Şahin E, Sipahioğlu S et al: [Results of anterior and posterior capsular approaches in bipolar hemiarthroplasty patients with femoral neck fractures.] *Ulus Travma Acil Cerr Derg*, 2013; 19(5): 456–62 [in Turkish]
- Sprague S, Bhandari M, Heetveld MJ et al: Factors associated with health-related quality of life, hip function, and health utility after operative management of femoral neck fractures. *Bone Joint J*, 2018; 100-B(3): 361–69
- Liodakis E, Antoniou J, Zukor DJ et al: Major complications and transfusion rates after hemiarthroplasty and total hip arthroplasty for femoral neck fractures. *J Arthroplasty*, 2016; 31(9): 2008–12
- Frisch NB, Wessell N, Charters M et al: Hip fracture mortality: Differences between intertrochanteric and femoral neck fractures. *J Surg Orthop Adv*, 2018; 27(1): 64–71
- Chiarello E, Tedesco G, Cadossi M et al: Surgical prevention of femoral neck fractures in elderly osteoporotic patients. A literature review. *Clin Cases Miner Bone Metab*, 2016; 13(1): 42–45
- Florschütz AV, Langford JR, Haidukewych GJ, Koval KJ: Femoral neck fractures: Current management. *J Orthop Trauma*, 2015; 29(3): 121–29
- Rudasill SE, Dattilo JR, Liu J, Kamath AF: Hemiarthroplasty or total hip arthroplasty: Is there a racial bias in treatment selection for femoral neck fractures? *Geriatr Orthop Surg Rehabil*, 2019; 10: 2151459319841741
- Rogmark C, Leonardsson O: Hip arthroplasty for the treatment of displaced fractures of the femoral neck in elderly patients. *Bone Joint J*, 2016; 98-B(3): 291–97
- Lewis DP, Wæver D, Thorninger R, Donnelly WJ: Hemiarthroplasty vs. total hip arthroplasty for the management of displaced neck of femur fractures: A systematic review and meta-analysis. *J Arthroplasty*, 2019; 34(8): 1837–43
- Bartels S, Gjertsen JE, Frihagen F et al: High failure rate after internal fixation and beneficial outcome after arthroplasty in treatment of displaced femoral neck fractures in patients between 55 and 70 years: An observational study of 2,713 patients reported to the Norwegian Hip Fracture Register. *Acta Orthop*, 2018; 89(1): 53–58
- Thürig G, Schmitt JW, Slankamenac K, Werner CML: Safety of total hip arthroplasty for femoral neck fractures using the direct anterior approach: A retrospective observational study in 86 elderly patients. *Patient Saf Surg*, 2016; 10: 12
- Thaler M, Lechner R, Putzer D et al: Two-year gait analysis controls of the minimally invasive total hip arthroplasty by the direct anterior approach. *Clin Biomech*, 2018; 58: 34–38
- Dorr LD, Maheshwari AV, Long WT et al: Early pain relief and function after posterior minimally invasive and conventional total hip arthroplasty. *J Bone Joint Surg Am*, 2007; 89-A(6): 1153–60
- Post ZD, Orozco F, Diaz-Ledezma C et al: Direct anterior approach for total hip arthroplasty: indications, technique, and results. *J Am Acad Orthop Surg*, 2014; 22(9): 595–603
- Grosso MJ, Danoff JR, Murtaugh TS et al: Hemiarthroplasty for displaced femoral neck fractures in the elderly has a low conversion rate. *J Arthroplasty*, 2017; 32(1): 150–54
- Enocson A, Tidermark J, Törnkvist H, Lapidus LJ: Dislocation of hemiarthroplasty after femoral neck fracture: Better outcome after the anterolateral approach in a prospective cohort study on 739 consecutive hips. *Acta Orthop*, 2008; 79(2): 211–17
- Barry JJ, Masonis JL, Mason JB: Recovery and outcomes of direct anterior approach total hip arthroplasty. *Annals of Joint*, 2018; 3(6): 1–8
- Menken LG, Berliner ZP, Mercer N, Rodriguez JA: Cemented primary total hip arthroplasty using a direct anterior approach. *Seminars in Arthroplasty*, 2018; 29(3): 147–52
- Lovell TP: Single-incision direct anterior approach for total hip arthroplasty using a standard operating table. *J Arthroplasty*, 2008; 23(7): 64–68
- Wroblewski A, Hoffman D, Miller ET: Direct anterior approach for hip hemiarthroplasty. *J Orthop Trauma*, 2019; 33: 17–18
- Bush JB, Wilson MR: Dislocation after hip hemiarthroplasty: Anterior versus posterior capsular approach. *Orthopedics*, 2007; 30(2): 138–44
- Kunkel ST, Sabatino MJ, Kang R et al: A systematic review and meta-analysis of the direct anterior approach for hemiarthroplasty for femoral neck fracture. *Eur J Orthop Surg Traumatol*, 2018; 28(2): 217–32
- Hansson S, Nemes S, Kärrholm J, Rogmark C: Reduced risk of reoperation after treatment of femoral neck fractures with total hip arthroplasty: a matched pair analysis. *Acta Orthop*, 2017; 88(5): 500–4
- Uhler LM, Schultz WR, Hill AD, Koenig KM: Health utility of early hemiarthroplasty vs. delayed total hip arthroplasty for displaced femoral neck fracture in elderly patients: A Markov model. *J Arthroplasty*, 2017; 32(5): 1434–38
- Tol MCJM, van den Bekerom MPJ, Sierevelt IN et al: Hemiarthroplasty or total hip arthroplasty for the treatment of a displaced intracapsular fracture in active elderly patients: 12-year follow-up of randomised trial. *Bone Joint J*, 2017; 99-B(2): 250–54
- Ravi B, Pincus D, Khan H et al: Comparing complications and costs of total hip arthroplasty and hemiarthroplasty for femoral neck fractures: A propensity score-matched, population-based study. *J Bone Joint Surg Am*, 2019; 101(7): 572–79