



Since January 2020 Elsevier has created a COVID-19 resource centre with free information in English and Mandarin on the novel coronavirus COVID-19. The COVID-19 resource centre is hosted on Elsevier Connect, the company's public news and information website.

Elsevier hereby grants permission to make all its COVID-19-related research that is available on the COVID-19 resource centre - including this research content - immediately available in PubMed Central and other publicly funded repositories, such as the WHO COVID database with rights for unrestricted research re-use and analyses in any form or by any means with acknowledgement of the original source. These permissions are granted for free by Elsevier for as long as the COVID-19 resource centre remains active.

Journal Pre-proof

A Surgical Perspective of Gastrointestinal Manifestations and Complications of COVID-19 Infection

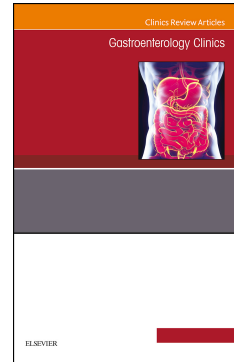
Anthony Gebran, MD, Ander Dorken Gallastegi, MD, Haytham M.A. Kaafarani, MD, MPH

PII: S0889-8553(22)00068-1

DOI: <https://doi.org/10.1016/j.gtc.2022.10.001>

Reference: GTC 1240

To appear in: *GASTROENTEROLOGY CLINICS OF NORTH AMERICA*



Please cite this article as: Gebran A, Gallastegi AD, Kaafarani HMA, A Surgical Perspective of Gastrointestinal Manifestations and Complications of COVID-19 Infection, *GASTROENTEROLOGY CLINICS OF NORTH AMERICA* (2022), doi: <https://doi.org/10.1016/j.gtc.2022.10.001>.

This is a PDF file of an article that has undergone enhancements after acceptance, such as the addition of a cover page and metadata, and formatting for readability, but it is not yet the definitive version of record. This version will undergo additional copyediting, typesetting and review before it is published in its final form, but we are providing this version to give early visibility of the article. Please note that, during the production process, errors may be discovered which could affect the content, and all legal disclaimers that apply to the journal pertain.

© 2022 Published by Elsevier Inc.

A Surgical Perspective of Gastrointestinal Manifestations and Complications of COVID-19 Infection

Anthony Gebran, MD¹; Ander Dorken Gallastegi, MD¹; Haytham M.A. Kaafarani, MD, MPH¹

¹Division of Trauma, Emergency Surgery, and Surgical Critical Care, Massachusetts General Hospital, Boston, MA.

Anthony Gebran, MD

Mailing address:

4601 Bayard Street, Apt 207

Pittsburgh, PA, 15213

E-mail: anthony.gebran@gmail.com

P: 857 233 7306

Ander Dorken Gallastegi, MD

Mailing address:

2984 Sidney St

Pittsburgh, PA, 15203

E-mail: adorkengallastegi@gmail.com

P: 617 620 6279

Corresponding Author:

Haytham Kaafarani, MD MPH FACS

Associate Professor of Surgery, Harvard Medical School

Division of Trauma, Emergency Surgery and Surgical Critical Care

Massachusetts General Hospital

165 Cambridge Street, Suite 810

Boston, MA 02114

P: 617-643-2433 F: 617-726-9121

E: hkaafarani@mgh.harvard.edu

Abstract

The coronavirus disease 2019 (COVID-19), caused by the severe acute respiratory syndrome coronavirus 2 (SARS-CoV-2), has quickly spread over the world since December 2019. COVID-19 is a systemic disease that can affect various organs throughout the body. Gastrointestinal (GI) symptoms have been reported in 16% to 33% of all COVID-19 patients and in 75% of critically ill patients. This chapter reviews the GI manifestations of COVID-19 as well as their diagnostic and treatment modalities.

Keywords

COVID-19, mesenteric ischemia, pancreatitis, cholecystitis, GI surgery

INTRODUCTION

The coronavirus disease 2019 (COVID-19), caused by the severe acute respiratory syndrome coronavirus 2 (SARS-CoV-2), has quickly spread over the world since December 2019. The most common symptoms of COVID-19 disease include fever, cough, dyspnea, fatigue, and myalgia. However, COVID-19 is a systemic disease that can affect various organs throughout the body. Gastrointestinal (GI) symptoms have been reported in 16% to 33% of all COVID-19 patients and in 75% of critically ill patients.^{1,2}

This chapter reviews the GI manifestations of COVID-19 as well as their diagnostic and treatment modalities from a surgical perspective.

GASTROINTESTINAL MANIFESTATIONS

The most common presenting GI symptoms of COVID-19 disease include nausea, vomiting, diarrhea, and abdominal pain.³ More severe GI complications ranging from ileus to life-threatening mesenteric ischemia arise in 74% to 86% of critically ill COVID-19 patients during their frequently lengthy hospitalization.^{2,4} These complications might be preceded by warning signs such as increasing abdominal distension and new or increasing vasopressor requirements.

Acute cholecystitis Acute cholecystitis refers to acute inflammation of the gallbladder, either due to obstruction of the cystic duct by a gallstone (calculous), or dysfunction of gallbladder emptying in the absence of stones (acalculous). Acute cholecystitis is one possible complication of COVID-19 infection, particularly among critically ill patients.^{2,4-8} When it occurs, acute cholecystitis is usually acalculous and the causal mechanism is unclear. Gallbladder wall hypomotility is common in critical illness; however, the identification of SARS-CoV2 RNA in

gallbladder epithelial cells and bile could indicate a more specific causal role of the virus.⁹⁻¹¹ Few case reports have detailed the occurrence of gangrenous cholecystitis leading to perforation. In one case this was possibly due to the increased risk of thrombosis and organ ischemia associated with COVID-19.^{12,13}

Antibiotics and percutaneous cholecystostomy should be attempted first in the management of acute cholecystitis among critically ill COVID-19 patients.^{14,15} Cholecystectomy should be reserved for cases where percutaneous drainage has failed.¹⁶ In a study conducted by the COVIDSurg Collaborative during the early phases of the pandemic, 145 COVID-19 patients who underwent cholecystectomy had a 30-day mortality of 10.3%, despite most not being critically ill preoperatively. Mortality risk was particularly exacerbated among patients who had preoperative respiratory signs or symptoms of COVID-19 as compared to those who did not (19.2% vs. 0.0%, $p < 0.001$).¹⁷

Acute colonic pseudo-obstruction Ogilvie's syndrome or acute colonic pseudo-obstruction refers to colonic distension in the absence of mechanical obstruction and it is most commonly caused by infection, electrolyte imbalance, and opioids. Several cases of acute colonic pseudo-obstruction have been reported among critically ill COVID-19 patients.^{2,18-22}

The exact etiology of acute colonic pseudo-obstruction in critically ill COVID-19 patients is unknown. Previously reported effects of SARS-CoV2 on the nervous system (e.g. Guillain-Barré syndrome, transverse myelitis, encephalitis) suggest that a similar impact of the virus on mesenteric nerves could be the etiology. Specifically, acute colonic pseudo-obstruction might be caused by a loss of parasympathetic regulation of bowels if SARS-CoV2 invades the myenteric plexus.

In a stable patient without evident sepsis or shock, conservative management should be attempted first. This should include bowel rest, colonic decompression with a rectal tube or by colonoscopy, electrolyte replacement, administration of intravenous fluids, treatment of an underlying infection, and discontinuation of any drugs that could worsen the paralytic ileus (e.g. opioids, sedatives). While there have been some reports of clinical improvement with the use of acetylcholinesterase inhibitors such as neostigmine, the evidence supporting its use remains weak. Surgery is reserved for cases that failed conservative management especially if there is progression to intestinal wall necrosis and perforation. Therefore, early diagnosis and appropriate management is essential for acute colonic pseudo-obstruction, while maintaining a high index of suspicion for ischemia and perforation in case of clinical deterioration.

Acute liver injury and transaminitis Acute liver injury, defined as an elevated alanine aminotransferase (ALT) and aspartate aminotransferase (AST) levels, is a common complication of COVID-19 disease and can be indicative of a severe disease course.

In two large cohort studies from the United States, elevations in ALT and AST were detected in 29-63% of patients.^{23,24} In a study of 2,273 SARS-CoV-2-positive and 1,108 SARS-CoV-2-negative hospitalized patients, SARS-CoV-2-positive patients had greater initial and peak ALT than those who had a similar clinical presentation but tested negative for SARS-CoV2.²⁵ Overall, 45% of SARS-CoV2-positive patients had mild liver injury (peak ALT <2 times the upper limit of normal [ULN]), 22% had moderate liver injury (peak ALT 2-5 times the ULN), and 6% had severe liver injury (peak ALT >5 times the ULN).

A systematic review including 9,889 confirmed cases of COVID-19 from a single country, reported an incidence of liver injury of 24.7%.²⁶ Patients with severe COVID-19 were twice as likely to suffer liver injury than those with non-severe COVID-19.

The etiology of acute liver injury in COVID-19 patients is uncertain but likely involves direct, viral-mediated damage and an indirect, immune-mediated inflammatory response.²⁷ Direct viral-induced damage could be mediated through the angiotensin-converting enzyme 2 (ACE2) receptors found in biliary and hepatic endothelial cells.²⁸⁻³⁰ Indirect immune-mediated damage results from cytokine storm with severe COVID-19, as evidenced by elevated C-reactive protein (CRP), serum ferritin, interleukin (IL)-6, and IL-2, which can lead to multisystem organ failure.^{31,32} Additional liver damage could be the result of concomitant critical illness (e.g. sepsis, shock). The degree of elevation of transaminases (notably peak ALT) was shown to be an independent predictor of mortality among COVID-19 patients.²⁵

Some studies have supported regular testing of liver transaminases in COVID-19 patients.³³ The American Association for the Study of Liver Diseases (AASLD) recommends nonetheless keeping a broad differential when dealing with elevated transaminase levels in the setting of COVID-19 and exploring other etiologies (e.g. hepatitis A, B, or C virus, myositis).³⁴

Acute pancreatitis Acute pancreatitis is a complex disease resulting from inappropriate activation of digestive enzymes leading to autodigestion of the pancreas. Acute pancreatitis is an uncommon complication of COVID-19. According to a large cohort study of 11,883 hospitalized COVID-19 patients from 12 hospitals, the incidence of acute pancreatitis was 0.27%.³⁵ In another retrospective study of more than 63,000 COVID-19 patients seen in the emergency department, the incidence of acute pancreatitis was reported at 0.07%.³⁶

It remains unclear whether acute pancreatitis that develops in the setting of COVID-19 disease is a direct result of SARS-CoV2 infection.³⁷ The presence of ACE2 receptors in pancreatic ductal, acinar, and islet cells as well as the isolation of SARS-CoV2 from a pancreatic pseudocyst point to a possible association.³⁸⁻⁴⁰ Ex-vivo and in-vivo studies as well as human autopsies have demonstrated that SARS-CoV-2 infection can target β -cells of the human pancreas and lead to metabolic dysregulation.^{41,42} Similar studies are needed to ascertain the association between COVID-19 and pancreatitis.

COVID-19-related acute pancreatitis is treated similarly to non-COVID-19-related acute pancreatitis. Supportive therapy with fluid resuscitation, pain control, and nutritional support are the mainstay of treatment in uncomplicated cases. Percutaneous, endoscopic, or surgical debridement may be required if necrotizing pancreatitis supervenes.⁴³

Ileus and feeding intolerance Ileus refers to obstipation and feeding intolerance resulting from disruption of normal bowel peristalsis in the absence of mechanical obstruction. Significant ileus and feeding intolerance have been reported in 46-56% of critically ill COVID-19 patients admitted to an intensive care unit (ICU).²

Critically ill COVID-19 patients frequently require substantial doses of sedatives and opiates for ventilator synchrony, which can independently result in decreased intestinal function. It remains unclear whether SARS-CoV2 infection plays a direct role in causing this pathology.

Management of COVID-19-related ileus is no different from the management of ileus unassociated with COVID-19 infection. Supportive care is the mainstay of treatment and includes electrolyte replacement as necessary, maintenance of fluids, bowel rest, and intestinal decompression as needed.

Mesenteric ischemia Mesenteric ischemia can affect the small and/or large intestine and is caused either by a reduction in intestinal blood flow from systemic hypotension or thromboembolic occlusion of the mesenteric vessels.⁴⁴ Its incidence was reported to be 3.8% to 4% in cohort studies of critically ill COVID-19 patients admitted to one institution.^{1,2}

Although the coagulopathy caused by COVID-19 is not fully understood, several studies show an association between SARS-CoV2 infection and mesenteric ischemia. Following matching based on baseline characteristics and clinical condition, critically ill patients with COVID-19 were significantly more likely to develop mesenteric ischemia than similarly ill patients without COVID-19.⁴⁵

The diagnosis of mesenteric ischemia is typically confirmed by imaging. Contrast-enhanced Computed Tomography (CT) scan of the abdomen plays an important role in the detection of this disease and should be considered early on in the management of critically ill patients who exhibit GI symptoms.⁴⁶ Ischemic bowel should be suspected if pneumatosis intestinalis, thick edematous intestine, and/or portal venous gas are present.⁴⁷ When using intravenous contrast, arterial phase imaging may reveal filling defects in the thoracoabdominal aorta or mesenteric arteries, which could indicate acute thromboembolic events.⁴⁸⁻⁵² Alternatively, delayed venous phase imaging may reveal filling defects in the mesenteric and/or portal veins.^{46,48,51} Finally, a considerable number of patients develop mesenteric ischemia despite having patent and well-perfusing mesenteric vessels on imaging.^{1,2,53} Such findings suggest a microvascular etiology of mesenteric ischemia in a significant number of patients. **Figure 1** shows the CT scan findings of a patient with COVID-19 who developed mesenteric ischemia and small bowel perforation.

Laboratory findings can include increasing lactate, elevated D-dimers, leukocytosis, and unexplained metabolic acidosis; however, such laboratory tests might be normal early on before metabolic alterations occur. Those findings are also non-specific and could be present in other conditions, such as severe viral sepsis in the absence of mesenteric ischemia.⁵⁴

Surgical resection of any necrotic bowel is the mainstay treatment of mesenteric ischemia in the setting of COVID-19 disease. When there is evidence of proximal arterial thromboembolic disease, endovascular thrombectomy can be used to reopen blocked mesenteric arteries and restore blood flow to the intestines.^{48,55} Anticoagulants may play a role in treating mesenteric ischemia; however, there is no compelling evidence to support their use prophylactically. The only available data comes from case reports describing a reversal of bowel ischemia in hemodynamically stable patients who were treated conservatively with anticoagulation.^{56,57}

On intraoperative gross examination of the bowel, many surgeons identified necrotic tissue, punctuate lesions, and/or frank perforation. Surgeons also reported peculiar findings of well-demarcated yellow discoloration with spotty or circumferential distribution on the antimesenteric side.⁵³ Pathological specimens may demonstrate sharp demarcation between areas of mucosal necrosis and viable mucosa, transmural infarction, and fibrin thrombi in small vessels underlying areas of necrosis.⁵⁸

PATHOPHYSIOLOGY

The exact pathophysiology of COVID-related GI complications is unknown. The high rate of GI complications in COVID-19 patients makes it more likely that they are not just a manifestation of critical illness but are at least in part caused by COVID-19. A propensity score-matched analysis of 184 critically ill patients with acute respiratory distress syndrome (ARDS),

showed that more patients with COVID-19 ARDS developed mesenteric ischemia (4% vs. 0%), elevated liver enzymes (55% vs. 27%), and ileus (48% vs. 22%).⁶¹ In addition, certain GI complications might manifest differently in COVID-19 versus non-COVID-19 patients. While mesenteric ischemia in critical illness affects watershed areas, patients with COVID-19 often present with patchy areas of necrosis throughout the entire small bowel (**Figure 2**).^{1,2,53} As a result, illness severity alone is unlikely to explain the increased rates of GI complications, and other COVID disease-specific mechanisms may occur.

Identification of SARS-CoV2 in the GI tract SARS-CoV2 RNA or proteins have been isolated from several parts of the GI tract in patients known to have COVID-19 disease.

Several studies have reported elevated viral loads in fecal samples of patients with COVID-19 disease. In a systematic review and meta-analysis of 1,636 COVID-19 patients, 43% of patients had evidence of fecal SARS-CoV-2 RNA. Patients with GI symptoms had a higher proportion of detectable fecal SARS-CoV-2 RNA as compared to those without GI symptoms (52.4% vs. 25.9%; OR=2.4). The difference was most notable for patients who developed diarrhea (51.6% vs. 24.0%; OR=3.0) versus those without diarrhea. Fecal shedding also persisted longer than respiratory shedding (mean duration: 21.8 days vs. 14.7 days; mean difference=7.1 days).⁶²

High SARS-CoV2 viral loads have been documented by RT-PCR inside a pancreatic pseudocyst's fluid in the setting of COVID-19 disease.⁴⁰

Viral proteins have been identified in the cytoplasm of gallbladder epithelial cells in several patients,^{9,10} and in the bile of one patient with COVID-19 disease.¹¹

ACE2 receptor interaction Intestinal epithelium contains the second highest expression of ACE2 receptors in the body after the lungs.⁴⁹ Specifically, the ileum is the most commonly

involved region of ischemia in COVID-related bowel disease and has a very high level of ACE2 expression.^{1,2,48,53,63} Other sites of ACE2 expression include the epithelial cells of the gallbladder, and ductal, acinar, and islet cells of the pancreas.^{38,39} The virus could attach to the ACE2 receptors in the GI tract, translocate to the submucosal tissue, and damage the underlying tissue and vasculature resulting in various pathologies.⁶⁴

Microvascular thrombosis Thromboembolic events are a well-documented complication of SARS-CoV2 infection.⁶⁵ Presentation can include cerebrovascular accidents, strokes, deep vein thrombosis, renal failure, and mesenteric ischemia. In the latter, SARS-CoV2 has a higher propensity towards microvasculature and often spares large mesenteric arteries. Microscopic analysis of resected intestinal tissue revealed fibrin microthrombi in capillaries beneath necrotic zones.⁶⁶

SUMMARY

- While COVID-19 is primarily characterized as a respiratory infection, it has serious extrapulmonary manifestations including serious GI complications.
- Diarrhea, nausea, vomiting, and abdominal pain are the most common GI manifestations seen in patients with COVID-19, accounting for up to one-third of early symptoms.
- Critically ill COVID-19 patients can experience a wide range of GI complications ranging from ileus to life-threatening mesenteric ischemia.
- The etiology of GI manifestations in COVID-19 is multifactorial. The propensity of the virus for ACE2 receptors and their high expression in the GI tract, viral isolation in GI tissues, and microvascular coagulopathy support a role of SARS-CoV2 in the reported GI complications.

REFERENCE

1. El Moheb M, Christensen MA, Naar L, et al. Comment on “Gastrointestinal Complications in Critically Ill Patients With COVID-19” An Update. *Annals of Surgery*. Published online 2020. doi:10.1097/SLA.0000000000004337
2. Kaafarani HMA, el Moheb M, Hwabejire JO, et al. Gastrointestinal Complications in Critically Ill Patients With COVID-19. *Ann Surg*. 2020;272(2):e61-e62. doi:10.1097/SLA.0000000000004004
3. Tabesh E, Soheilipour M, Sami R, et al. Gastrointestinal manifestations in patients with coronavirus disease-2019 (COVID-19): Impact on clinical outcomes. *Journal of Research in Medical Sciences*. 2022;27(1):32. doi:10.4103/jrms.jrms_641_21
4. Sun JK, Liu Y, Zou L, et al. Acute gastrointestinal injury in critically ill patients with COVID-19 in Wuhan, China. *World Journal of Gastroenterology*. 2020;26(39):6087-6097. doi:10.3748/wjg.v26.i39.6087
5. Hossein Hassani A, Beheshti A, Almasi F, Ketabi Moghaddam P, Azizi M. *Unusual Gastrointestinal Manifestations of COVID-19: Two Case Reports*.
6. Alhassan SM, Iqbal P, Fikrey L, et al. Post COVID 19 acute acalculous cholecystitis raising the possibility of underlying dysregulated immune response, a case report. *Annals of Medicine and Surgery*. 2020;60:434-437. doi:10.1016/j.amsu.2020.11.031
7. Puig G, Giménez-Milà M, Campistol E, Caño V, Valcarcel J, Colomina MJ. Development of concomitant diseases in COVID-19 critically ill patients. *Revista Espanola de Anestesiologia y Reanimacion*. 2021;68(1):37-40. doi:10.1016/j.redar.2020.09.001
8. Scutari R, Piermatteo L, Manuelli MC, et al. Long-term sars-cov-2 infection associated with viral dissemination in different body fluids including bile in two patients with acute cholecystitis. *Life*. 2020;10(11):1-9. doi:10.3390/life10110302
9. Hong X, He J, Li P, et al. Evidence of SARS-CoV-2 infection in gallbladder and aggravating cholecystitis to septic shock: a case report. *Annals of Translational Medicine*. 2021;9(21):1631-1631. doi:10.21037/atm-21-4778
10. Balaphas A, Gkoufa K, Meyer J, et al. COVID-19 can mimic acute cholecystitis and is associated with the presence of viral RNA in the gallbladder wall. *Journal of Hepatology*. 2020;73(6):1566-1568. doi:10.1016/j.jhep.2020.08.020
11. Liao Yusheng, Wang Bangmao, Wang Jian, Shu Juan, Zhou Weilai, Zhang Heng. SARS-CoV-2 in the bile of a patient with COVID-19-associated gallbladder disease. *Endoscopy*. 2020;12(1148):52. doi:10.1093/cid/ciaa461
12. Bruni A, Garofalo E, Zuccalà V, et al. Histopathological findings in a COVID-19 patient affected by ischemic gangrenous cholecystitis. *World Journal of Emergency Surgery*. 2020;15(1). doi:10.1186/s13017-020-00320-5

13. Alam W, Karam K. Gangrenous Cholecystitis as a Potential Complication of COVID-19: A Case Report. *Clinical Medicine Insights: Case Reports*. 2021;14. doi:10.1177/11795476211042459
14. Ying M, Lu B, Pan J, et al. COVID-19 with acute cholecystitis: A case report. *BMC Infectious Diseases*. 2020;20(1). doi:10.1186/s12879-020-05164-7
15. Çiyiltepe H, Yıldırım G, Fersahoğlu MM, et al. Clinical approach to patients admitted to the emergency room due to acute cholecystitis during the COVID-19 pandemic and percutaneous cholecystostomy experience. *Ulusal Travma ve Acil Cerrahi Dergisi*. 2021;27(1):34-42. doi:10.14744/tjtes.2020.80083
16. Mattone E, Sofia M, Schembari E, et al. Acute acalculous cholecystitis on a COVID-19 patient: a case report. *Annals of Medicine and Surgery*. 2020;58:73-75. doi:10.1016/j.amsu.2020.08.027
17. Gebran A, Gaitanidis A, Argandykov D, et al. Mortality & Pulmonary Complications in Emergency General Surgery Patients with Mortality COVID-19: A Large International Multicenter Study. Published online 2022. doi:10.1097/TA.0000000000003577
18. Sattar Y, Connerney M, Rauf H, et al. Three Cases of COVID-19 Disease with Colonic Manifestations. *American Journal of Gastroenterology*. 2020;115(6):948-950. doi:10.14309/ajg.0000000000000692
19. Ibrahim YS, Karuppasamy G, Parambil J v., Alsoub H, Al-Shokri SD. Case report: Paralytic ileus: A potential extrapulmonary manifestation of severe COVID-19. *American Journal of Tropical Medicine and Hygiene*. 2020;103(4):1600-1603. doi:10.4269/ajtmh.20-0894
20. Chong Collins, Airini Ibrahim Noor, Abdul Maei Ngazraini. Ogilvie's Syndrome - A Complication of Severe COVID-19 Infection. *Mal J Med Health Sci*. 2022;18(1):375-377.
21. Zhang H, Li HB, Lyu JR, et al. Specific ACE2 expression in small intestinal enterocytes may cause gastrointestinal symptoms and injury after 2019-nCoV infection. *International Journal of Infectious Diseases*. 2020;96:19-24. doi:10.1016/j.ijid.2020.04.027
22. Wang J, Marusca G, Tariq T, Mohamad B. Ogilvie Syndrome and COVID-19 Infection. *Journal of Medical Cases*. 2021;12(8):328-331. doi:10.14740/jmc3728
23. Richardson S, Hirsch JS, Narasimhan M, et al. Presenting Characteristics, Comorbidities, and Outcomes among 5700 Patients Hospitalized with COVID-19 in the New York City Area. *JAMA - Journal of the American Medical Association*. 2020;323(20):2052-2059. doi:10.1001/JAMA.2020.6775
24. Goyal P, Choi JJ, Pinheiro LC, et al. Clinical Characteristics of Covid-19 in New York City. *New England Journal of Medicine*. 2020;382(24):2372-2374. doi:10.1056/nejmc2010419

25. Phipps MM, Barraza LH, Lasota ED, et al. Acute Liver Injury in COVID-19: Prevalence and Association with Clinical Outcomes in a Large U.S. Cohort. 2020;72(3). doi:10.1002/hep.31404/supinfo
26. Zhao X, Lei Z, Gao F, Xie Q, Jang K, Gong J. The impact of coronavirus disease 2019 (COVID-19) on liver injury in China A systematic review and meta-analysis. *Medicine (United States)*. 2021;100(4). doi:10.1097/MD.00000000000024369
27. Sun J, Aghemo A, Forner A, Valenti L. COVID-19 and liver disease. *Liver International*. 2020;40(6):1278-1281. doi:10.1111/liv.14470
28. Wang D, Hu B, Hu C, et al. Clinical Characteristics of 138 Hospitalized Patients With 2019 Novel Coronavirus-Infected Pneumonia in Wuhan, China JAMA | Original Investigation | CARING FOR THE CRITICALLY ILL PATIENT. *JAMA*. 2020;323(11):1061-1069. doi:10.1001/jama.2020.1585
29. Chai X, Hu L, Zhang Y, et al. Specific ACE2 Expression in Cholangiocytes May Cause Liver Damage After 2019-nCoV Infection. doi:10.1101/2020.02.03.931766
30. Hu S. Comment on “Organ-protective effect of angiotensin-converting enzyme 2 and its effect on the prognosis of COVID-19.” *Journal of Medical Virology*. 2020;92(9):1425-1426. doi:10.1002/jmv.25937
31. Mehta P, McAuley DF, Brown M, Sanchez E, Tattersall RS, Manson JJ. COVID-19: consider cytokine storm syndromes and immunosuppression. *The Lancet*. 2020;395(10229):1033-1034. doi:10.1016/S0140-6736(20)30628-0
32. Liu J, Li S, Liu J, et al. Longitudinal characteristics of lymphocyte responses and cytokine profiles in the peripheral blood of SARS-CoV-2 infected patients. *EBioMedicine*. 2020;55. doi:10.1016/j.ebiom.2020.102763
33. Yu D, Du Q, Yan S, et al. Liver injury in COVID-19: clinical features and treatment management. *Virology Journal*. 2021;18(1). doi:10.1186/s12985-021-01593-1
34. Fix OK, Hameed B, Fontana RJ, et al. Clinical Best Practice Advice for Hepatology and Liver Transplant Providers During the COVID-19 Pandemic: AASLD Expert Panel Consensus Statement. *Hepatology*. 2020;72(1):287-304. doi:10.1002/hep.31281
35. Inamdar S, Benias PC, Liu Y, Sejpal D v., Satapathy SK, Trindade AJ. Prevalence, Risk Factors, and Outcomes of Hospitalized Patients With Coronavirus Disease 2019 Presenting as Acute Pancreatitis. *Gastroenterology*. 2020;159(6):2226-2228.e2. doi:10.1053/j.gastro.2020.08.044
36. Miró Ò, Llorens P, Jiménez S, et al. Frequency of five unusual presentations in patients with COVID-19: Results of the UMC-19-S1. *Epidemiology and Infection*. Published online 2020. doi:10.1017/S0950268820001910

37. de-Madaria E, Capurso G. COVID-19 and acute pancreatitis: examining the causality. *Nature Reviews Gastroenterology and Hepatology*. 2021;18(1):3-4. doi:10.1038/s41575-020-00389-y
38. Liu F, Long X, Zhang B, Zhang W, Chen X, Zhang Z. ACE2 Expression in Pancreas May Cause Pancreatic Damage After SARS-CoV-2 Infection. *Clinical Gastroenterology and Hepatology*. 2020;18(9):2128-2130.e2. doi:10.1016/j.cgh.2020.04.040
39. Hikmet F, Méar L, Edvinsson Å, Micke P, Uhlén M, Lindskog C. The protein expression profile of ACE2 in human tissues. *Molecular Systems Biology*. 2020;16(7). doi:10.15252/msb.20209610
40. Schepis T, Larghi A, Papa A, et al. SARS-CoV2 RNA detection in a pancreatic pseudocyst sample. *Pancreatology*. 2020;20(5):1011-1012. doi:10.1016/j.pan.2020.05.016
41. Müller JA, Groß R, Conzelmann C, et al. SARS-CoV-2 infects and replicates in cells of the human endocrine and exocrine pancreas. *Nature Metabolism*. 2021;3(2):149-165. doi:10.1038/s42255-021-00347-1
42. Steenblock C, Richter S, Berger I, et al. Viral infiltration of pancreatic islets in patients with COVID-19. *Nature Communications*. 2021;12(1). doi:10.1038/s41467-021-23886-3
43. Kumaran NK, Karmakar BK, Taylor OM. Coronavirus disease-19 (COVID-19) associated with acute necrotising pancreatitis (ANP). *BMJ Case Reports*. 2020;13(9). doi:10.1136/bcr-2020-237903
44. Cerqueira NF, Hussni CA, Yoshida WB. Pathophysiology of mesenteric ischemia/reperfusion: a review. *Acta Cir Bras*. 2005;20(4):336-343.
45. el Moheb M, Naar L, Christensen MA, et al. Gastrointestinal Complications in Critically Ill Patients with and without COVID-19. *JAMA - Journal of the American Medical Association*. 2020;324(18):1899-1901. doi:10.1001/jama.2020.19400
46. Keshavarz P, Rafiee F, Kavandi H, Goudarzi S, Heidari F, Gholamrezanezhad A. Ischemic gastrointestinal complications of COVID-19: a systematic review on imaging presentation. *Clinical Imaging*. 2021;73:86-95. doi:10.1016/j.clinimag.2020.11.054
47. Bhayana R, Som A, Li MD, et al. Abdominal imaging findings in COVID-19: Preliminary observations. *Radiology*. 2020;297(1):E207-E215. doi:10.1148/radiol.2020201908
48. de Barry O, Mekki A, Diffre C, Seror M, el Hajjam M, Carlier RY. Arterial and venous abdominal thrombosis in a 79-year-old woman with COVID-19 pneumonia. *Radiology Case Reports*. 2020;15(7):1054-1057. doi:10.1016/j.radcr.2020.04.055
49. Rodriguez-Nakamura RM, Gonzalez-Calatayud M, Martinez Martinez AR. Acute mesenteric thrombosis in two patients with COVID-19. Two cases report and literature review. *International Journal of Surgery Case Reports*. 2020;76:409-414. doi:10.1016/j.ijscr.2020.10.040

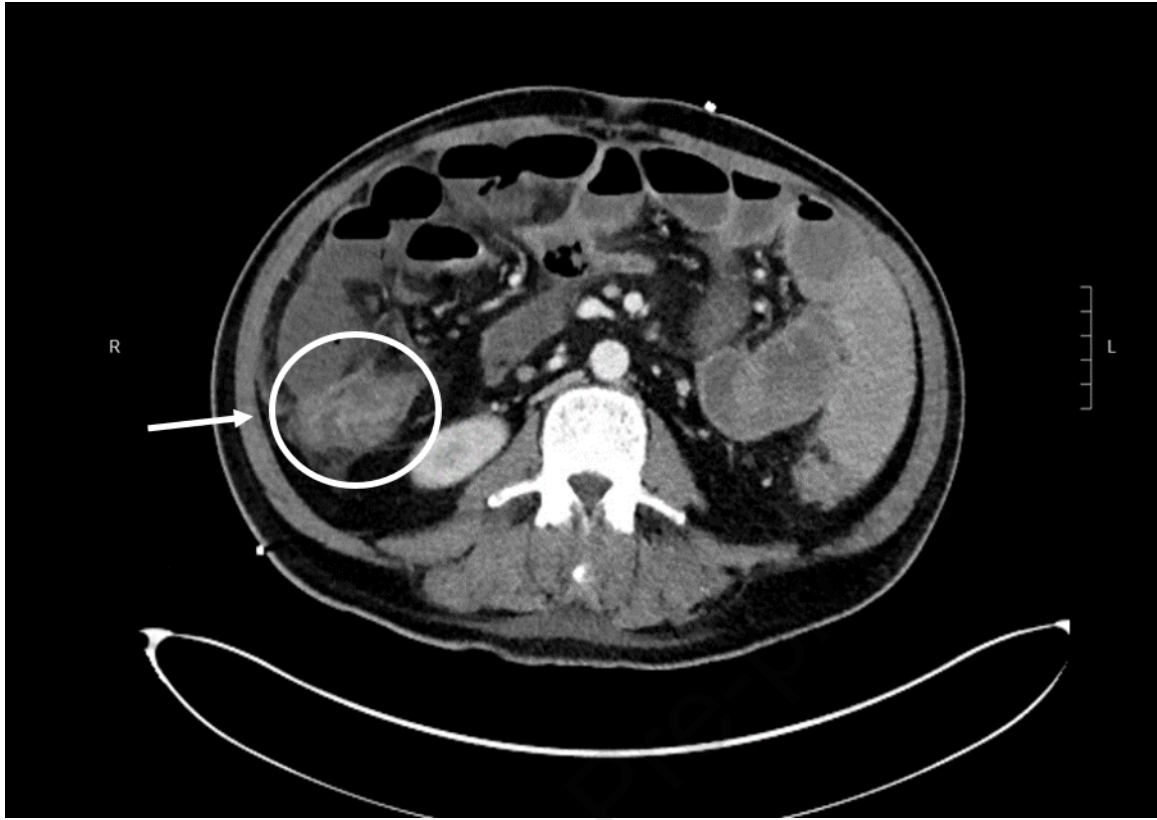
50. A Beccara L, Pacioni C, Ponton S, Francavilla S, Cuzzoli A. Arterial Mesenteric Thrombosis as a Complication of SARS-CoV-2 Infection. *Eur J Case Rep Intern Med.* 2020;7(5):001690. doi:10.12890/2020_001690
51. Norsa L, Valle C, Morotti D, Bonaffini PA, Indriolo A, Sonzogni A. Intestinal ischemia in the COVID-19 era. *Digestive and Liver Disease.* 2020;52(10):1090-1091. doi:10.1016/j.dld.2020.05.030
52. Osilli D, Pavlovica J, Mane R, Ibrahim M, Bouhelal A, Jacob S. Case reports: mild COVID-19 infection and acute arterial thrombosis. *Journal of Surgical Case Reports.* 2020;2020(9). doi:10.1093/jscr/rjaa343
53. Gartland RM, Velmahos GC. Bowel Necrosis in the Setting of COVID-19. *Journal of Gastrointestinal Surgery.* 2020;24(12):2888-2889. doi:10.1007/s11605-020-04632-4
54. Klok FA, Kruip MJHA, van der Meer NJM, et al. Incidence of thrombotic complications in critically ill ICU patients with COVID-19. *Thrombosis Research.* 2020;191:145-147. doi:10.1016/j.thromres.2020.04.013
55. Azouz E, Yang S, Monnier-Cholley L, Arrivé L. Systemic arterial thrombosis and acute mesenteric ischemia in a patient with COVID-19. *Intensive Care Medicine.* 2020;46(7):1464-1465. doi:10.1007/s00134-020-06079-2
56. Thuluva SK, Zhu H, Tan MML, et al. A 29-year-old male construction worker from india who presented with left-sided abdominal pain due to isolated superior mesenteric vein thrombosis associated with SARS-CoV-2 infection. *American Journal of Case Reports.* 2020;21:1-5. doi:10.12659/AJCR.926785
57. Lakshmanan S, Toubia N. Pneumatosis Intestinalis in COVID-19. *Clinical Gastroenterology and Hepatology.* Published online May 2020. doi:10.1016/j.cgh.2020.05.048
58. Hwabejire JO, A Kaafarani HM, Mashbari H, et al. Bowel Ischemia in COVID-19 Infection: One-Year Surgical Experience. *The American Surgeon.* 2021;87(12):1893-1900. doi:10.1177/00031348211038571
59. Clark R, Waters B, Stanfill AG. *Elevated Liver Function Tests in COVID-19: Causes, Clinical Evidence, and Potential Treatments.*; 2021. www.tnpj.com
60. Naar L, Langeveld K, el Moheb M, et al. Acute Kidney Injury in Critically-ill Patients With COVID-19: A Single-center Experience of 206 Consecutive Patients. *Ann Surg.* 2020;272(4):e280-e281. doi:10.1097/SLA.0000000000004319
61. el Moheb M, Naar L, Christensen MA, et al. Gastrointestinal Complications in Critically Ill Patients With and Without COVID-19. *JAMA.* 2020;324(18):1899-1901. doi:10.1001/jama.2020.19400
62. Zhang Y, Cen M, Hu M, et al. Prevalence and Persistent Shedding of Fecal SARS-CoV-2 RNA in Patients with COVID-19 Infection: A Systematic Review and Meta-analysis.

- Clinical and Translational Gastroenterology*. 2021;12(4):E00343.
doi:10.14309/ctg.0000000000000343
63. Almafrefji I, Ranganath S. Bowel Ischemia in a Patient With SARS CoV-2-Like Illness and Negative Real-Time Reverse Transcription Polymerase Chain Reaction Test Results During the Peak of the Pandemic. *Cureus*. Published online September 14, 2020.
doi:10.7759/cureus.10442
 64. Chai X, Hu L, Zhang Y, et al. Specific ACE2 expression in cholangiocytes may cause liver damage after 2019-nCoV infection. *bioRxiv*. Published online February 4, 2020.
doi:10.1101/2020.02.03.931766
 65. Llitjos JF, Leclerc M, Chochois C, et al. High incidence of venous thromboembolic events in anticoagulated severe COVID-19 patients. *Journal of Thrombosis and Haemostasis*. 2020;18(7):1743-1746. doi:10.1111/jth.14869
 66. Cheung KS, Hung IFN, Chan PPY, et al. Gastrointestinal Manifestations of SARS-CoV-2 Infection and Virus Load in Fecal Samples From a Hong Kong Cohort: Systematic Review and Meta-analysis. *Gastroenterology*. 2020;159(1):81-95.
doi:10.1053/j.gastro.2020.03.065

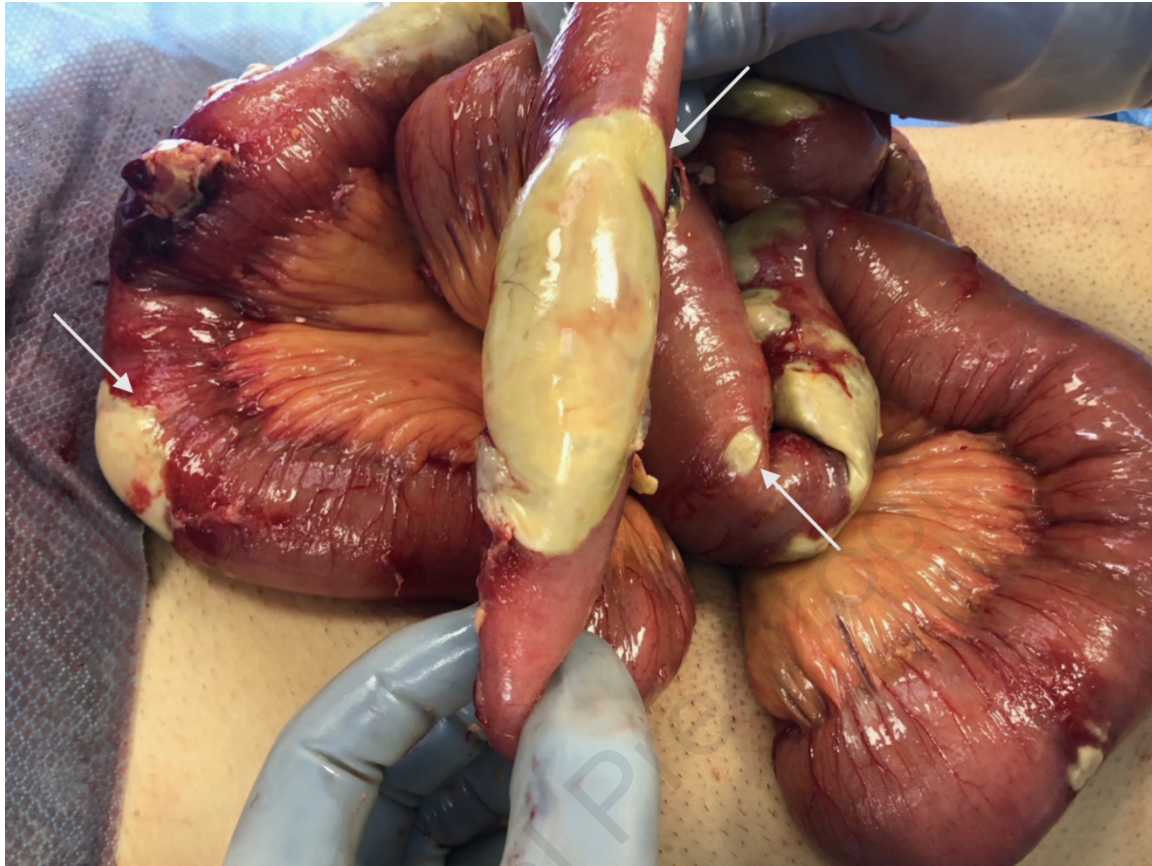FIGURE LEGENDS

Figure 1. Abdominal CT scan in a patient diagnosed with COVID-19 infection demonstrating small intestinal ischemia with perforation and loss of integrity of the small bowel wall in the right lower quadrant contiguous with a fluid and gas-containing collection.

Figure 2. Patchy antimesenteric bowel necrosis with bright yellow discoloration and clear demarcation in a patient diagnosed with COVID-19 infection. *From Kaafarani HMA, el Moheb M, Hwabejire JO, et al. Gastrointestinal Complications in Critically Ill Patients With COVID-19. Ann Surg. 2020;272(2):e61-e62. doi:10.1097/SLA.0000000000004004; with permission*



Journal Pre-proof



Journal Pre-proof