



Arthroscopy-Assisted All-Suture Coracoclavicular and Acromioclavicular Joint Stabilization in Acute Acromioclavicular Joint Injuries

Amit Joshi, M.S. (Ortho.), Bibek Basukala, M.S. (Ortho.), Nagmani Singh, M.S. (Ortho.), Sanjeeb Rijal, M.S. (Ortho.), Dhan Bahadur Karki, M.S. (Ortho.), Rohit Bista, M.S. (Ortho.), and Ishor Pradhan, M.S. (Ortho.)

Abstract: The existing literature agrees on surgical management for Rockwood grade IV and V injuries, but there is no consensus which type of surgery is the most appropriate one. More than 150 surgeries have been described for this condition in the literature. In an injury of less than 3 weeks, most surgeons prefer suture-button devices for coracoclavicular stabilization. Recent biomechanical studies have demonstrated that coracoclavicular stabilization provides good vertical stability but poor horizontal stability of acromioclavicular joint. Hence, they recommend acromioclavicular stabilization along with coracoclavicular stabilization. The use of a suture-button device for coracoclavicular stabilization requires special implants and instruments along with high surgical skills to drill precisely placed holes in the clavicle and the coracoid in order to avoid fractures from the drill hole. Due to relatively smaller clavicle and coracoid in Asian population, making holes in the clavicle and the coracoid has increased risk of fracture. We describe a technique in which no drill holes are made in the clavicle or the coracoid. In our technique, suture tape is used, which is looped around the coracoid and the clavicle, and the limbs are tied over the clavicle to maintain the coracoclavicular distance. The remaining limbs of suture tape is further looped through the tunnels made in acromion and tied over the acromion to augment the acromioclavicular ligament. The potential advantages of this technique are no costly implant and instruments are required, avoidance of complications associated with drill holes in coracoid and clavicle, both coracoclavicular and acromioclavicular joints are stabilized, direct repair of the acromioclavicular ligament can be performed, and no need of second surgery for implant removal.

Acromioclavicular (AC) joint injuries are common injuries around the shoulder, and the incidence of these injuries has increased recently.¹ Over the last decade, several surgical techniques have been described for the management of the AC joint dislocations.²⁻⁴ The

existing surgical treatment options can be divided into 2 groups: indirect repair techniques and coracoclavicular (CC) ligament reconstruction with free tendon graft.⁵ Healing of CC and AC ligament in indirect repair technique is achieved by maintaining the clavicle–coracoid relationship in a reduced position for long enough to allow healing of the these ligaments.⁵ These techniques are said to be useful only in acute cases with duration of injury of less than 3 weeks.⁶

Among the various methods described for indirect repair of acute AC joint separations, suspensory CC fixation techniques (suture-button devices) are popular ones.⁷ However, these techniques are fraught with greater complication rates.⁷ Most of these complications are associated with the drill holes made in clavicle and coracoid. Recently, AC fixation along with CC fixation is shown to be horizontally more stable.⁸ Hence, there is increased trend of both AC and CC fixation in management AC dislocations. Seo et al.⁴ described a technique of AC fixation after CC fixation with suspensory technique where a dog button was used for CC fixation,

From the AKB Center for Arthroscopy, Sports Injuries and Regenerative Medicine, B&B Hospital, Gwarko, Lalitpur (A.J., B.B., N.S., R.B., I.P.); KIST Medical College and Teaching Hospital, Lalitpur (A.J.); Chitwan Medical College and Teaching Hospital, Bharatpur (S.R.); and Karnali Academy of Health Sciences, Jumla (D.B.K.), Nepal.

The authors report that they have no conflicts of interest in the authorship and publication of this article. Full ICMJE author disclosure forms are available for this article online, as [supplementary material](#).

Received December 11, 2020; accepted January 29, 2021.

Address correspondence to Prof. Amit Joshi, M.S. (Ortho.), AKB Center for Arthroscopy, Sports Injuries and Regenerative Medicine, B&B Hospital, Lalitpur, Nepal. E-mail: dramitjoshi7@gmail.com

© 2021 THE AUTHORS. Published by Elsevier Inc. on behalf of the Arthroscopy Association of North America. This is an open access article under the CC BY-NC-ND license (<http://creativecommons.org/licenses/by-nc-nd/4.0/>).

2212-6287/202002

<https://doi.org/10.1016/j.eats.2021.01.029>

Table 1. Key Surgical Steps of This Technique With Main Goals Achieved in Each Step

Steps	Name of Steps	Goals
Step 1	Arthroscopic exposure of coracoid	Inferior, lateral, superior, and medial border of coracoid is exposed through transinterval approach.
Step 2	Looping suture tape around base of coracoid.	Suture tape is shuttled from clavicular incision to the coracoid to loop around the base of coracoid.
Step 3	Temporary fixation of the AC joint	AC joint is reduced under vision and provisional fixation is done with 2-mm K wire across AC joint.
Step 4	Knot-tying over the clavicle	Two limbs of suture tape are tied over the clavicle for CC fixation.
Step 5	Looping suture tape through the acromion tunnels	Two holes 1 cm apart are drilled from superior to inferior surface of acromion under arthroscopic guidance. Sutures are then delivered to acromial incision and shuttled through these holes.
Step 6	Knot-tying over the acromion	Knots are tied over the acromion and soft-tissue repair is done around the AC joint.

AC, acromioclavicular; CC, coracoclavicular.

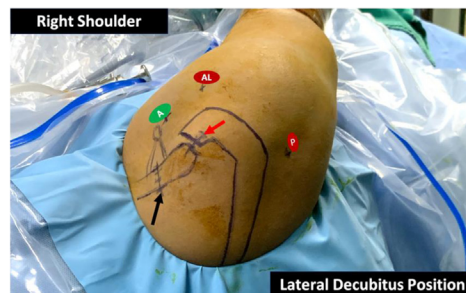


Fig 1. Right shoulder of a patient in the lateral decubitus position viewed from the top. Portals and skin incisions marked preoperatively: posterior portal (P), anterolateral portal (AL), anterior portal (A), clavicular incision (black arrow), and acromioclavicular incision (red arrow).

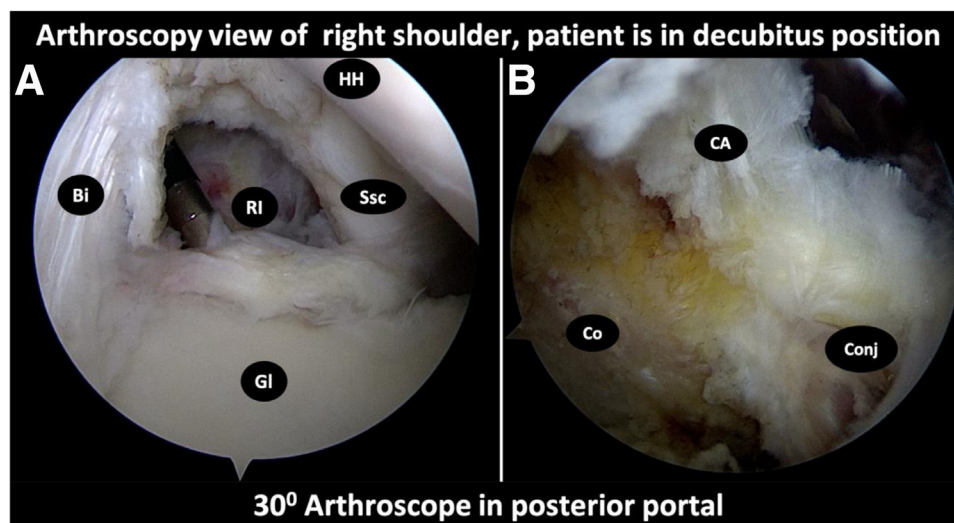


Fig 2. Exposure of the coracoid through the transinterval portal. A 30° arthroscope is in the posterior portal and the patient is in the lateral decubitus position. (A) Arthroscopy view of rotator interval showing biceps (Bi), subscapularis (Ssc), glenoid (Gl), humeral head (HH), and rotator interval (RI) after capsule removal. (B) Transinterval view of coracoid with structures attached to it. (CA, coracoacromial ligament attached to lateral border of coracoid; Co, coracoid inferior surface; Conj, conjoint tendon attached to the tip of the coracoid.)

Fig 3. Clearing the coracoid through various portals. (A) Outside picture of right shoulder superior view showing purple cannula in anterolateral portal (red arrow), radiofrequency (RF) wand introduced from anterior portal (green arrow), and arthroscope introduced from posterior portal (white arrow). (B) Right shoulder transinterval view of coracoid showing tip of coracoid (Co), conjoint tendon (Conj), tip of RF wand (RF), and 7.5-mm arthroscopy cannula (C).

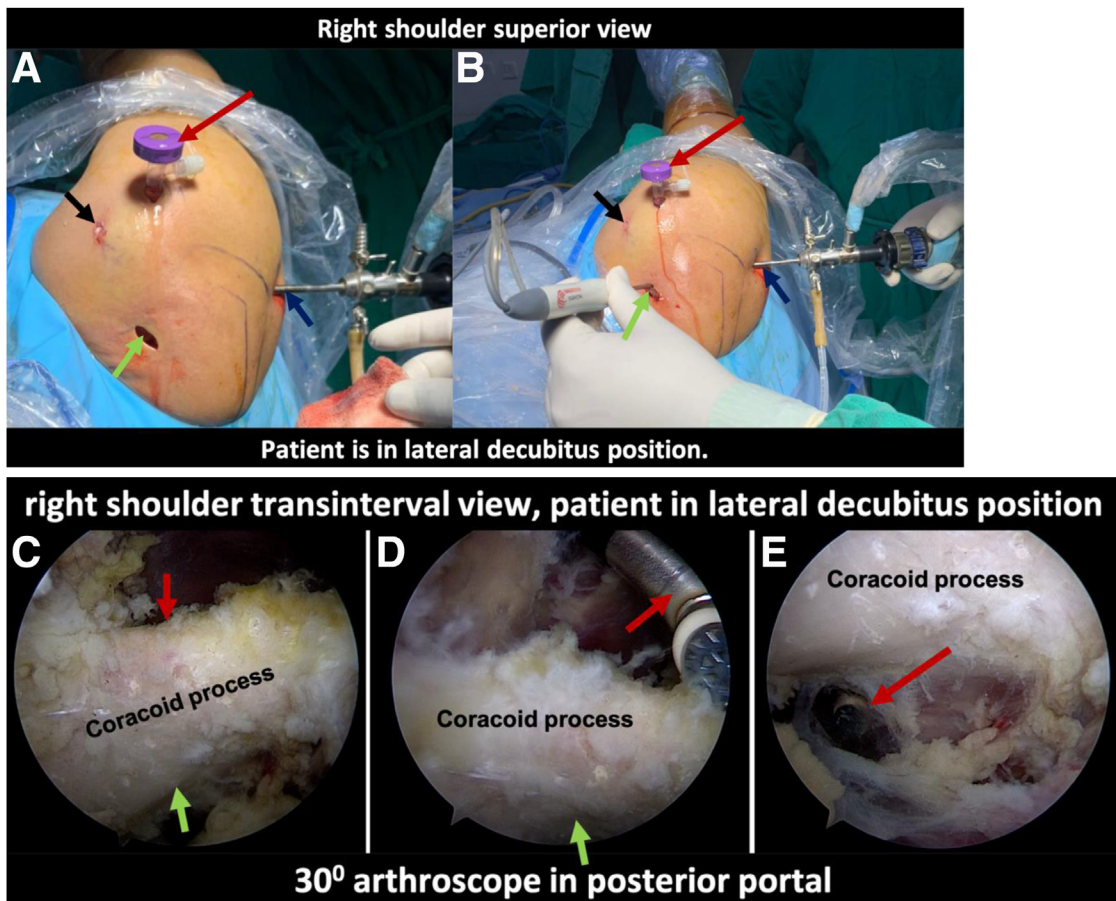
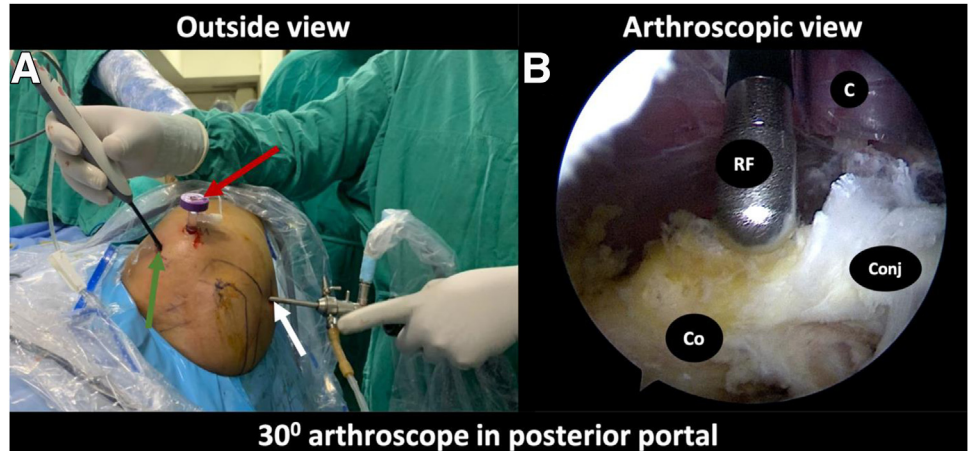


Fig 4. Exposure of coracoid. (A) outside picture of the right shoulder with the patient in the lateral decubitus position, viewed from the top, depicting a 1.5-cm incision (green arrow) over the clavicle (located 3 cm medial to the acromioclavicular joint). (B) Outside picture showing a radiofrequency (RF) wand introduced through the clavicular incision (green arrow) with the arthroscope in posterior portal (blue arrow), cannula in anterolateral portal (red arrow), and black arrow indicating the location of anterior portal. (C) Right shoulder transinterval arthroscopy view of the coracoid. Red arrow: superior border, and green arrow: inferior surface of coracoid. (D) Transinterval view of coracoid depicting undersurface of coracoid (green arrow) and tip of the RF wand (red arrow) clearing tissue from superior surface and medial border of coracoid. (E) Transinterval view of coracoid revealing window around the inferolateral border of the coracoid. The wand has traversed through the pectoralis minor and the tip has come through the window (red arrow).

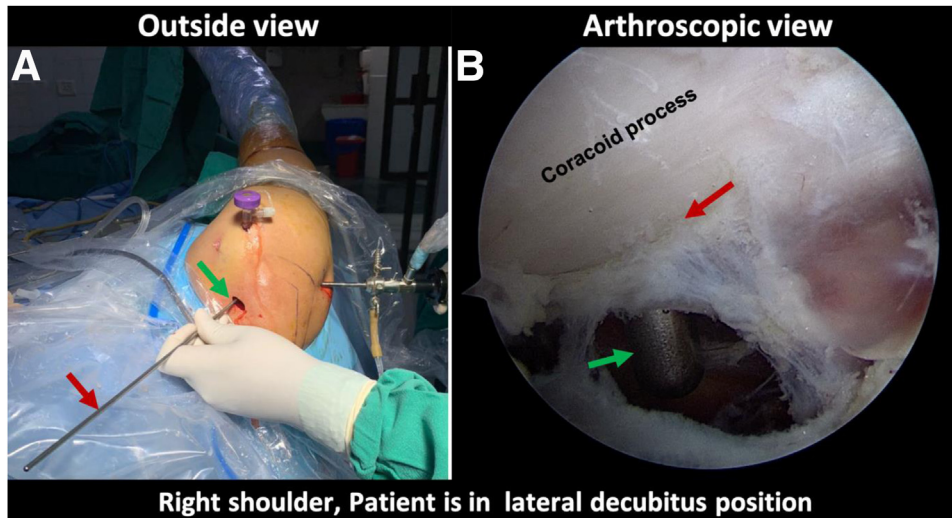


Fig 5. Process of suture shuttling under the coracoid. The patient is in the lateral decubitus position and a 30° arthroscope is in the posterior portal. (A) Outside picture, superior view of the right shoulder. A 4-mm Wissinger rod (red arrow) is introduced through the clavicular incision (green arrow) and directed toward the coracoid. (B) Transinterval view of coracoid showing inferomedial border of coracoid (red arrow) and Wissinger rod (green arrow) is visible in the window made in the pectoralis minor.

and knotless anchors were used for AC fixation. El Shewy and El Azizi⁹ in their study looped the suture tape around the coracoid and made drill hole only in clavicle for CC fixation to reduce the complication of coracoid fracture. Both the aforementioned techniques have mentioned the drilling of hole in clavicle to achieve secure fixation.

Considering the fact that Asian population has a smaller coracoid and clavicle width, there is an increased chance of fracture of either of these if a hole is drilled for any surgery.¹⁰ Hence, we modified the CC fixation technique by looping the suture tape around coracoid first then around the clavicle. In this Technical Note, we describe our preferred method of CC and AC fixation with suture tapes only. The suture tape is looped around the coracoid base and clavicle for CC

fixation, and a limb of the tape is passed through small tunnels made in the acromion for AC fixation (Video 1). A summary of key steps is provided in Table 1.

Operative Technique (With Video Illustration)

The patient is placed in the lateral decubitus position with arm on lateral traction and draped in a manner to provide sufficient access to the lateral 5 cm of clavicle. The C-arm is kept on the contralateral side for its possible use during the surgery, specifically to confirm reduction of AC joint. Anatomic landmarks are identified and marked on the skin (Fig 1).

Through the posterior portal (soft spot 1.5 cm below and medial to the posterolateral corner of acromion), a

Fig 6. Process of suture shuttling under the coracoid. The patient is in the lateral decubitus position with 30° arthroscope in posterior portal of right shoulder. (A) External, superior view of right shoulder showing a dilator (red arrow) being introduced over the Wissinger rod (green arrow). (B) Arthroscopic transinterval view of right shoulder with a 30° arthroscope in posterior portal showing a dilator (red arrow) being introduced over the Wissinger rod (green arrow).

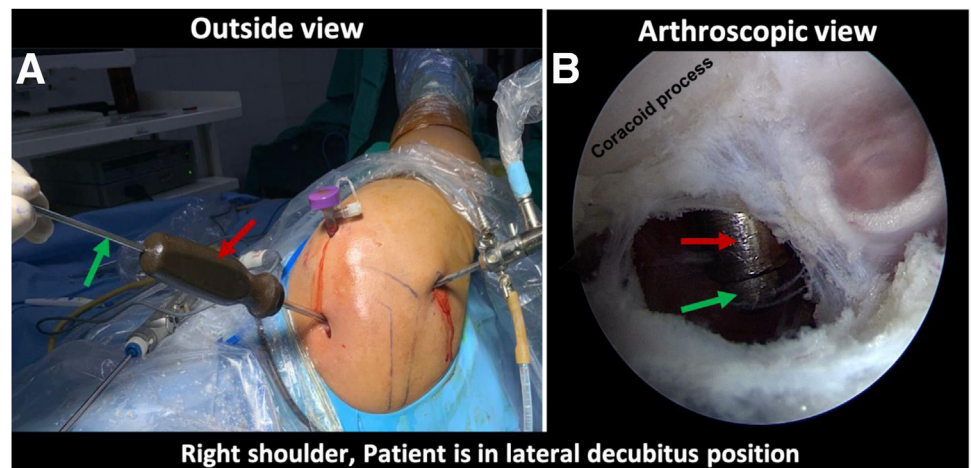


Fig 7. The process of shuttling the suture tape. (A) Outside view of the right shoulder with the patient in lateral decubitus position. Loop of PROLENE (green arrow) is inserted through the lumen of the dilator (red arrow). (B) Transinterval arthroscopic view of right shoulder with a 30° arthroscope in posterior portal. The tip of the dilator (red arrow) is visualized through the window and the PROLENE loop (red arrow) exits through the lumen of the dilator. (C) A suture manipulator (green arrow) is holding the loop of PROLENE (red arrow). (D) External, superior view of right shoulder with the patient in lateral decubitus position showing PROLENE (yellow arrow) being passed through the clavicular incision and exiting (red arrow) through the cannula placed in anterolateral portal.

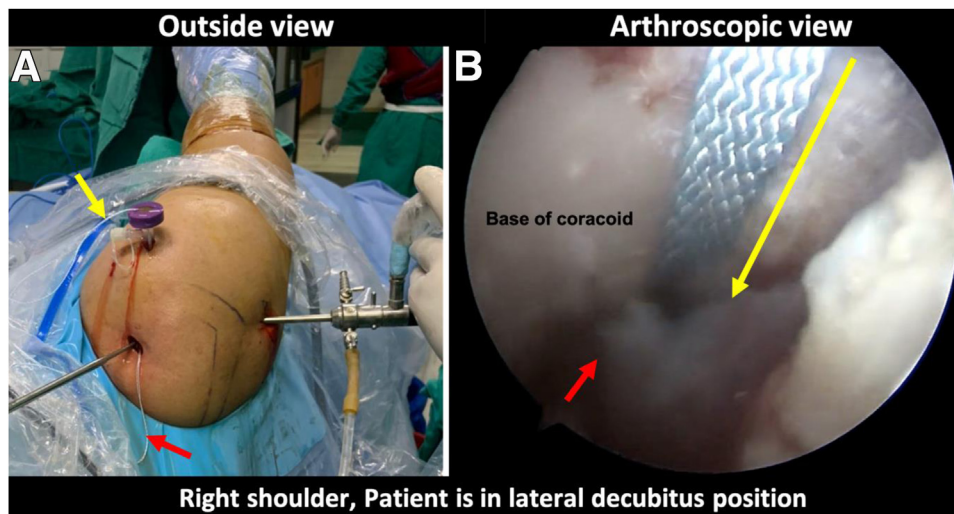
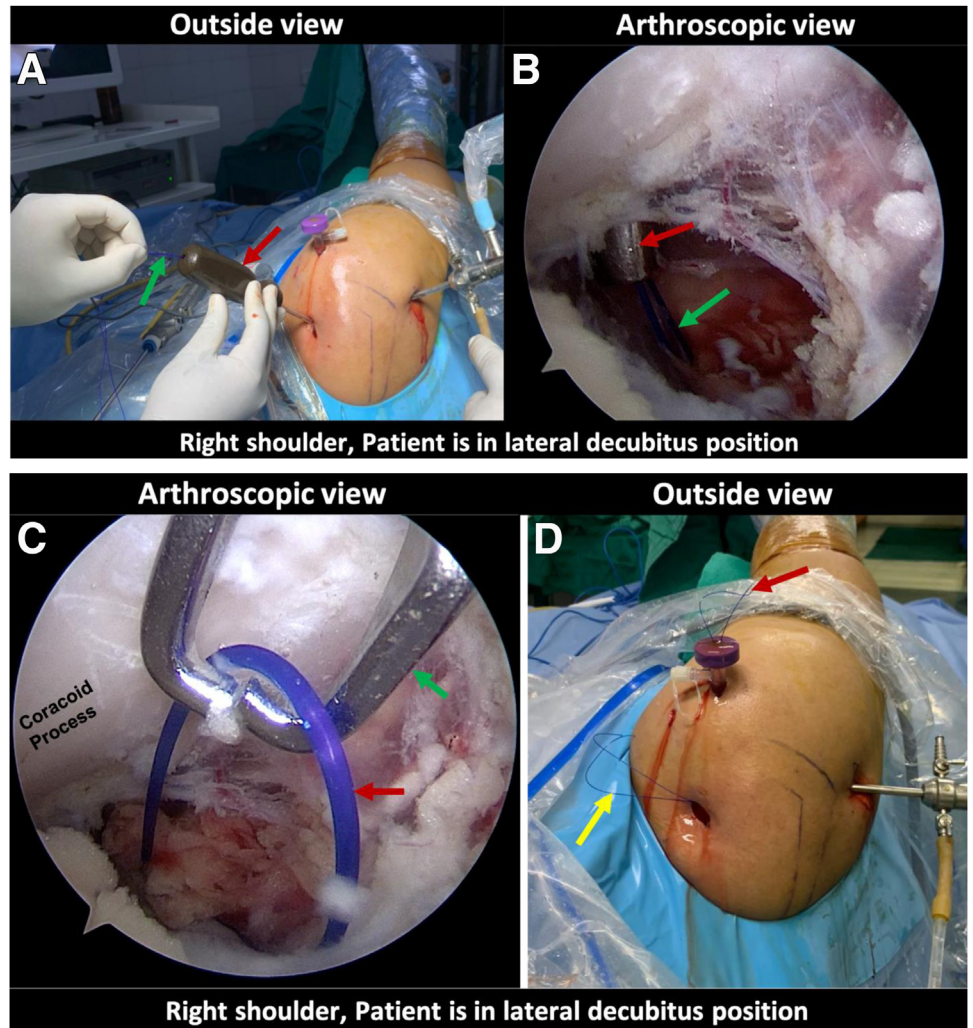


Fig 8. Right shoulder with the patient in the lateral decubitus position. (A) Outside view showing one end of the suture tape in anterolateral portal cannula (yellow arrow) and the other limb (red arrow) exiting through the clavicular incision. (B) Transinterval arthroscopic view of coracoid depicting the inferolateral border (red arrow), and the suture tape exiting through the anterolateral cannula and passing to the window of pectoralis minor. The direction of suture passage is shown by the yellow arrow (the tail of the arrow points towards the cannula and head of the arrow points toward the window).

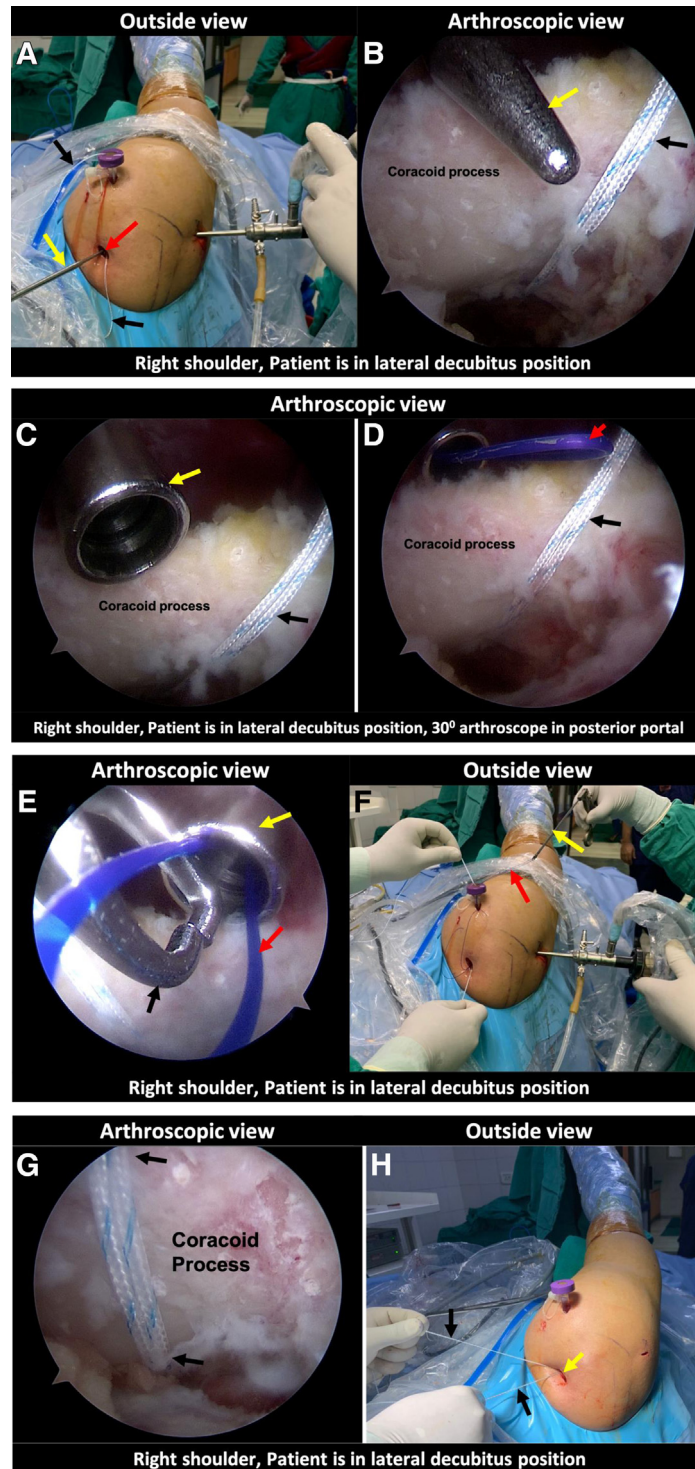
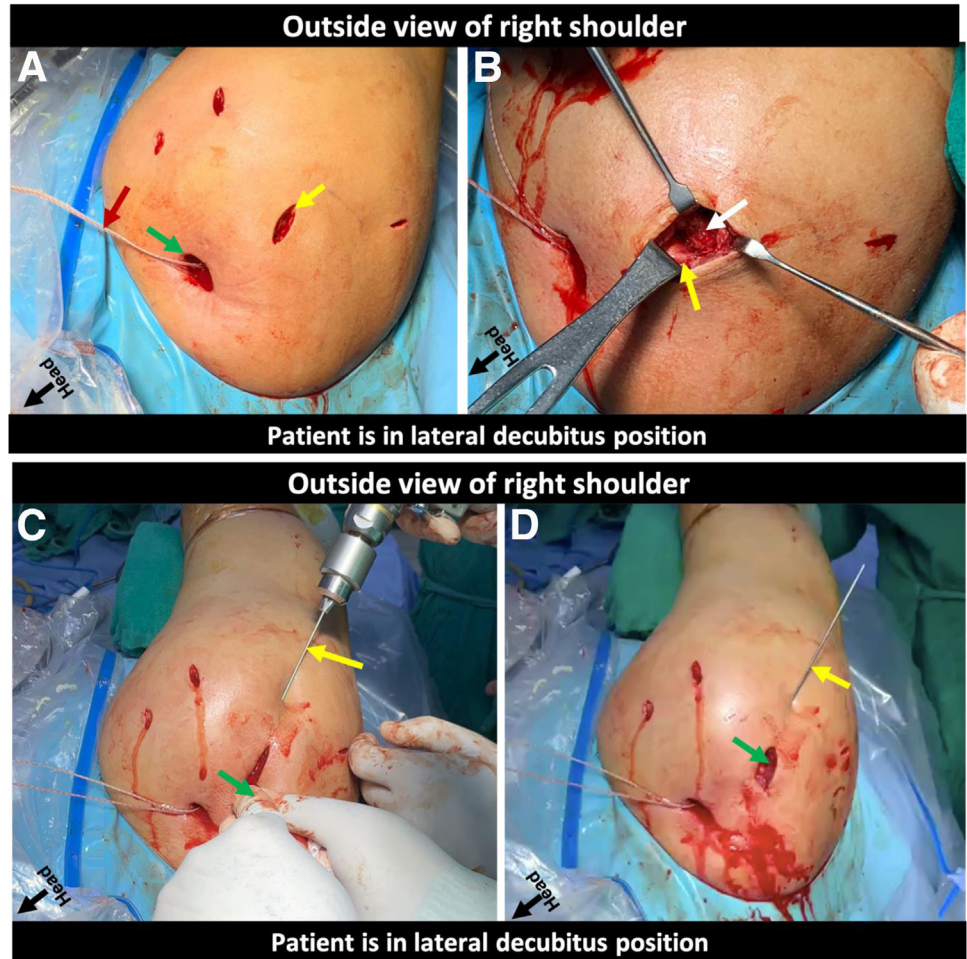


Fig 9. The process of shuttling the second limb of suture tape. (A) Outside view of the right shoulder with the patient in the lateral decubitus position. The Wissinger rod (yellow arrow) is inserted through the clavicular incision (red arrow), aiming toward the lateral border of coracoid; Black arrows showing limbs of previously shuttled suture tape. (B) Transinterval arthroscopic view of coracoid showing the previously shuttled suture tape (black arrow), and the tip of a 4-mm blunt Wissinger rod (yellow arrow) abutting superolateral border of coracoid. (C) Arthroscopic transinterval view of coracoid from posterior portal, using a 30° arthroscope, showing the tip of the dilator (yellow arrow) and suture tape (black arrow). (D) PROLENE loop (red arrow) exiting through the lumen of the dilator. (E) Arthroscopic view depicting the dilator (yellow arrow) through which the PROLENE loop (red arrow) has been passed, and suture manipulator (black arrow) is inserted through the anterolateral cannula to retrieve the loop. (F) The loop of PROLENE (red arrow) is delivered outside using suture manipulator (yellow arrow). This loop is used to shuttle the limb of suture tape to the clavicular incision forming a loop around the coracoid process. (G) Transinterval arthroscopic view of coracoid showing the suture tape looped around the coracoid (black arrow). (H) External view of right shoulder with patient in lateral decubitus position depicting both the limbs of suture tape (black arrows) retrieved out through the clavicular incision (yellow arrow).

Fig 10. Process depicting the provisional fixation of the AC joint of the right shoulder with the patient in the lateral decubitus position. (A) Both limbs of the suture tape (red arrow) exit through the clavicular incision (green arrow) with a 2-cm transverse incision over the AC Joint (yellow arrow). (B) Exposure of the lateral end of clavicle (yellow arrow) and medial 1 cm of acromion (white arrow). (C) Reduction of the AC joint by pushing the clavicle down with a blunt periosteal elevator (green arrow) and humerus up. A 1.5-mm K-wire (yellow arrow) is introduced from the lateral border of acromion to clavicle. (D) The reduced AC joint (green arrow) transfixed with 1.5 mm K-wire (yellow arrow). (AC, acromioclavicular.)



thorough diagnostic arthroscopy is performed, and an anterior portal is created by outside-in technique to complete the arthroscopy and probe intra-articular structures. The rest of the procedure is performed in 6 steps, as shown in the Table 1. The detailed procedure is described in stepwise manner for ease of understanding.

Step 1: Arthroscopic Exposure of Coracoid

With the 30° arthroscope placed in posterior portal and the radiofrequency (RF) ablator through the anterior portal, the rotator interval is opened (Fig 2A). Preparation of the coracoid base is performed via a transinterval approach, which is through the opening in the rotator interval (Fig 2B). Exposure of the coracoid is performed slowly and meticulously using a RF ablator with caution during the entire process. The tip of wand can be used to palpate the bony part of the coracoid and soft tissue is ablated adjacent to the bone only. Once the undersurface of coracoid is identified, with swiping movement of RF ablator, soft tissue from

undersurface of the coracoid is removed toward the base. To reach to the base of coracoid, a lateral portal (1.5 cm distal to anterolateral edge of acromion) is created by outside in technique and secured with a 7.5-mm cannula for suture shuttling later (Fig 3 A and B). The coracoacromial ligament is released and superior aspect of the coracoid is exposed (Fig 4C). This is followed by making a 1.5- to 2-cm long incision, 3 cm medial to the AC joint centering over the clavicle in an anterior to posterior direction (Fig 4A). The RF ablator is then introduced through the clavicular incision toward the coracoid (Fig 4B). The superior surface of the coracoid is cleared to reach to the medial border. While clearing the superior surface and moving towards the medial border of the coracoid, the ablation has to be performed carefully under arthroscopic vision which is aided by palpation of the coracoid with the tip of the RF. With the tip of the wand directed toward the lateral border, a window in the pectoralis minor is created using the RF in a superoinferior direction until the tip of the wand is

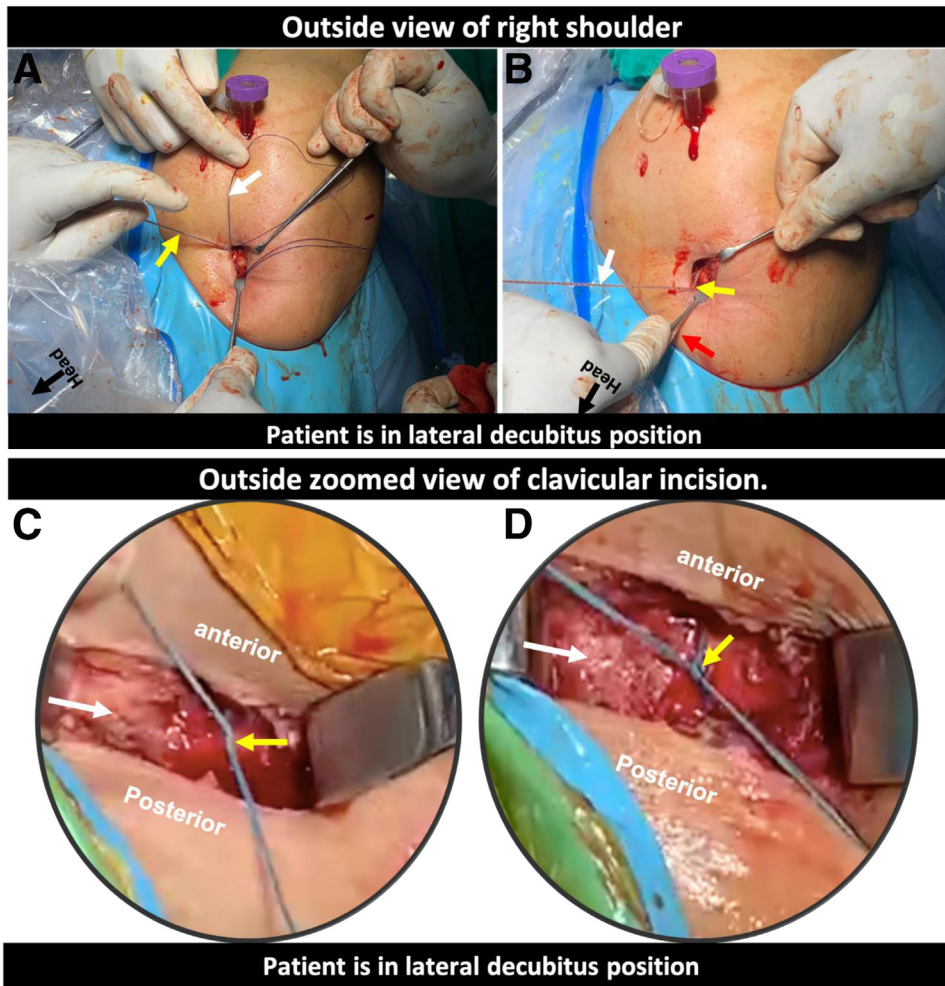


Fig 11. External view of the right shoulder with the patient in the lateral decubitus position depicting the process of knot-tying over the clavicle. (A) A PROLENE loop is passed from posterior to anterior (white arrow) and is used to shuttle the medial limb of suture tape (yellow arrow). (B) Both the limbs (white and red arrow) are tied (yellow arrow) over the clavicle. (C) Magnified view of the clavicular incision showing knots (yellow arrow) being tied over the clavicle (white arrow). (D) Final knots construct (yellow arrow) after being tied over the clavicle (white arrow).

visible on the inferomedial surface of the coracoid through the window (Fig 3 D and E).

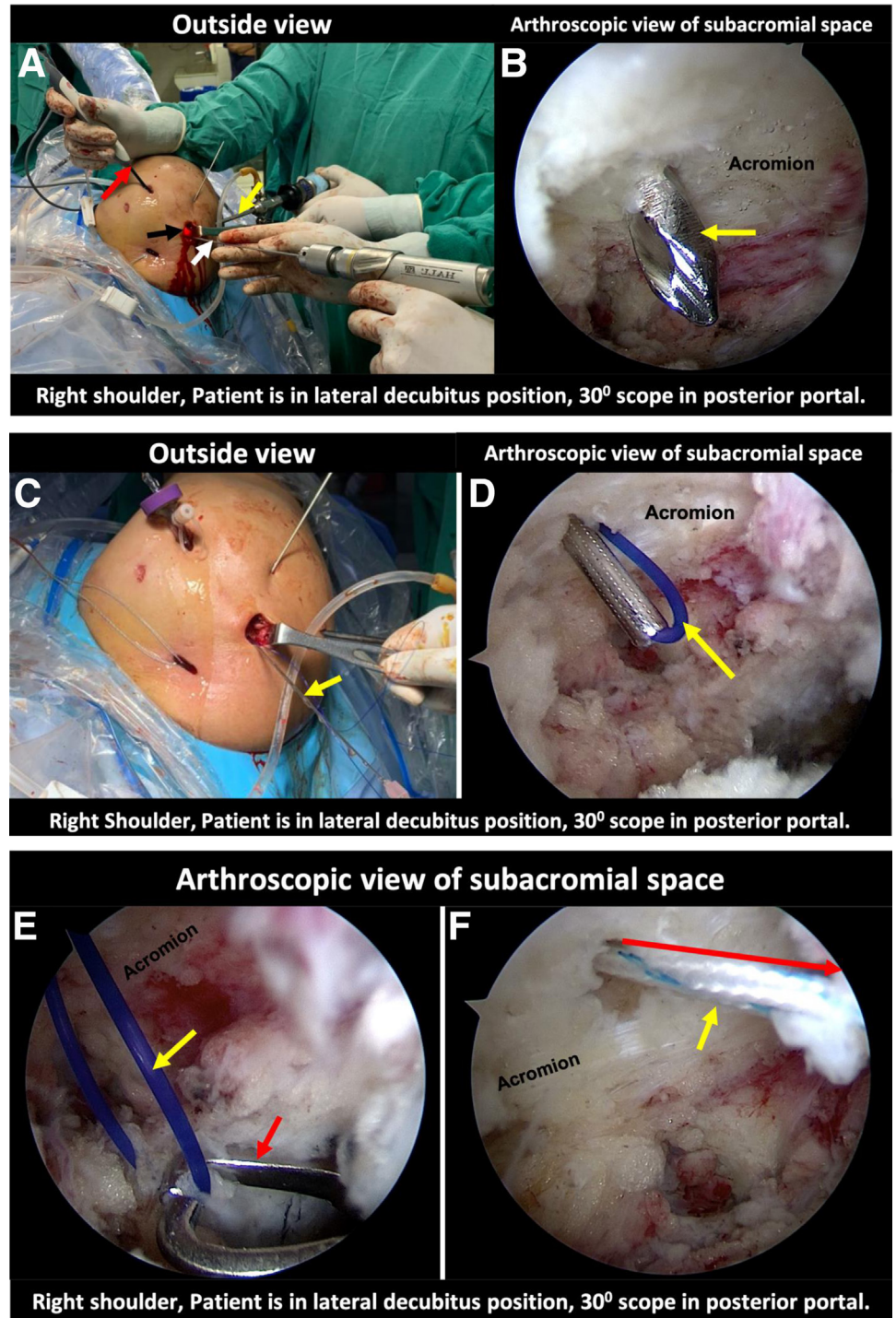
Step 2: Looping Suture Tape Around Base of the Coracoid

Once the coracoid is exposed and a superior-to-inferior window is made through the pectoralis minor around the medial border of coracoid, a 4-mm blunt pointed Wissinger rod is introduced from anterior to the clavicle through clavicular incision and is directed toward the coracoid (Fig 5A). The Wissinger rod is then progressed to the inferomedial border of the coracoid through the pectoralis minor window (Fig 5B). Keeping the Wissinger rod steady, a 4-mm dilator is introduced over the Wissinger rod (Fig 6 A and B). The Wissinger rod is then removed, keeping the dilator in situ. A loop of a No. 1 PROLENE (J&J Medical devices, Ethicon, Somerville, NJ) is inserted through the lumen of the dilator (Fig 7A) and is visualized through the window on inferomedial part of the coracoid (Fig 7B). A suture manipulator is introduced from the cannula in anterolateral portal

(Fig 7C) and the PROLENE loop is retrieved outside through the cannula (Fig 7D). The loop is used to shuttle one limb of a suture tape (Biotek; Chetan Meditek Pvt Ltd., Gujarat, India), which passes through the anterolateral cannula to the under surface of the coracoid and then along the medial border of coracoid it enters the window in the pectoralis minor and comes out anterior to the clavicle through the clavicular incision (Fig 8 A and B).

The entire process is repeated to retrieve the other limb of suture tape from anterolateral cannula to clavicular incision. The Wissinger rod is introduced from the same clavicular incision anterior to the clavicle (Fig 9A). The tip of the Wissinger rod is brought to lateral border of coracoid (Fig 9B). A 5-mm dilator is introduced over Wissinger rod and the rod is removed, keeping the dilator on lateral border of coracoid (Fig 9C). A loop of No. 1 PROLENE is inserted through the lumen of the dilator to deliver the loop lateral to the coracoid (Fig 9D). A suture manipulator is then inserted from the anterolateral cannula and the loop of PROLENE is retrieved out (Fig 9 E and F). Using the loop of

Fig 12. Process of shuttling the suture tape from the acromion to the anterolateral cannula. (A) A 30° arthroscope is introduced into the subacromial space through the posterior portal (yellow arrow). A radiofrequency ablator is inserted through anterolateral portal to the subacromial space (red arrow). Through a point on the acromion, which is 1 cm lateral to the acromioclavicular joint along the posterior border of clavicle (black arrow), a drill hole is made from superior surface of acromion to inferior using a beath pin (white arrow). (B) Arthroscopic view of the subacromial space showing the tip of the beath pin (yellow arrow) being passed into the subacromial space. (C) Outside view of the right shoulder showing beath pin being replaced by IP needle with a PROLENE loop (yellow arrow). (D) Arthroscopic view of subacromial space depicting the IP needle and a loop of PROLENE (yellow arrow). (E) A suture manipulator (red arrow) is then introduced from anterolateral cannula to retrieve the loop outside. (F) Figure depicting the suture tape being pulled from acromial incision to the anterolateral cannula (yellow arrow), and a red arrow showing the direction of the suture tape being pulled out.



PROLENE, the other limb of suture tape is shuttled out of the clavicular incision from the anterolateral cannula, looping it around the base of the coracoid (Fig 9 G and H).

Step 3: Temporary Fixation of the AC Joint

A 2-cm incision across the AC joint is made to expose the acromion and lateral end of the clavicle (Fig 10 A

and B). At this stage, a meticulous inspection of the AC joint is performed. The AC ligament (superior and posterior) is identified and preserved. If the AC joint disc is torn and extruded from the joint, it is excised. AC joint is reduced under vision by pushing the arm up in a cephalad direction maintaining the elbow flexed at 90°, and pushing the clavicle down with a blunt instrument. An image intensifier can be used at this stage to confirm

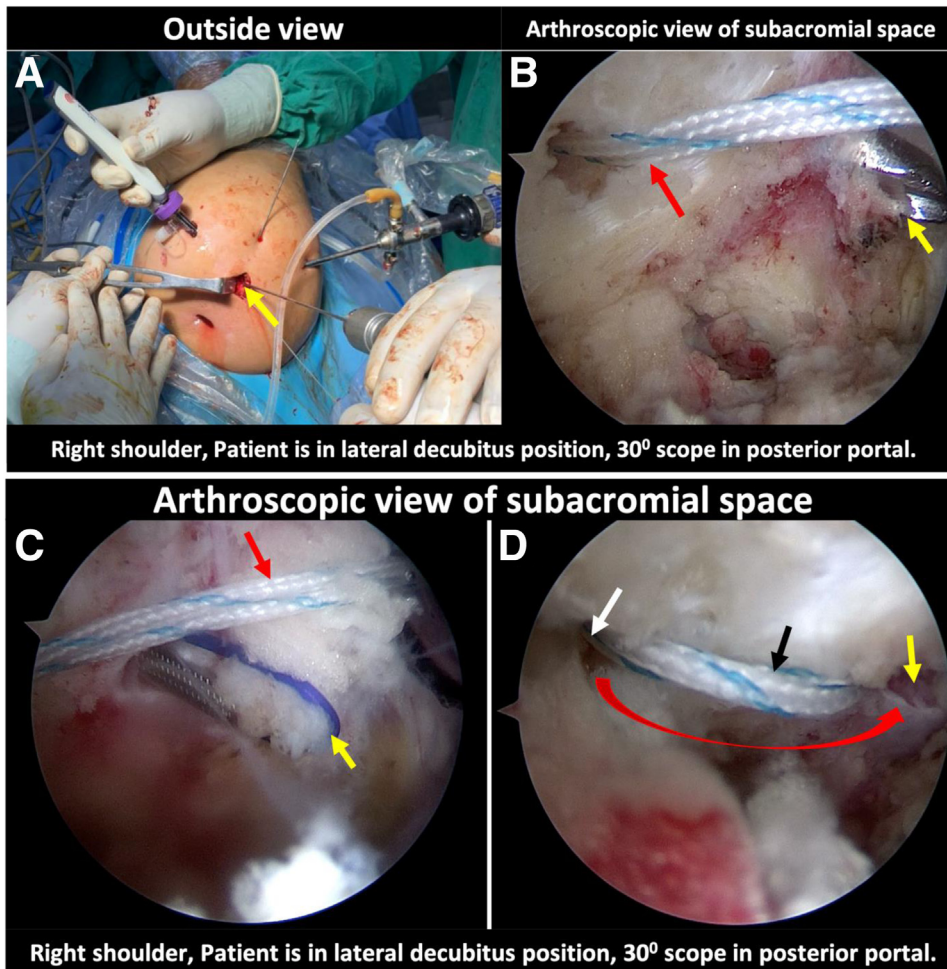


Fig 13. Process of retrieving suture tape from the anterolateral cannula to the acromion. (A) Outside view of the right shoulder showing an anterior drill hole being made using the Beath pin (yellow arrow). The anterior drill hole is placed 1 cm lateral to the acromioclavicular joint along the anterior border of the clavicle. (B) Arthroscopy view of the subacromial space showing the posterior drill hole through which the suture tape (red arrow) is exiting to the cannula and the tip of the beath pin is anterior to it (yellow arrow). (C) Arthroscopy view of the subacromial space showing previously passed suture tape (red arrow) and IP needle with a PROLENE loop (yellow arrow) inserted through the anterior hole. (D) Arthroscopy view of subacromial space depicting both anterior (yellow arrow) and posterior (white arrow) drill holes in the acromion through which the suture tape (black arrow) is being passed. Red arrow depicts the direction of suture tape passage.

the reduction. Provisional fixation of the AC joint is performed with a 2-mm K wire passing from the acromion to the clavicle across the AC joint (Fig 10 C and D).

Step 4: Knot-Tying Over the Clavicle

Both limbs of the suture tape are retrieved anterior to the clavicle in step 3. One limb of the suture tape is shuttled posterior to the clavicle from anterior position. A right-angled forceps is passed through the clavicular incision from anterior of the clavicle to the posterior. The jaws of this forceps are used to grab a loop of PROLENE, which is pulled from posterior to anterior side, and this PROLENE loop is used to shuttle medial limb of suture (coming from medial to the coracoid) posterior to the clavicle. Both the limbs are tied over the clavicle fixing the CC joint (Fig 11 A-D). After this, both the limbs of sutures are passed to the acromial incision by connecting clavicular and acromial incision.

Step 5: Looping Suture Tape Through the Acromion Tunnels

Through the posterior arthroscopy portal, a 30° arthroscope is introduced into the subacromial space. Then, under vision, the previously placed anterolateral cannula is redirected to the subacromial space. With posterior portal as viewing portal and anterolateral as working portal, minimal debridement of subacromial fat is performed to expose the under surface of the acromion. Using a 1.8-mm Beath pin, a drill hole is made through the acromial incision from superior to inferior surface of acromion, 1 cm lateral to the AC joint along the posterior border of the clavicle (Fig 12 A and B). A Beath pin is replaced with an IP (Initial Puncture) needle (Blueneem, Bengaluru, India) with a PROLENE suture passed through its lumen, making a loop of PROLENE at its tip (Fig 12 C and D). Using a suture manipulator, the loop of prolene in the subacromial space is pulled outside through the anterolateral cannula. With this PROLENE suture, one limb of the suture

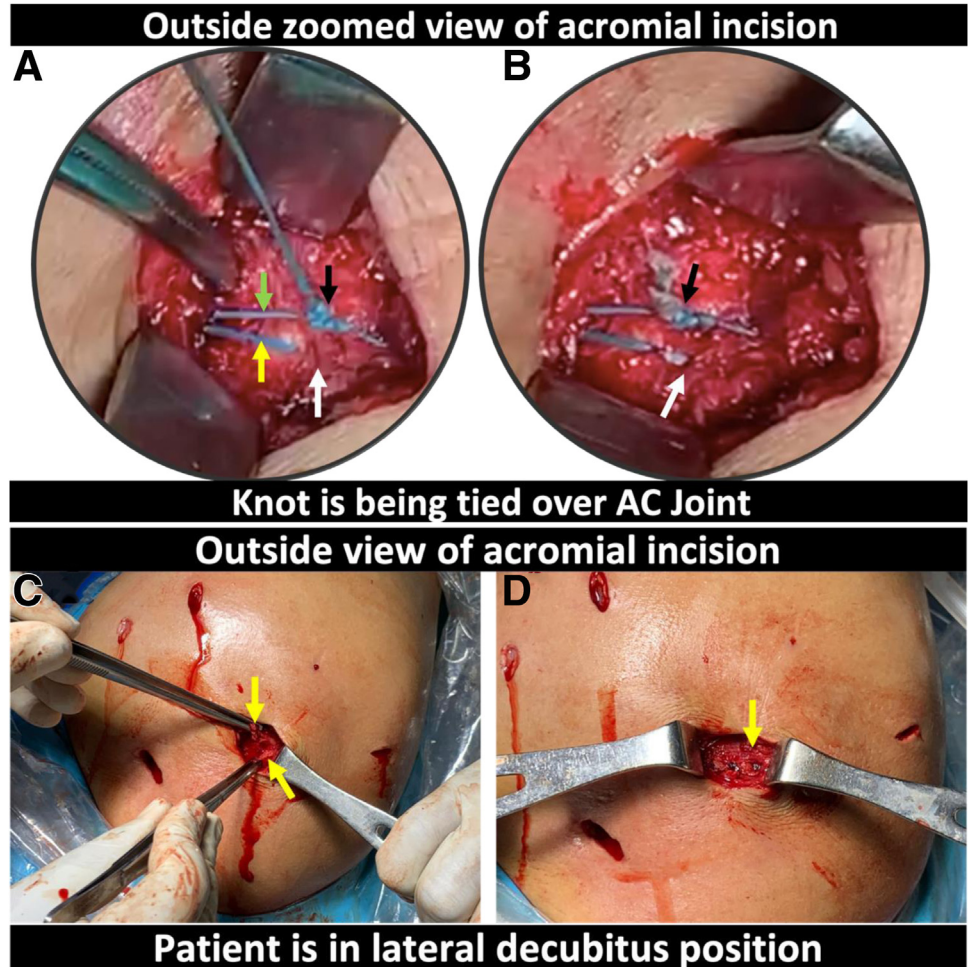


Fig 14. Knot-tying above the acromion and repairing the soft tissues. (A) Both limbs of the suture tape (one limb passing through the posterior hole and exiting from the anterior hole [yellow arrow] and other passing from the clavicular incision to acromial incision [green arrow]) are tied (black arrow) above the AC joint (white arrow). (B) Outside view of the acromial incision where knot has been tied and cut (black arrow) above the AC joint. (C) View of the acromial incision showing the acromioclavicular ligaments along with the deltotracheal fascia (yellow arrows). (D) Final picture of the acromial incision after repairing the acromioclavicular and deltotracheal fascia.

tape is now shuttled from the acromial wound to the anterolateral cannula (Fig 12 E and F).

The same process is repeated to retrieve the suture tape limb from other drill hole in acromion. Another drill hole is made through the acromial incision from superior to inferior surface of acromion, 1 cm lateral to the AC joint along the anterior border of the clavicle (Fig 13 A and B). The Beath pin is again replaced by the IP needle with a PROLENE passed through its lumen making a loop of PROLENE at its tip (Fig 13 C and D). The loop of PROLENE is pulled outside from the sub-acromial space through the anterolateral cannula. The PROLENE loop is then used to shuttle back the limb of suture tape in the cannula making a loop across the 2 holes in the acromion (Fig 13 C and D).

Step 6: Knot-Tying Over the Acromion

Since both limbs of the suture tape are above the acromion, 4 simple surgical knots are made alternating the post (Fig 14A) and both the limbs are cut (Fig 14B). After the suture limbs are tied, the K-wire transfixing the AC joint is removed. Anterior, superior, and

posterior AC ligaments along with the deltotracheal fascia are identified, and they are repaired with absorbable sutures (Fig 14 C and D).

Clavicular and acromion incisions are closed in layers. A vertical mattress suture is applied to close the skin incision (Fig 15). Preoperative and postoperative radiographs of the patient should show adequately reduced CC and AC joints (Fig 16).

Discussion

In a review article, Beitzel et al.¹¹ mention that there are more than 150 techniques for AC joint stabilization. AC joint transfixation with K-wires and the CC cerclage techniques, which were popular in 2001, are used infrequently in present practice because of unknown reasons.² Balke et al.² described that general orthopaedic surgeons preferred the hook plate, whereas specialists favored the arthroscopic suture button device technique. Both these techniques are indirect repair techniques that rely on healing of CC and AC ligaments by holding the clavicle–coracoid relationship in a

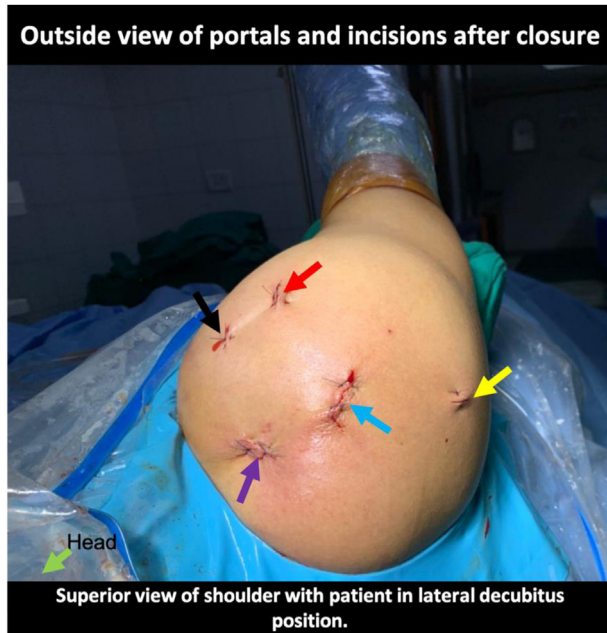

Fig 15. Outside view of the right shoulder with patient in lateral decubitus position, showing closure of posterior portal (yellow arrow), anterolateral portal (red arrow), anterior portal (black arrow), clavicular incision (purple arrow), and acromion incision (blue arrow).

reduced position long enough to allow healing of these ligaments.⁵ Arthroscopic CC fixation of acute AC joint dislocations has become popular in the recent years, as it is a minimally invasive, “one-step” procedure using special implants that do not require a second surgery for implant removal. However, these techniques have complication rates as high as 27%, and many of these complications are related to drilling of coracoid and clavicle.⁷

Recently, horizontal stability has been found to have an important role in achieving good biomechanical

stability. In their biomechanical study, Dyrna et al.¹² mention that the combined stabilization of the AC capsule and CC ligaments has the optimal capacity to restore native stability against translational and rotational loads at AC joint. They also examined several configurations of the AC capsule repair and found that those configurations revealed no significant individual differences.

Seo et al.⁴ performed CC fixation with a dog button device and used limbs of the same suture to fix AC joint using knotless anchors. El Shewy and El Azizi⁹ looped the suture tape around the coracoid and made a single drill hole in clavicle for CC fixation to reduce the complication of coracoid fracture.

Our technique is a combination and modification of various techniques used to stabilize both CC and AC joints. In this technique, we do not make any holes in coracoid or clavicle. Rather, we loop the tape around the coracoid and clavicle, which will avoid complications associated with the drilling of the clavicle and the coracoid. The advantages and disadvantages of this technique are summarized in [Table 2](#). This technique is technically demanding, as it requires arthroscopic exposure of the medial border of coracoid and skills to perform subacromial arthroscopy is required. The risks and tips to avoid them during each step of this technique are described in [Table 3](#).

Our technique does not require any special implant or instrumentation. It can be easily performed with general shoulder arthroscopy instruments. In addition, it is cost-effective. A major advantage of our technique is that an open, under vision reduction of AC joint is performed. This help in adequate reduction of AC joint, inspection of the disc tissue, and the torn AC ligaments can be identified which can be repaired during closure of the incision.

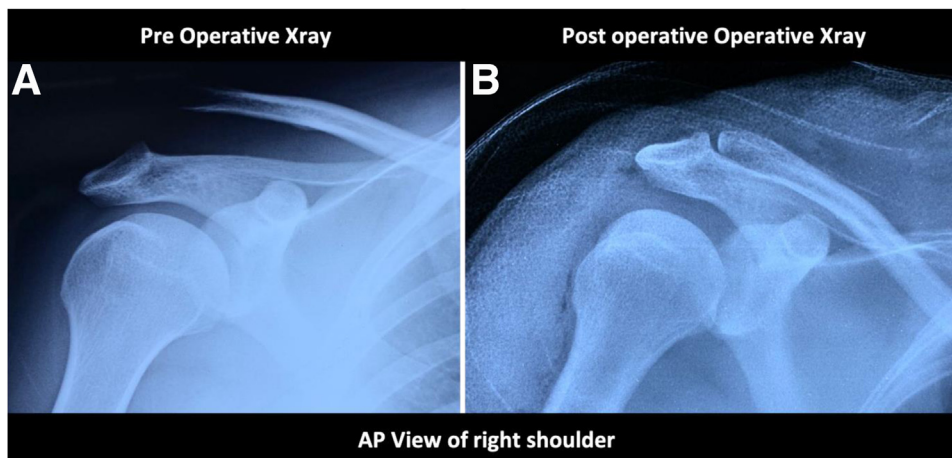


Fig 16. Comparison between preoperative and postoperative radiographs. (A) Preoperative anteroposterior (AP) view of the right shoulder. (B) Postoperative radiographs of the right shoulder of same patient depicting well reduced acromioclavicular joint.

Table 2. Advantages and Disadvantages of This Technique

Advantages	Disadvantages
<ol style="list-style-type: none"> 1. Fixation of both coracoclavicular and acromioclavicular joint, which provides both vertical and horizontal stability. 2. No requirement of special implants, and it can be performed by materials used in basic shoulder arthroscopy procedures. 3. Less-invasive compared with open technique. 4. Diagnosis and treatment of intra-articular pathologies with preliminary arthroscopy. 5. No need of implant removal. 6. No tunnels are made in coracoid or clavicle, which avoids complications associated with drilling of tunnel such as fractures. 7. Along with suture augmentation, direct repair of acromioclavicular ligament and clavitrapezoidal fascia is performed. 	<ol style="list-style-type: none"> 1. Technically more demanding as medial border of coracoid has to be exposed. 2. Coracoacromial ligament has to be sacrificed. 3. Subacromial arthroscopy is required for this technique. 4. Two small drill holes are required in the acromion.

All surgical techniques described in literature for the treatment of AC joint dislocation has its own advantages and disadvantages (Table 2).¹¹ Our technique has advantage of both CC and AC joint

fixation without drilling any holes in coracoid or clavicle. The risks and tips to avoid are described in Table 3. At present, this technique is our preferred technique for acute (<3 weeks) injuries, but its true

Table 3. Risks and Tips to Avoid in Our Techniques

Steps	Risks	Tips to Avoid
Step 1: Arthroscopic exposure of the coracoid	Bleeding	While exposing the coracoid, RF ablator alone has to be used to ablate the tissue. Aggressive shavers should not be used.
	Injury to the conjoint tendon	The arthroscopic anatomic position has to be maintained during the entire procedure to carefully identify the structures around the coracoid, and tissue ablation has to be performed toward the base of coracoid rather than toward the tip. While ablating tissue around the coracoid, the RF wand has to be used as probe as well, and the tissue adjacent to bone only is cut.
	Brachial plexus injury	Brachial plexus lies medial to the coracoid. Hence, there is risk of injury while making window in pectoralis minor. The window is created after adequate exposure of medial border and cutting tip of RF has to be always kept touching the coracoid.
Step 2: Looping suture tape around base of coracoid.	Entanglement of sutures	A cannula has to be placed in working portal to avoid any entanglement of sutures.
Step 3: Temporary fixation of the AC joint	Malreduction of AC joint	AC joint is reduced under vision through the acromial incision. In case of doubt, an image intensifier can be used to confirm the reduction.
Step 4: Knot-tying over the clavicle.	Loose knots	The knot has to be tied meticulously and an artery forceps can be used to hold the first simple knot tight until the surgeon applies the subsequent knots. At this stage, sliding and locking knots also can be applied if a high-tensile suture is used. A sliding knot is difficult with suture tape.
Step 5: Looping suture tape through the acromion tunnels.	Entanglement of sutures	Suture management has to be done through anterolateral working portal in which arthroscopy cannula is placed.
Step 6: Knot-tying over the acromion	Loose knots	The knot has to be tied meticulously and an artery forceps can be used to hold the first simple knot tight until the surgeon applies the subsequent knots.

AC, acromioclavicular; RF, radiofrequency.

clinical significance needs to be investigated with future studies.

References

1. Warth RJ, Martetschläger F, Gaskill TR, Millett PJ. Acromioclavicular joint separations. *Curr Rev Musculoskelet Med* 2012;6:71-78.
2. Balke M, Schneider MM, Shafizadeh S, Bähis H, Bouillon B, Banerjee M. Current state of treatment of acute acromioclavicular joint injuries in Germany: Is there a difference between specialists and non-specialists? A survey of German trauma and orthopaedic departments. *Knee Surg Sports Traumatol Arthrosc* 2015;23:1447-1452.
3. Martetschläger F, Tauber M, Habermeyer P, Selim HA. Arthroscopic coracoclavicular and acromioclavicular stabilization of acute acromioclavicular joint dislocation by suspensory fixation system. *Arthrosc Tech* 2019;8:e611-e615.
4. Seo JB, Heo K, Kim SJ, Jung JU, Yoo JS. Arthroscopic acromioclavicular fixation with suture tape augmentation after coracoclavicular fixation with dog bone button: Surgical technique. *Arthrosc Tech* 2018;7:e1197-e1203.
5. Lee SJ, Nicholas SJ, Akizuki KH, McHugh MP, Kremenec IJ, Ben-Avi S. Reconstruction of the coracoclavicular ligaments with tendon grafts: A comparative biomechanical study. *Am J Sports Med* 2003;31:648-655.
6. Frank RM, Cotter EJ, Leroux TS, Romeo AA. Acromioclavicular joint injuries: Evidence-based treatment. *J Am Acad Orthop Surg* 2019;27:e775-e788.
7. Martetschläger F, Horan MP, Warth RJ, Millett PJ. Complications after anatomic fixation and reconstruction of the coracoclavicular ligaments. *Am J Sports Med* 2013;41:2896-2903.
8. Barth J, Duparc F, Andrieu K, et al. Is coracoclavicular stabilisation alone sufficient for the endoscopic treatment of severe acromioclavicular joint dislocation (Rockwood types III, IV, and V)? *Orthop Traumatol Surg Res* 2015;101:S297-S303.
9. El Shewy MT, El Azizi H. Suture repair using loop technique in cases of acute complete acromioclavicular joint dislocation. *J Orthop Traumatol* 2011;12:29-35.
10. Jen CL, Toon DH, Tan CH. Radiological study of the Asian coracoid process and clavicle: Implications for coracoclavicular ligament reconstruction. *Chin J Traumatol* 2020;23:56-59.
11. Beitzel K, Cote MP, Apostolakis J, et al. Current concepts in the treatment of acromioclavicular joint dislocations. *Arthroscopy* 2013;29:387-397.
12. Dyrna F, Imhoff FB, Haller B, et al. Primary stability of an acromioclavicular joint repair is affected by the type of additional reconstruction of the acromioclavicular capsule. *Am J Sports Med* 2018;46:3471-3479.