

# Distribution of Basic Fibroblast Growth Factor in the 18-Day Rat Fetus: Localization in the Basement Membranes of Diverse Tissues

Ana-Maria Gonzalez, Marino Buscaglia, Michael Ong, and Andrew Baird

Department of Molecular and Cellular Growth Biology, The Whittier Institute for Diabetes and Endocrinology, La Jolla, California 92037

**Abstract.** Immunohistochemical methods were used to study the distribution of basic FGF in the 18-d rat fetus. The results reveal a pattern of widespread yet specific staining that is consistent with the wide distribution of basic FGF. Immunoreactive basic FGF is associated with mesenchymal structures, mesoderm- and neuroectoderm-derived cells, and their extracellular matrices. As an example, skeletal and smooth muscle cells are strongly positive. The basement membrane underlying the epithelia always contain basic FGF. In some tissues (i.e., cartilage and bone) the intensity of immunostaining is dependent on the stage of

cell differentiation.

Although the staining of tissues is primarily associated with the extracellular matrix, there is significant intracellular staining in various cell types. This is particularly evident in the endocrine cells of the adrenal cortex, testis, and ovary. The histochemical findings reported here support the notion that basic FGF has the characteristics required to mediate many of the effects of the mesenchyme on cell growth and differentiation. The significance of these findings in understanding the role of basic FGF in regulating cell proliferation and differentiation is discussed.

**B**ASIC fibroblast growth factor (FGF)<sup>1</sup> is a pluripotential growth factor that is mitogenic for various types of mesoderm- and neuroectoderm-derived cells in culture (6, 23, 24). In various *in vivo* models, basic FGF is multifunctional. As an example, it is a potent angiogenic factor that can also induce the formation of mesenchyme (16, 30), yet it represses terminal differentiation of skeletal muscle (10). It has also been associated with such processes as wound healing (18, 37, 42), normal reproductive function (21),<sup>2</sup> fetal (32) and embryonic (38, 39, 43) development, and in tumorigenesis (16). The high concentrations of basic FGF that are found in the brain and the fact that it can increase the survival of peripheral and central neurons *in vivo* and *in vitro*, support the notion that it is also a neurotrophic factor (3, 35, 41, 48, 50).

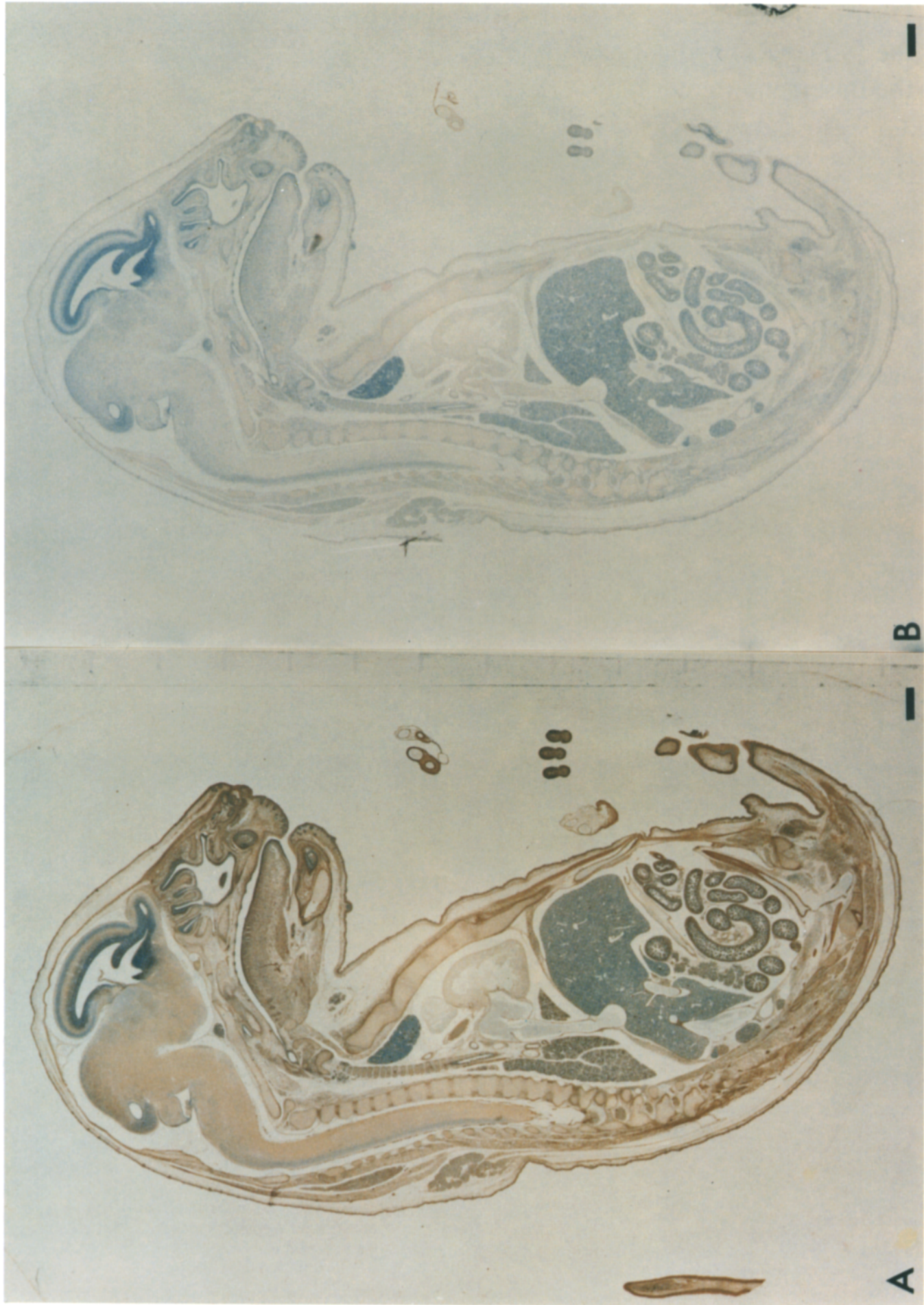
Although basic FGF can be purified from different organs and tissues, its distribution in these tissues is not known. The characterization of the protein and the cloning of its mRNA from bovine (1, 14), ovine (45), human (2, 9), rat (44), and frog (30) cDNA libraries has revealed that the sequence of basic FGF is highly conserved between species and permitted the direct study of the gene transcription and translation. It is synthesized by almost all of its target cells (including

some tumor cells) when they are grown in culture (5). Yet, while the expression of basic FGF is high in the adult brain, in peripheral tissues its mRNA is low to undetectable (13, 34, 44). This is particularly remarkable when coupled to the fact that it is present in sufficiently high concentrations to be purified and characterized from many peripheral tissues including pituitary, cartilage, bone, placenta, corpus luteum, kidney, adrenal, heart, muscle, eye, and retina (5, 24). Because of this wide distribution, the virtual absence of its mRNA, and its high affinity for heparin, several investigators have proposed that basic FGF is stored and stabilized in the extracellular matrix (4, 5, 17, 49).

Several studies have now shown that the gene for basic FGF is expressed in early embryonic development, and have suggested that the growth factor may play an important role in tissue growth and differentiation (26, 30–32). Because the expression of basic FGF during embryonic development occurs at a time when there is extensive tissue growth and remodeling, the conditions are ideal for its incorporation into the basement membrane. In the study described here, we have localized basic FGF to the basement membrane in many diverse tissues of the 18-d fetal rat. At this stage, tissues are almost completely differentiated but there is extensive remodeling in progress. The observation that the appearance of basic FGF in the extracellular matrix is dependent on the stage of tissue differentiation may help determine its physiological function in normal mammalian development and emphasizes the need for further studies on the distribution of basic FGF in the developing embryo.

1. *Abbreviations used in this paper:* FGF, fibroblast growth factor; TGF, transforming growth factor.

2. Baird, A., N. Emoto, S. Shimasaki, A. M. Gonzalez, B. Fauser, and A. J. W. Hsueh, unpublished observations.



## Materials and Methods

### Tissue Preparation

18-d-old Sprague-Dawley rat fetuses were collected from pregnant rats, fixed in Bouin's solution, dehydrated through a graded series of ethanol, and embedded in paraffin. 8- $\mu$ m sagittal sections were deparaffinized and hydrated. Endogenous peroxidase activity was quenched by incubating the sections for 30 min in 0.3% hydrogen peroxide in absolute methanol at room temperature. To facilitate penetration of the antibody into the tissue, the sections were then washed in PBS and treated with 1 mg/ml of hyaluronidase (type V; Sigma Chemical Co., St. Louis, MO) buffered at pH 5.5 with 0.1 M sodium acetate containing 0.15 M NaCl, for 30 min at 37°C. Unless described otherwise, each step of the staining procedure was performed at room temperature.

### Antibodies

Polyclonal antibodies were raised against the 1-24 synthetic fragment of bovine basic FGF (1-146). These antibodies detect basic FGF and do not recognize (<1%) acidic FGF. Although their cross-reactivity with int-2, hst/ks, FGF-5, and FGF-6 is not known, there is low sequence homology in the area corresponding to the peptide antigen sequence used. IgG fractions were prepared by ammonium sulfate precipitation (30%), were purified by passage over a protein A-Sepharose column and used in the studies reported here. In control studies, the IgG (2.5  $\mu$ g/ml of IgG) used was preincubated with Affigel 10 alone or with Affigel 10 that had been coupled with recombinant basic FGF (400  $\mu$ g/ml). The Affigel was removed by centrifugation and the supernatants were used. These controls were confirmed by staining in the presence (100  $\mu$ g/ml) of the peptide fragment FGF(1-24) or by removing the anti-FGF IgG by passage through an Affigel-FGF affinity column. Both of these procedures failed to stain the tissue sections (not shown). Basic FGF was coupled to the Affigel 10 according to manufacturer (Bio-Rad Laboratories, Richmond, CA) specifications. Identical staining was observed with IgG prepared from a polyclonal antibody raised in rabbits against intact human recombinant basic FGF (8) (not shown).

### Immunohistochemistry

The tissue sections were incubated in 1.5% goat serum (Vector Laboratories, Inc., Burlingame, CA) for 30 min to reduce nonspecific staining. The sections were subsequently incubated overnight (20 h) at 4°C with the protein A-purified antibodies (2.5  $\mu$ g/ml) diluted in PBS supplemented with 0.3% Triton and 5% BSA. The sections were then treated with a 1:200 dilution of biotinylated goat anti-rabbit IgG (Vector Laboratories, Inc.) for 1 h, followed by a 30-min incubation with a biotin-avidin-peroxidase complex (Vector Laboratories, Inc.). Finally, the sections were treated for 5 min in 0.5 mg/ml of diaminobenzidine (Sigma Chemical Co.) prepared in 10 mM TBBS, pH 7.6, and containing 0.01% hydrogen peroxide. All steps were separated by buffer washes consisting of PBS-0.3% Triton. The sections were counterstained in Harris hematoxylin, dehydrated, cleared, and mounted. In control experiments, the antibodies were replaced with either (a) BSA, (b) normal rabbit serum, (c) Affigel 10-treated IgG, (d) Affigel 10/FGF-treated IgG, (e) IgG prepared from the flow through of a Affigel-basic FGF immunoaffinity column, or (f) IgG presorbed with FGF (1-24). Some of the tissue sections were also pretreated with 0.15 M NaCl, 1 M NaCl, or 2 M NaCl in PBS for 5 or 15 min before the immunostaining to selectively remove the basic FGF from the extracellular matrix of tissues.

## Results

### Cross Section of the Entire 18-d Rat Fetus

Staining of the 18-d rat fetus with the protein A-purified antibody to basic FGF revealed a widespread distribution of staining in several though not all tissues (Fig. 1 A). Absorp-

tion of the antibody to Affigel-basic FGF beads abolished virtually all staining (Fig. 1 B). A total absence of staining was also obtained by passing the antibody through an Affigel-FGF immunoaffinity column or by pre- or coincubating the antisera with the peptide antigen basic FGF(1-24)NH<sub>2</sub> (not shown). When the anti-basic FGF was replaced by BSA or normal rabbit serum, there was also no staining observed (not shown). As expected, when the anti-basic FGF antiserum was preincubated with uncoupled Affigel 10 only, there was no blocking of the staining. On this basis we concluded that the antisera is recognizing a basic FGF-like antigen in the tissue sections. It is important to note that a combination of high background and extensive undisplaceable staining of the skin, gut, and ganglionic neurons precluded the use of unpurified antisera (not shown).

As shown in Fig. 1 A, there is a clear, widespread, and diffuse pattern of staining that is not exclusively localized in any one tissue. Mesodermal-derived tissues are positively stained and the staining is more intense where there is juxtaposition with the epithelium. The epithelial cells in each of the different tissues and the blood cells are devoid of any basic FGF. It is the mesenchyme underneath epithelial tissues (i.e., skin, buccal tract, salivary gland, gut, kidney, and lung in Fig. 2) that shows intense positive staining. This pattern of staining is associated for the most part with the extracellular matrix but can also be associated with the cell itself (Fig. 2). All basement membranes underlying the epithelial cells of the digestive tract, skin, lung, kidney, Müllerian and Wolffian ducts, salivary glands, pancreas, sex cords, and sebaceous glands are strongly positive, but the epithelial cells themselves are negative (see Figs. 2, 5, 7, and 8). The endothelial cells from capillaries and large vessels show a strong staining (Figs. 2 A and 3, C and D). In the brain and spinal cord there is also widespread staining. In all instances, however, there is an absence of staining when performed with ligand affinity-absorbed antibody (see Fig. 9, B-E).

### Muscle

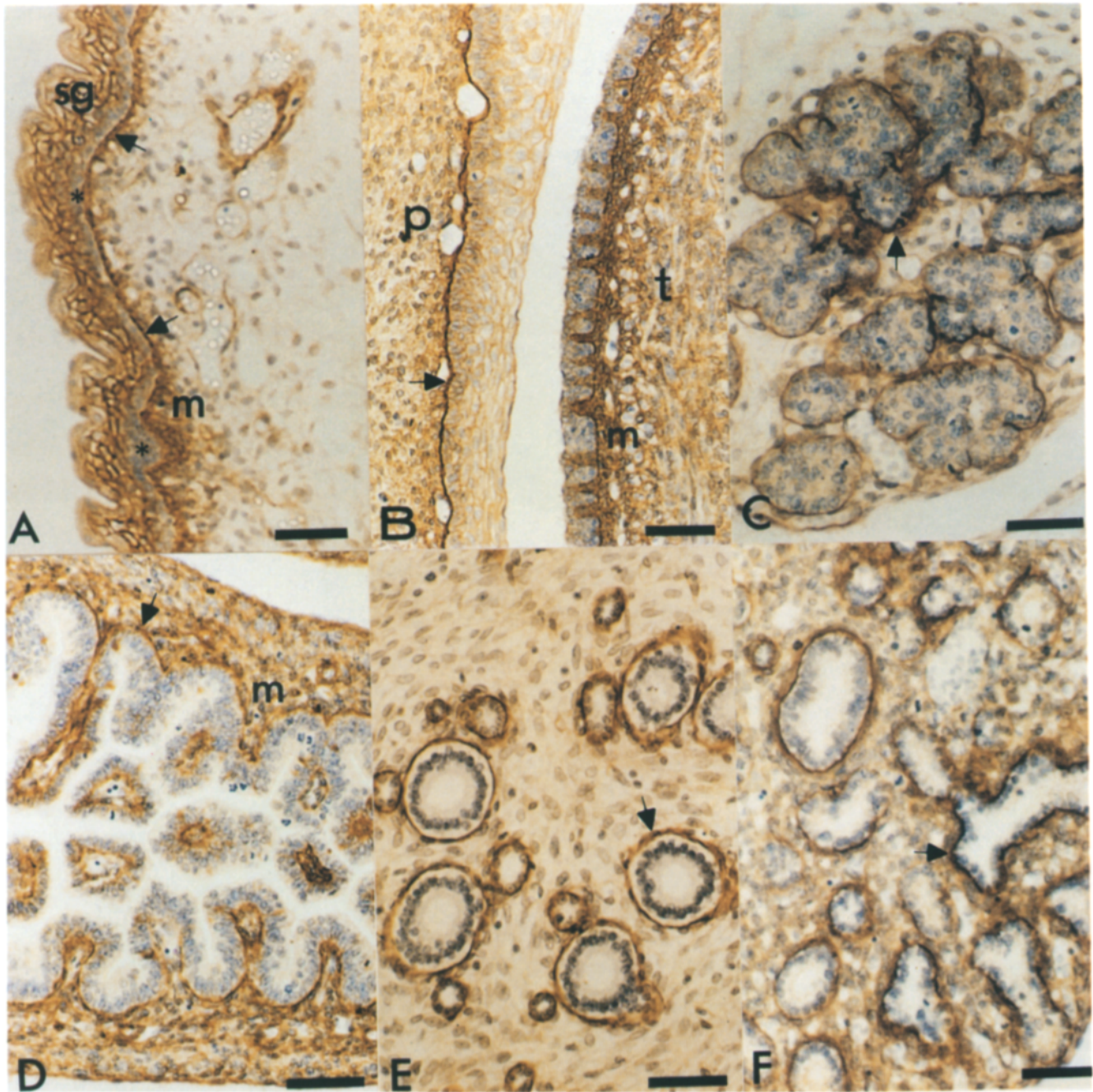
Among mesoderm-derived tissues, skeletal muscle (Fig. 3, A and B) and smooth muscle associated with the digestive tract (Fig. 2 D) and arteries (Fig. 3 D) are strongly positive. Staining can be clearly seen in transversal as well as in longitudinal sections. The staining is associated with intracellular myofibers as well as with the surrounding connective tissue (Fig. 3, A and B). In the heart (Fig. 3 C), the myofibers show a very low signal, but the small vessels that supply the ventricular muscular fibers are distinctly positive. The smooth muscle cells of the walls of the large vessels show intense staining (Fig. 3 D).

### Cartilage and Bone

In cartilage, the pattern of staining changes according to the stage of differentiation (Fig. 4). As an example, chondrocytes in early stages of differentiation are clearly positive (Fig. 4 A), but before ossification, when they are turning hyper-

**Figure 1.** Sagittal section of an 18-d-old rat fetus. Sections were stained as described in the text with protein A-purified anti-basic FGF (A) and a preparation of antibody specifically depleted of anti-FGF IgG by FGF affinity chromatography (B). Bars, 1 mm.





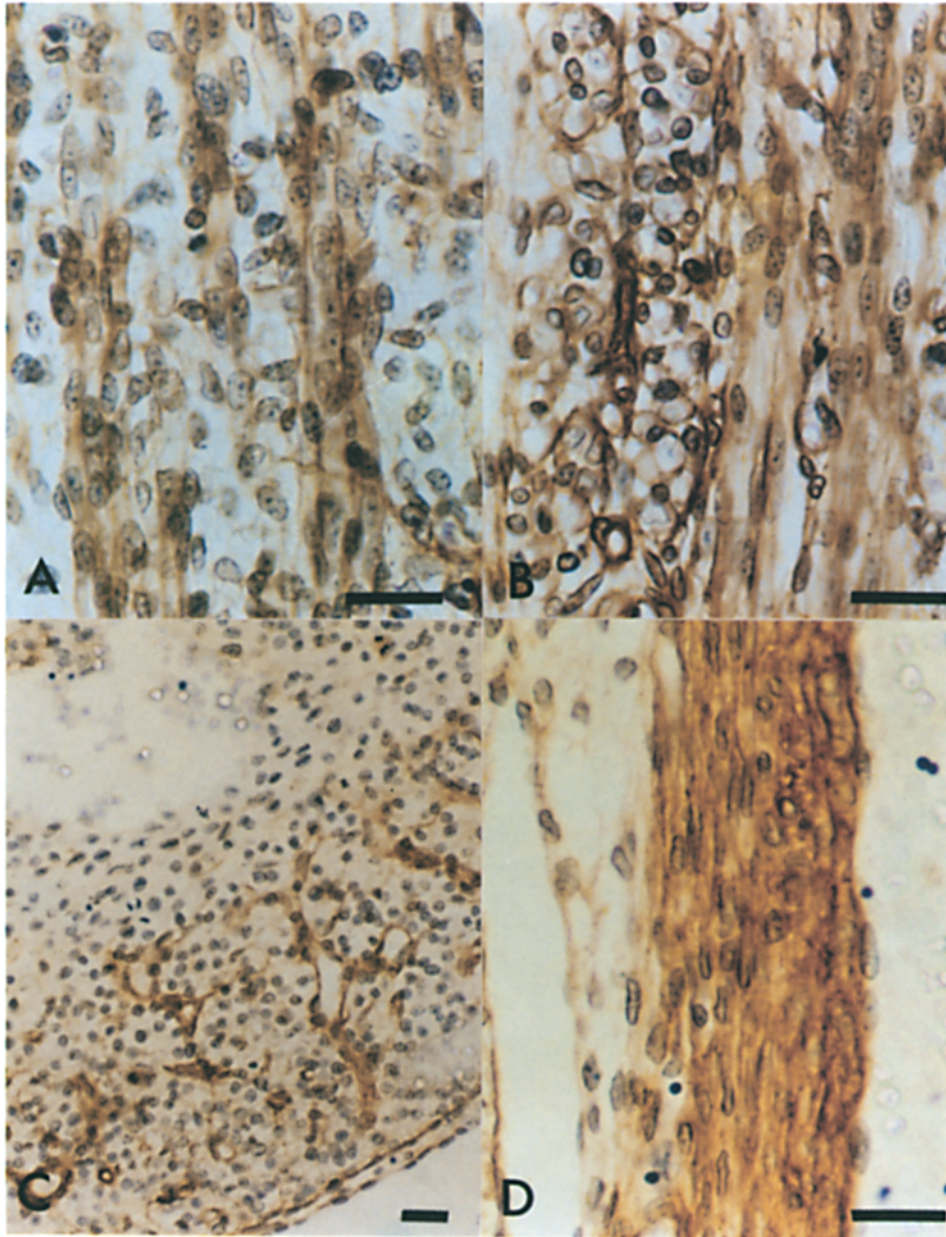
**Figure 2.** Localization of basic FGF in epithelial tissues and their basement membranes. The basement membrane (arrows) underlying different epithelium and the associated cell-dense mesenchyme (*m*) is consistently stained in various tissue sections. (A) Skin; (B) buccal tract; (C) salivary gland; (D) digestive tract; (E) kidney; (F) lung. Stratum granulosum (*sg*), stratum basale (\*), palate (*p*), and tongue (*t*) are indicated. Bars, 50  $\mu$ m.

trophic, immunoreactive basic FGF is localized in the cartilage matrix (Fig. 4 B). This distribution is clearly visible during the process of ossification where the matrix is strongly positive (Fig. 4 C). The centers of ossification (which are characterized by calcification of the hyaline matrix, regressive hypertrophy of the chondrocytes, and by active capillary growth), contain intense staining for basic FGF in both the calcified matrix and inside the osteoblasts (Fig. 4 D). The absence of staining in control studies can be established in all instances of chondrocyte differentiation (see Fig. 9, F-I).

#### **Skin, Hair Follicles, and Teeth**

The specific staining in skin is associated with the compact cells of the mesenchyme and with basement membranes (Fig. 5 A). Strong staining is observed in the stratum granulosum and it appears exclusively extracellular (Fig. 5 B). The stratum basale is devoid of staining but the mesenchymal cells of the dermis show an intense positive reaction that is stronger in cell-dense areas (Fig. 5, B and C). In the hair follicles and in the forming teeth, basic FGF is also found in the compact mesenchyme. As in other tissues, the





**Figure 3.** Staining of basic FGF in muscle. The striated and smooth muscle and the surrounding loose connective tissue contain basic FGF immunoreactivity. (A) Longitudinal section of a striated muscle. (B) Transversal and longitudinal sections of striated muscle. (C) In the heart, the capillaries that irrigate the ventricular muscular fibers are strongly positive but the cardiac fibers show only low staining. (D) The medial layer of arteries which are mainly composed of smooth muscle cells are strongly positive. Bars, 25  $\mu$ m.

capillary endothelium and the basement membrane associated with the epidermis contain basic FGF immunoreactivity.

### **Central and Peripheral Nervous System**

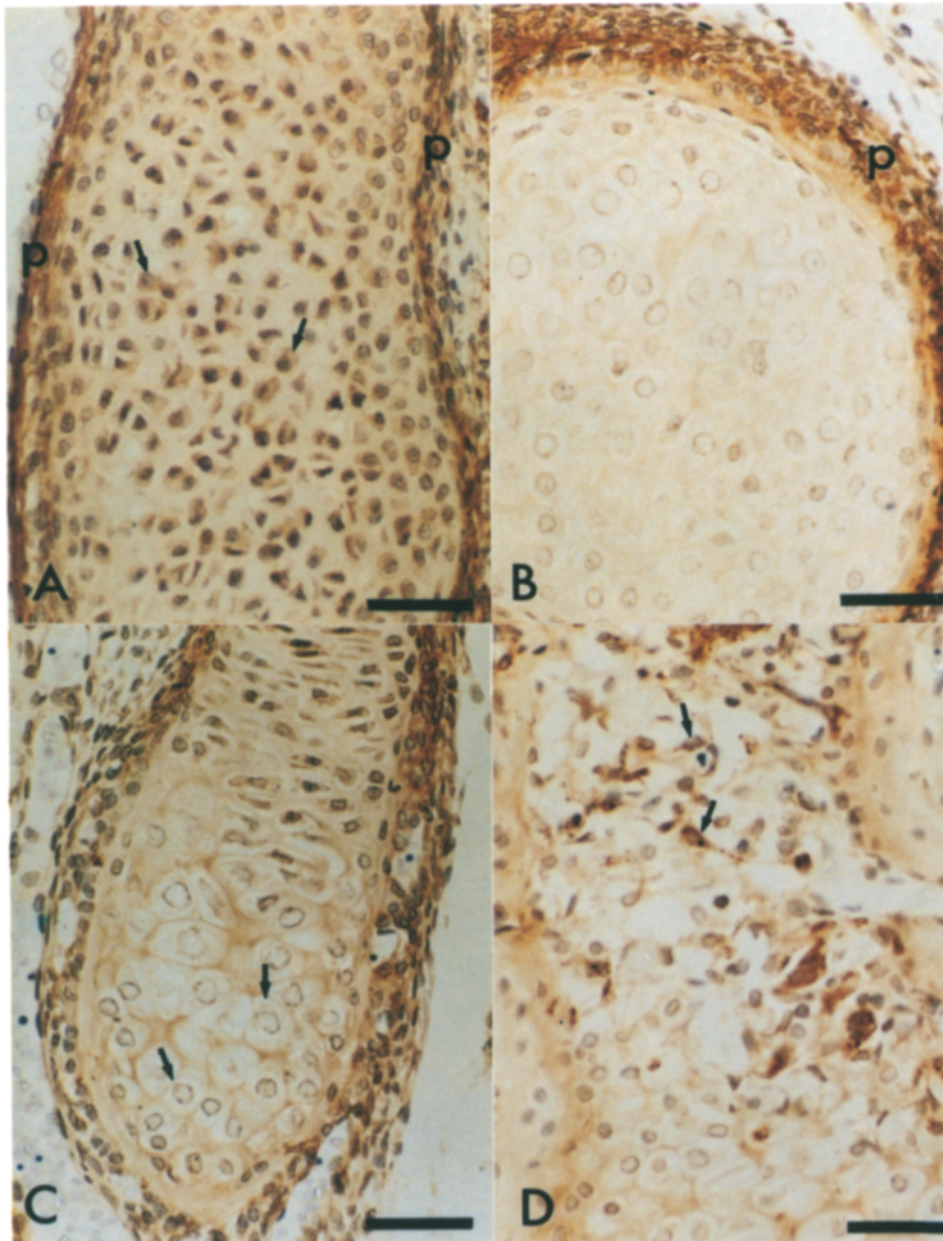
On the whole, the brain shows widely distributed, although not homogeneous, staining for basic FGF (Fig. 6 A). Some areas (such as the telencephalon) show a higher intensity of staining in areas that are neuron rich. The staining is also specific as judged by the failure of ligand affinity-absorbed antibody to show a reaction (Fig. 9 A). In the diencephalon and mesencephalon, however, the staining is associated with fibers (Fig. 6 B). It is similar in the spinal cord, which also shows a diffuse staining pattern that is stronger around cells associated with the capillary endothelium (Fig. 6 C). In the paravertebral ganglions (Fig. 6 D), the ganglionic cells show low levels of staining which are unremarkable, especially

when compared to peripheral nerves. The peripheral nerves entering the ganglia show an intense staining that is associated with the nerve fibers, fibroblasts, endothelial cells, and the extracellular matrix. Unlike these areas of the nervous system, the choroid plexus shows the same pattern of staining that is seen in most other tissues (Fig. 6 A). The immunoreactive basic FGF is associated with loose connective tissue and the capillary bed, but not with epithelial cells. The meninges are also strongly positive (Fig. 6 A).

### **Endocrine Tissues**

In the testis (Fig. 7, A and B), ovary (Fig. 7, C and D), and adrenal cortex (Fig. 8 A), the steroidogenic cells all show the presence of immunoreactive basic FGF. The extracellular matrix that is associated with the loose connective tissue, the capillary endothelial cells, and their basement membranes are also stained. In the testis, the sex cords are completely





**Figure 4.** Staining of basic FGF at different stages of cartilage differentiation. (A) Chondrocytes (arrows) and hyaline matrix show a positive staining for anti-basic FGF. The perichondrium (p) is also highly stained. As shown in B in the early stages of ossification, the staining is mainly localized in the perichondrium (p) and the hyaline matrix is only slightly positive. At later stages of ossification (C), the hypertrophic chondrocytes (arrows) are almost negative and the hyaline matrix is positive. Finally when the hyaline matrix is ossified (D), basic FGF immunoreactivity is observed inside the osteoblasts (arrows) and the matrix shows a strong staining. Bar, 50  $\mu\text{m}$ .

negative but are underlined by a strongly positive basement membrane (Fig. 7 A). At high magnification (Fig. 7 B), the fibroblast-like cells of the interstitium only show moderate immunoreactivity whereas the basement membrane and the peritubular cells are more strongly stained. In the Leydig cells of the testis, the staining is both intracellular and cell surface associated (Fig. 7 B). The tunica albuginea and the interstitium show only a moderate positive reaction. In the ovary, the stroma, which is not yet fully differentiated, is stained (Fig. 7, C and D). The positive staining in the adrenal appears to be restricted to the fasciculata and reticularis layers of the cortex (Fig. 8 A). The glomerulosa and the adrenal capsule contain no basic FGF. When the tissue sections are incubated with the antibodies depleted of anti-IgGs by affinity chromatography, there is no staining (Fig. 8 B).

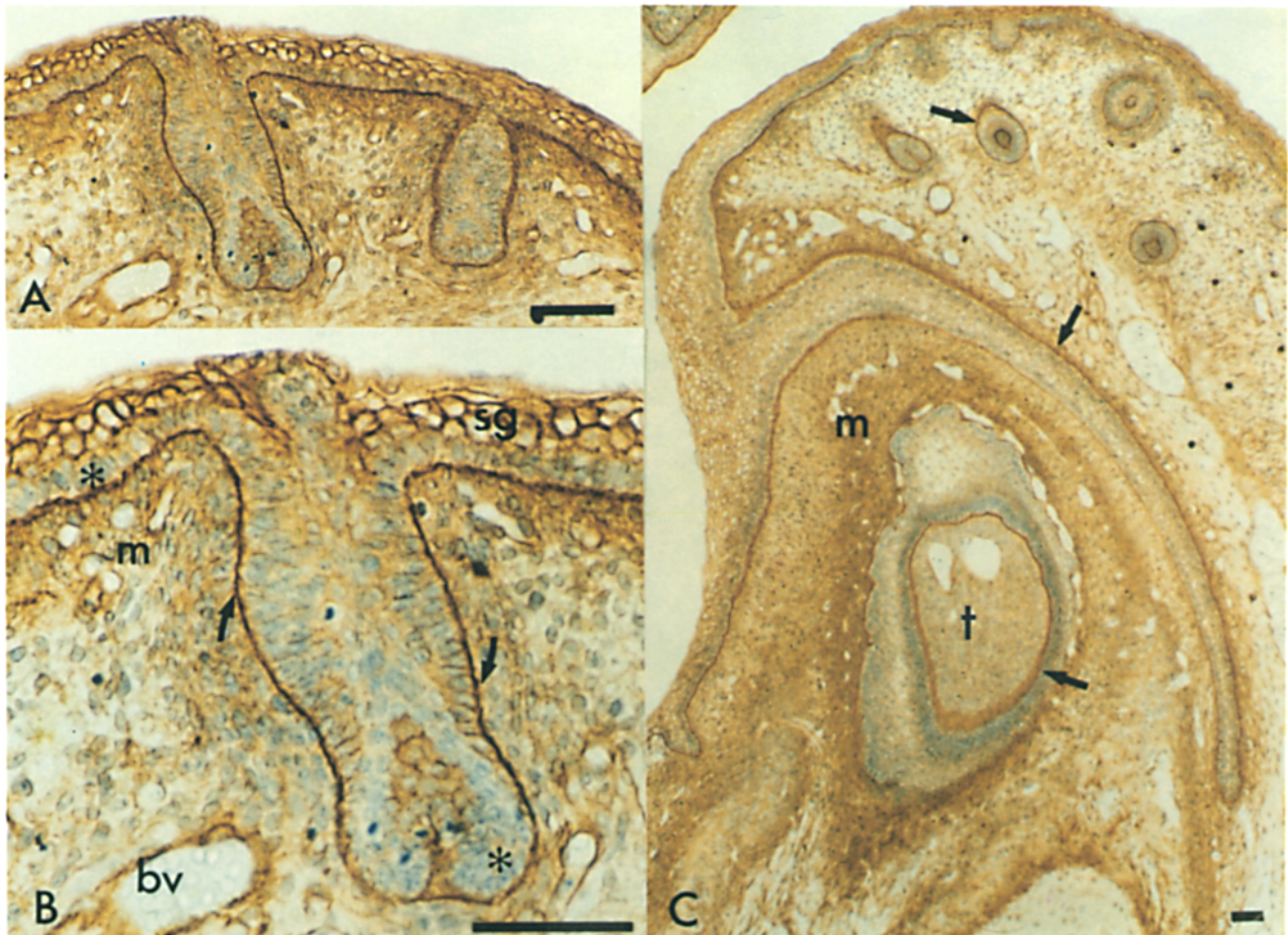
There is significant basic FGF associated with the base-

ment membrane underlying the endocrine cells of the differentiating pituitary gland (Fig. 8 C). With the exception of some cells, the pars nervosa, intermedia, and pars distalis all contain basic FGF.

#### **Basic FGF is Located in the Extracellular Matrix**

Tissue sections were incubated with PBS containing 2 M NaCl for 15 min to differentiate between extracellular and intracellular staining and remove any endogenous basic FGF bound to glycosaminoglycans. Under these conditions, the presence of basic FGF disappeared from the basement membrane, but intracellular staining was unaffected (Fig. 8 D). Washing the sections with lower salt concentrations (0.15 M NaCl in PBS) had no effect (Fig. 8 D). As expected, when the tissues are incubated with IgGs that are specifically





**Figure 5.** Localization of basic FGF in the skin. The specific staining is associated with cells of the compact mesenchyme (*m*), basement membrane (*arrows*), and the capillary endothelium (*A-C*). In the skin (*A* and *B*), the strong staining seen in the stratum granulosum (*sg*) is exclusively extracellular. The stratum basale (*\**) is negative. *A* and *B* also show staining surrounding the hair follicles and *C* shows a tooth in formation. Blood vessels (*bv*), stratum granulosum (*sg*), stratum basale (*\**), tooth (*†*), and basement membrane (*arrows*) are indicated. Bars, 50  $\mu$ m.

depleted of anti-basic FGF antibodies, there is no staining (Fig. 8 *E*).

#### ***Tissues Lacking Basic FGF***

The fetal liver shows the lowest staining for basic FGF among all of the tissues studied. Only the capsule and the vessels perfusing the organ reveal the presence of basic FGF (data not shown). There exist several cell types that are clearly devoid of immunoreactive basic FGF in the 18-d fetus. In each instance, they are distributed in many tissues. As an example, epithelial cells appear to be negative (Figs. 2-5). Similarly, cells of the adrenal capsule and zona glomerulosa appear devoid of immunoreactive basic FGF (Fig. 8 *A*).

#### ***Specificity of Staining***

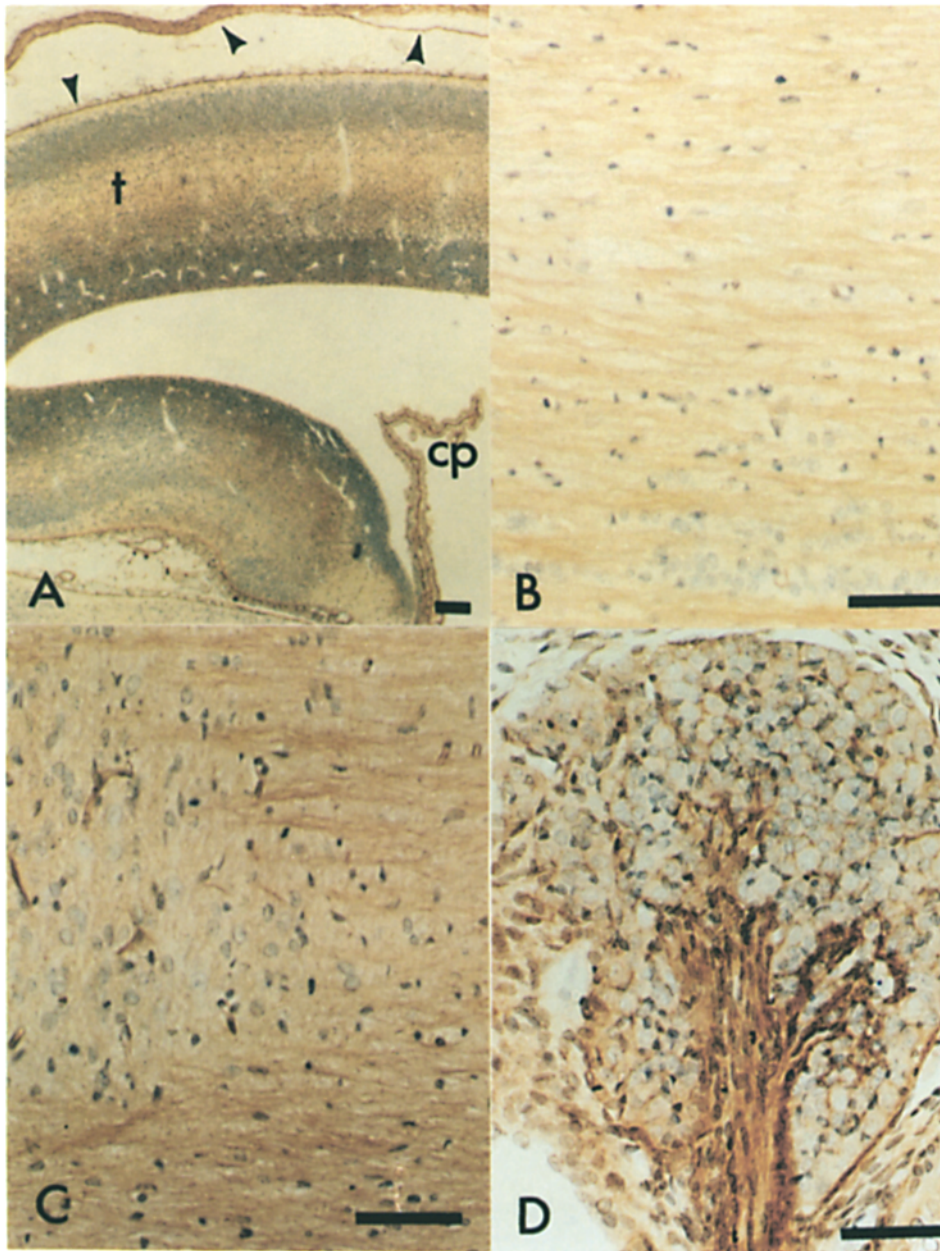
Tissue sections that have been shown to contain FGF by immunohistochemical analyses were all tested for the specificity of the staining (Fig. 9). In each instance, there is an absence of staining when the sections are examined using an

IgG preparation that is depleted of anti-basic FGF antibodies. Similarly, there is no staining when the anti-FGFs are coincubated with the antigen peptide FGF (1-24).

#### ***Discussion***

The results presented here demonstrate that basic FGF is associated with tissues of mesodermal and ectodermal origin and is predominantly localized in areas where the epithelium and mesenchyme are in juxtaposition. In the 18-d-old rat fetus, the distribution of basic FGF in some tissues (such as cartilage) is related to the stage of differentiation. Specifically, the presence of basic FGF in compact early chondrocytes, and its absence later in the hypertrophic ones, supports the notion that it is released into the matrix and plays a role in regulating chondrocyte function before ossification (19). These data thus correlate well with the reported mitogenic activity of the matrix of bone and cartilage (25, 49), and the fact that ossification is accompanied by an intense burst of angiogenesis.





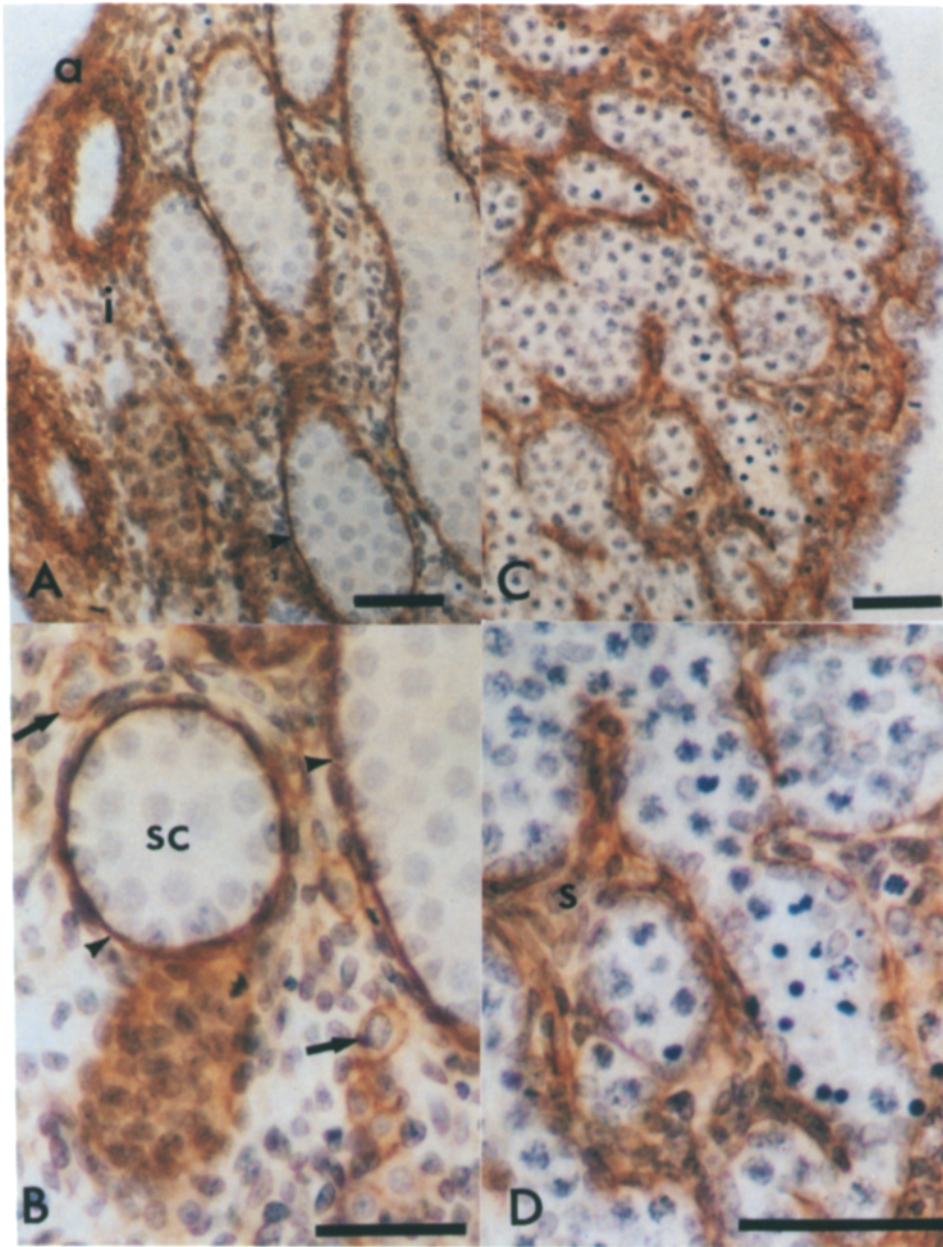
**Figure 6.** Immunostaining of basic FGF in the nervous system. (A) Low magnification of the brain. (B) Mesencephalon. (C) Spinal cord. (D) Paravertebral ganglion. In the telencephalon (*t*), an homogeneous staining is seen in high density neuron perikaria areas. The meninges (*arrowheads*) are very positive. The choroid plexus (*cp*) shows a positive staining that is associated with loose connective tissue but not with epithelial cells. The mesencephalon (*B*) and the spinal cord (*C*) show a different pattern of staining. The peripheral nerves (*D*) that are entering a paravertebral ganglion show strong staining compared to the ganglionic neurons. Telencephalon (*t*), choroid plexus (*cp*), and meninges (*arrows*) are indicated. Bars: (A) 100  $\mu$ m; (B-D) 50  $\mu$ m.

In the brain, as well as in the spinal cord, basic FGF is widely distributed but is clearly more concentrated in endothelial cells. Staining in the telencephalon correlates with areas where there is a high density of neuronal cell bodies. In contrast, in the diencephalon and mesencephalon the staining is associated with fiber-rich areas. Staining of basic FGF in the fetal brain is consistent with many of its potent effects on central nervous system-derived neurons and glia (3, 5, 35, 41, 48, 50). The intense staining in the peripheral nervous system contrasts with the low staining of paravertebral ganglionic cells. Several investigators have demonstrated that basic FGF enhances peripheral nerve regeneration and that it promotes the survival, axonal bridging, and remodeling of transected nerve stumps (references 11, 18, 36, 51; Cuevas, P., F. Carceller, A. Baird, and R. Guillemin, unpublished results; Cuevas, P., F. Carceller, A. Esteban, A.

Baird, and R. Guillemin, unpublished results). It is obviously difficult to specify the actual intra- or extracellular location of basic FGF without a further analysis using double staining and/or immunoelectron microscopy. The results at 18 d of gestation are clearly compatible with a trophic function for endogenous basic FGF and may explain, at least in part, the regenerative capacity of this tissue. Further studies at different stages of development are in progress and will help to elucidate the role of basic FGF in the morphogenesis of central and peripheral nervous systems.

The localization of basic FGF in the adrenal cortex, in the Leydig cells of the developing testes, and in the stroma of the ovary is compatible with its reported effects on cells derived from the adrenal (20, 28), testis (15), and ovary.<sup>2</sup> It was, thus, of particular interest to note that the basic FGF that has been localized in the adrenal is not associated with the cap-





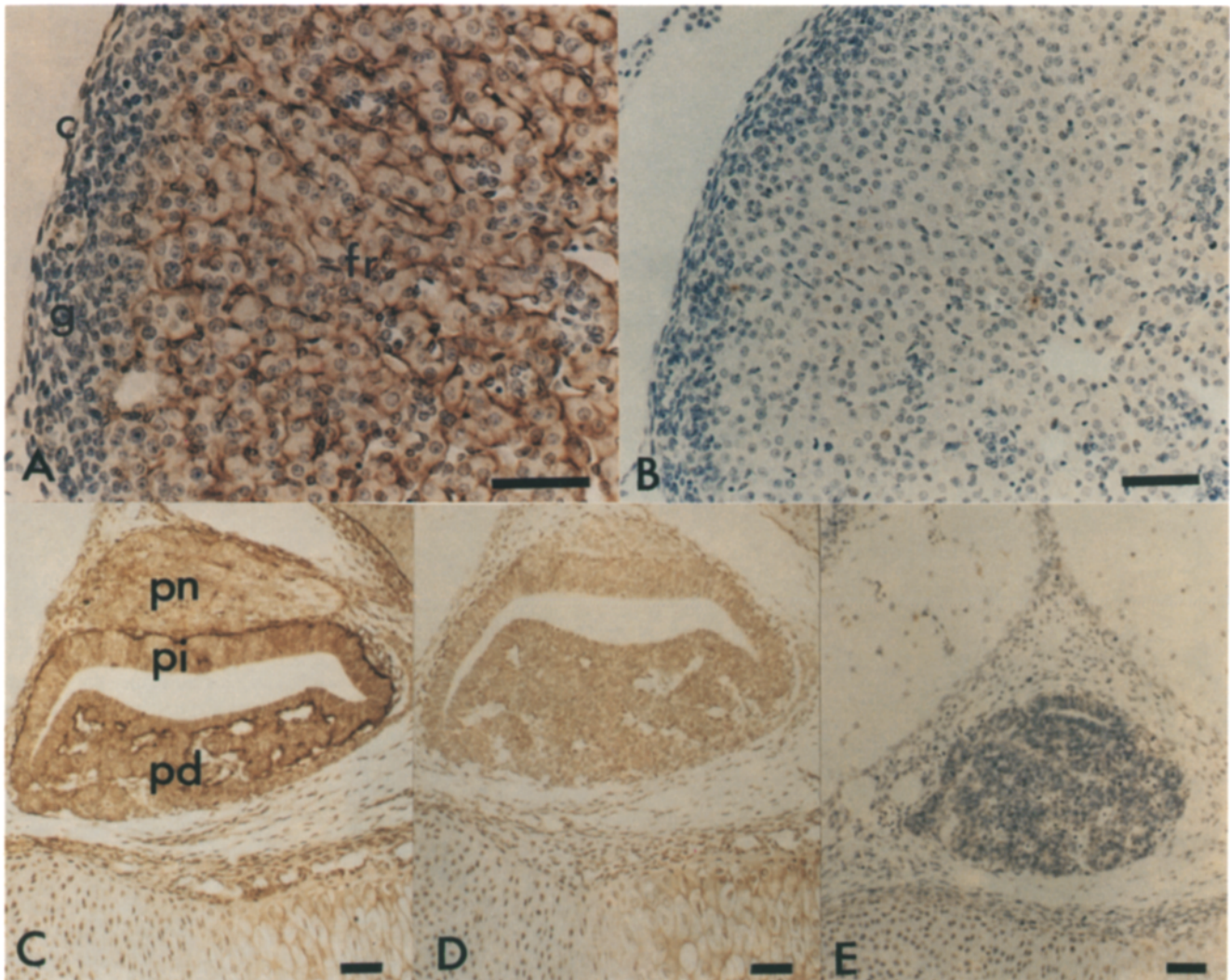
**Figure 7.** Localization of basic FGF in gonads. (A and B) In the testis, Leydig cells (arrows) and the basement membrane are strongly positive; the interstitium and tunica albuginea show moderate positive staining. At higher magnification (B), the absence of staining over the sex cords and the moderate staining over the non-differentiated fibrocyte-like cells of the interstitium is clear. There is also intense staining over the basement membrane (arrows) and of the peritubular cells. A similar pattern of staining is observed in the ovary where the stroma and the basement membrane are strongly positive when observed at low (C) and high (D) magnification. Interstitium (i), stroma (s), sex cords (sc), tunica albuginea (a), basement membrane (arrowheads), and Leydig cells (arrows) are indicated. Bars, 100  $\mu$ m.

sule and glomerulosa zone of the cortex, which are the active sites of cell proliferation and aldosterone production, respectively, but with its target cells, the cells of the zona fasciculata and reticularis which produce corticosterone. However, just as the basic FGF stored in the basement membrane of the sex cords may play a role in the regulation of germ cell proliferation (and as such, participate in sexual differentiation), further studies are required to confirm the physiological function of basic FGF in endocrine tissues. In particular, it will be important to establish the distribution of basic FGF in adult tissues. Clearly, however, its wide distribution is consistent with the notion that basic FGF is a pluripotent, multifunctional factor. As such its activities in each tissue are most likely autonomous and restricted to the local environment.

Several lines of evidence suggest that growth factors and

in particular the acidic and basic FGFs are involved in the regulation of growth and differentiation of mammalian embryos (30, 32, 46). Growth factors are mitogenic for a wide range of stem cell types, and they can induce differentiation in various cells, including many embryonic cells in vitro. Extracts of rat embryos can stimulate fibroblast proliferation in vitro in a manner similar to that of purified basic FGF (27). Moreover, recent evidence has established that FGFs are transiently expressed in the kidneys of mouse embryos (39), and are detectable in the fetal brain (40) and in the developing chick embryo (33, 43). In this latter instance, immunohistochemical studies have localized basic FGF in the muscle of the developing chick (29). Basic FGF has also been detected, isolated, and recently characterized from the human placenta (22, 47), and specific antisera can inhibit fertility of rats and rabbits (Baird, A., M. Ong, and A. M. Gonzalez,





**Figure 8.** Staining of basic FGF in the adrenal and pituitary gland. The positive staining for basic FGF in the fetal adrenal (A) is restricted to the fasciculata and reticularis layers of cells. The zona glomerulosa and the adrenal capsule are completely negative. As shown in B, no staining of the adrenal is observed using the preparation depleted of anti-basic FGF by affinity chromatography. *c*, capsule; *g*, zona glomerulosa; *fr*, zona fasciculata-reticularis. In the pituitary (C), there is a strong staining in the basement membrane surrounding the endocrine cells. Some cells of the anterior pituitary are also positive. When the sections are preincubated with buffer containing 2 M NaCl (D), the extracellular staining disappears. No staining is observed with the affinity-depleted preparation (E). Pars distalis (*pd*), pars intermedia (*pi*), and pars nervosa (*pn*) are indicated. Bars: (A and B) 100  $\mu$ m; (C-E) 50  $\mu$ m.

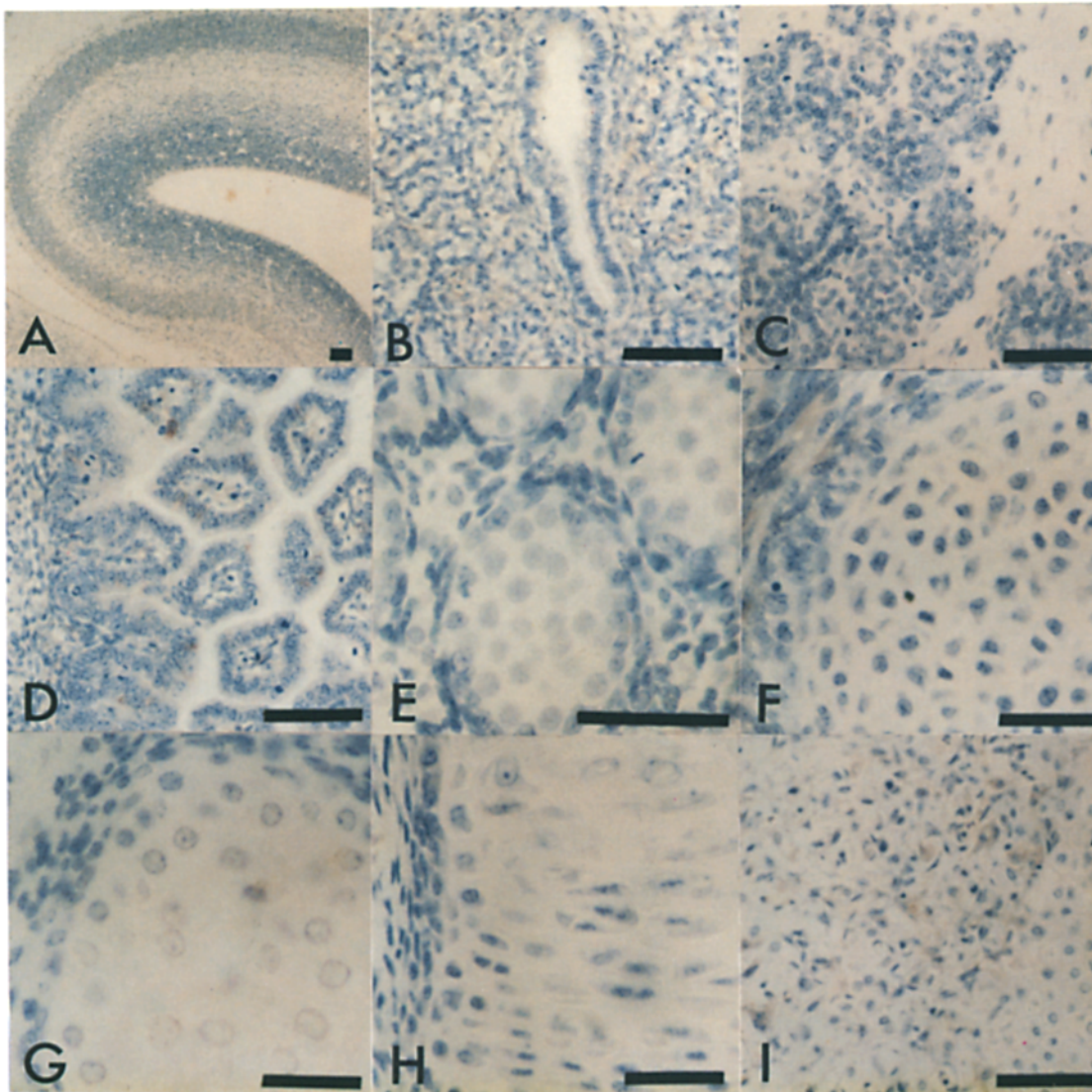
unpublished observations). The observation that basic FGF stimulates the growth of transplanted rat embryos, whereas a specific antibody raised against basic FGF induces growth retardation and underdevelopment of all tissues of endodermal and mesodermal origin, strongly supports a role for basic FGF in fetal development (32).

There is also strong evidence that basic FGF promotes growth and/or affects differentiation in adult vertebrates. FGFs are powerful angiogenic factors found in normal and tumor tissues (16). They promote wound healing in rodents, and lens and limb regeneration in amphibians (references 18, 37, 42; Cuevas, P., F. Carceller, A. Esteban, A. Baird, and R. Guillemin, unpublished observations). The fact that basic FGF is present at the level of the basement membrane in the fetus (as shown here) suggests that it is released from the cell and stored in this structure during development. Whether or

not it is this same basic FGF that is later localized in the adult matrix (12) remains to be established. Because basic FGF exhibits a very high affinity for heparin *in vitro*, this localization of basic FGF is not surprising when one considers the presence of heparan sulfated proteoglycans in many extracellular matrices.

The mechanism through which basic FGF gets outside the cells is not known for it lacks a classical signal sequence to mediate secretion (1, 2, 44). During development, the basement membrane and other structures in the extracellular matrix undergo very extensive remodeling and, as such, during this time basic FGF could be locally released. By virtue of its association with the extracellular matrix, basic FGF may participate in regulating tissue growth and differentiation. This could suggest that the extracellular matrix is regulating FGF activity (4, 5, 17). In the adult, basic FGF stored in this





**Figure 9.** Specificity of basic FGF staining. Tissue sections were incubated as described in Materials and Methods with an IgG preparation that was depleted of anti-basic FGF antibodies using Affigel 10–basic FGF. In sections of (A) brain, (B) lung, (C) salivary gland, (D) gut, (E) testis, and (F–I) cartilage, there is an absence of staining. In the latter instance, there is no staining in (F) hyaline cartilage, (G) matrix and hypertrophic chondrocytes, (H) ossification centers and (I) during matrix calcification and regression of chondrocytes. Bars, 50  $\mu\text{m}$ .

structure could then be released to participate in tissue repair, and maintenance of differentiated function.

The polyclonal antibody used in this study was raised against a 1–24 synthetic fragment of bovine basic FGF(1–146), thus decreasing the possibility of cross-reactivity with other members of the basic FGF family. This antiserum reacts with human basic FGF and shows a 10% cross-reactivity with rat basic FGF, but >0.1% cross-reactivity with acidic FGF (data not shown). Because the sequences of many of the rat-derived proteins are not known and with the large number of members of the FGF family, we cannot exclude the possibility that the staining pattern is exclusively related to basic FGF. Western blotting analysis has shown that this antibody recognizes all of the molecular forms of rat basic FGF that have been identified so far (not shown). It is important to note that the staining pattern that is reported here has

also been seen with an antibody raised against intact recombinant basic FGF. Furthermore, the pattern of staining with other antisera, such as antifibronectin and anti-transforming growth factors  $\beta 1$  and 2 (TGF $\beta 1$  and 2), is quite different (not shown).

The present study, while descriptive, clearly identifies basic FGF in many cellular structures. The results do not rule out the possibility of interaction of basic FGF with other growth factors in developmental processes. As an example, Kimelman and Kirschner (30) have shown that TGF $\beta$  can modulate the effect of basic FGF during development. Clearly, it will be important to compare the findings reported here to the distribution of other growth factors during fetal development. To this end, the localization of TGF $\beta 1$  in the mouse embryo was recently described (26), and it is interesting to note that in spite of the fact that many mesoderm-derived tis-

sues contain TGF $\beta$ 1, the precise pattern of distribution is significantly different from that of basic FGF. As an example, TGF $\beta$ , while extracellular, is not localized in the basement membrane. Because embryonic development most likely relies on local time and concentration-dependent effects of growth factors, comparative analyses of growth factor distribution will require an assessment of their cellular localization, quantitation, and time course of expression. The results presented here establish the presence of basic FGF adjacent to cells that *in vitro* and *in vivo* studies predicted were the target of its potential physiological function. It remains necessary to establish, however, that basic FGF actually plays a physiological function at each of these sites.

The authors thank Drs. Roger Guillemin, David Schubert, Alberto Hayek, and Pamela Maher for critical review of the manuscript.

This research was supported by grants from the National Institutes of Health (DK-1811 and HD-09690) and the Whittier Institute Angiogenesis Research Program.

Received for publication 18 July 1989 and in revised form 1 September 1989.

### References

- Abraham, J. A., A. Mergia, J. L. Whang, A. Tumolo, J. Friedman, K. A. Hjerfield, D. Gospodarowicz, and J. C. Fiddes. 1986. Nucleotide sequence of a bovine clone encoding the angiogenic protein, basic fibroblast growth factor. *Science (Wash. DC)*. 233:545-548.
- Abraham, J. A., J. L. Whang, A. Tumolo, A. Mergia, J. Friedman, D. Gospodarowicz, and J. C. Fiddes. 1986. Human basic fibroblast growth factor: nucleotide sequence and genomic organization. *EMBO (Eur. Mol. Biol. Organ.) J.* 5:2523-2528.
- Anderson, K. J., D. Dam, S. Lee, and C. W. Cotman. 1988. Basic fibroblast growth factor prevents death of lesioned cholinergic neurons *in vivo*. *Nature (Lond.)*. 332:360-361.
- Baird, A., and N. Ling. 1987. Fibroblast growth factors are present in the extracellular matrix produced by endothelial cells *in vitro*: implication for a role of heparinase-like enzymes in the neovascular response. *Biochem. Biophys. Res. Commun.* 142:428-435.
- Baird, A., and P. A. Walicke. 1989. Fibroblast growth factors. *Brit. Med. J.* 45:438-452.
- Baird, A., F. Esch, P. Mormède, N. Ueno, N. Ling, P. Böhlen, S. Y. Ying, W. Wehrenberg, and R. Guillemin. 1986. Molecular characterization of fibroblast growth factor: distribution and biological activities in various tissues. *Recent Prog. Horm. Res.* 42:143-205.
- Baird, A., N. Ueno, F. Esch, and N. Ling. 1989. Distribution of fibroblast growth factors (FGFs) in tissues and structure-function studies with synthetic fragments of basic FGF. *J. Cell. Physiol.* 5(Suppl.):101-106.
- Barr, P. J., L. S. Cousins, C. T. Lee-Ng, A. Medina-Selby, F. R. Masiarz, R. A. Hallewell, S. Chamberlain, J. Bradley, D. Lee, K. S. Steimer, L. Poulter, A. L. Burlingame, F. Esch, and A. Baird. 1988. Expression and processing of biologically active fibroblast growth factors in the yeast *Saccharomyces cerevisiae*. *J. Biol. Chem.* 263:16471-16478.
- Böhlen, P., F. Esch, A. Baird, K. L. Jones, and D. Gospodarowicz. 1985. Human brain fibroblast growth factor: isolation and partial chemical characterization. *FEBS (Fed. Eur. Biochem. Soc.) Lett.* 185:177-181.
- Clegg, C. H., T. A. Linkhart, B. B. Olwin, and S. D. Hauschka. 1987. Growth factor control of skeletal muscle differentiation: commitment to terminal differentiation occurs in G1 phase and is repressed by fibroblast growth factor. *J. Cell Biol.* 105:949-956.
- Danielsen, N., B. Pettmann, H. L. Vahlsing, M. Manthorpe, and S. Varon. 1988. Fibroblast growth factor effects on peripheral nerve regeneration in a silicone chamber model. *J. Neurosci. Res.* 20:320-330.
- DiMario, J., N. Buffinger, S. Yamada, and R. C. Strohmman. 1989. Fibroblast growth factor in the extracellular matrix of dystrophic (mdx) mouse muscle. *Science (Wash. DC)*. 244:688-690.
- Emoto, N., A. M. Gonzalez, P. A. Walicke, E. Wada, D. M. Simmons, S. Shimasaki, and A. Baird. 1989. Identification of specific loci of basic fibroblast growth factor synthesis in the rat brain. *Growth Factors*. In press.
- Esch, F., A. Baird, N. Ling, N. Ueno, F. Hill, L. Denoroy, R. Klepper, D. Gospodarowicz, P. Böhlen, and R. Guillemin. 1985. Primary structure of bovine pituitary basic fibroblast growth factor (FGF) and comparison with the amino-terminal sequence of bovine acidic FGF. *Proc. Natl. Acad. Sci. USA*. 82:6507-6511.
- Fausser, B. C. J. M., A. Baird, and A. J. W. Hsueh. 1988. Fibroblast growth factor inhibits luteinizing hormone-stimulated androgen production by cultured rat testicular cells. *Endocrinology*. 123:2935-2941.
- Folkman, J., and M. Klagsbrun. 1987. Angiogenic factors. *Science (Wash. DC)*. 235:442-447.
- Folkman, J., M. Klagsbrun, J. Sasse, M. G. Wadzinski, D. Ingber, and I. Vlodavsky. 1988. A heparin-binding angiogenic protein—basic fibroblast growth factor—is stored within basement membrane. *Amer. J. Pathol.* 130:393-400.
- Fredj-Reygrobelle, D., J. Plouet, T. Delayre, C. Baudoin, F. Bourret, and P. Lapalus. 1987. Effects of aFGF and bFGF on wound healing in rabbit corneas. *Curr. Eye Res.* 6:1025-1029.
- Globus, R. K., P. Patterson-Buckendahl, and D. Gospodarowicz. 1988. Regulation of bovine bone cell proliferation by fibroblast growth factor and transforming growth factor  $\beta$ . *Endocrinology*. 123:98-105.
- Gospodarowicz, D., C. R. III, P. J., Hornsby, and G. Gill. 1977. Control of bovine adrenal cortical cell proliferation by fibroblast growth factor: lack of effect of epidermal growth factor. *Endocrinology*. 100:1080-1089.
- Gospodarowicz, D., J. Cheng, G. M. Lui, A. Baird, F. Esch, and P. Böhlen. 1985. Corpus luteum angiogenic factor is related to fibroblast growth factor. *Endocrinology*. 117:2383-2391.
- Gospodarowicz, D., J. Cheng, G. M. Lui, D. K. Fujii, A. Baird, and P. Böhlen. 1985. Fibroblast growth factor in the human placenta. *Biochem. Biophys. Res. Commun.* 128:554-562.
- Gospodarowicz, D., G. Neufeld, and L. Schweigerer. 1986. Fibroblast growth factor. *Mol. Cell. Endocrinol.* 46:187-204.
- Gospodarowicz, D., N. Ferrara, L. Schweigerer, and G. Neufeld. 1987. Structural characterization and biological functions of fibroblast growth factor. *Endocr. Rev.* 8(2):95-114.
- Hauschka, P. V., A. E. Mavrakos, M. D. Iafrazi, S. Doleman, and M. Klagsbrun. 1986. Growth factors in bone matrix: isolation of multiple types by affinity chromatography on heparin-Sepharose. *J. Biol. Chem.* 261:12665-12674.
- Heine, U. I., E. F. Munoz, K. C. Flanders, L. R. Ellingsworth, H. Y. P. Lam, N. L. Thompson, A. B. Roberts, and M. B. Sporn. 1987. Role of transforming growth factor-beta in the development of the mouse embryo. *J. Cell Biol.* 105:2861-2876.
- Hoffman, R. S. 1940. The growth-activating effect of extracts of adult and embryonic tissues of the rat on fibroblast colonies in culture. *Growth*. 4:361-376.
- Hornsby, P. J., and G. N. Gill. 1977. Hormonal control of adrenocortical cell proliferation: desensitization to ACTH and interaction between ACTH and fibroblast growth factor in bovine adrenocortical cell cultures. *J. Clin. Invest.* 60:342-354.
- Joseph-Silverstein, J., S. A. Consigli, K. M. Lyser, and C. Ver Pault. 1989. Basic Fibroblast Growth Factor in the chick embryo: Immunolocalization to Striated Muscle Cells and their Precursors. *J. Cell Biol.* 108:2459-2466.
- Kimelman, D., and M. Kirschner. 1987. Synergistic induction of mesoderm by FGF and TGF-beta and the identification of an mRNA coding for FGF in the early *Xenopus* embryo. *Cell*. 51:869-877.
- Kimelman, D., J. A. Abraham, T. Haaparanta, T. M. Palisi, and M. W. Kirschner. 1988. The presence of fibroblast growth factor in the frog egg: its role as a natural mesoderm inducer. *Science (Wash. DC)*. 242:1053-1056.
- Liu, L., and C. S. Nicoll. 1988. Evidence for a role of basic fibroblast growth factor in rat embryonic growth and differentiation. *Endocrinology*. 123:2027-2031.
- Mascarelli, F., D. Raulais, M. F. Counis, and Y. Courtois. 1987. Characterization of acidic and basic fibroblast growth factors in brain, retina and vitreous chick embryo. *Biochem. Biophys. Res. Commun.* 146:478-486.
- Mergia, A., R. Eddy, J. A. Abraham, J. C. Fiddes, and T. B. Shows. 1986. The genes for basic and acidic fibroblast growth factors are on different human chromosomes. *Biochem. Biophys. Res. Commun.* 138:644-651.
- Morrison, R. S., A. Sharma, J. DeVellis, and R. A. Bradshaw. 1986. Basic fibroblast growth factor supports the survival of cerebral cortical neurons in primary culture. *Proc. Natl. Acad. Sci. USA*. 83:7537-7541.
- Otto, D., K. Unsicker, and C. Grothe. 1987. Pharmacological effects of nerve growth factor and fibroblast growth factor applied to the transected sciatic nerve on neuron death in adult rat dorsal root ganglia. *Neurosci. Lett.* 83:156-160.
- Petroutsos, G., J. Courty, R. Guimaraes, Y. Pouliquen, D. Barrault, J. Plouet, and Y. Courtois. 1984. Comparison of the effects of EGF, bFGF, and EDGF on corneal epithelium wound healing. *Curr. Eye Res.* 3:593-598.
- Risau, W. 1986. Developing brain produces an angiogenesis factor. *Proc. Natl. Acad. Sci. USA*. 83:3855-3859.
- Risau, W., and P. Eklom. 1986. Production of a heparin-binding angiogenesis factor by the embryonic kidney. *J. Cell Biol.* 103:1101-1107.
- Risau, W., P. Gautschi-Sova, and P. Böhlen. 1988. Endothelial cell growth factors in embryonic and adult chick brain are related to human acidic fibroblast growth factor. *EMBO (Eur. Mol. Biol. Organ.) J.* 7:959-962.
- Schubert, D., N. Ling, and A. Baird. 1987. Multiple influences of a heparin-binding growth factor on neuronal development. *J. Cell Biol.* 104:635-643.
- Schweigerer, L. 1988. Basic fibroblast growth factor as a wound healing



- hormone. *Trends Physiol. Sci.* 9:427-428.
43. Seed, J., B. B. Olwin, and S. D. Hauschka. 1988. Fibroblast growth factor levels in the whole embryo and limb bud during chick development. *Dev. Biol.* 128:50-57.
  44. Shimasaki, S., N. Emoto, A. Koba, M. Mercado, F. Shibata, K. Cooksey, A. Baird, and N. Ling. 1988. Complementary DNA cloning and sequencing of rat ovarian basic fibroblast growth factor and tissue distribution study of its mRNA. *Biochem. Biophys. Res. Commun.* 157:256-263.
  45. Simpson, R. J., R. L. Moritz, C. J. Lloyd, L. J. Fabri, E. C. Nice, M. R. Rubira, and A. W. Burgess. 1987. Primary structure of ovine pituitary basic fibroblast growth factor. *FEBS (Fed. Eur. Biochem. Soc.) Lett.* 224:128-132.
  46. Slack, J., B. Darlington, H. Heath, and S. Godsave. 1987. Mesoderm induction in early *Xenopus* embryos by heparin-binding growth factors. *Nature (Lond.)* 326:197-200.
  47. Sommer, A., M. T. Brewer, R. C. Thompson, D. Moscatelli, M. Presta, and D. B. Rifkin. 1987. A form of human basic fibroblast growth factor with an extended amino terminus. *Biochem. Biophys. Res. Commun.* 144:543-550.
  48. Unsicker, K., H. Reichert-Preibsch, R. Schmidt, B. Pettmann, G. Labourdette, and M. Sensenbrenner. 1987. Astroglial and fibroblast growth factors have neurotrophic functions for cultured peripheral and central nervous system neurons. *Proc. Natl. Acad. Sci. USA.* 84:5459-5463.
  49. Vlodavsky, I., J. Folkman, R. Sullivan, R. Fridman, R. Ishai-Michaeli, J. Sasse, and M. Klagsbrun. 1987. Endothelial cell-derived basic fibroblast growth factor: synthesis and deposition into subendothelial extracellular matrix. *Proc. Natl. Acad. Sci. USA.* 84:2292-2296.
  50. Walicke, P., W. M. Cowan, N. Ueno, A. Baird, and R. Guillemin. 1986. Fibroblast growth factor promotes survival of dissociated hippocampal neurons and enhances neurite extension. *Proc. Natl. Acad. Sci. USA.* 83:3012-3016.
  51. Weibel, M., B. Pettmann, G. Labourdette, M. Miehle, E. Bock, and M. Sensenbrenner. 1985. Morphological and biochemical maturation of rat astroglial growth factor. *Int. J. Dev. Neurosci.* 3:617-630.