

Giant cell myositis and myocarditis revisited

Piraye Oflazer

Department of Neurology, Koç University Hospital Muscle Center, Koç University Medical Faculty, Topkapı, Istanbul, Turkey

Giant cell myositis (GCMm) and giant cell myocarditis (GCMc) are two rare auto-immune conditions. Among these, GCMc is a life-threatening disease with a 1-year mortality rate of 70%. Lethal ventricular arrhythmias, rapid evolution to heart failure and sudden death risk makes GCMc an emergency condition. It is thought to be mediated by T-cells and characterized by the presence of myofiber necrosis and giant cells in biopsies. Most commonly co-manifesting conditions with GCMm and/or GCMc are thymoma, myasthenia gravis and orbital myositis, all of which are treatable. As suspicion is the key approach in diagnosis, the physician following patients with thymoma with or without myasthenia gravis and with orbital myositis should always be alert. The fatal nature of GCMc associated with these relatively benign diseases deserves a special emergency attention with prompt institution of combined immunosuppressive treatment and very early inclusion of heart failure teams.

Key words: giant cell myositis, giant cell myocarditis, thymoma/myasthenia gravis, orbital myositis

Giant cell myositis/giant cell myocarditis

Giant cell myositis and myocarditis, diseases of skeletal and cardiac muscles are both abbreviated as GCM. As both conditions are the subjects of this report abbreviations will be GCMmuscle (GCMm) for giant cell myositis and GCMcardiac (GCMc) for giant cell myocarditis.

Myositis with giant cells is a rare but treatable acquired inflammatory disease of the skeletal muscle. As cardiac involvement rapidly leads to lethal ventricular arrhythmias, heart failure or sudden death, combination of GCMm with GCMc can develop into a fulminant and fatal condition. Without any treatment, the 1-year mortality approaches 70% when GCMc takes the stage ¹. Diagnosing and differentiating the entity from other more frequent cardiomyopathies and inflammatory myopathies depend on demonstrating the presence of a non-granuloma forming, diffuse giant cells in biopsy specimens ². Therefore, if not suspected it is arduous to make a prompt and accurate diagnosis. Furthermore, the importance lies in its recognition not only by cardiologists but also by other disciplines such as neurologists, rheumatologists, and ophthalmologists for rapid involvement of necessary emergency teams to start an aggressive treatment ³.

First description of GCM cases was on fatal idiopathic GCMc and was made by Saltykow in 1905 ⁴. The main pathological findings in this report were widespread inflammation and myocyte necrosis with abundant giant cells. The condition was considered in tandem with sarcoidosis until the 1950s when received recognition as a separate entity with the diffuse nature of inflammation and necrosis versus granuloma and fibrosis formation in sarcoidosis (Veia A, 2014). From 1905 to 1980s, all reported GCMc

Received: October 15, 2020
Accepted: October 15, 2020

Correspondence

Piraye Oflazer

Department of Neurology, Koç University Hospital Muscle Center, Koç University Medical Faculty, Davutpaşa Cad 4, Topkapı, Istanbul, Turkey. Tel.: +90 850 2508250
E-mail: poflazer@ku.edu.tr

Conflict of interest

The Author declares no conflict of interest

How to cite this article: Oflazer P. Giant cell myositis and myocarditis revisited. Acta Myol 2020;39:302-6. <https://doi.org/10.36185/2532-1900-033>

© Gaetano Conte Academy - Mediterranean Society of Myology



OPEN ACCESS

This is an open access article distributed in accordance with the CC-BY-NC-ND (Creative Commons Attribution-NonCommercial-NoDerivatives 4.0 International) license. The article can be used by giving appropriate credit and mentioning the license, but only for non-commercial purposes and only in the original version. For further information: <https://creativecommons.org/licenses/by-nc-nd/4.0/deed.en>

cases were diagnosed at autopsy ¹. The development of diagnostic tools such as endomyocardial biopsy (single or repeated), imaging-guided endomyocardial biopsy, apical wedge-sectioning during placement of ventricular assist devices, cardiac gadolinium-enhanced MRI, FDG-PET, has allowed diagnosis and treatment in living patients only after mid 1980s, prolonging transplant-free survival and life expectancy ^{5,6}. Tissue histopathology is still the gold standard of diagnosis and almost all studies on the inflammation of muscle tissue with giant cells is performed in GCMc. Due to the rarity of the condition, a multi-center Giant Cell Myocarditis Registry was established in the early 1990s in the United States ⁷.

The first description of GCMm was appended to GCMc and appeared in the report of Giordano and Haymond in 1944. This patient also manifested thymoma and myasthenia gravis ⁸⁻¹⁰. From 1944 to 1974, only 10 patients with idiopathic GCMm were found to be reported in the literature with additional 3 patients with GCMc. All the reported GCMc patients were associated with thymoma ¹¹. As GCMc is a more serious manifestation of the GCMm/GCMc, the combination and diagnosis is established by myocardial histopathology and there is usually no time to evaluate any skeletal muscle pathology unless the patient presents relative symptoms. Thus, as it is not known how much latent GCMc patients also have GCMm it could be way more common than reported ¹³. On the other hand, there are also patients with GCMm without GCMc ^{14,15}.

GCMc is a very rare condition that affects otherwise healthy young adults. Incidence rate is 0.007% in Japan and 0.051% in India ¹⁶. Review of 377,841 autopsies over a 20-year period found myocarditis in 0.11% but giant cell myocarditis in only 0.007% of the cases ¹⁷. Considering that patients passed away before reaching the hospital, this incidence rate might even be higher.

GCMc can be idiopathic or occur in various conditions, such as infection (tuberculosis, syphilis, pneumocystis jirovecii parvovirus, coxsackie), inflammation, drug sensitivity, hypersensitivity and vasculitis ⁷. At least one group of the condition is considered as an autoimmune disease in 19% of patients in some registries that co-manifest with other autoimmune diseases such as inflammatory bowel disease, cryofibrinogenemia, optic neuritis, Hashimoto thyroiditis, rheumatoid arthritis, Takayasu arteritis, temporal arteritis, myasthenia gravis (MG), alopecia totalis, vitiligo, orbital myositis, autoimmune hepatitis, Guillain-Barré syndrome, systemic lupus erythematosus, Sjögren's and pernicious anemia ¹⁶. Furthermore, the inducibility of a similar idiopathic myocarditis in Lewis rats by cardiac myosin strongly suggests that GCMm and GCMc are both autoimmune conditions ^{16,18}. Combined immunosuppression retards the progression

of the disease and results in a partial remission both in humans and experimental rat models. This fact, together with the up-regulation of genes involved in T-cell response are other evidences of autoimmunity ⁷. Tumors of the immune cells such as thymoma and lymphoma – thymoma being the most common – are the main tumours accompanying GCMm and GCMc, either separately or in combination ⁷. Considering that other autoimmune diseases also accompany thymoma, this feature also suggests autoimmune or dysimmune mechanisms in GCMm/GCMc. When looked at from GCMm point of view, almost – if not all- cases reported are present in patients with myasthenia gravis with or without thymoma.

Although clinically presents similar to other myocarditis conditions GCMc is more severe and has a unique pathology ¹¹. Histopathological hallmark of GCMm or GCMc adheres to the presence of diffuse inflammation including giant cells without well-formed granuloma formation. Muscle fiber destruction in the muscle biopsy specimens from heart and skeletal muscles, CD8(+) lymphocytes, plasma cells and eosinophils all accompany giant cells at different proportions ^{2,16}. Giant cells generally embrace necrosis areas diffusely but they don't form granulomas. Origin of these giant cells are reported to be histiocytic and/or myogenic. It was immunohistochemically demonstrated in one patient that myogenic giant cells express increased lysosome-proteasome system (cathepsins A, B and D) and late endosomal system (LAMP-2) proteins, whereas histiocytic giant cells express only lysosome-protein system proteins (cathepsins A, B, D, L and S) but not the late endosomal marker LAMP-2. They were both negative for ubiquitin-proteasome system, autophagosome and aggregates systems ¹⁹. Thus, it is assumed that the digestion of the same endocytotic material by more than one macrophage engenders these macrophages to fuse and form a giant cell ¹⁹.

GCMm/GCMc and thymoma

Approximately 1% of patients with thymoma exhibit GCMc and/or GCMm ^{10,20}. Being an autoantigen expressing tumor which results in production of antibodies mainly against muscle and nerve tissues such as acetylcholine receptors (AChR), voltage gated calcium channels (VGCC), voltage gated potassium channels (VGKC/Kv1.4), and striational proteins called ryanodine (RyR) and titin, thymoma is the most common tumor associated with GCMc or GCMm ²¹. These antibodies are either clinically silent or they cause MG, myositis, neuro-myotonia, encephalitis, autonomic neuropathy, subacute hearing loss and even encephalitis ²². Most of the cases with co-manifestation of thymoma and GCMm and/or GCMc bear Kv1.4, RyR and/or titin antibodies ¹⁹. The defective immunity found in patients with thymoma is thought to

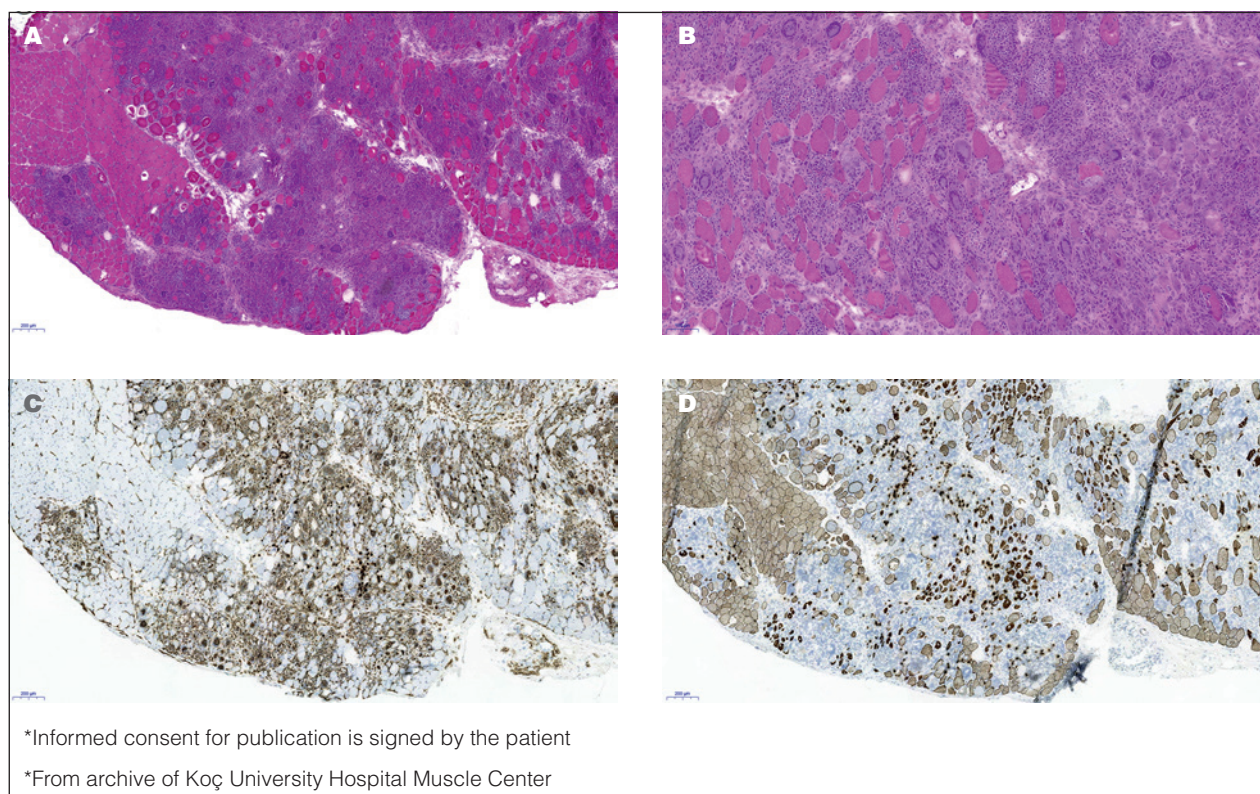


Figure 1. Muscle biopsy of a 58-year old patient with GCMm, who had been followed up for AChR and Titin antibodies positive generalized MG under corticosteroid therapy. He also had had metastatic colon cancer and received anti-VEGF therapy 1 year before the development of GCMm. He did not develop GCMc and the GCMm was controlled by increasing the corticosteroid dose. A) H&E (320x): diffuse myonecrosis with inflammatory cells including many giant cells; B) H&E (640x): abundance of giant cells; C) CD68 positive macrophages (320x): macrophages diffusely invade the necrosis area. Giant cells are also positive for macrophage marker CD68; D) Desmin (320x): only the normal areas and redundant, atrophic myofibers are positive for desmin.

play a role in a giant cell immune reaction against heart and skeletal tissues (Fig. 1) ¹⁰.

GCMm/GCMc and MG (with or without thymoma)

Although rare, presence of polymyositis with lymphocytic inflammation in autoimmune myasthenia with or without thymoma has been a well-known entity. Myositis-MG combination has gained more importance lately due to the employment of immune checkpoint inhibitors (ICI) in cancer therapy with widespread uncontrolled T-cell response attacking different tissues ^{23,24}. Myocarditis is also discernible in ICI myositis and may co-manifest with skeletal myositis and myasthenia gravis ²⁰. However, the description of GCMm, GCMc or the combination of them in patients with MG with or without thymoma is an extremely rare but a more important situation as GCMm has a very rapid course and fatal outcome ²². In the report of Evoli, among 50/207 patients 3 of whom died without any previous cardiac disease, had sudden death, giving

the suspicion that they may have held GCMc ²⁵. Uchio et al reported 8/889 (9%) myositis cases with MG, only one of them had GCMm ²⁶.

Case reports on GCMm are almost exclusively in myasthenic and/or thymomatous patients, whereas only some of GCMc cases do occur in the same patient population ²². Therefore, idiopathic GCMc cases without an autoimmune etiology do exist and these cases are much more frequent (around 80%) than the autoimmune disease related group (19%) ¹⁵. In general patients with MG and myositis are more likely to express striational antibodies Titin, RyR, Kv1.4. This is the same for GCMm or GCMc in myasthenic patients that express Kv1.4, titin or RyR antibodies ^{19,27}. Heart and skeletal muscles may be the autoimmune targets in some patients with MG ²⁷.

GCMm/GCMc and orbital myositis

Orbital myositis is a self limited condition under immunosuppressive treatment. This self-limited disease be-

comes life-threatening when co-manifests with GCMc. Presence of GCMc in orbital myositis was first described in 1989 by Klein BR²⁹. In this report, authors suggested that this combination could be regarded as a separate entity²⁹. To date, less than 10 cases of GCMc and/or GCMm with orbital myositis are reported, most of which have died due to cardiac involvement^{3,29-34}. It has also been described in a pediatric patient³³. In all reported cases cardiac disease manifested later in the course with a time lapse of days, months or even years³⁴. Therefore, the possible development of GCMc and/or GCMm should be kept in mind in the follow-up of patients with orbital myositis^{34,35}.

Management of GCMm and GCMc

Immunosuppressive treatment either with corticosteroids or in combination with others is sufficient for GCMm only, like in other inflammatory myopathies, and it responds well. Long term maintenance therapy is necessary to prevent relapses and also for its potential to develop GCMc. However, the potential of developing GCMc in the course of GCMm is a factor that alerts the physician than in other inflammatory myopathies. Therefore, it is of vital importance to start an immunosuppressive treatment immediately upon suspicion or diagnosis and include cardiology discipline for supportive therapy right from the beginning in the follow-up^{22,34}. As GCMm may start simultaneously or before the diagnosis of thymoma or MG and also most GCMc patients carry striational antibodies, every patient with GCMm should be checked for thymoma and thymoma-related striational antibodies. Presentation of GCMm and/or GCMc in all reported orbital myositis cases manifest later in the course of orbital myositis. Therefore, orbital myositis itself should raise the suspicion of potential emanation of GCMm or GCMc.

As mentioned before, most of the research on GCM has been performed in GCMc patients and Lewis rat models. It has been shown that the GCMm transferred to rats were prevented by cyclosporine or anti-T-lymphocyte antibodies but not by corticosteroids alone^{6,9,36-38}. Although there are no controlled large scale trials, due to the positive response in anecdotal cases or small patient groups of this fulminant disease, different combinations of immunosuppression with corticosteroids, azathioprine, cyclosporine-A and anti-T-lymphocyte antibodies are used^{6, 8,11,39}. In a multicentric retrospective study of 63 biopsy- proven GCMc patients showed that the median survival was 3 months in patients who did not receive any immunosuppression, 3,8 months in the ones receiving corticosteroids only, but was 12.6 months in the patients who received cyclosporine with different combinations (corticosteroids, azathioprine, muromonab-CD3)⁸. As fast tapering and cessation of immunosuppression is associated with the recurrence of GCMc even up to 8 years

after the initial diagnosis careful tapering of the drug doses without discontinuation is recommended⁴⁰.

Supportive treatment has vital importance in GCMc. If the diagnosis is prompt or GCMc is suspected in a living patient, left ventricular assist devices, medical therapy of heart failure and timely heart transplantation is life-saving when needed. However, it should be noted that and although the cause is unknown, a transplanted heart may also develop GCMc as well. To avoid this probability, immunosuppression should be maintained in tolerable doses^{6,8,39}.

Conclusions

The consequences of developing GCMc during the course of some neurological diseases which are treatable and have more benign courses such as GCMm, thymoma, MG or orbital myositis are devastating. Neurologists should be alert in prompt diagnosis of the condition and should immediately include cardiology teams into the diagnostic and treatment process.

References

- Cooper LT Jr. Giant cell myocarditis: diagnosis and treatment. *Herz* 2000;25:291-8. <https://doi.org/10.1007/s000590050023>
- Davies MJ, Pomerance A, Teare RD. Idiopathic giant cell myocarditis – a distinctive clinico-pathological entity. *Br Heart J* 1975;37:192-5. <https://doi.org/10.1007/s00059005002310.1136/hrt.37.2.192>
- Garg V, Tan W, Ardehali R, et al. Giant cell myocarditis masquerading as orbital myositis with a rapid, fulminant course necessitating mechanical support and heart transplantation. *ESC Heart Fail* 2017;4:371-5. <https://doi.org/10.1007/s00059005002310.1002/ehf2.12141>
- Saltykow, S. Über diffuse myokarditis. *Virchows Arch Path Anat* 1905;182:1-39. <https://doi.org/10.1007/BF01995636>
- Kandolin R, Lehtonen J, Salmenkivi K, et al. Diagnosis, treatment, and outcome of giant-cell myocarditis in the era of combined immunosuppression. *Circ Heart Fail* 2013;6:15-22. <https://doi.org/1161/CIRCHEARTFAILURE.112.969261>
- Xu J, Brooks EG. Giant cell myocarditis: a brief review. *Arch Pathol Lab Med* 2016;140:1429-34. <https://doi.org/10.1007/s00059005002310.5858/arpa.2016-0068-RS>
- Cooper LT Jr, Berry GJ, Shabetai R. Idiopathic giant-cell myocarditis – natural history and treatment. Multicenter Giant Cell Myocarditis Study Group Investigators. *N Engl J Med* 1997;336:1860-6. <https://doi.org/10.1056/NEJM199706263362603>
- Tanahashi N, Sato H, Nogawa S, et al. A case report of giant cell myocarditis and myositis observed during the clinical course of invasive thymoma associated with myasthenia gravis. *Keio J Med* 2004;53:30-42.
- Sasaki H, Yano M, Kawano O, et al. Thymoma associated with fatal myocarditis and polymyositis in a 58-year-old man following treatment with carboplatin and paclitaxel: a case report. *Oncol Lett* 2012;3:300-2. <https://doi.org/10.3892/ol.2011.501>

- 10 Veia A, Cavallino C, Bacchini S, et al. Idiopathic giant cell myositis: State of the art. *World J Cardiovascular Dis* 2014;4:316-24. <http://dx.doi.org/10.4236/wjcd.2014.4641>
- 11 Namba T, Brunner NG, Grob D. Idiopathic giant cell polymyositis. Report of a case and review of the syndrome. *Arch Neurol* 1974;31:27-30. <https://doi.org/10.1001/archneur.1974.00490370053007>
- 12 Ikarashi K, Uto K, Kawamura S, et al. An autopsy case of giant cell myocarditis showing shared pathology in the myocardium and skeletal muscles. *Cardiovasc Pathol* 2019;42:10-4. <https://doi.org/10.1016/j.carpath.2019.05.003>
- 13 Stefanou MI, Komorowski L, Kade S, et al. A case of late-onset, thymoma-associated myasthenia gravis with ryanodine receptor and titin antibodies and concomitant granulomatous myositis. *BMC Neurol* 2016;16:172. <https://doi.org/10.1186/s12883-016-0697-x>
- 14 Iqbal SM, Burns L, Zhi C. Granulomatous myositis associated with myasthenia gravis: a rare case. *Cureus* 2019;11:e5090. <https://doi.org/10.7759/cureus.5090>
- 15 Shih JA, Shih JA. Small steps for idiopathic giant cell myocarditis. *Curr Heart Fail Rep* 2015;12:263-8. <https://doi.org/10.1007/s11897-015-0260-x>
- 16 Izumi T, Kodama M, Shibata A. Experimental giant cell myocarditis induced by cardiac myosin immunization. *Eur Heart J* 1991;12(Suppl D):166-8. https://doi.org/10.1093/eurheartj/12.suppl_d.166
- 17 Wakafuji S, Okada R. Twenty year autopsy statistics of myocarditis incidence in Japan. *Jpn Circ J* 1986;50:1288-93. <https://doi.org/10.1253/jcj.50.1288>
- 18 Kon T, Mori F, Tanji K, et al. Giant cell polymyositis and myocarditis associated with myasthenia gravis and thymoma. *Neuropathology* 2013;33:281-7. <https://doi.org/10.1111/j.1440-1789.2012.01345.x>
- 19 Suzuki S, Ishikawa N, Konoeda F, et al. Nivolumab-related myasthenia gravis with myositis and myocarditis in Japan. *Neurology* 2017;89:1127-34. <https://doi.org/10.1212/WNL.0000000000004359>
- 20 Bernard C, Frih H, Pasquet F, et al. Thymoma associated with autoimmune diseases: 85 cases and literature review. *Autoimmun Rev* 2016;15:82-92. <https://doi.org/10.1016/j.autrev.2015.09.005>
- 21 Shah A, Pace A, Hilton D, et al. Giant cell myositis responsive to combined corticosteroids and immunoglobulin. *Pract Neurol* 2015;15:456-9. <https://doi.org/10.1136/practneurol-2015-001145>
- 22 Dalakas MC. Neurological complications of immune checkpoint inhibitors: what happens when you 'take the brakes off' the immune system. *Ther Adv Neurol Disord* 2018;11:1756286418799864. <https://doi.org/10.1177/1756286418799864>
- 23 Moreira A, Loquai C, Pöhler C, et al. Myositis and neuromuscular side-effects induced by immune checkpoint inhibitors. *Eur J Cancer* 2019;106:12-23. <https://doi.org/10.1016/j.ejca.2018.09.033>
- 24 Evoli A, Minisci C, Di Schino C, et al. Thymoma in patients with MG: characteristics and long-term outcome. *Neurology* 2002;59:1844-50. <https://doi.org/10.1212/01.wnl.0000032502.89361.0c>
- 25 Uchio N, Taira K, Ikenaga C, et al. Inflammatory myopathy with myasthenia gravis: thymoma association and polymyositis pathology. *Neurol Neuroimmunol Neuroinflamm* 2018;6:e535. <https://doi.org/10.1212/NXI.0000000000000535>
- 26 Suzuki S. Autoantibodies in thymoma-associated myasthenia gravis and their clinical significance. *Brain Nerve* 2011;63:705-12.
- 27 Suzuki S, Utsugisawa K, Yoshikawa H, et al. Autoimmune targets of heart and skeletal muscles in myasthenia gravis. *Arch Neurol* 2009;66:1334-8. <https://doi.org/10.1001/archneurol.2009.229>
- 28 Klein BR, Hedges TR 3rd, Dayal Y, et al. Orbital myositis and giant cell myocarditis. *Neurology* 1989;39:988-90. <https://doi.org/10.1212/wnl.39.7.988>
- 29 Stevens AW, Grossman ME, Barr ML. Orbital myositis, vitiligo, and giant cell myocarditis. *J Am Acad Dermatol* 1996;35:310-2. [https://doi.org/10.1016/s0190-9622\(96\)90656-8](https://doi.org/10.1016/s0190-9622(96)90656-8)
- 30 Selva D, Dolman PJ, Rootman J. Orbital granulomatous giant cell myositis: a case report and review. *Clin Exp Ophthalmol* 2000;28:65-8. <https://doi.org/10.1046/j.1442-9071.2000.00273.x>
- 31 Kollmeier M, Brodhun M, Sliwka U, et al. Doppelbilder und kardiogener Schock. Eine okuläre Myositis assoziiert mit einer Riesenzellmyokarditis [Diplopia and cardiogenic shock]. *Nervenarzt* 2006;77:187-8. <https://doi.org/10.1007/s00115-005-1931-8>
- 32 Lind-Ayres MR, Abramowsky C, Mahle WT. Pediatric giant cell myocarditis and orbital myositis. *Pediatr Cardiol* 2009;30:510-2. <https://doi.org/10.1007/s00246-008-9338-5>
- 33 Ali MS, Mba BI, Husain AN, et al. Giant cell myocarditis: a life-threatening disorder heralded by orbital myositis. *BMJ Case Rep* 2016;2016:bcr2015213759. <https://doi.org/10.1136/bcr-2015-213759>
- 34 Kattah JC, Zimmerman LE, Kolsky MP, et al. Bilateral orbital involvement in fatal giant cell polymyositis. *Ophthalmology* 1990;97:520-5. [https://doi.org/10.1016/s0161-6420\(90\)32554-x](https://doi.org/10.1016/s0161-6420(90)32554-x)
- 35 Zhang S, Kodama M, Hanawa H, et al. Effects of cyclosporine, prednisolone and aspirin on rat autoimmune giant cell myocarditis. *J Am Coll Cardiol* 1993;21:1254-60. [https://doi.org/10.1016/0735-1097\(93\)90254-x](https://doi.org/10.1016/0735-1097(93)90254-x)
- 36 Hanawa H, Kodama M, Inomata T, et al. Anti-alpha beta T cell receptor antibody prevents the progression of experimental autoimmune myocarditis. *Clin Exp Immunol* 1994;96:470-5. <https://doi.org/10.1111/j.1365-2249.1994.tb06053.x>
- 37 Menghini VV, Savcenko V, Olson LJ, et al. Combined immunosuppression for the treatment of idiopathic giant cell myocarditis. *Mayo Clin Proc* 1999;74:1221-6. <https://doi.org/10.4065/74.12.1221>
- 38 Ooka J, Tanaka H, Hatani Y, et al. Treatment of fulminant giant cell myocarditis associated with polymyositis using a left ventricular assist device and subsequent corticosteroid and immunosuppressive therapy leading to remission. *Intern Med* 2017;56:2155-8. <https://doi.org/10.2169/internalmedicine.8639-16>
- 39 Cooper, L.T., Orellana, V., Kuhl, et al. Long term risk of death, transplantation, and disease recurrence in giant cell myocarditis. *J Am College Cardiol* 2012;59:e1547.