

# Stent-Assisted Coil Embolization for Cavernous Carotid Artery Aneurysms

Kenichi KONO,<sup>1</sup> Aki SHINTANI,<sup>1</sup> Hideo OKADA,<sup>1</sup>  
Yuko TANAKA,<sup>1</sup> and Tomoaki TERADA<sup>1</sup>

<sup>1</sup>Department of Neurosurgery, Wakayama Rosai Hospital, Wakayama, Wakayama

## Abstract

Internal carotid artery (ICA) occlusion with or without a bypass surgery is the traditional treatment for cavernous sinus (CS) aneurysms with cranial nerve (CN) dysfunction. Coil embolization without stents frequently requires retreatment because of the large size of CS aneurysms. We report the mid-term results of six unruptured CS aneurysms treated with stent-assisted coil embolization (SACE). The mean age of the patients was 72 years. The mean size of the aneurysms was 19.8 mm (range: 13–26 mm). Before treatment, four patients presented with CN dysfunction and two patients had no symptoms. SACE was performed under local or general anesthesia in three patients each. Mean packing density was 29.1% and tight packing was achieved. There were no neurological complications. CN dysfunction was cured in three patients (75%) and partly resolved in one patient (25%). Transient new CN dysfunction was observed in two patients (33%). Clinical and imaging follow-up ranged from 6 to 26 months (median: 16 months). Recanalization was observed in three patients (50%; neck remnant in two patients and dome filling in one patient), but no retreatment has yet been required. No recurrence of CN dysfunction has occurred yet. In summary, SACE increases packing density and may reduce requirement of retreatment with an acceptable cure rate of CN dysfunction. SACE may be a superior treatment for coiling without stents and be an alternative treatment of ICA occlusion for selected patients, such as older patients and those who require a high-flow bypass surgery or cannot receive general anesthesia.

Key words: cavernous carotid artery aneurysm, cranial nerve dysfunction, internal carotid artery, recanalization, stent-assisted coil embolization

## Introduction

Aneurysms of the cavernous sinus (CS) of the internal carotid artery (ICA) usually have a benign clinical course, with mass effects on cranial nerves (CNs). Rupture commonly leads to carotid cavernous fistula and, rarely, to subarachnoid hemorrhage.<sup>1,2)</sup> Traditional treatment of unruptured aneurysms at this location consists of ICA occlusion, with or without preceding bypass surgery, or coil embolization without stents.<sup>3–7)</sup> ICA occlusion occasionally requires high-flow bypass, which may have a certain risk of peri-procedural complications.<sup>8)</sup> Coil embolization without stents for CS aneurysms frequently requires retreatment because of the large size of aneurysms.<sup>7)</sup> Recently, stent-assisted coil embolization (SACE) has been used for wide-neck or complex aneurysms. However, results of SACE focusing on CS

aneurysms have not yet been reported. This study reports the mid-term results of six CS aneurysms treated with SACE.

## Materials and Methods

Between July 2010 and May 2012, a total of six patients with CS aneurysms were treated with SACE (Tables 1 and 2). The location of the aneurysm was the carotid cavernous sinus in five patients and bifurcation of the ICA and the primitive trigeminal artery in one patient. All of the patients were women, with a mean age of 72 years (range: 59–81 years). All of the aneurysms were unruptured. The mean size of the aneurysms was 19.8 mm (range: 13–26 mm). Two of the six aneurysms were partially thrombosed. CN dysfunction was observed in four patients (Table 1). The remaining two patients were asymptomatic. A balloon occlusion test of the ICA was performed in five patients, and three of them

**Table 1 Summary of cavernous carotid artery aneurysms treated with stent-assisted coil embolization**

Patient no.	Age (yrs) /Sex	Location	Size (mm)	Partially thrombosed	Tolerance (BOT)	CN dysfunction			
						Pre-treatment	Duration of CN dysfunction before treatment (mo)	Post-treatment	Latest follow-up (mo)
1 (Fig. 1)	81/F	Cav	26	+	-	CN V, CN VI	2	Resolved	- (26)
2	75/F	Cav	17	-	-	CN VI	2	Resolved	- (25)
3	59/F	Cav	20	-	+	-	NA	-	- (22)
4	75/F	PTA	13	-	Not performed	-	NA	CN VI (transient)	- (10)
5	78/F	Cav	26	+	-	CN V, CN III, CN VI	1	Only CN V was resolved	- (9)
6 (Fig. 2)	64/F	Cav	17	-	+	CN V	28	Resolved, CN VI (transient)	- (8)

Hyphens in the "CN dysfunction" columns indicate no CN dysfunction. BOT: balloon occlusion test, Cav: cavernous, CN: cranial nerve, CO: complete occlusion, DF: dome filling, F: female, mo: months, NA: not applicable, PTA: primitive trigeminal artery.

**Table 2 Summary of treatments and imaging follow-ups**

Patient no.	Anesthesia	The number of coils	Packing density (%)	Initial angiographic results	Latest imaging follow-up (months/modality)
1 (Fig. 1)	Local	29	46.7 <sup>b</sup>	NR	Increased NR (22/MRA)
2	Local	9 <sup>a</sup>	22.0 <sup>b</sup>	DF	Increased DF (17/MRA)
3	Local	21	19.0	CO	NR (16/MRA)
4	General	9	27.3	CO	CO (6/DSA)
5	General	29	28.6	CO	CO (6/DSA)
6 (Fig. 2)	General	26	31.1	CO	CO (6/DSA)

<sup>a</sup>: The procedure was finished when a coil became stuck in a microcatheter. <sup>b</sup>: Hydrogel-coated coils (HydroCoil Embolic System, MicroVention, Aliso Viejo, California, USA) were used. CO: complete occlusion, DF: dome filling, DSA: digital subtraction angiography, MRA: magnetic resonance angiography, NR: neck remnant.

did not show tolerance (Table 1).

We performed SACE using Enterprise stents (Cordis Neurovascular, Miami, Florida, USA) under local or general anesthesia in three patients each. Patient no. 3 had bilateral CS aneurysms, and the larger one was treated. Dual antiplatelet agents were administered 1 week prior to the procedure and maintained for 6 months, and then a single antiplatelet agent was continued. A follow-up angiogram was performed 6 months after treatment, and magnetic resonance imaging (MRI) was performed at various intervals thereafter.

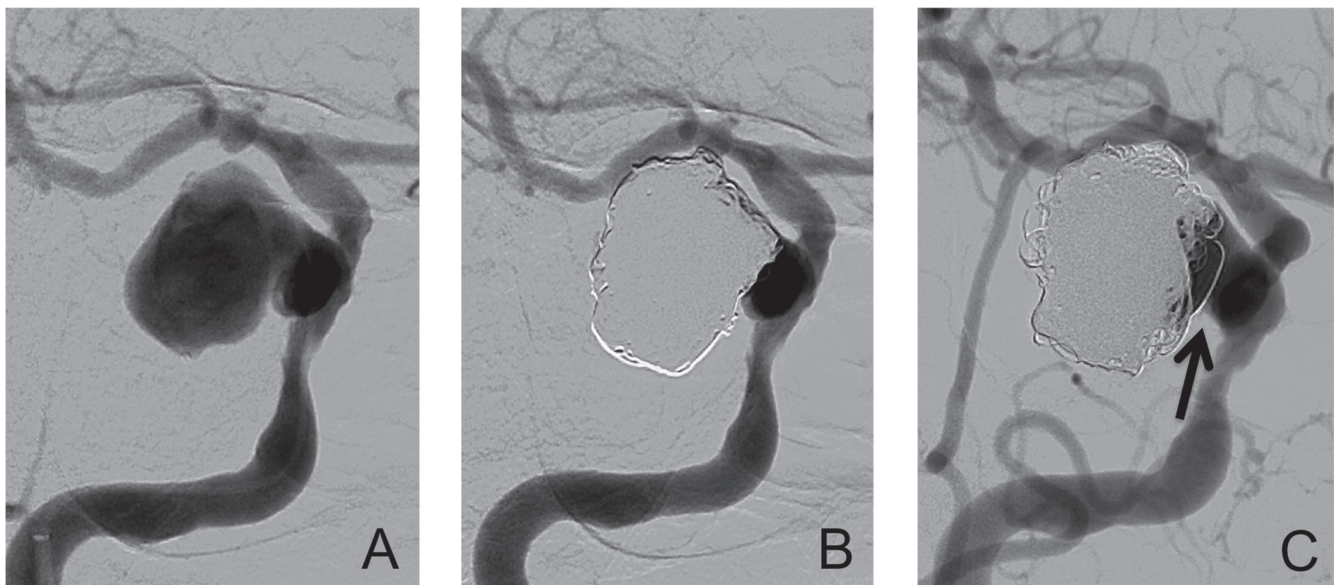
## Results

There were no neurological complications of SACE in any of the six patients. An asymptomatic procedural complication occurred in one patient (patient no. 2) where a coil became stuck in a microcatheter, and the procedure was finished, although slight dome filling was observed. In the post-operative angiograms, we observed complete occlusion in four aneurysms, a neck remnant in one aneurysm, and dome filling in one aneurysm (Table 2). The number of coils used in the operations and the packing density were  $20.5 \pm 9.4$  and  $29.1\% \pm 9.7\%$  (mean  $\pm$  standard deviation), respectively. The mean length of hospital stay was approximately 1 week. CN dysfunction was cured within 3 months in three patients (75%) and was partly cured in

one patient (25%). Although two patients (33%) showed new CN VI dysfunction, because of mass effects by coils, it was resolved within 2 months in both patients. Clinical follow-up ranged from 8 months to 26 months (median: 16 months). During the follow-up, no new CN dysfunction or other complications have occurred.

Imaging follow-up ranged from 6 months to 22 months (median: 11 months). Three aneurysms still had complete occlusion. Although the rest of the three aneurysms (50%) showed recanalization (neck remnant in two patients and dome filling in one patient), no retreatment of additional coiling has yet been required during the follow-up (Table 2).

Representative case (patient no. 1): An 81-year-old woman presented with trigeminal neuralgia (CN V) and diplopia due to abducens nerve palsy (CN VI). An angiogram showed a 26-mm cavernous carotid artery aneurysm (Fig. 1A). The patient could not tolerate a balloon occlusion test of the ICA. General anesthesia was not recommended because the patient had poor cardiac function due to triple-vessel disease. Therefore, we performed SACE under local anesthesia. An angiogram after SACE showed a neck remnant of the aneurysm (Fig. 1B). A total of 29 coils were inserted with a packing density of 46.7%. This high packing density was achieved because we used the stent and hydrogel-coated coils (HydroCoil Embolic System, MicroVention, Aliso Viejo, California, USA). CN dysfunction



**Fig. 1** An 81-year-old woman presented with trigeminal neuralgia and diplopia due to abducens nerve palsy. **A:** An angiogram shows a 26-mm cavernous carotid artery aneurysm. **B:** After stent-assisted coil embolization, an angiogram shows a neck remnant of the aneurysm. Cranial nerve dysfunction was resolved in 2 months. **C:** A follow-up angiogram at 6 months after treatment shows an increased neck remnant (arrow).



was completely resolved in 2 months. A follow-up angiogram at 6 months after treatment showed an increased neck remnant (Fig. 1C), but no additional coiling was required. No retreatment has yet been required based on follow-up MRI at 22 months after treatment. No new CN dysfunction has occurred 26 months after treatment (present day).

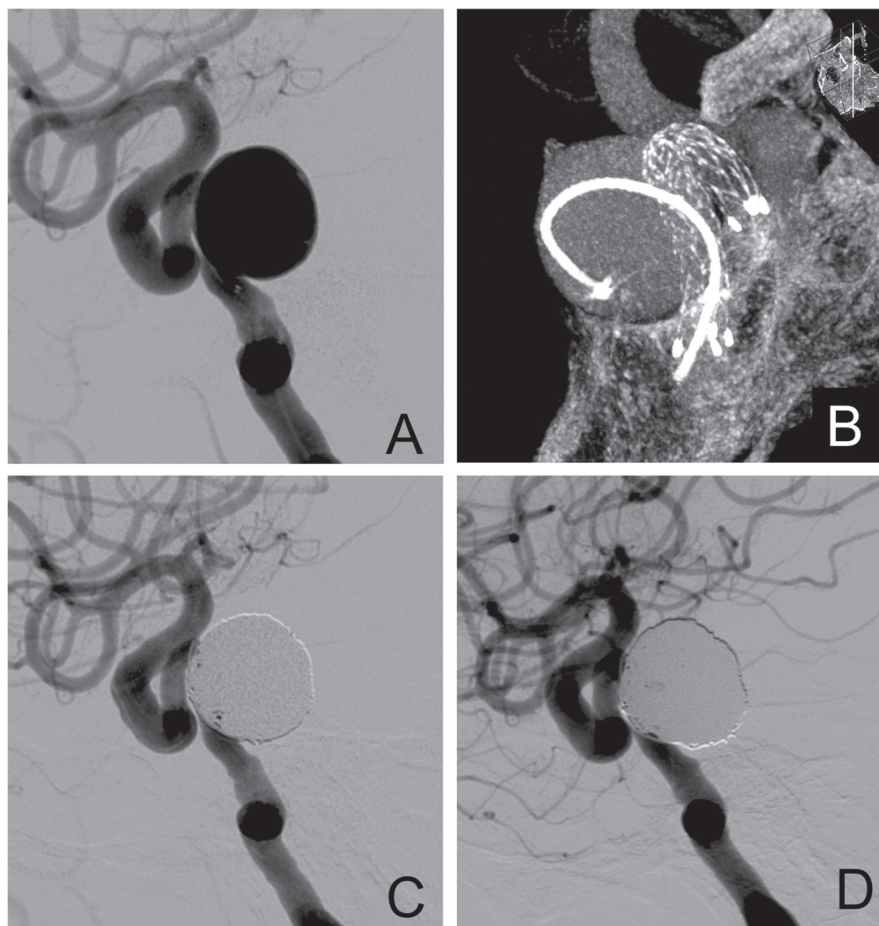
Representative case (patient no. 6): A 62-year-old woman presented with trigeminal neuralgia (CN V). An angiogram showed a 17-mm cavernous carotid artery aneurysm (Fig. 2A). The patient refused any type of operation and received carbamazepine. The pain was relieved for 2 years, but became worse. We treated the patient with SACE using a jailing technique (Fig. 2B). We were able to insert coils tightly because the Enterprise stent covered the neck orifice of the aneurysm (Fig. 2C). A total of 26 coils were inserted in the aneurysm. Complete occlusion of the aneurysm was achieved and the packing density was 31.1%. The trigeminal neuralgia was gradually relieved and completely resolved in 1 month. No medical treatment for the pain was necessary. Following the operation, transient

diplopia occurred because of CN VI palsy. The CN VI palsy was completely resolved in 2 months. A follow-up angiogram at 6 months after the operation showed complete occlusion of the aneurysm (Fig. 2D). The patient is still free from neurological deficits 8 months after the operation.

## Discussion

In our study, CN dysfunction induced by CS aneurysms was cured by SACE in three out of four patients (75%), while transient new CN dysfunction was observed in two patients. Recanalization was observed in three patients (50%), but no retreatment of additional coiling has yet been required and no new or recurrent CN dysfunction has appeared.

For CS aneurysms with CN dysfunction, ICA occlusion with or without preceding bypass surgery is the traditional treatment, which can resolve mass effects induced by aneurysms.<sup>1,2,9)</sup> However, there are no clear criteria for the necessity of low- or high-flow bypass,<sup>10,11)</sup> and high-flow bypass has a relatively high likelihood of complications.<sup>8)</sup> ICA



**Fig. 2** A 64-year-old woman presented with trigeminal neuralgia. **A:** An angiogram shows a 17-mm cavernous carotid artery aneurysm. **B:** Flat-panel detector computed tomography (XperCT; Philips Healthcare, Best, the Netherlands) shows that a microcatheter is placed in the aneurysm and that an Enterprise stent (Cordis Neurovascular, Miami, Florida, USA) covers the wide neck orifice of the aneurysm. **C:** After stent-assisted coil embolization, an angiogram shows complete occlusion of the aneurysm. Trigeminal neuralgia was resolved in 1 month. **D:** A follow-up angiogram at 6 months after the operation shows no recanalization.

occlusion without bypass may develop *de novo* aneurysms in the long term because of hemodynamic stress,<sup>12)</sup> or may cause cerebral infarctions.<sup>6)</sup> SACE is less invasive, results in less post-operative pain, and requires a shorter length of hospital stay compared to ICA occlusion with bypass surgery. In addition, SACE can preserve the ICA and has a wider application for wide-neck CS aneurysms.

In a study by van Rooij and Sluzewski,<sup>7)</sup> coil embolization without stents for 17 CS aneurysms with CN dysfunction was performed, and CN dysfunction resolved or improved in 13 patients (76%), which is comparable with our results (75%). However, in 9 of 17 patients (53%), additional coiling was required because of recanalization during follow-up. This is probably because of the large size of aneurysms and coiling without stents. There are several reports showing that SACE for cerebral aneurysms reduces the recanalization rate compared with coiling without stents.<sup>13–17)</sup> Piotin et al.<sup>16)</sup> reported that stents were associated with a significant decrease in angiographic recurrence (14.9% vs. 33.5%), even though the size of the aneurysms was larger in the stented group than in the non-stented group (9.3 mm vs. 7.1 mm). This is probably because of two reasons: higher packing density and hemodynamic effects of stents. With regard to higher packing density, Izar et al.<sup>14)</sup> reported that packing density was significantly higher in SACE than in coiling alone (36.59% vs. 28.58%).<sup>14)</sup> In our case series, considering the large size of the aneurysms (mean: 19.8mm), the mean packing density of 29.1% was high. This is because the neck orifice of the aneurysms was covered by stents and we were able to tightly insert coils without any concerns of coil protrusion into parent vessels. With regard to hemodynamic effects of stents, they have hemodynamic effects on decreasing velocity in aneurysms because of stent struts, as demonstrated by computational fluid dynamics simulations or silicone model experiments.<sup>18–20)</sup> These hemodynamic effects are considered to contribute to decreasing recanalization or the retreatment rate. In our study, although recanalization was observed in three of six patients, no additional treatment has yet been required during the follow-up period of 8 months to 26 months (median: 16 months).

It would be better if we could compare our current cases with our previous cases treated without intracranial stents as a single-center study. However, there are only two such cases in our hospital since 2006. This small number is probably because of following reasons. Before intracranial stents were available in Japan, surgical or endovascular treatments for CS aneurysms were performed in each hospital. After Enterprise stent became available, patients were

referred to our hospital because Enterprise stent was available by eligible endovascular surgeons in selected institutions for a certain period. Therefore, the number of CS aneurysms treated with SACE increased in our hospital.

Asymptomatic CS aneurysms are commonly observed conservatively because of little risk of subarachnoid hemorrhage. However, in selected cases, surgical or endovascular treatments may be justified. We treated the two asymptomatic patients because of the following reasons. Patient no. 3 was relatively young, 59 years old, and had bilateral CS aneurysms of 8 mm and 20 mm. Previous reports have described the natural history of CS aneurysms as follows: 3 out of 10 patients<sup>1)</sup> and 7 out of 10 patients<sup>21)</sup> with asymptomatic large or giant CS aneurysms showed symptoms on long-term follow-up. Therefore, we decided to treat the larger aneurysm before symptoms appeared. Patient no. 4 had an aneurysm at the bifurcation of the ICA and the primitive trigeminal artery. Subarachnoid hemorrhage owing to ruptured aneurysms at the same location has been reported.<sup>22,23)</sup> Therefore, we treated the aneurysm to prevent subarachnoid hemorrhage. Although our treatment decisions may be controversial, we consider that they are acceptable.

For partially thrombosed aneurysms, parental vessel occlusion is superior to coil embolization of aneurysms because coil embolization occasionally causes growth of aneurysms.<sup>24,25)</sup> However, there are recent reports on partially thrombosed large aneurysms successfully treated with SACE,<sup>26,27)</sup> probably because stents can increase packing density and decrease flow velocity in aneurysms. Patient no. 5 in our study had a 26-mm partially thrombosed giant aneurysm, which has showed no recanalization during the follow-up. Although a large-scale study on SACE for partially thrombosed aneurysms is necessary, our results and recent reports<sup>26,27)</sup> suggest that SACE may improve the cure rate of partially thrombosed aneurysms compared to coil embolization without stents.

Considering the drawbacks of SACE for CS aneurysms, there is a concern that tight packing in SACE may increase mass effects by coils and cause new CN dysfunction. In our two patients, new CN dysfunction following SACE occurred, but was resolved within 2 months. Many more cases are necessary to elucidate this problem. The required prolonged antiplatelet medication is another disadvantage of SACE. The most common cause of late thromboembolic complications is intended or unintended cessation of antiplatelet agents.<sup>28)</sup> Delayed in-stent stenosis or in-stent occlusion is another concern.<sup>29,30)</sup>

Although MRI can detect recanalization after SACE, MRI or computed tomographic angiography can hardly detect in-stent stenosis because of metal artifact or a small vessel size. An angiogram is necessary for evaluation of in-stent stenosis. With regard to the costs of SACE, the mean number of coils used in our study was 20.5. The cost of 20.5 coils is approximately 30,000 US dollars. Although the length of hospital stay is shorter in SACE than in ICA occlusion with high-flow bypass surgery, the total cost of SACE is higher than surgery. Therefore, this high cost of SACE for large or giant aneurysms needs to be considered.

Taking these advantages and disadvantages of SACE into consideration, our study suggests that SACE is an alternative treatment for CS aneurysms, at least for selected patients, such as older patients, those who require high-flow bypass surgery, those who cannot receive general anesthesia, or those who cannot suspend dual antiplatelet agents (due to the placement of drug eluting stents in coronary arteries). Further studies using more cases in long-term follow-up are necessary to elucidate the efficacy of SACE for CS aneurysms.

New flow-diverting stents are designed to occlude the aneurysm without coils or with a small number of coils.<sup>31</sup> Although the first clinical results for ICA aneurysms are encouraging, the safety and effectiveness of these devices in the long-term is not yet known. Further studies are necessary to determine the efficacy of these flow-diverting stents in the treatment of CS aneurysms.

## Conflicts of Interest Disclosure

The authors have no conflict of interest and have registered online self-reported conflict of interest disclosure statement forms through the website for Japan Neurosurgical Society members.

## References

- 1) Linskey ME, Sekhar LN, Hirsch WL, Yonas H, Horton JA: Aneurysms of the intracavernous carotid artery: natural history and indications for treatment. *Neurosurgery* 26: 933–937; discussion 937–938, 1990
- 2) Stiebel-Kalish H, Kalish Y, Bar-On RH, Setton A, Niimi Y, Berenstein A, Kupersmith MJ: Presentation, natural history, and management of carotid cavernous aneurysms. *Neurosurgery* 57: 850–857; discussion 850–857, 2005
- 3) Choulakian A, Drazin D, Alexander MJ: Endosaccular treatment of 113 cavernous carotid artery aneurysms. *J Neurointerv Surg* 2: 359–362, 2010
- 4) Kazekawa K, Tsutsumi M, Aikawa H, Iko M, Kodama T, Go Y, Tanaka A: Internal carotid aneurysms presenting with mass effect symptoms of cranial nerve dysfunction: efficacy and imitations of endosaccular embolization with GDC. *Radiat Med* 21: 80–85, 2003
- 5) van der Schaaf IC, Brilstra EH, Buskens E, Rinkel GJ: Endovascular treatment of aneurysms in the cavernous sinus: a systematic review on balloon occlusion of the parent vessel and embolization with coils. *Stroke* 33: 313–318, 2002
- 6) van Rooij WJ: Endovascular treatment of cavernous sinus aneurysms. *AJNR Am J Neuroradiol* 33: 323–326, 2012
- 7) van Rooij WJ, Sluzewski M: Unruptured large and giant carotid artery aneurysms presenting with cranial nerve palsy: comparison of clinical recovery after selective aneurysm coiling and therapeutic carotid artery occlusion. *AJNR Am J Neuroradiol* 29: 997–1002, 2008
- 8) Mohit AA, Sekhar LN, Natarajan SK, Britz GW, Ghodke B: High-flow bypass grafts in the management of complex intracranial aneurysms. *Neurosurgery* 60: ONS105–122; discussion ONS122–123, 2007
- 9) Tsuura M, Terada T, Nakamura Y, Nakai K, Itakura T: Magnetic resonance signal intensity and volume changes after endovascular treatment of intracranial aneurysms causing mass effect. *Neuroradiology* 40: 184–188, 1998
- 10) Sia SF, Morgan MK: High flow extracranial-to-intracranial brain bypass surgery. *J Clin Neurosci* 20: 1–5, 2013
- 11) Vishteh AG, Alleyne CH, Spetzler RF: Therapeutic carotid occlusion: the case for prophylactic bypass. *Clin Neurosurg* 46: 339–350, 2000
- 12) Briganti F, Cirillo S, Caranci F, Esposito F, Maiuri F: Development of “de novo” aneurysms following endovascular procedures. *Neuroradiology* 44: 604–609, 2002
- 13) Chalouhi N, Jabbour P, Gonzalez LF, Dumont AS, Rosenwasser R, Starke RM, Gordon D, Hann S, Tjoumakaris S: Safety and efficacy of endovascular treatment of basilar tip aneurysms by coiling with and without stent assistance: a review of 235 cases. *Neurosurgery* 71: 785–794, 2012
- 14) Izar B, Rai A, Raghuram K, Rotruck J, Carpenter J: Comparison of devices used for stent-assisted coiling of intracranial aneurysms. *PLoS ONE* 6: e24875, 2011
- 15) Lawson MF, Newman WC, Chi YY, Mocco JD, Hoh BL: Stent-associated flow remodeling causes further occlusion of incompletely coiled aneurysms. *Neurosurgery* 69: 598–603; discussion 603–604, 2011
- 16) Piotin M, Blanc R, Spelle L, Mounayer C, Piantino R, Schmidt PJ, Moret J: Stent-assisted coiling of intracranial aneurysms: clinical and angiographic results in 216 consecutive aneurysms. *Stroke* 41: 110–115, 2010
- 17) Wakhloo AK, Linfante I, Silva CF, Samaniego EA, Dabus G, Etezadi V, Spilberg G, Gounis MJ: Closed-cell stent for coil embolization of intracranial aneurysms: clinical and angiographic results. *AJNR Am J Neuroradiol* 33: 1651–1656, 2012



- 18) Ford MD, Nikolov HN, Milner JS, Lownie SP, Demont EM, Kalata W, Loth F, Holdsworth DW, Steinman DA: PIV-measured versus CFD-predicted flow dynamics in anatomically realistic cerebral aneurysm models. *J Biomech Eng* 130: 021015, 2008
- 19) Kono K, Terada T: Hemodynamics of 8 different configurations of stenting for bifurcation aneurysms. *AJNR Am J Neuroradiol* 34: 1980-1986, 2013
- 20) Tremmel M, Xiang J, Natarajan SK, Hopkins LN, Siddiqui AH, Levy EI, Meng H: Alteration of intra-aneurysmal hemodynamics for flow diversion using enterprise and vision stents. *World Neurosurg* 74: 306-315, 2010
- 21) Goldenberg-Cohen N, Curry C, Miller NR, Tamargo RJ, Murphy KP: Long term visual and neurological prognosis in patients with treated and untreated cavernous sinus aneurysms. *J Neurol Neurosurg Psychiatr* 75: 863-867, 2004
- 22) Kai Y, Ohmori Y, Watanabe M, Morioka M, Hirano T, Kawano T, Sakurama T, Miura A, Kuratsu J: Coil embolization of an aneurysm located at the trunk of the persistent primitive trigeminal artery. *Neurol Med Chir (Tokyo)* 51: 361-364, 2011
- 23) Li MH, Li WB, Pan YP, Fang C, Wang W: Persistent primitive trigeminal artery associated with aneurysm: report of two cases and review of the literature. *Acta Radiol* 45: 664-668, 2004
- 24) Ferns SP, van Rooij WJ, Sluzewski M, van den Berg R, Majoie CB: Partially thrombosed intracranial aneurysms presenting with mass effect: long-term clinical and imaging follow-up after endovascular treatment. *AJNR Am J Neuroradiol* 31: 1197-1205, 2010
- 25) Iihara K, Murao K, Yamada N, Takahashi JC, Nakajima N, Satow T, Hishikawa T, Nagata I, Miyamoto S: Growth potential and response to multimodality treatment of partially thrombosed large or giant aneurysms in the posterior circulation. *Neurosurgery* 63: 832-842; discussion 842-844, 2008
- 26) Abe T, Hagihara N, Hirohata M, Uchiyama Y, Tanaka N, Hayabuchi N: Partially thrombosed vertebral artery aneurysm with wall enhancement treated by stent-assisted coil embolization. *Neurol Med Chir (Tokyo)* 51: 431-433, 2011
- 27) Kim YJ, Ko JH: Endovascular treatment of a large partially thrombosed basilar tip aneurysm. *J Korean Neurosurg Soc* 51: 62-65, 2012
- 28) Kanaan H, Jankowitz B, Aleu A, Kostov D, Lin R, Lee K, Panipitiya N, Gologorsky Y, Sandhu E, Rissman L, Crago E, Chang YF, Kim SR, Jovin T, Horowitz M: In-stent thrombosis and stenosis after neck-remodeling device-assisted coil embolization of intracranial aneurysms. *Neurosurgery* 67: 1523-1532; discussion 1532-1533, 2010
- 29) Chalouhi N, Drueding R, Starke RM, Jabbour P, Dumont AS, Gonzalez LF, Rosenwasser R, Tjoumakaris S: In-stent stenosis after stent-assisted coiling: incidence, predictors and clinical outcomes of 435 cases. *Neurosurgery* 72: 390-396, 2013
- 30) Kono K, Shintani A, Tanaka Y, Terada T: Delayed in-stent occlusion due to stent-related changes in vascular geometry after cerebral aneurysm treatment. *Neurol Med Chir (Tokyo)* 53: 182-185, 2013
- 31) Nelson PK, Lylyk P, Szikora I, Wetzel SG, Wanke I, Fiorella D: The pipeline embolization device for the intracranial treatment of aneurysms trial. *AJNR Am J Neuroradiol* 32: 34-40, 2011

---

*Address reprint requests to:* Kenichi Kono, MD, Department of Neurosurgery, Wakayama Rosai Hospital, 93-1 Kinomoto, Wakayama, Wakayama 640-8505, Japan. *e-mail:* vyr01450@gmail.com