

HELMINTHOLOGIA, 56, 3: 247 - 251, 2019

## Research Note

# Human dirofilariasis in Bulgaria between 2009 and 2018

V. VELEV<sup>1\*</sup>, K. VUTOVA<sup>1</sup>, T. PELOV<sup>2</sup>, I. TSACHEV<sup>3</sup>

<sup>1</sup>University Hospital for Infectious and Parasitic Diseases “Prof. Iv. Kirov,” Medical University of Sofia, Sofia, Bulgaria, \*E-mail: [velev\\_md@abv.bg](mailto:velev_md@abv.bg); <sup>2</sup>Department of Pediatric Urology, University Hospital for Emergency Medicine “Pirogov,” Sofia, Bulgaria; <sup>3</sup>Department of Microbiology, Infectious and Parasitic Diseases, Faculty of Veterinary Medicine, Trakia University, Stara Zagora, Bulgaria

### Article info

Received February 26, 2019  
Accepted April 10, 2019

### Summary

Autochthonous *Dirofilaria repens* infections have been found in dogs and other carnivores in most European countries. In the same countries, reports of human dirofilariasis are becoming increasingly prevalent. We present 18 cases of people infected with *D. repens* for a 10-year period traced in our hospital. The data was collected from the observations and tests of all 18 patients from the whole country treated at the Specialized Hospital for Infectious and Parasitic Diseases in Sofia in the period 2009 – 2018. We used a morphological method, serology test and Knott’s method for microfilariae. The patients were 11 to 74 years of age, 12 female and 6 male. In most cases, patients have subcutaneous nodules or face, eyelid and eyes localization. The trend of increasing incidence in Bulgaria continues, with age and sex distribution and localization of the larva being similar to those in other European countries.

**Keywords:** *Dirofilaria repens*; dirofilariasis; dogs; subcutaneous nodules

### Introduction

The most common mosquito-borne nematodiasis in Europe is dirofilariasis. Two types of parasites are etiological agents in Europe: *Dirofilaria immitis* and *Dirofilaria (Nochtiella) repens*. Reservoirs of both parasites are predominantly dogs and wild-living carnivores, and vectors are mosquitoes of order *Diptera* (Angelov & Vuchev, 2010; Cancrini & Gabrielli, 2007). In Bulgaria and neighbouring countries are found several mosquito species capable to transmit dirofilaria: *Anopheles maculipennis* complex, *Culex pipiens*, *Cochillettidia richiardii* and *Aedes vexans* (Mikov *et al.*, 2011; Pudar *et al.*, 2018; Tomazatos *et al.*, 2018).

*D. immitis* localizes in the pulmonary artery of dogs and wild predators and causes severe disease. Infections in people are rare in Europe, but not in North America (Miterpáková *et al.*, 2018).

*Dirofilaria repens* typically causes a milder, subcutaneous infection in dogs, wild predators, and more rarely in cats. It is the major

parasite causing dirofilariasis in humans, with an increasing number of cases reported in Europe. In dogs and wild predators, the parasite is localized in the subcutaneous tissues, and the microfilariae circulate in the bloodstream. Microfilaraemic dogs are the most important reservoir of infection (Genchi & Kramer, 2017). In humans, the larvae rarely reach sexual maturity, and most often migrate into the subcutaneous tissue, rarely localizing in an organ (Poppert *et al.*, 2009; Kludkowska *et al.*, 2018). In the past ten years, *D. repens* has been described as a typical example of an emerging pathogen, since it is affecting more and more regions in Europe. This phenomenon is typical of most vector borne zoonotic diseases and is explained mainly with warmer climate.

Autochthonous cases of dirofilariasis in dogs have been reported in almost the entire southern part of the Old World, most of all are the Mediterranean countries and Central Europe (Sassnau *et al.*, 2013; Muro *et al.*, 1999).

In Bulgaria, prevalence of both parasites has been confirmed in

\* – corresponding author

dogs and wild predators – *D. immitis* was found in 5 dogs of 40 tested and in 4 foxes of 78 tested. 8.6 % of the dogs tested and almost 9 % of the jackals tested were microfilaraemic (Panayotova-Pencheva *et al.*, 2016). In another study in Sofia, 240 dogs were tested, 15 of which were infected with *D. immitis*, 12 with *D. repens* and 6 with both parasites (Konstantinov, 2017). In Bulgaria, all reported cases of infected people are only with *D. repens*. For a period of 39 years, 1973-2011, Harizanov *et al.* summarized 47 cases in different centers. We summarize 18 cases of people infected with *D. repens* for a period of 10 years (Harizanov *et al.*, 2014).

## Material and Methods

The data was collected from the observations and tests of all 18 patients from the whole country treated at the Specialized Hospital for Infectious and Parasitic Diseases in Sofia in the period 2009-2018. 8 out of 28 regions (Sofia-city, Blagoevgrad, Kardzhali, Burgas, Pleven, Stara Zagora, Ruse, Varna) were covered by place of residence. Most of the cases were reported in Sofia-city (7) and Blagoevgrad (4).

Patients were classified by demographic characteristics and by clinical and diagnostic data. Morphological methods were used for species determination of the parasite - macroscopic in the case of a preserved worm and microscopic, using a histological preparation (Heidari *et al.*, 2015). In some cases, serological methods were used commercial ELISA kit (Bordier Affinity Products SA, Crissier,

Switzerland) and Knott's method for microfilariae. Full blood count were performed in all patients, with follow-up of eosinophil levels.

## Ethical Approval and/or Informed Consent

The study was performed in accordance with the Declaration of Helsinki and approved by the ethics committee of the hospital. Most of the patients were referred by their family doctors or by surgeons after removal of the worm.

## Results

### Demographic characteristics

In a 10-year period, 2009-2018, we observed and described 18 patients with dirofilariasis (Table 1). The patients were 11 to 74 years of age, 12 female and 6 male, only one patient was a child – an 11-year-old boy with epididymal dirofilariasis. This is the first reported case of a child affected by dirofilariasis in Bulgaria (Velev *et al.*, 2019).

### Clinical data

In most cases, patients have subcutaneous nodules - the dead and calcified larva. Before it dies, the larva can move through the subcutaneous tissue or submucosa, causing unpleasant sensations. The patient can see the moving larva if it is in a visible place or feel the formed parasitic nodule. Most commonly, the patient seeks medical attention because of finding a calcified nodule.

Table 1. *Dirofilaria repens*-infections in humans registered in Sofia hospital between 2009 and 2018.

No	Year of diagnosis	Gender	Age	Place (v=village; c=city)	Localization
1	2009	m	26	c. Sofia	Subcutaneous – upper limb
2	2010	f	64	c. Varna	Subcutaneous – eyelid
3	2010	f	34	v. Strumyani, c. Blagoevgrad	Subcutaneous – chest
4	2011	f	52	v. Obnova, c. Pleven	Eye
5	2012	m	48	c. Sofia	Subcutaneous-lower limb
6	2013	f	30	v. Belchin, c. Sofia	Lymph node
7	2013	f	55	v. Sozopol, c. Burgas	Subcutaneous – upper limb
8	2015	f	23	c. Vraca	Subcutaneous – eyelid
9	2015	m	44	v. Volvo, c. Ruse	Eye
10	2016	f	74	c. Sofia	Subcutaneous – upper limb
11	2016	f	61	v. Kravino, c. Stara Zagora	Subcutaneous – face
12	2016	f	29	c. Blagoevgrad	Eye
13	2016	f	35	c. Sofia	Subcutaneous – upper limb
14	2017	m	37	c. Sofia	Oral cavity
15	2017	f	72	v. Gulia, c. Kurdzali	Eye
16	2017	m	61	c. Blagoevgrad	Subcutaneous—lower limb
17	2018	m	11	v. Gotse Delchev, c. Blagoevgrad	Testis
18	2018	f	67	c. Sofia	Subcutaneous – upper limb

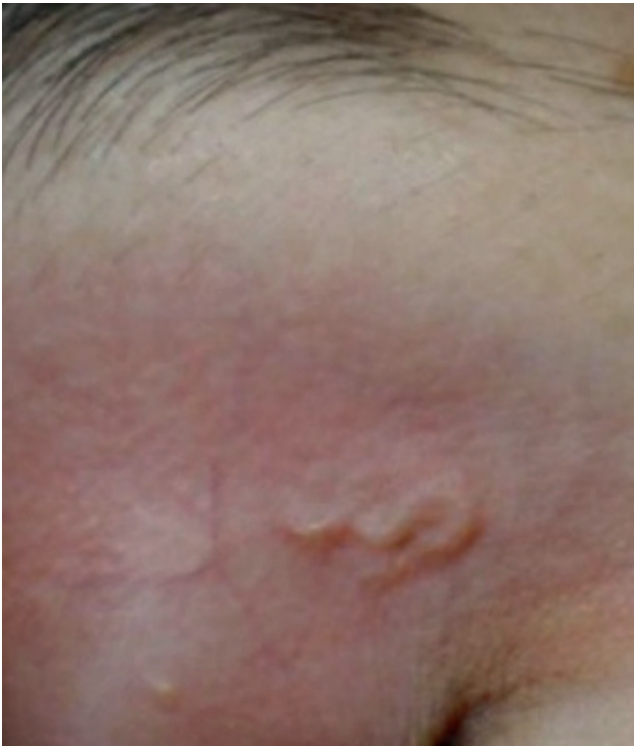

Fig. 1. Subcutaneous localization of *Dirofilaria repens* in an eyelid.

Only in ocular dirofilariasis, the larva remains intact subconjunctivally, does not calcify, and is usually easily noticed. Numerous subcutaneous and organ localizations have been described in the literature - lungs, oral cavity, reproductive organs, lymph nodes. In most of the cases described by us localization was subcutaneous - 11 (61.1 %), in 9 of these 11 cases, the larva was localized in the upper part of the body - subcutaneous tissue of the upper limb, face, eyelid (Fig. 1). Next was subconjunctival localization - in 4 (22.2 %) cases. In two of these cases, the larva was freely moving. The onset in all four patients manifested with blurred vision of the affected eye, photophobia, irritation, conjunctival injection and tearing. In one patient, the localization was in the oral cavity, and the larva located buccally was extirpated alive (Fig. 2a, b, c). We also described one case of lymph node localization and one case of epididymal localization. Besides local swelling and a subcutaneous nodule found upon palpation, in these individual cases, the patients had no symptoms. In one of the patients with subcutaneous localization of the larva in the area of the right mamilla, we observed a transient maculo-papular rash covering the upper half of the trunk, which, in our opinion, can be explained with antigenic irritation by the parasite.

#### Diagnosics

In all 18 patients, histological preparations of the extirpated nodules or whole larva were made, and the diagnosis was based on the morphological characteristics of the parasite. In one of our patients, with localization in the oral cavity, a whole living larva was

also extirpated, which was subject to macroscopic diagnostics as well. Attention should be paid to the longitudinal ridges of the cuticle, which is a characteristic morphological feature of *D. repens*. In one case, with histologically proven subcutaneous dirofilariasis in a 34-year-old woman, we performed a serological test with a commercial ELISA kit, Bordier Affinity Products SA, Switzerland, but the result was negative. In two patients, one of them with a larva in an inguinal lymph node, we performed testing of blood samples for microfilariae using a Knott's method, but both cases were negative.

In literature, recommendations are made to measure the total IgE level and eosinophilia if dirofilariasis is suspected (Kłodkowska *et al.*, 2018; Ermakova *et al.*, 2017). In all 18 patients, we analysed complete blood count, but only in the patient with a living larva extirpated from the oral cavity, we found elevated eosinophil levels reaching 31 %.

#### Treatment

All 18 patients underwent surgical treatment with extirpation of the larva or parts of it, before or after our definitive diagnosis. No one was treated with anthelmintic medication and there is no evidence of relapse of the disease.

#### Discussion

The trend of increasing the incidence of human dirofilariasis in the European countries, and, in particular, in Bulgaria, continues. In the period 1973 – 2011, Harizanov *et al.* (2014) summarized 47 cases from the whole country, and in the period 2009 – 2018, we described 18 cases from only one clinical center. The distribution by age group does not differ significantly from that described in other European countries, nor from the previous large study in Bulgaria. This is our first case in a child, as these cases are rare in Europe, but in countries like Sri Lanka they are not uncommon (Dissanaike *et al.*, 1997). In our study, the female sex predominates, and this trend is described by most authors, with no satisfactory explanation suggested so far. The fact that most of the patients are in Sofia-city and Blagoevgrad regions is probably due to the proximity of our clinical center, but the fact that Blagoevgrad is usually the warmest area in Bulgaria is likely to matter. In most cases, patients have no subjective symptoms except in the case of a moving larva or ocular localization. Due to the absence of specific symptoms, the initial diagnoses may be various - lymphadenitis, lipoma, infectious or allergic conjunctivitis. The definitive diagnosis is made after removal of the worm and macroscopic or histological assessment. In the only case in which we were able to perform a serological diagnosis, we obtained a negative result, which, along with other literature data, makes us reserved regarding this diagnostic method (Genchi & Kramer, 2017; Pampiglione & Rivasi, 2000). In the literature examined, we found several published cases of microfilaraemia in humans (Popper *et al.*, 2009; Kłodkowska *et al.*, 2018). We performed two tests for microfilaraemia in blood

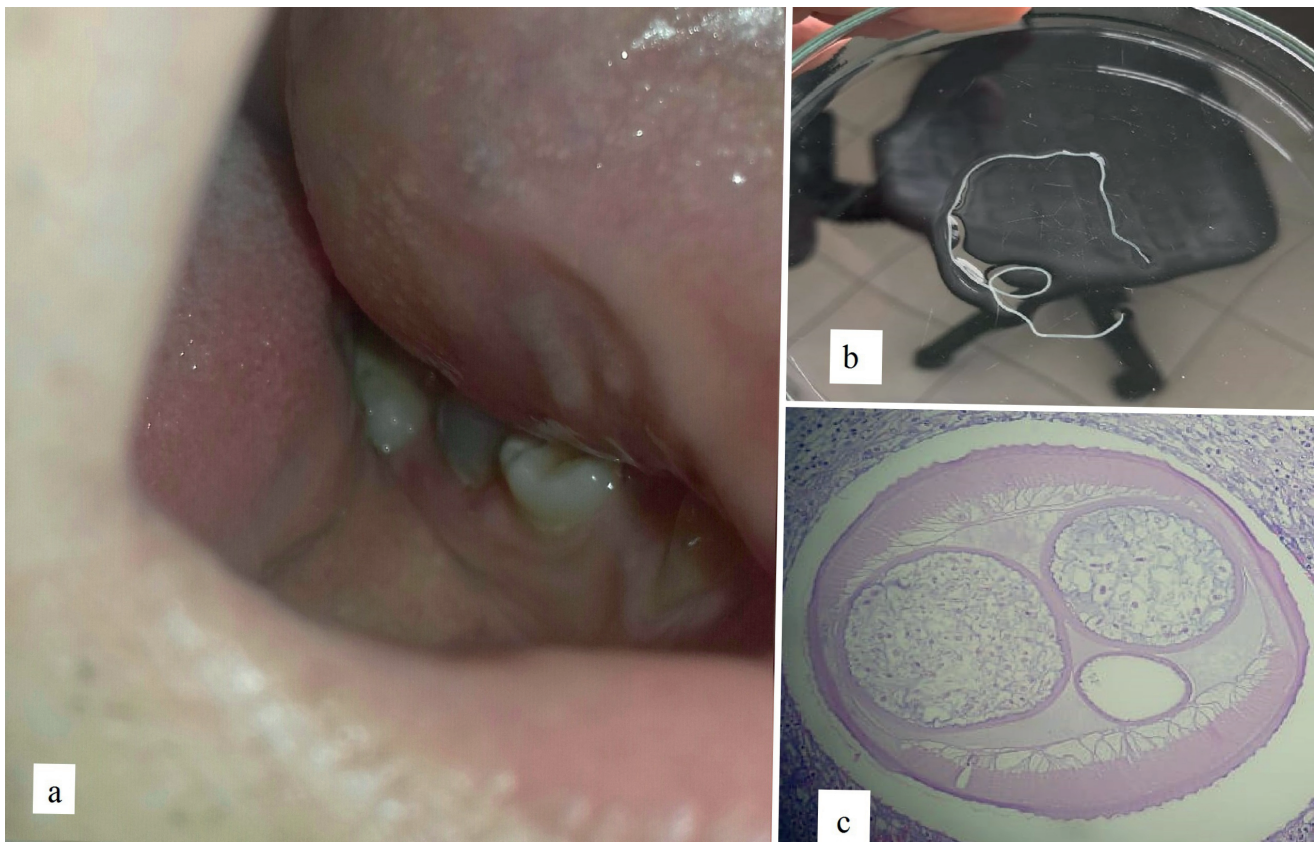


Fig. 2. *Dirofilaria repens* located in oral cavity (a). Extracted living parasite (b). Cross section of the extracted worm (c).

samples, one in a patient with lymph node localization, but the results obtained were negative.

Regarding the therapy, like other authors, we think surgical removal of the larva is sufficient.

### Conclusion

We summarized the cases of dirofilariasis in patients at one clinical center in a ten-year-period. The trend of increasing incidence in Bulgaria continues, with age and sex distribution and localization of the larva being similar to those in other European countries. The increasing incidence of dirofilariasis can be explained both by the warmer climate and by the large number of stray dog in Bulgaria. Dirofilariasis is already endemic in most Southern and Central European countries and is an increasingly important clinical and social problem. Such summaries of clinical cases help to draw the attention of both medical doctors and veterinarians in Europe for active search of this disease.

### Conflict of Interest

The authors report no conflict of interests.

### References

- ANGELOV, I., VUCHEV, D. (2010): Dirofilariasis caused by *Dirofilaria repens* in humans. *Infectology* 1:36 – 39 (In Bulgarian)
- CANCRINI, G., GABRIELLI, S. (2007): Vectors of *Dirofilaria* nematodes: biology, behaviour and host/parasite relationships. In: GENCHI, C., RINALDI, L., CRINGOLI, G. (Eds) *Dirofilaria immitis* and *D. repens* in dog and cat and human infections. *Mappe Parassitologiche* 8: 49 – 58
- DISSANAIKE, A.S., ABYEYEWICKREME, W., WIJESUNDERA, M.D., WEERASOORIYA, M.V., ISMAIL, M.M. (1997:) Human dirofilariasis caused by *Dirofilaria* (Nochtiella) *repens* in Sri Lanka. *Parasitologia* 39(4): 375 – 382
- ERMAKOVA, L., NAGORNY, S., PSHENICHNAYA, N., AMBALOV, Y., BOLTACHIEV, K. (2017): Clinical and laboratory features of human dirofilariasis in Russia. *IDCases*, 9: 112 – 115. DOI: 10.1016/j.idcr.2017.07.006. eCollection 2017
- GENCHI, C., KRAMER, L. (2017): Subcutaneous dirofilariasis (*Dirofilaria repens*): an infection spreading throughout the old world. *Parasit. Vectors.*, 10(Suppl. 2): 517. DOI: 10.1186/s13071-017-2434-8
- HARIZANOV, R.N., JORDANOVA, D.P., BIKOV, I.S. (2014): Some aspects of the epidemiology, clinical manifestations, and diagnosis

- of human dirofilariasis caused by *Dirofilaria repens*. *Parasitol Res.*, 113(4): 1571 – 1579. DOI: 10.1007/s00436-014-3802-3
- HEIDARI, Z., KIA, E.B., ARZAMANI, K., SHARIFDINI, M., MOBEDI, I., ZAREI, Z., KAMRANRASHANI, B. (2015): Morphological and molecular identification of *Dirofilaria immitis* from Jackal (*Canis aureus*) in North Khorasan, northeast Iran. *J Vector Borne Dis.*, 52(4): 329 – 333
- KŁUDKOWSKA, M., PIELOK, Ł., FRĄCKOWIAK, K., MASNY, A., GOŁĄB, E., PAUL, M. (2018): *Dirofilaria repens* infection as a cause of intensive peripheral microfilariaemia in a Polish patient: process description and cases review. *Acta Parasitol.*, 63(3): 657 – 663. DOI: 10.1515/ap-2018-0077
- KONSTANTINOV, M. (2017): *Dirofilariasis* in Veterinary Medicine in Bulgaria. In *VII Conference on Veterinary Medicine in Plovdiv, Bulgaria*, pp. 21 – 23 (In Bulgarian)
- MIKOV, O., VUCHEV, D., LALKOVSKI, N. (2011): Distribution of mosquito species as potential vectors of dirofilariases in humans and animals in Bulgaria. In *Abstracts of the "Anniversary Scientific Session 110 years from foundation of the NDSRVMI"*. Sofia, Bulgaria: National Diagnostic Science-and-Research Veterinary Medical Institute (NDSRVMI), Sofia, Bulgaria, pp. 152 – 156 (In Bulgarian)
- MITERPÁKOVÁ, M., VALENTOVÁ, D., ČABANOVÁ, V., BEREŠÍKOVÁ, L. (2018): Heartworm on the rise—new insights into *Dirofilaria immitis* epidemiology. *Parasitol Res.*, 117(7): 2347 – 2350. DOI: 10.1007/s00436-018-5912-9
- MURO, A., GENCHI, C., CORDERO, M., SIMON, F. (1999): Human dirofilariasis in the European Union. *Parasitol. Today*, 15: 386 – 389
- PAMPIGLIONE, S., RIVASI F. (2000): Human dirofilariasis due to *Dirofilaria* (*Nochtiella*) *repens*: an update of world literature from 1995 to 2000. *Parassitologia*, 42: 231 – 254
- PANAYOTOVA-PENCHEVA, M.S., MIRCHEV, R., TRIFONOVA, A. (2016): *Dirofilaria immitis* infection in carnivores from Bulgaria: 2012 – 2013 update. *Bulg. J. Vet. Med.*, 19: 153 – 162. DOI: 10.15547/bjvm.918
- POPERT, S., HODAPP, M., KRUEGER, A., HEGASY, G., NIESEN, W.D., KERN, W.V., TANNICH, E. (2009): *Dirofilaria repens* infection and concomitant meningoencephalitis. *Emerg Infect Dis.*, 15(11): 1844 – 1846. DOI: 10.3201/eid1511.090936
- PUDAR, D., PETRIĆ, D., ALLÈNE, X., ALTEN, B., AYHAN, N., CVETKOVIKJ, A., GARROS, C., GOLETIC, T., GUNAY, F., HLAVACKOVA, K., IGNJATOVIC CUPINA, A., KAVRAN, M., LESTINOVA, T., MATHIEU, B., MIKOV, O., PAJOVIC, I., RAKOTOARIVONY, I., STEFANOVSKA, J., VASELEK, S., ZUKO, A., BALENGHIEN, T. (2018): An update of the Culicoides (Diptera: Ceratopogonidae) checklist for the Balkans. *Parasit. Vectors.*, 11(1): 462. DOI: 10.1186/s13071-018-3051-x
- SASSNAU, R., KOHN, M., DEMELER, J., KOHN, B., MÜLLER, E., KRÜCKEN, J., VON SAMSON-HIMMELSTJERNA, G. (2013): Is *Dirofilaria repens* endemic in the Havelland district in Brandenburg, Germany? *Vector Borne Zoonotic Dis.*, 13(12): 888 – 891. DOI: 10.1089/vbz.2012.1293
- TOMAZATOS, A., CADAR, D., TÖRÖK, E., MARANDA, I., HORVÁTH, C., KERESZTES, L., SPINU, M., JANSEN, S., JÖST, H., SCHMIDT-CHANASIT, J., TANNICH, E., LÜHKEN, R. (2018): Circulation of *Dirofilaria immitis* and *Dirofilaria repens* in the Danube Delta Biosphere Reserve, Romania. *Parasit. Vectors.*, 11(1): 392. DOI: 10.1186/s13071-018-2980-8
- VELEV, V., PELOV, T., GAREV, T., PEEV, S., KAFTANDJIEV, I., HARIZANOV, R. (2019): Epididymal *Dirofilariasis* in a Child. First Case Report from Bulgaria. *Med Princ Pract.*, 28(1): 96 – 98. DOI: 10.1159/000494619