

A case of late-onset dopa-responsive isolated dystonia secondary to a novel tyrosine hydroxylase gene variant



S.P. Chaithra^a, Albert Stezin^{a,b}, Shweta Prasad^{a,b}, Vikram V. Holla^a, Abhishek Lenka^{a,b}, Nitish Kamble^a, Ravi Yadav^a, Pramod Kumar Pal^{a,*}

^a Department of Neurology, National Institute of Mental Health & Neurosciences (NIMHANS), Hosur Road, Bangalore 560029, Karnataka, India

^b Department of Clinical Neurosciences, National Institute of Mental Health & Neurosciences (NIMHANS), Hosur Road, Bangalore 560029, Karnataka, India

ARTICLE INFO

Article history:

Received 10 October 2019

Received in revised form 5 December 2019

Accepted 9 December 2019

Available online 21 January 2020

Keywords:

Dopa responsive dystonia

Tyrosine hydroxylase

Novel variant

Dystonia

Dopa-responsive dystonia (DRD) is a genetically heterogeneous disorder characterised by levodopa responsive dystonia with diurnal fluctuation. The most common genetic variant involves GTP cyclohydrolase 1 (*GCH1*). Variants affecting other genes involved in dopamine synthesis, i.e., tyrosine hydroxylase (*TH*), sepiapterin reductase, and 6-pyruvoyl tetrahydrobiopterin synthase can also produce DRD [1]. This report describes a case of DRD with a novel compound heterozygous variant of the *TH* gene and an atypical phenotype.

A 20-year-old man born of non-consanguineous parentage, with normal psychomotor development, presented with an 8-year history of progressive deviation of the head toward the right. This was associated with a gradually increasing sensation of stiffness and abnormal posturing of bilateral upper and lower limbs. He had progressive difficulty walking, associated with dragging of the right leg and forward falls for 3 years, and had recently resorted to walking on all four limbs. He reported a definite diurnal fluctuation with sleep benefit and worsening toward evening. There was no history of other abnormal movements, significant past medical history or positive family history of similar symptoms. A video was taken after written informed consent.

On examination (Video-1, Segment-1), while seated, the patient had torticollis toward the right with mild retrocollis, and dystonic posturing of the left hand. Upon attempting to stand and walk, the patient lurches

forwards and moves by crawling on all fours; dystonic posturing of the left upper and lower limbs is also observed. When attempting to walk upright, the patient raises his hands above his head, while touching his forehead. This manoeuvre probably acted like a geste-antagoniste, following which, he was able to walk rapidly on his toes before lurching forward and falling.

Routine clinical workup, including MRI of the brain and spine were unremarkable. In view of the history of significant diurnal fluctuation, the possibility of DRD was considered. Low dose levodopa/carbidopa (50 mg/12.5 mg) was started and a reduction of 13 points on the Burke-Fahn-Marsden dystonia rating scale (BFMDRS) (pre-levodopa:29, post-levodopa:16) was observed. The patient was prescribed levodopa/carbidopa (100 mg/25 mg twice a day) and at one-year follow-up (Video-1, Segment-2), significant improvement was observed. The patient had minimal cervical dystonia, was able to walk upright, and BFMDRS score had reduced to four.

Considering the provisional diagnosis of DRD, a targeted clinical-exome sequencing was performed to identify the pathogenic variant. Targeted gene capture using a customised capture kit was performed on the DNA extracted from blood. DNA libraries were sequenced to more than 80–100 × coverage on the Illumina sequencing platform. The sequences were aligned to the human reference genome (GRCh37/hg19) and analysed to identify variants of clinical significance. On analysis, a heterozygous single base pair deletion in exon 4 (chr11:2189776delC;c.525delG;p.Leu176SerfsTer61) and a heterozygous missense variation in exon 14 (chr11:2185569G>G/A;c.1481C>C/T;p.Thr494Met) of the *TH* gene (ENST00000381178) were detected in the proband. A heterozygous variation in the exon 4 was detected in the unaffected father and a heterozygous variation in exon 14 was detected in the unaffected mother (Fig. 1), indicating that the parents were asymptomatic heterozygous carriers of one of each variation detected in the proband. Validation was performed using Sanger sequencing in the proband and parents.

TH related DRDs are rare in comparison to *GCH1* variants and exhibit significant clinical variability [1,2]. The common phenotypes are progressive hypokinetic-rigid syndrome with dystonia (type-A) and complex encephalopathy (type-B) [1,2]. Atypical presentations include myoclonus-dystonia, spastic paraparesis, myopathy-like features and intellectual disability. A mild *TH* deficiency phenotype presents in early childhood, although onset in early adulthood has been reported [3]. They tend to have poor levodopa response, early dyskinesia and mild intellectual disability

* Corresponding author at: Department of Neurology, National Institute of Mental Health & Neurosciences (NIMHANS), Hosur Road, Bangalore 560029, Karnataka, India.

E-mail address: palpramod@hotmail.com. (P.K. Pal).

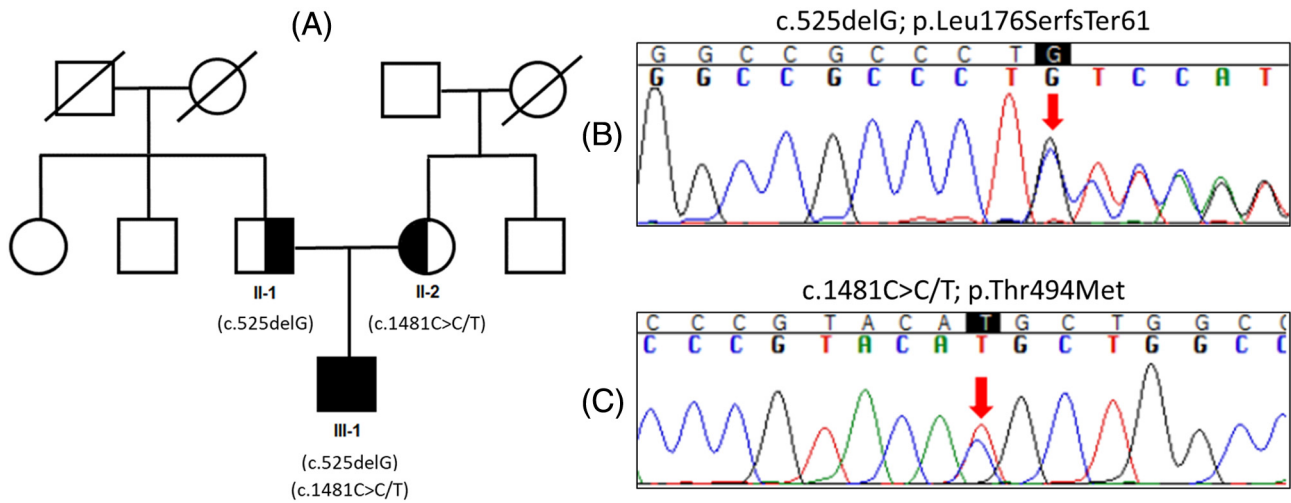


Fig. 1. Pedigree and Chromatogram of the Proband (a) Pedigree showing autosomal recessive inheritance of proband and carrier state of parents (b) Sequencing chromatogram showing the c.525delG variant (c) Sequencing chromatogram showing the c.1481C>C/T variant.

[4]. In contrast, the proband had onset in early adolescence with axial dystonia without hypokinesia, intellectual impairment or autonomic dysfunction and a good response to low dose levodopa. This atypical presentation may be due to the novel genetic variations observed in this case. The deletion variant observed in exon 4 is predicted to cause frameshift and premature termination of the protein product and has not reported previously in ethnically matched controls (MedGenome database- $n = 6028$) and population databases (ExAC and 1000 genomes). The variant in exon 14 is predicted to cause substitution of amino-acid and is known to cause DRD in a compound heterozygous state [5], which may influence TH activity and modulate biosynthesis of dopamine in the brain. To further ascertain the role of these variants in the present case, combined annotation dependent depletion (CADD) scores were computed. For the variant on exon 4 (c.525DelG) the CADD score was 24.1, and for the variant on exon 14 (c.1481C>C/T) the CADD score was 24.3. This suggests that these variants are among the top 1% of deleterious mutations. DAT scans are typically normal in patients with DRD, unfortunately a DAT scan was not performed in this subject. If present, this would have contributed to supporting a diagnosis of DRD.

In conclusion, this report describes a novel genetic variant of TH with an atypical phenotype of DRD. This disorder may present with diverse and atypical phenotypes based on the causative genetic variations. A high index of suspicion is warranted while evaluating patients with dystonia.

Supplementary data to this article can be found online at <https://doi.org/10.1016/j.prd.2020.100039>.

Declaration of competing interests

Nothing to declare.

Acknowledgements

We thank MedGenome Lab Pvt. Ltd. for performing the exome sequencing on the subjects.

References

- [1] S. Wijemanne, J. Jankovic, Dopa-responsive dystonia—clinical and genetic heterogeneity, *Nat. Rev. Neurol.* 11 (7) (2015) 414–424.
- [2] M.A. Willemsen, M.M. Verbeek, E.J. Kamsteeg, J.F. de Rijk-van Andel, A. Aeby, N. Blau, A. Burlina, M.A. Donati, B. Geurtz, P.J. Grattan-Smith, M. Haeussler, G.F. Hoffmann, H. Jung, J.B. de Klerk, M.S. van der Knaap, F. Kok, V. Leuzzi, P. de Lonlay, A. Megarbane, H. Monaghan, W.O. Renier, P. Rondot, M.M. Ryan, J. Seeger, J.A. Smeitink, G.C. Steenbergen-Spanjers, E. Wassmer, B. Weschke, F.A. Wijburg, B. Wilcken, D.I. Zafeiriou, R.A. Wevers, Tyrosine hydroxylase deficiency: a treatable disorder of brain catecholamine biosynthesis, *Brain*. 133 (Pt 6) (2010) 1810–1822.
- [3] L.E. Katus, S.J. Frucht, An unusual presentation of tyrosine hydroxylase deficiency, *J Clin Mov Disord.* 4 (2017) 18.
- [4] Y. Furukawa, S.J. Kish, S. Fahn, Dopa-responsive dystonia due to mild tyrosine hydroxylase deficiency, *Ann. Neurol.* 55 (1) (2004) 147–148.
- [5] R.J. Swaans, P. Rondot, W.O. Renier, L.P. Van Den Heuvel, G.C. Steenbergen-Spanjers, R. A. Wevers, Four novel mutations in the tyrosine hydroxylase gene in patients with infantile parkinsonism, *Ann. Hum. Genet.* 64 (Pt 1) (2000) 25–31.