

Oncology

Adult testicular rhabdomyosarcoma, a rare tumour arising in a teratoma with somatic type malignancy: A case report

C. Vanderstappen^{a,*}, E. Denies^a, C. Perdaens^b, H. Vandendriessche^a

^a Department of Urology, AZ Jan Portaels, Vilvoorde, Belgium

^b Department of Pathology, AZ Jan Portaels, Vilvoorde, Belgium



ARTICLE INFO

Keywords:

Rhabdomyosarcoma
Testicular malignancies
Somatic type malignancies

ABSTRACT

We describe a case of a 40 year old male who presented with a painless testicular mass, suspected for a testicular tumor. On microscopic examination, diagnosis of a testicular rhabdomyosarcoma was made, which is rare in an adult population.

Introduction

We describe a case of a testicular rhabdomyosarcoma in an adult male which is a rare and on microscopic examination difficult diagnosis.

Case presentation

We describe the case of a 40 year old male with a painless left testicular mass since one year. He is a firefighter with no relevant medical history. Whilst palpating the testis, a hard mass could be felt. Ultrasonography revealed a tumoral testicular mass.

Preoperative abdominal CT showed one para-aortic lymph node with calcifications (Fig. 1). Chest CT showed no evidence of lung metastasis. Tumormarkers (LDH, AFP, bHCG) were within normal ranges (LDH 232 U/L, hCG <0,2 IU/L, AFP 1,9 mcg/l)

A standard radical inguinal orchidectomy was performed.

Macroscopic examination showed a tumoral mass in the testis measuring 6 x 5,5x5,5 cm consisting of hard white tissue mixed with cysts and hemorrhagic zones.

Well differentiated (Fig. 2) and poorly differentiated (Fig. 3) rhabdomyoblasts were found on microscopic examination. There was a high mitotic activity and furthermore, there were other teratoma components, like cartilage, bone formation, respiratory epithelium and intestinal type glandulae, and GCNIS to be found. Intravascular trombi without evidence of tumor were present. There was no invasion of the tunica albuginea or vaginalis. Surgical margins were clear of tumor. Multiple immunohistochemical tests were performed. Desmine, Alpha-SMA and myogenin were positive in the rhabdomyoblasts. Prekeratin

was positive in teratoma elements. OCT-4 and D2-40 stainings showed evidence of germ cell neoplasia. Glial fibrillary acidic protein (GFAP) was negative.

Anatomopathological conclusion was that the tumor consisted of a teratoma with somatic-type malignancy, mainly rhabdomyosarcoma (of which 65% was well differentiated and 20% undifferentiated). The rest of the mass consisted of mature teratoma (13%) and germ cell neoplasia in situ (2%).

Multidisciplinary counseling postoperative in a tertiary centre suggested to re-evaluate the para-aortic lymph node by PET-CT. The node was not positive on this scan. Decision was made to perform an ipsilateral retroperitoneal lymphadenectomy (RPLND). A total of 24 para-aortic lymph nodes were harvested and examined, two of which were metastatic with teratoma components but no evidence of rhabdomyosarcoma. As expected on CT scan, the nodes contained chondroid and osteoid tissue. With these findings, we can conclude that our patient had a stage 2A non seminoma germ cell tumor (NSGCT). Finally, adjuvant chemotherapy, consisting of 9 cycles of VAC, was given after informing and consulting the patient.

Discussion

Testicular rhabdomyosarcoma is a rare entity.¹ According to the WHO Classification, somatic-type malignancies occur in 3–6% of testicular germ cell tumors of adults and of the sarcoma-group half of them consist of rhabdomyosarcomas.

A testicular rhabdomyosarcoma is a non-seminoma germ cell tumor (NSGCT), originating from a teratoma with somatic malignancy.² 7% of

* Corresponding author.

E-mail address: charlottevanderstappen@hotmail.com (C. Vanderstappen).

<https://doi.org/10.1016/j.eucr.2020.101385>

Received 9 July 2020; Received in revised form 6 August 2020; Accepted 12 August 2020

Available online 12 August 2020

2214-4420/© 2020 Published by Elsevier Inc. This is an open access article under the CC BY-NC-ND license (<http://creativecommons.org/licenses/by-nc-nd/4.0/>).

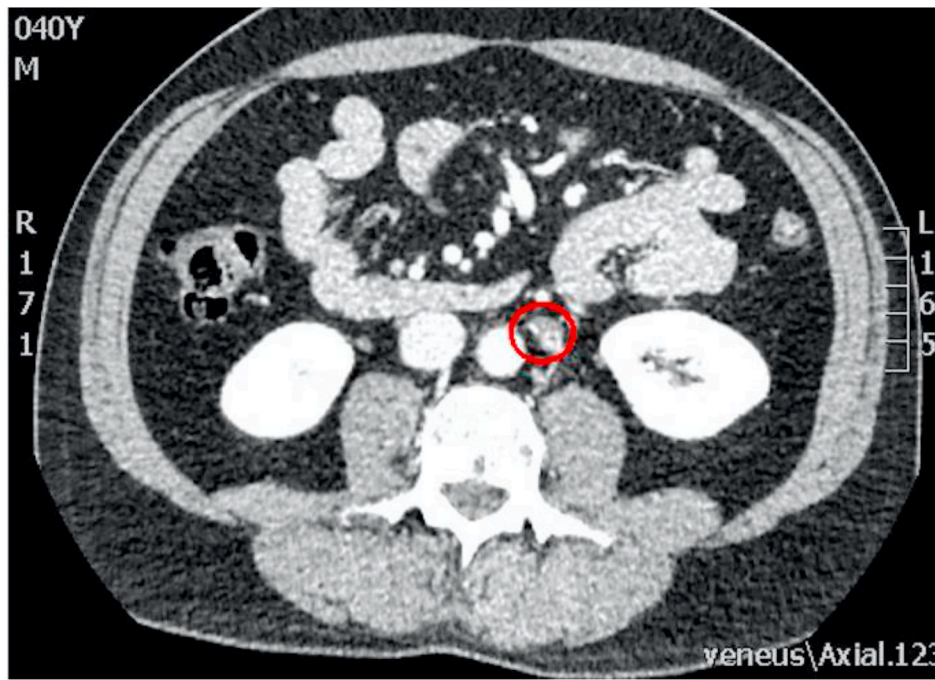


Fig. 1. Preoperative CT scan. Red circle: para-aortic lymph node, suspected for metastasis. (For interpretation of the references to colour in this figure legend, the reader is referred to the Web version of this article.)

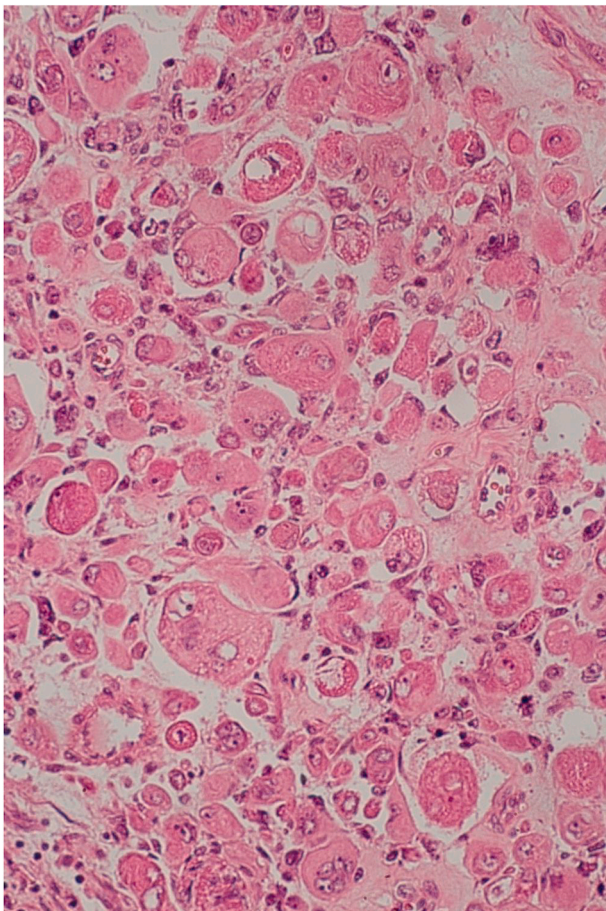


Fig. 2. Microscopic examination of the tumor: well differentiated rhabdomyosarcoma consisting of large cells with abundant eosinophilic cytoplasm and pleiomorphic nuclei and prominent nucleoli. These cells stained with Alpha-SMA, desmin and myogenin.

all rhabdomyosarcomas are of testicular origin.³

The clinical presentation of the tumor is the same as a classic testicular malignancy: a hard painless testicular mass. Diagnosis is made by ultrasonography and microscopic examination of the testis after radical orchidectomy by inguinal incision. Biopsy is not advised since it can cause metastatic spread.⁴

Further staging is done by determining pre-operative tumor markers, abdominal and chest CT. Further imaging (Magnetic resonance imaging (MRI) Brain, bone scan,..) is only necessary when there are clinical manifestations of metastasis.

Treatment

There is no absolute standard in the treatment of testicular rhabdomyosarcoma in the adult population.¹ Most of what we know, is based on gathered experiences in children. That experience shows that it is more aggressive, with a higher recurrence rate, in adults.⁴ Given its high malignant potential it is mandatory to start treatment as soon as possible. Treatment starts standard with a radical inguinal orchidectomy. Optionally, a testicular implant can be placed in the same time if requested by the patient. After radical orchidectomy, our patient underwent an ipsilateral RPLND. On microscopic examination, two lymph nodes were positive. Considering these data, a stage IIA disease was proposed. There is a general consensus that initial treatment should be chemotherapy in all advanced cases of NSGCT with the exception of stage IIA/B NSGCT disease consisting of post-pubertal teratoma without elevated tumor markers. In these cases, primary chemotherapy and primary RPLND are comparable options in terms of oncological outcome. They differ in early and long-term side effects and toxicity, allowing for involvement of the patient in selecting treatment of choice. Following RPLND, patients with PS-IIA or B characteristics can remain in follow up or they may receive two cycles of BEP. The cure rate with either approach will be close to 98%.² In this case, BEP wouldn't be an option because of our patient's profession and histopathological characteristics of the tumor. We do know that these tumors react to different types of chemotherapy.⁵ In case of metastatic teratoma and RMS, preference goes to VAC.

