

Contents lists available at [ScienceDirect](https://www.sciencedirect.com)

American Journal of Ophthalmology Case Reports

journal homepage: www.ajocasereports.com/

“Persistence of Memory” – Multimodal imaging of delayed sympathetic ophthalmia

Carl S. Wilkins^{a,b}, Masako Chen^{a,b}, Gaurav Chandra^{a,b}, Thomas O. Muldoon^a, Paul A. Sidoti^{a,b},
C. Michael Samson^c, Richard B. Rosen^{a,b,*}

^a Department of Ophthalmology, New York Eye and Ear Infirmary of Mount Sinai, 310 East 14th Street, New York, NY, 10003, USA

^b Department of Ophthalmology, Icahn School of Medicine at Mount Sinai, One Gustave L. Levy Place, New York, NY, 10029, USA

^c Department of Ophthalmology, Manhattan Eye, Ear, and Throat Hospital, Zucker School of Medicine at Hofstra/Northwell Health, 210 East 64 Street, New York, NY, 10021, USA

ARTICLE INFO

Keywords:

Retinal detachment
Vitreotomy
Transscleral cyclophotocoagulation
Sympathetic ophthalmia
OCT-A
Dalen-Fuchs nodule

ABSTRACT

Purpose: To describe a case of late post-surgical sympathetic ophthalmia documented with multimodal imaging. **Observations:** A 74-year-old male presented to the urgent care of the New York Eye and Ear Infirmary with blurry vision and discomfort in his left eye for three weeks. His vision was 20/50, with intraocular pressure of 13 mmHg, and slit lamp examination was significant for conjunctival congestion, 1+ anterior segment cell and flare, and diffuse keratic precipitates. His right eye was no light perception with a condensed hyphema, intraocular lens and inferonasal tube. His medical history included coronary artery bypass, prostate cancer, hyperlipidemia, and hypertension. His ocular history included blunt trauma to the right eye at age 11 with development of a traumatic macular hole and later rhegmatogenous retinal detachment at age 53, repaired with multiple vitreoretinal procedures. He developed glaucoma in the right eye and was treated with a tube shunt and ultimately transscleral cyclophotocoagulation (TSCPC) 7 years later, 13 years prior to his presentation of the left eye. Dilated fundus examination of his left eye revealed diffuse chorioretinal folds in the macula without any discrete chorioretinal lesions. Ultrasound of the right showed serous macular detachments with scleral thickening. Presumptive diagnosis of sympathetic ophthalmia was made and oral corticosteroid therapy was initiated. Subsequent SD-OCT and en-face OCT-A demonstrated Dalen-Fuchs nodules within the macula underlying areas of resolved serous detachment, after 6 weeks of oral steroids and initiation of immunomodulatory therapy (IMT). **Conclusions:** Sympathetic ophthalmia may rarely present with very delayed onset, and TSCPC is an uncommon inciting event. These patients may develop serous detachment, choroidal folds and inflammatory nodules identifiable on exam and multimodal imaging, which can resolve when treated appropriately. OCT-A may provide utility in monitoring response to immunosuppressive treatment in these patients.

1. Introduction

Sympathetic ophthalmia (SO) is characterized by bilateral, granulomatous uveitis that can develop following ocular surgery or uveal trauma to one eye.¹ While the exact pathogenesis is unknown, the disease is thought to be an autoimmune response to uveal antigens exposed to Langerhans cells of the conjunctiva, causing both the traumatized and sympathizing eye to be affected, and potentially leading to bilateral visual loss and blindness.¹ Current data suggests that ocular surgery, particularly vitreoretinal surgery, presents a greater risk factor for SO than accidental trauma, with up to 90% of cases reported within 1 year

of the stimulating injury.²

Multimodal imaging of posterior uveitis is rapidly becoming standard of care for identification of active lesions and monitoring response to treatment. Prior to OCTA, FA and ICG imaging were the gold standard, and both remain indispensable tools for management of uveitis. OCT-A, however, provides a non-invasive way to evaluate capillary perfusion in the retina and choroid. Prior studies have identified decreased retinal capillary density in active birdshot chorioretinopathy, decreased choriocapillaris flow in acute multifocal placoid pigment epitheliopathy, which reconstitutes after treatment, and inflammatory choroidal neovascular membranes in punctate inner choroiditis and

* Corresponding author. New York Eye and Ear Infirmary of Mount Sinai, 310 E 14th Street, New York, NY, 10003, USA.

E-mail address: rosen@nyee.edu (R.B. Rosen).

<https://doi.org/10.1016/j.ajoc.2022.101572>

Received 27 August 2021; Received in revised form 13 April 2022; Accepted 1 May 2022

Available online 18 May 2022

2451-9936/© 2022 Published by Elsevier Inc. This is an open access article under the CC BY-NC-ND license (<http://creativecommons.org/licenses/by-nc-nd/4.0/>).

multifocal choroiditis.⁴

We present an uncommon case of delayed onset SO appearing 13 years after transscleral cyclophotocoagulation, which was managed using serial multimodal imaging.

2. Case report

A 74-year-old African American male presented with blurry vision in his left eye for three weeks. His past ocular history is significant for a traumatic macular hole in his right eye since age 11. His right eye subsequently developed a total rhegmatogenous retinal detachment, requiring pars plana vitrectomy (PPV), scleral buckle placement, and C3F8 gas tamponade 21 years prior to presentation. One year later he developed recurrent detachment repaired by PPV and silicone oil. He subsequently underwent cataract extraction, and a Baerveldt glaucoma drainage implant for secondary open-angle glaucoma. Seven years later, 13 years prior to his current presentation, the patient underwent transscleral cyclophotocoagulation for uncontrolled intraocular pressure in his right eye. His left eye had no significant history.

Examination revealed a visual acuity of no light perception (NLP) in the right eye (OD) and 20/50 in the left eye (OS). Intraocular pressures were 6 mmHg OD and 13 mmHg OS. Slit lamp examination OD revealed a condensed hyphema, deep anterior chamber with inferonasal tube shunt, a dense pupillary membrane and posterior chamber intraocular lens, with no view to the posterior segment. Anterior segment examination OS revealed mild conjunctival congestion, keratic precipitates, and grade 1+ cell without flare. Dilated fundus exam was significant for optic nerve head hyperemia and prominent chorioretinal folds without any identifiable chorioretinal lesions. His ocular ultrasound demonstrated choroidal thickening of both eyes. Spectral domain optical coherence tomography (SD-OCT) demonstrated thickened choroid with chorioretinal folds without subretinal fluid (Fig. 1A).

The patient was started on topical prednisolone acetate 1% every 2 hours while awake. An initial uveitic workup was obtained including fluorescent treponemal antibody, interferon-gamma release assay, Lyme IgG/IgM western blot assay, and a chest x-ray. All results returned within normal limits.

At two-weeks follow-up, the patient's visual acuity OS worsened to 20/80 and SD-OCT macula revealed a new serous retinal detachment (Fig. 1B) Fluorescein and indocyanine green angiography revealed multiple hypofluorescent spots in the macula (Fig. 2). The patient was started on 60 mg of oral prednisone daily with a weekly taper for presumed sympathetic ophthalmia, with a bridge to oral methotrexate. Two weeks after initiating therapy, the patient's visual acuity improved to 20/30 with resolution of the serous detachment (Fig. 1C).

SD-OCT revealed multiple hyperreflective, drusenoid elevations overlying the retinal pigment epithelium (Fig. 3). OCT-angiography segmented at the outer retina and choroid help localize and distinguish these lesions as Dalen-Fuchs nodules (Fig. 4). At six-week follow-up, these lesions had improved (Fig. 5). The patient remained stable

with 20/30 vision OS on methotrexate.

3. Discussion

While early reports suggested that SO occurs within several months of stimulus, more recent data shows that 50–90% of all SO cases occur within one year.³ Late presentation of SO has been reported up to 66 years after initial injury.⁵ Progress made in vitreoretinal surgical diagnostics and tools has led to an increase in number of procedures performed, and most cases of SO now occur following retinal surgery.² The mainstay of treatment is systemic immunosuppression; oral corticosteroids are the first-line treatment, and many patients need to be transitioned to IMT.³ While our patient responded rapidly to oral corticosteroids, the decision was made to start early IMT due to the fellow eye having NLP vision.

SD-OCT and OCT-angiography (OCT-A) are newer imaging modalities that may be useful in the diagnosis and management of sympathetic ophthalmia. FA and ICG in our patient show multiple hypofluorescent spots and SD-OCT reveals irregular, hyperreflective elevations overlying the RPE corresponding to those areas of blockage on FA and ICG. These findings represent Dalen-Fuchs nodules, which have been found in up to 44% of patients at presentation but developed on follow-up examination in our patient.² These nodules are presumed focal, inflammatory infiltrates within the choroid or between RPE and Bruch's membrane.⁴ OCT-A with associated en-face images can help further localize these lesions, as in our patient. Additionally, regions of reduced capillary density in the retinal capillary layers and choriocapillaris on OCT-angiography suggest localized areas of ischemia during the active phase of inflammation. These flow defects can be followed over time to assess for adequate levels of suppression, though stability rather than reconstitution of vascular density may be the goal.^{4,6}

After an initial trauma and a 42-year hiatus, our patient underwent multiple vitreoretinal and glaucoma surgeries in the fellow eye, the most recent of which was transscleral cyclophotocoagulation (TSCPC) and presented with sympathetic ophthalmia 13 years later. The breakdown of the blood-aqueous barrier resulting induced by TSCPC may have provided the uveal trauma necessary to initiate sympathetic ophthalmia. Ten patients with sympathetic ophthalmia after TSCPC have been described in the literature, with the longest recorded time to development being 15 years.^{5,7,8} All patients having undergone TSCPC have also had a history of other ocular surgeries. Laser treatment, in this context, may represent a triggering factor for the development of SO in eyes with already compromised blood-retinal barriers, even when the initial stimuli occurred greater than 10 years prior.⁷

4. Conclusions

Sympathetic ophthalmia is an uncommon but blinding disease if not effectively managed and should be considered in the differential diagnosis for all patients who present with uveitis following ocular surgery

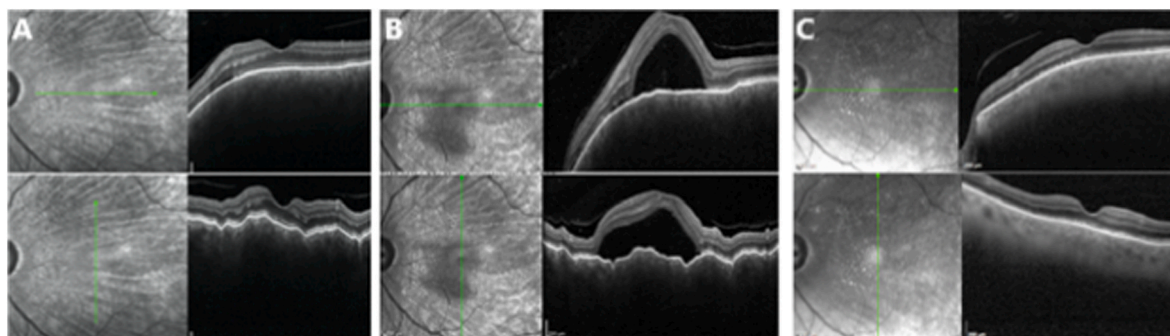


Fig. 1. SD-OCT images demonstrating choroidal folds at presentation (A), with new serous retinal detachment of the central macula 2 weeks later (B), both of which are resolved following 2 weeks of treatment with oral corticosteroid (C).

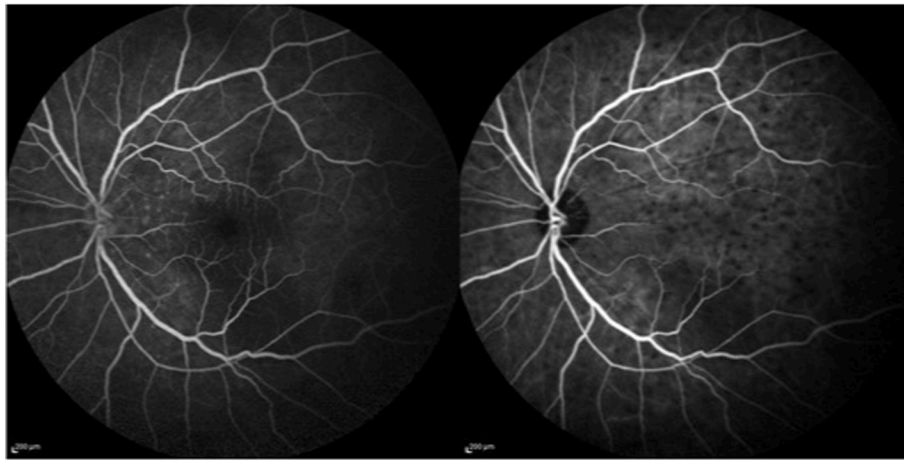


Fig. 2. Late phase FA (left) and ICG (right) demonstrating pinpoint areas of leakage and multifocal hypofluorescent spots in the macula, respectively.

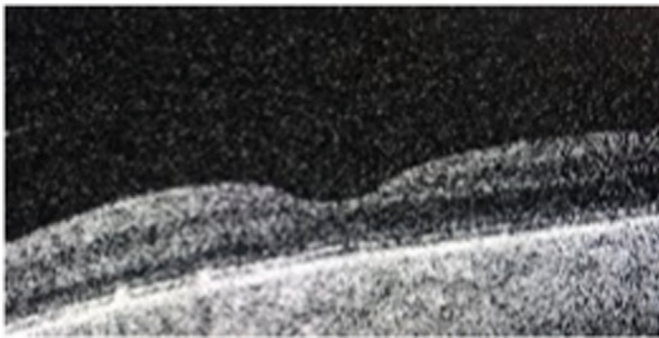


Fig. 3. SD-OCT of single raster scan demonstrating multiple hyper-reflective deposits in the nasal outer retina with ellipsoid zone disruption.

or trauma. Transscleral cyclophotocoagulation may rarely trigger such an inflammatory response. Though SO is most reported within 1 year of an inciting event, it has occasionally been described to occur greater than 10 years later. Newer imaging modalities can play a key role in the diagnosis and management of this condition, providing in-vivo biomarkers with which to monitor response to treatment. OCTA may demonstrate resolution of flow voids as inflammation improves. In those patients with inflammatory nodules, en-face OCT may be used to monitor for resolution, indicating adequate level of immunosuppression.

Patient Consent: All patient identifiers and information contained within this manuscript have been made anonymous in compliance with institutional and HIPAA policies. No identifiable patient information or images are included in this report, therefore, patient consent to publish was not obtained. This manuscript is adherent to the principles of the Declaration of Helsinki.

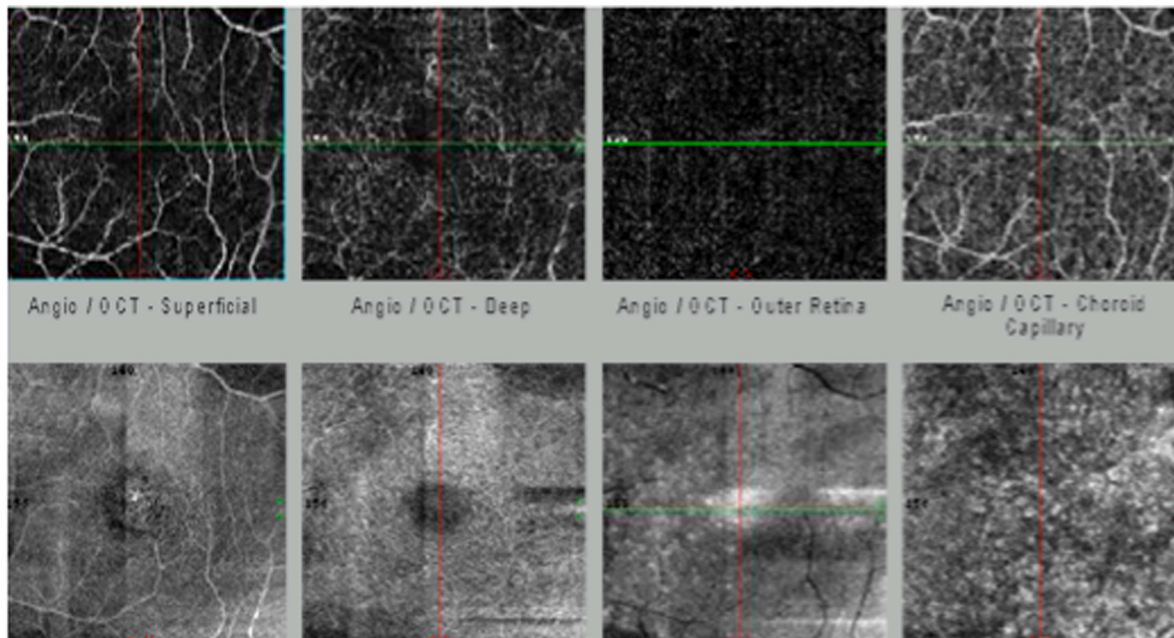


Fig. 4. OCT Angiography demonstrating perifoveal flow disturbances during active inflammatory phase (top left and top-middle left), with corresponding en-face OCT slabs localizing the nodular deposits to the RPE-Bruch' interface (top/bottom far right). Additionally, flow voids can be seen in the deep retinal capillary plexus and the choriocapillaris, indicating active inflammation at time of imaging. Resolution of flow voids occurs with immunosuppression.

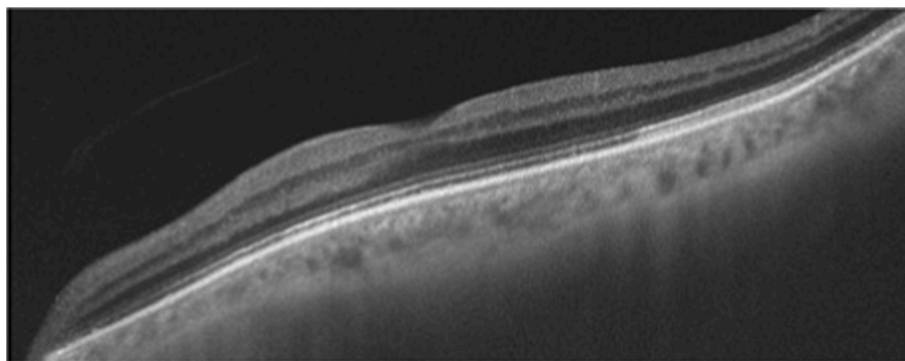


Fig. 5. SD-OCT single line raster following successful suppression of inflammation, demonstrating resolution of Dalen-Fuchs nodules in the nasal macula with restoration of normal laminations.

Intellectual property

We confirm that we have given due consideration to the protection of intellectual property associated with this work and that there are no impediments to publication, including the timing of publication, with respect to intellectual property. In so doing we confirm that we have followed the regulations of our institutions concerning intellectual property.

Research ethics

We further confirm that any aspect of the work covered in this manuscript that has involved human patients has been conducted with the ethical approval of all relevant bodies and that such approvals are acknowledged within the manuscript.

Authorship

All listed authors meet the ICMJE criteria. We attest that all authors contributed significantly to the creation of this manuscript, each having fulfilled criteria as established by the ICMJE.

We confirm that the manuscript has been read and approved by all named authors.

We confirm that the order of authors listed in the manuscript has been approved by all named authors.

Contact with the editorial office

This author submitted this manuscript using his/her account in EVIDENCE.

We understand that this Corresponding Author is the sole contact for the Editorial process (including EVIDENCE and direct communications with the office). He/she is responsible for communicating with the other authors about progress, submissions of revisions and final approval of proofs.

We confirm that the email address shown below is accessible by the Corresponding Author, is the address to which Corresponding Author's EVIDENCE account is linked, and has been configured to accept email from

the editorial office of American Journal of Ophthalmology Case Reports: Farzan.gorgani@gmail.com

Funding

None of the authors have received funding toward the creation of this manuscript.

Declaration of competing interest

The following authors report no potential conflicts of interest: G.C, M.C., T.O.M, P.A.S, C.M.S.

R.B.R. R. reports the following disclosures: Boehringer-Ingelheim (C), Advanced Cellular Technologies (C), Genentech- Roche (C), Nano-Retina (C), OD-OS (C), Optovue (C), and Regeneron (C), Opticology (I), Guardian Health(I)

R.B.T. C.S.W. reports the following disclosures: EyePoint Pharmaceuticals (C)

References

1. Patel S, Dodds E, Ehandi L, et al. Long-term, drug-free remission of sympathetic ophthalmia with high-dose, short-term chlorambucil therapy. *Ophthalmology*. 2014; 121:596–602.
2. Kilmartin D, Dick A, Forrester J. Prospective surveillance of sympathetic ophthalmia in the UK and Republic of Ireland. *Br J Ophthalmol*. 2000;84:259–263.
3. Cunningham ET, Kilmartin D, Agarwal M, Zierhut M. Sympathetic ophthalmia. *Ocul Immunol Inflamm*. 2017;25(2):149–151.
4. Tranos P, Karasavvidou EM, Gkorou O, Pavesio C. Optical coherence tomography angiography in uveitis. *J Ophthalmic Inflamm Infect*. 2019;9(1):21. Published 2019 Dec 23.
5. Zaharia MA, Lamarche J, Laurin M. Sympathetic uveitis 66 years after injury. *Can J Ophthalmol*. 1984 Aug;19(5):240–243.
6. Brar M, Sharma M, Grewal S, Grewal DS. Treatment response in sympathetic ophthalmia as assessed by widefield OCT angiography. *Ophthalmic Surg Lasers Imaging Retina*. 2018;49(9):726–730.
7. Albahlal A, Dhibi H, Shahwan S, Khandekar R, Edward D. Sympathetic ophthalmia following diode laser cyclophotocoagulation. *Br J Ophthalmol*. 2014;98:1101–1106.
8. Tan XL, Seen S, Dutta Majumder P, et al. Analysis of 130 cases of sympathetic ophthalmia - a retrospective multicenter case series. *Ocul Immunol Inflamm*. 2019;27(8):1259–1266.