

The Rectus Abdominis Perforator Turndown Flap for Preserving Rectus Continuity: A DIEP Alternative?

Warren M. Rozen, MBBS,
BMedSc, MD, PhD, FRACS*†
Robert Phan, MBBS*†
Marc A. Seifman, MBBS,
BMedSc*†
Lisa Ellis, MBBS*†
David J. Hunter-Smith, MBBS,
MPH, FRACS, FACS*†

Background: The deep inferior epigastric artery perforator (DIEP) flap for breast reconstruction has been popularized over the transverse rectus abdominis myocutaneous (TRAM) flap, as it spares rectus abdominis muscle and has low donor site morbidity. This progression to muscle preservation, however, has been associated with an increased difficulty in vascular dissection, perfusion-related complications, and lengthier surgical times. We pilot a technique that may achieve the benefits of the TRAM flap in terms of ease of dissection and vascularity, with the benefits of the DIEP flap in terms of maintaining rectus abdominis continuity.

Methods: A cohort of six consecutive patients underwent a free TRAM flap for reconstructive surgery. All patients underwent a segmental, periumbilical harvest of rectus abdominis muscle as part of flap design, and the segmental defect was reconstructed with an innervated rectus abdominis perforator turndown (RAPT) flap harvested supraumbilically. Postoperative assessment of rectus continuity was performed clinically, with muscle electromyography and ultrasound.

Results: In all six cases, there was successful TRAM flap transfer, with no flap-related complications. Rectus abdominis muscle reconstruction with the RAPT flap was achieved, with continuity and function of the rectus muscle confirmed.

Conclusions: We describe the innervated RAPT flap for reconstitution of rectus continuity after TRAM flap harvest. This technique may achieve the benefits of the TRAM flap in terms of ease of dissection and flap vascularity, and the benefits of the DIEP flap in terms of maintaining rectus abdominis continuity. (*Plast Reconstr Surg Glob Open* 2022;10:e4037; doi: [10.1097/GOX.0000000000004037](https://doi.org/10.1097/GOX.0000000000004037); Published online 25 January 2022.)

INTRODUCTION

Breast reconstruction with lower abdominal wall free flaps has become the standard for autologous breast reconstruction, with techniques evolving to achieve improvements in donor site morbidity, while maintaining the aesthetic and benefits of the abdominal wall integument. The transverse rectus abdominis myocutaneous (TRAM) flap has been used the longest for this purpose, and although this technique is associated with short operative

times and robust vascularity, it does require compromise of rectus abdominis muscle, and thus newer techniques have evolved. One such evolution of these techniques, the muscle-sparing TRAM flap has been used widely, and different classification systems have been used to describe the portion of rectus muscle spared during flap harvest.^{1,2} The deep inferior epigastric artery perforator (DIEP) flap has been further developed as an extension of this concept, becoming the gold standard procedure for breast reconstruction, as no muscle is included in the flap and, thus, the maximal amount of muscle is spared. First described in 1989 by Koshima and Soeda and developed for breast reconstruction by Allen and Treece in 1994,^{3,4} many studies have highlighted that flap vascularity can be maintained with the DIEP flap, while providing an improvement in donor-site morbidity over the previous methods.^{2,5–13} However, abdominal wall weakness and abdominal bulge still remain significant complications. Some studies comparing the muscle-sparing TRAM with the DIEP flap have suggested no significant improvement in abdominal wall morbidity, suggesting that the maintenance of rectus

From the *Department Surgery, Peninsula Clinical School, Central Clinical School, Faculty of Medicine, Monash University, Frankston, Victoria, Australia; and †Monash University Plastic and Reconstructive Surgery Group (Peninsula Clinical School), Peninsula Health, Frankston, Victoria, Australia.

Received for publication July 27, 2021; accepted November 9, 2021.

Copyright © 2022 The Authors. Published by Wolters Kluwer Health, Inc. on behalf of The American Society of Plastic Surgeons. This is an open-access article distributed under the terms of the [Creative Commons Attribution-Non Commercial-No Derivatives License 4.0 \(CCBY-NC-ND\)](https://creativecommons.org/licenses/by-nc-nd/4.0/), where it is permissible to download and share the work provided it is properly cited. The work cannot be changed in any way or used commercially without permission from the journal.

DOI: [10.1097/GOX.0000000000004037](https://doi.org/10.1097/GOX.0000000000004037)

Disclosure: The authors have no financial disclosures or conflicts of interest to declare.

abdominis continuity is more important than just the sacrifice of a limited segment of rectus abdominis, with damage to the motor innervation of rectus abdominis muscle during the raising of the flap postulated as a cause for more widespread donor morbidity.^{1,14,15}

Although much emphasis has been placed on changing flap design from the TRAM flap to improved donor site morbidity, little has been described in modifying the donor site itself after TRAM flap harvest to enable improvements in donor site outcomes. Given this, an operative approach that maintains caudocranial continuity of the rectus abdominis muscle, while maximizing perforator inflow and minimizing operative time was designed. We describe the innervated rectus abdominis perforator turn-down (RAPT) flap for reconstitution of functional rectus continuity after TRAM flap harvest, and present a pilot feasibility study highlighting the technique and operative approach.

METHODOLOGY

Patients

Six consecutive patients underwent reconstructive surgery, planned with a lower abdominal wall free flap, with this cohort planned prospectively for a pilot study in the assessment and feasibility of the RAPT flap. This cohort comprised five patients undergoing unilateral breast reconstruction, and one patient undergoing reconstruction of the forearm integument (following necrotizing fasciitis). Donor site selection was based on individual patient suitability, with the abdominal donor site optimal for the breast reconstruction cases, and the thinnest of the fasciocutaneous options for the forearm reconstruction (significantly thinner than the thigh donor). The mean patient age was 56 (range 39–67), and patient BMI range was 24–29.

Technique

Perforator mapping with CTA was performed in all cases, with all CTAs performed at a single institution using a Siemens Somatom Sensation 64 multi detector row CT scanner (Siemens Medical Solutions, Erlangen, Germany). Three dimensional and multiplanar images were generated, achieved by reformatting into maximum intensity projection (MIP) and volume-rendered technique (VRT) reconstructions using commercially available software (Siemens Syngo InSpace. Version: InSpace2004A_PRE_19).

Patients were selected based on a suitable perforator configuration. Where there was an overtly large (>1.5 mm diameter) periumbilical perforator, a DIEP flap was preferred, and such patients were excluded. Included patients had suitable periumbilical perforators (between 0.8 and 1.4 mm) as the basis of supply to the flap, and with these a muscle-sparing TRAM flap was designed, utilizing the full width, but a limited length of rectus abdominis muscle. A schematic representation of this approach is shown in [Figure 1A](#).

Immediately before TRAM flap transfer, the caudocranial length of rectus muscle being harvested was

Takeaways

Question: Is it possible to reconstitute continuity of the rectus abdominis muscle after TRAM flap harvest, as a means to achieving the benefits of the TRAM flap in terms of ease of dissection and flap vascularity, and the benefits of the DIEP flap in terms of maintaining rectus abdominis continuity.

Findings: We describe the segmental defect of rectus muscle reconstructed with an innervated RAPT flap, harvested supraumbilically.

Meaning: This technique may achieve the benefits of the TRAM flap in terms of ease of dissection and flap vascularity, and the benefits of the DIEP flap in terms of maintaining rectus abdominis continuity.

measured, such that reconstruction could be planned with all muscle fibers maintaining their resting lengths. After flap transfer, the remaining rectus abdominis muscle stumps were then prepared for reconstruction of rectus continuity. Cranially, the rectus abdominis was split longitudinally along its midportion, and an intercostal neurovascular bundle identified for neurovascular supply (see [Fig. 1B](#)). This muscle segment was then islanded (although not essential in all cases) to the premeasured length, and the flap transferred caudally toward the segmental defect in rectus abdominis from initial TRAM flap harvest. Movement of the flap while maintaining neurovascular supply was technically challenging but achievable in all cases. This is achieved with careful skeletonization of the pedicle, and careful selection of the transfer technique of choice. This transfer was most readily achieved as a turn-down/turnover flap, but was suitable for direct transposition if the defect was suitably sized to limit pedicle tension. The caudal and cranial native rectus stumps were freed of loose attachments to the limits of the rectus sheath and the transferred innervated RAPT muscle flap was inset to the native rectus stumps using a size 0 permanent, braided suture ([Fig. 1C](#)). The use of a prolene mesh deep to the rectus abdominis muscle was used in all cases, as is our standard practice in all DIEP and TRAM flaps.

Assessments of Outcome

An intraoperative assessment was performed, with vascular supply to the flap confirmed by muscle edge bleeding, and innervation confirmed using an intraoperative nerve stimulator. Upon nerve localization, intraoperative nerve stimulation was undertaken with the use of a surgical nerve locator (Vari-Stim III Surgical Nerve Locator, Medtronic Xomed Inc, Fla.). This was a battery-powered, single-use device, with adjustable current settings and a subdermal needle as the grounding (anode) electrode. Intraoperative nerve stimulation for nerve localization has been utilized for many years, with the current device shown to be safe and effective for clinical use.¹⁶ In all cases, a setting of 0.5 mA was used, with a “current flow” light enabling confirmation of current flow. Nerve stimulation enabled the dual function of confirming the structures

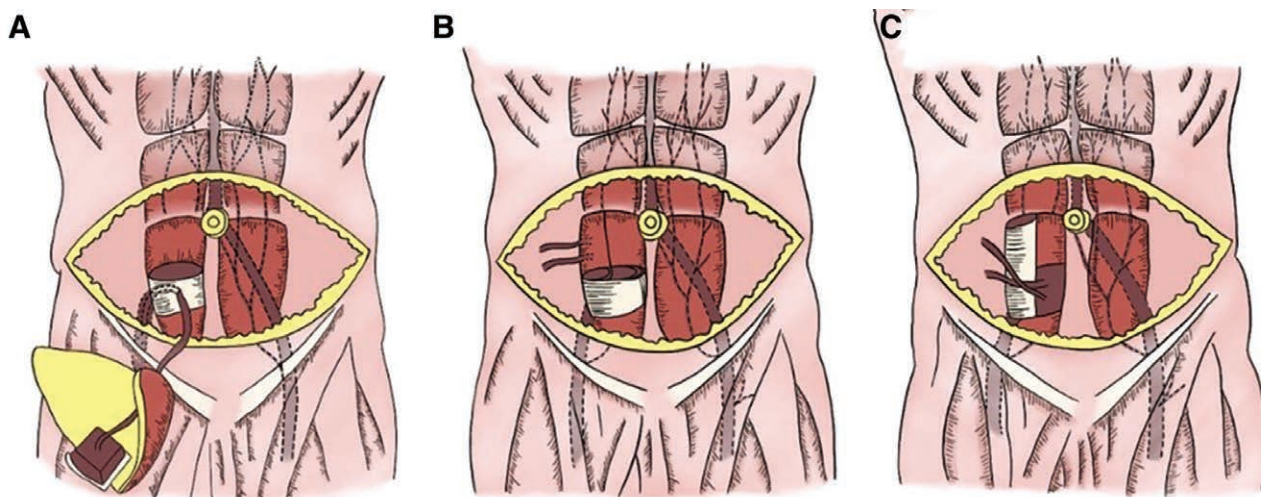


Fig. 1. Schematic representation of the sequences in RAPT flap harvest. A, An MS TRAM flap is harvested based on periumbilical perforators. B, After TRAM flap transfer, the cranial rectus abdominis stump is split longitudinally along its midportion, and an intercostal neurovascular bundle identified for neurovascular supply. C, This muscle segment is then transferred caudally to reconstruct the segmental defect in rectus abdominis from initial TRAM flap harvest.

identified as nerves, as well as to quantify the motor distribution of innervation.

Postoperative assessment of rectus continuity was performed clinically, through palpation and crude functional assessment with flexion performed as a sit-up in an outpatient setting, given that this was a pilot study of the technique, with the inclusion of formal functional testing and a physical therapist reserved for a larger trial of the technique. Testing with both muscle electromyography and ultrasound were performed at 6 weeks postoperatively.

RESULTS

In all six cases, there was successful TRAM flap transfer, with no flap-related complications, and rectus abdominis muscle reconstruction with the RAPT flap was also successfully achieved in all cases. The rectus abdominis caudocranial defect after TRAM flap harvest (equaling the caudocranial height of the RAPT flap) had a mean of 4.8 cm (range 4.1–5.5 cm).

Continuity and function of the rectus muscle was confirmed in all cases, with clinical assessment, imaging, and electromyographic studies all demonstrating successful functional transfer. Intraoperative nerve stimulation was performed in each case, confirming innervation with an intercostal nerve, and an adjacent intercostal artery visualized in each case, and the flap confirmed as being vascularized by active bleeding. The results of postoperative ultrasound and electromyography were uniform across all six cases, demonstrating continuity of the rectus muscle flap segment visualized and contractility confirmed on dynamic ultrasound. Long-term assessment of this was not sought in this study, with long-term ultrasound and MRI (for atrophy) planned in further studies. Electromyography similarly confirmed innervation, with normal motor unit morphology and recruitment, and muscle activity within the flap segment comparable to the contralateral side.

There were no donor site complications or complications from RAPT flap harvest. Case examples are demonstrated in [Figures 2–13](#).

DISCUSSION

Abdominal wall weakness, lower abdominal bulge, and abdominal wall herniation are all potential complications of breast reconstruction flaps based on the deep inferior epigastric artery (DIEA). Improvements in operative techniques over time have attempted to diminish this abdominal wall morbidity through a variety of means. The most significant of these have been the progression of lower abdominal flaps from muscle-containing to muscle-sparing. However despite these significant changes, abdominal wall dysfunction still remains a significant operative complication.

Early abdominal wall flaps comprised myocutaneous flaps based on one or both DIEAs, and comprised the inclusion of one or both rectus abdominis muscles in their entirety. These flaps were associated with significant abdominal wall morbidity. Bipedicled flaps utilizing

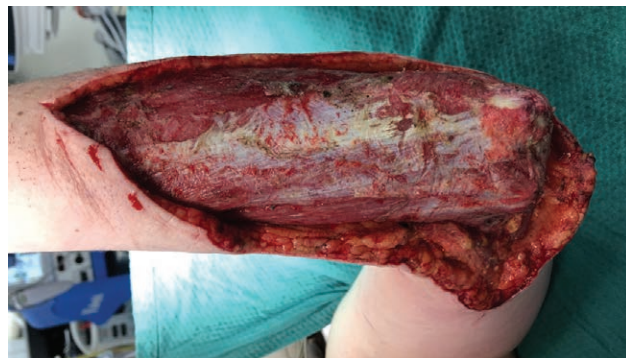

Fig. 2. Clinical photograph of the soft tissue defect of the forearm.

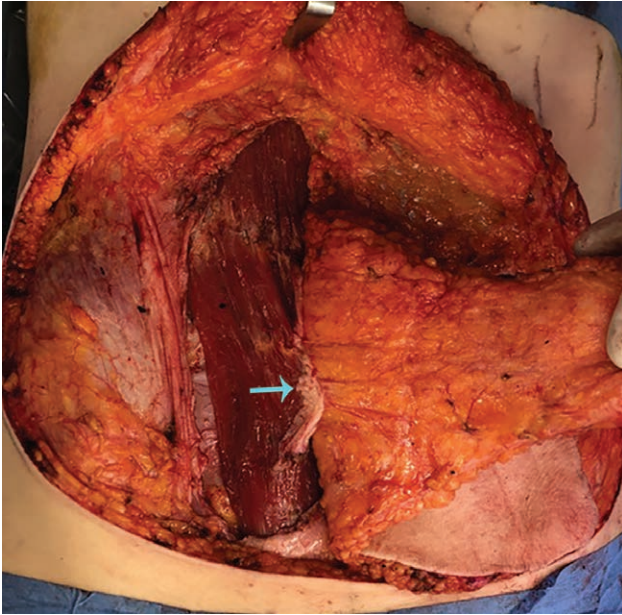


Fig. 3. Operative approach: TRAM flap raised on periumbilical perforators (blue arrow).

both rectus muscles were associated with abdominal wall weakness and bulge in a significant majority of patients. Hartrampf and Bennett demonstrated postoperative trunk weakness in 64% of bipedicle TRAM flap patients

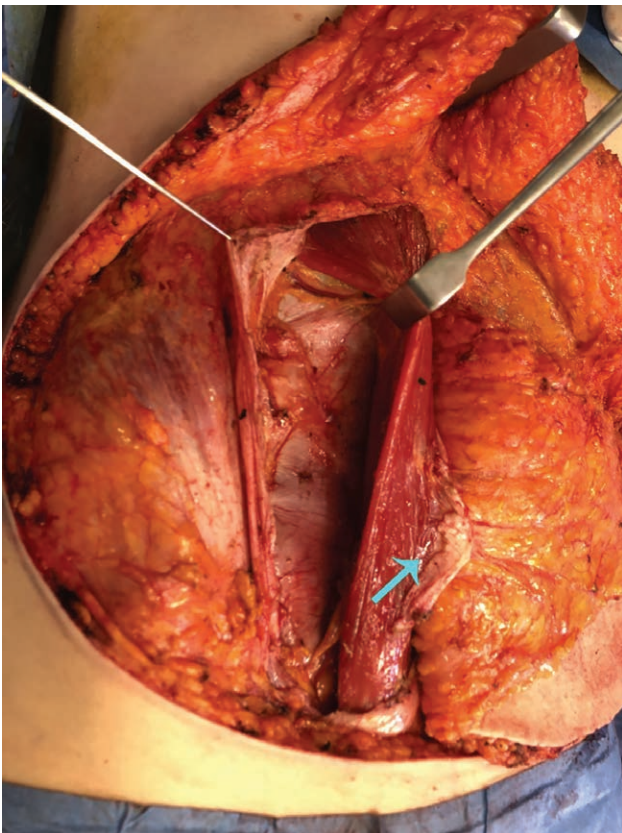


Fig. 4. Intercostal neurovascular bundle identified for neurovascular supply to the supraumbilical RAPT flap (green arrow).

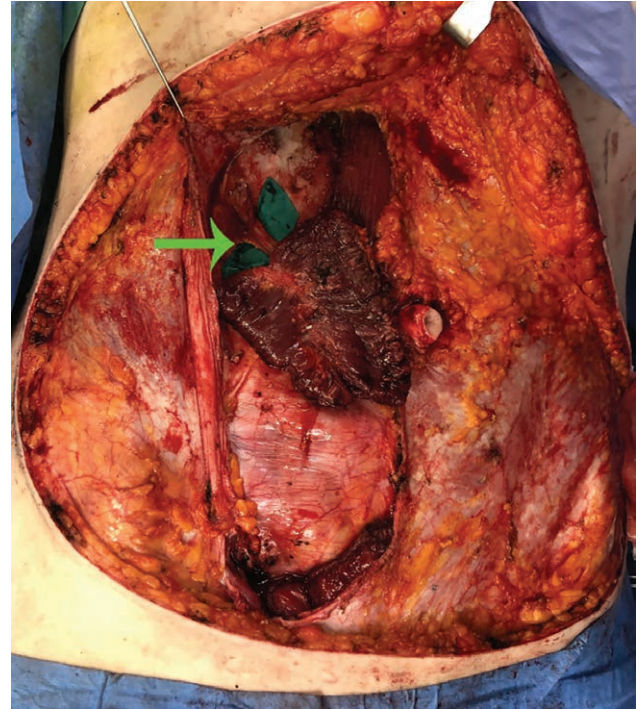


Fig. 5. RAPT flap raised based on the cranial rectus abdominis stump split longitudinally, with intercostal neurovascular bundle intact (green arrow).

compared with 17% of unipedicle TRAM flaps.¹⁷ Other authors reiterated significant functional deficit, using a range of measures for abdominal wall function.¹⁸⁻²² The inclusion of a single rectus abdominis muscle, although

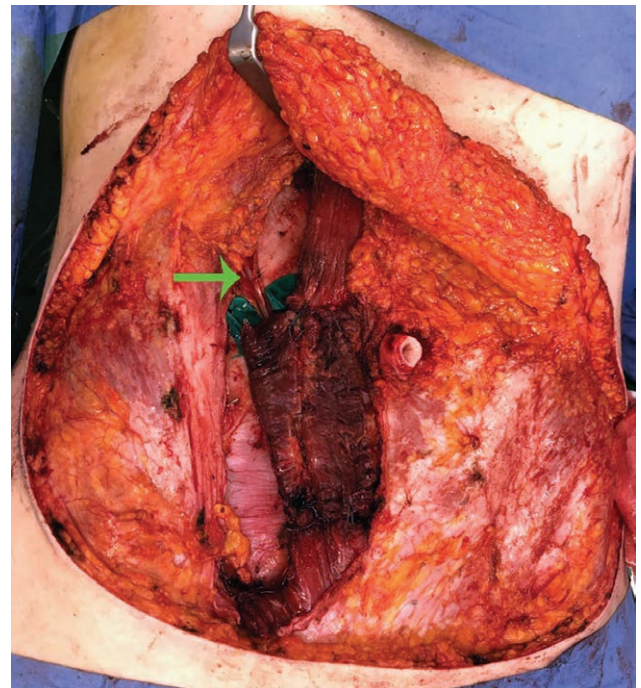


Fig. 6. RAPT flap transferred caudally to reconstruct the segmental defect in rectus abdominis from initial TRAM flap harvest.

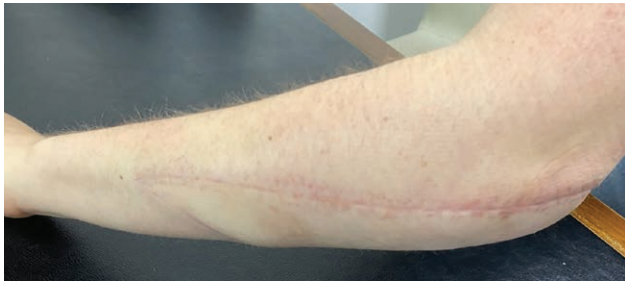

Fig. 7. Clinical photograph at 3 months postoperative.

demonstrating improvement over the bipedicle technique, has been shown to result in marked abdominal wall morbidity, with the incidence of lower abdominal bulge reaching 82% in one study.²³

The free TRAM flap was the first in a progression of techniques that spare rectus abdominis muscle. This required only the inclusion of the lower part of rectus abdominis muscle, and was associated with improvements

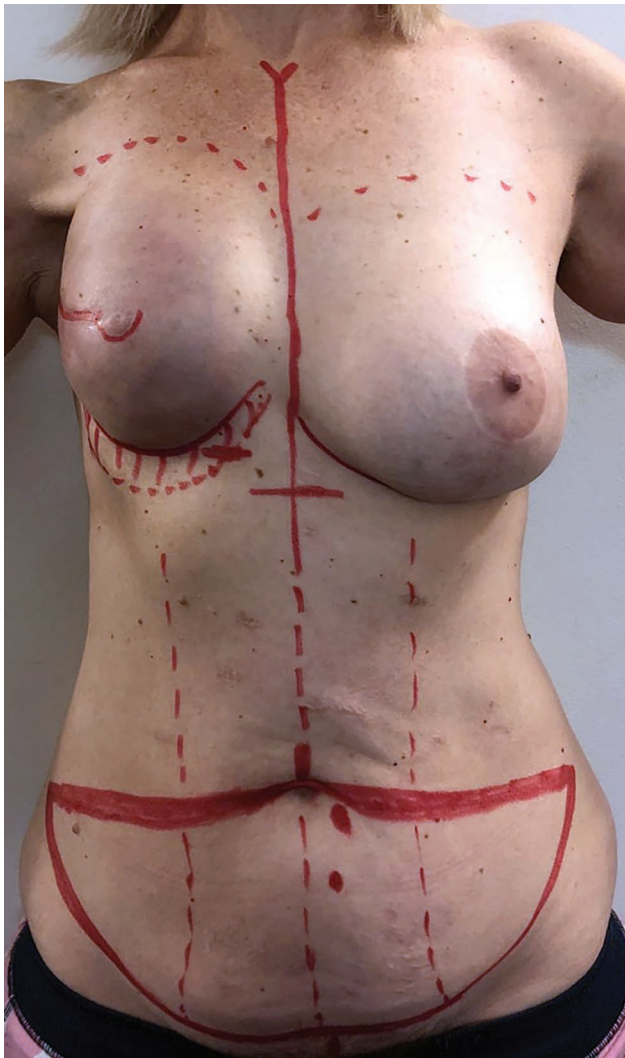

Fig. 8. Clinical photograph before autologous right breast reconstruction.

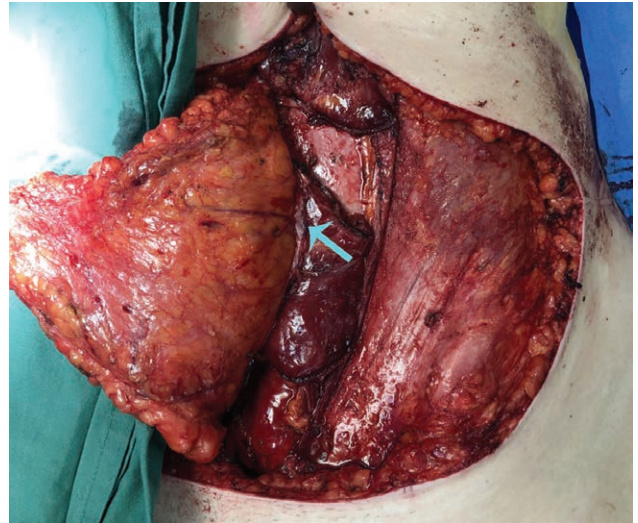


Fig. 9. Operative approach: TRAM flap raised on periumbilical perforators (blue arrow).

in reported donor site sequelae.^{23–25} In a move to further diminish abdominal wall morbidity, TRAM flaps based on DIEA perforators were subsequently designed with increasingly smaller portions of muscle included in the flap, each designed to capture perforators while sparing maximal muscle. These “muscle-sparing” (MS) TRAM flaps, described by Nahabedian et al, refer to preservation of a lateral strip of rectus abdominis (MS1) or both a lateral and medial strip (MS2).² This classification was further extended by Bajaj et al, describing MS1 flaps as preserving a lateral strip (MS1-L) or medial strip (MS1-M). These techniques for muscle preservation have demonstrated significant improvements in functional donor

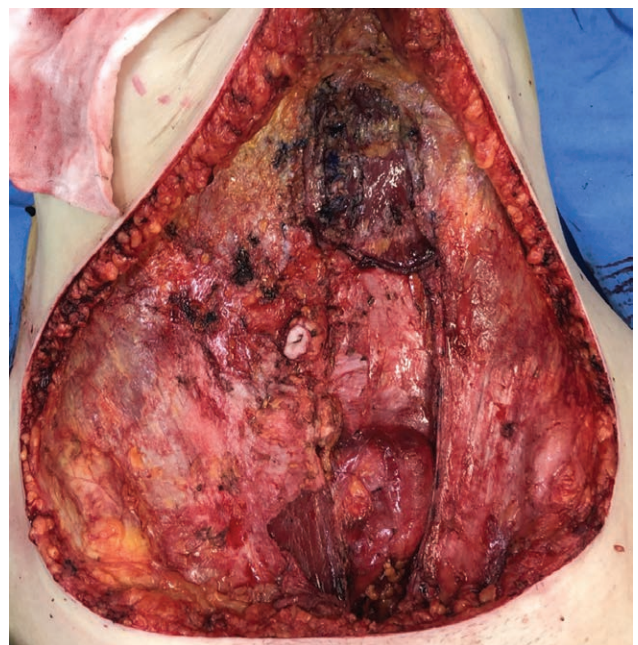


Fig. 10. Segmental defect in rectus abdominis muscle is evident within the rectus sheath.

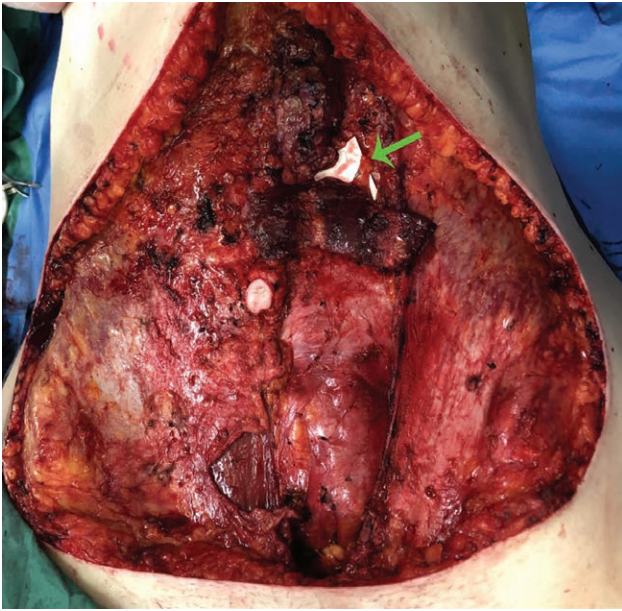


Fig. 11. RAPT flap raised based on the cranial rectus abdominis stump split longitudinally, with intercostal neurovascular bundle intact (green arrow).

site outcomes over the previous techniques,^{2,8,26,27} although there was no difference between the choice of medial or lateral strips.²⁸

The ultimate advance in muscle-sparing techniques has been the introduction of the DIEP flap, a flap that can (if based on a single perforator or multiple aligned perforators) spare rectus abdominis muscle entirely. Despite this, the DIEP flap has commonly shown no improvement in outcome over muscle-sparing TRAM flaps, and nonetheless has been associated with abdominal wall complications.^{1,7–10,14,15,27} Although a small amount of muscle is likely to be cut during the raising of this flap on more than one perforator,²⁹ this is unlikely to account for the abdominal wall sequelae complicating this flap.

Although progressive muscle sparing techniques have been shown to be advantageous, other causes for donor site complications require consideration,

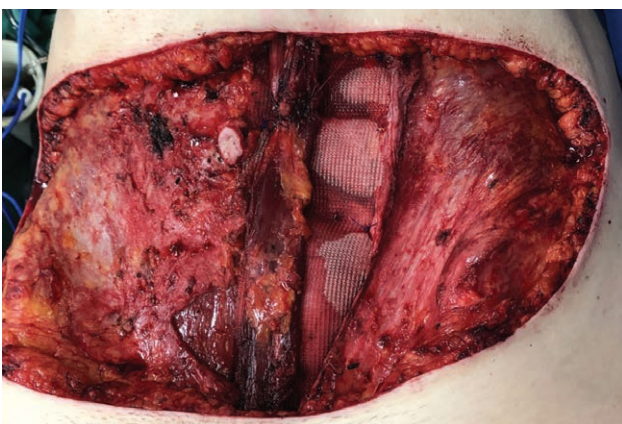


Fig. 12. RAPT flap transferred caudally to reconstruct the segmental defect in rectus abdominis from initial TRAM flap harvest.

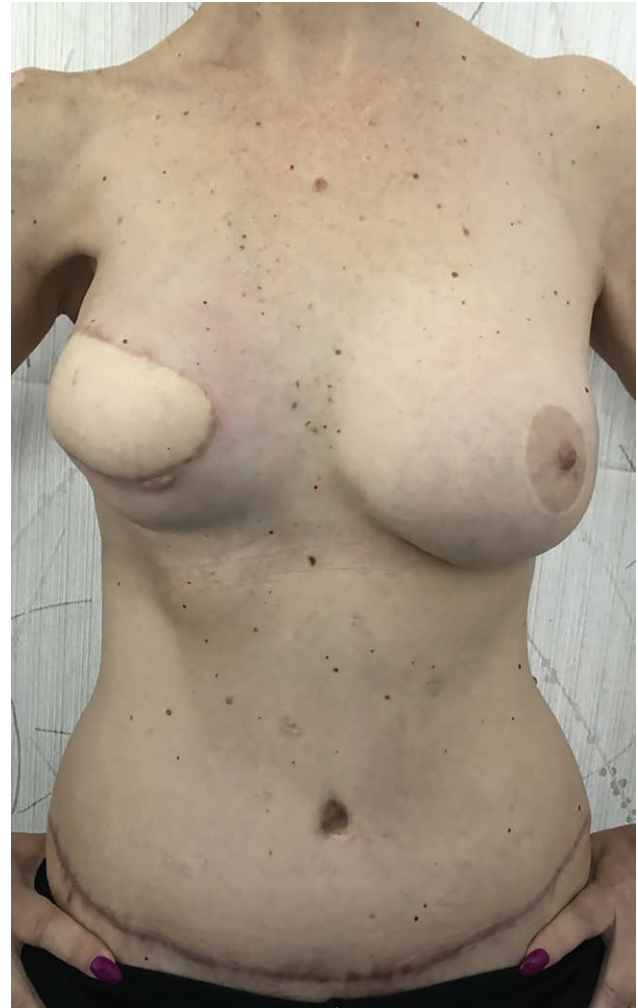

Fig. 13. Clinical photograph at 3 months postoperatively.

given the presence of this complication in DIEP flaps. Postulated causes in the literature have included the denervation of rectus abdominis muscle,^{30–33} inadequate closure of the anterior rectus sheath,^{26,34} and attenuation and/or laxity of the anterior rectus sheath.^{7–9} Denervation of the rectus abdominis muscle is a further etiology of abdominal wall morbidity following TRAM and DIEP flaps, with the nerves supplying rectus abdominis forming a plexus around the main DIEA trunk and the most lateral branch of the DIEA in the case of a bifurcating or trifurcating DIEA (according to the DIEA branching classification of Moon and Taylor).³⁵ Furthermore, motor nerves enter rectus abdominis with the lateral row perforators, arising from the lateral trunks of the DIEA. Davies et al described in 1931 the “very free plexus formation” of intercostal nerves in the anterior abdominal wall,³⁶ and Yap et al reiterated this, describing that “nerves are closely related to the DIEA vascular axis.”³⁷ Dissection or disruption to the lateral half of a rectus abdominis muscle risks damage to these nerves and creates the potential for rectus muscle denervation.^{38–41}

As such, despite theoretical donor benefits, the DIEP flap has commonly shown no improvements over muscle-sparing TRAM flaps, suggesting that rectus muscle continuity may be more important than muscle sacrifice alone. The current technique offers an approach to maintain rectus abdominis continuity after MS1 TRAM flap harvest. Although this may not replace the DIEP flap or MS2 TRAM flap as reconstructive choices, it adds an option that may maintain abdominal wall function and minimize morbidity, with selection able to be individually tailored. The technique is applicable to a broad range of patients, including those with both sizeable and diminutive perforators. In addition, although there were no obese patients in our cohort, the technique is equally applicable to obese patients, as the procedure is performed after elevation of the abdominal pannus, and thus the approach is not hampered by the thickness of the integument. There were no immediate or early complications of the procedure, and given that follow-up was only 12 weeks, functional testing was rudimentary and the cohort was small, a larger cohort and longer follow-up would be useful to make definitive statements as to maintaining abdominal wall function and strength. This pilot feasibility study highlights the role for a more definitive investigation into outcomes from the RAPT flap, and comparison with other abdominal wall flaps such as more traditional DIEP and TRAM flaps. The RAPT flap described herein may achieve the benefits of the TRAM flap in terms of ease of dissection and flap vascularity, and the benefits of the DIEP flap in terms of maintaining rectus abdominis continuity. Ultimately, this adds to the armamentarium of abdominal donor site options for free tissue harvest, and an individual approach to selection may be further bolstered with this option.

CONCLUSIONS

We describe the innervated RAPT flap for reconstitution of rectus continuity after TRAM flap harvest. This technique may achieve the benefits of the TRAM flap in terms of ease of dissection and flap vascularity, and the benefits of the DIEP flap in terms of maintaining rectus abdominis continuity.

Warren M. Rozen, MBBS, BMedSc, MD, PhD, FRACS
Department of Plastic and Reconstructive Surgery
Peninsula Clinical School, Central Clinical School
Faculty of Medicine, Monash University
Frankston, Victoria 3199
Australia
E-mail: warrenrozen@hotmail.com

REFERENCES

1. Bajaj AK, Chevray PM, Chang DW. Comparison of donor-site complications and functional outcomes in free muscle-sparing TRAM flap and free DIEP flap breast reconstruction. *Plast Reconstr Surg*. 2006;117:737–746.
2. Nahabedian MY, Momen B, Galdino G, et al. Breast reconstruction with the free TRAM or DIEP flap: patient selection, choice of flap, and outcome. *Plast Reconstr Surg*. 2002;110:466–475.
3. Allen RJ, Treece P. Deep inferior epigastric perforator flap for breast reconstruction. *Ann Plast Surg*. 1994;32:32–38.
4. Koshima I, Soeda S. Inferior epigastric artery skin flaps without rectus abdominis muscle. *Br J Plast Surg*. 1989;42:645–648.
5. Blondeel N, Vanderstraeten GG, Monstrey SJ, et al. The donor site morbidity of free DIEP flaps and free TRAM flaps for breast reconstruction. *Br J Plast Surg*. 1997;50:322–330.
6. Futter CM, Webster MH, Hagen S, et al. A retrospective comparison of abdominal muscle strength following breast reconstruction with a free TRAM or DIEP flap. *Br J Plast Surg*. 2000;53:578–583.
7. Nahabedian MY. Secondary operations of the anterior abdominal wall following microvascular breast reconstruction with the TRAM and DIEP flaps. *Plast Reconstr Surg*. 2007;120:365–372.
8. Nahabedian MY, Dooley W, Singh N, et al. Contour abnormalities of the abdomen after breast reconstruction with abdominal flaps: the role of muscle preservation. *Plast Reconstr Surg*. 2002;109:91–101.
9. Nahabedian MY, Momen B. Lower abdominal bulge after deep inferior epigastric perforator flap (DIEP) breast reconstruction. *Ann Plast Surg*. 2005;54:124–129.
10. Nahabedian MY, Tsangaris T, Momen B. Breast reconstruction with the DIEP flap or the muscle-sparing (MS-2) free TRAM flap: is there a difference? *Plast Reconstr Surg*. 2005;115:436–444.
11. Zhong T, Lao A, Werstein MS, et al. High-frequency ultrasound: a useful tool for evaluating the abdominal wall following free TRAM and DIEP flap surgery. *Plast Reconstr Surg*. 2006;117:1113–1120.
12. Allen RJ. DIEP versus TRAM for breast reconstruction. *Plast Reconstr Surg*. 2003;111:2478.
13. Allen RJ. Comparison of the costs of DIEP and TRAM flaps. *Plast Reconstr Surg*. 2001;108:2165.
14. Chen CM, Halvorson EG, Disa JJ, et al. Immediate postoperative complications in DIEP versus free/muscle-sparing TRAM flaps. *Plast Reconstr Surg*. 2007;120:1477–1482.
15. Schaverien MV, Perks AG, McCulley SJ. Comparison of outcomes and donor-site morbidity in unilateral free TRAM versus DIEP flap breast reconstruction. *J Plast Reconstr Aesthet Surg*. 2007;60:1219–1224.
16. Van Beek A, Hubble B, Kinkead L, et al. Clinical use of nerve stimulation and recording techniques. *Plast Reconstr Surg*. 1983;71:225–240.
17. Hartrampf CR Jr, Bennett GK. Autogenous tissue reconstruction in the mastectomy patient. A critical review of 300 patients. *Ann Surg*. 1987;205:508–519.
18. Lejour M, Dome M. Abdominal wall function after rectus abdominis transfer. *Plast Reconstr Surg*. 1991;87:1054–1068.
19. Mizgala CL, Hartrampf CR Jr, Bennett GK. Assessment of the abdominal wall after pedicled TRAM flap surgery: 5- to 7-year follow-up of 150 consecutive patients. *Plast Reconstr Surg*. 1994;93:988–1002.
20. Petit JY, Rietjens M, Ferreira MA, et al. Abdominal sequelae after pedicled TRAM flap breast reconstruction. *Plast Reconstr Surg*. 1997;99:723–729.
21. Simon AM, Bouwense CL, McMillan S, et al. Comparison of unipedicled and bipedicled TRAM flap breast reconstructions: assessment of physical function and patient satisfaction. *Plast Reconstr Surg*. 2004;113:136–140.
22. Mizgala CL, Hartrampf CR Jr, Bennett GK. Abdominal function after pedicled TRAM flap surgery. *Clin Plast Surg*. 1994;21:255–272.
23. Edsander-Nord A, Jurell G, Wickman M. Donor-site morbidity after pedicled or free TRAM flap surgery: a prospective and objective study. *Plast Reconstr Surg*. 1998;102:1508–1516.
24. Arnez ZM, Khan U, Pogorelec D, et al. Rational selection of flaps from the abdomen in breast reconstruction to reduce donor site morbidity. *Br J Plast Surg*. 1999;52:351–354.

25. Kroll SS, Schusterman MA, Reece GP, et al. Abdominal wall strength, bulging, and hernia after TRAM flap breast reconstruction. *Plast Reconstr Surg*. 1995;96:616–619.
26. Kroll SS, Marchi M. Comparison of strategies for preventing abdominal-wall weakness after TRAM flap breast reconstruction. *Plast Reconstr Surg*. 1992;89:1045–1051.
27. Nahabedian MY, Manson PN. Contour abnormalities of the abdomen after transverse rectus abdominis muscle flap breast reconstruction: a multifactorial analysis. *Plast Reconstr Surg*. 2002;109:81–87.
28. Garvey PB, Salavati S, Feng L, et al. Abdominal donor-site outcomes for medial versus lateral deep inferior epigastric artery branch perforator harvest. *Plast Reconstr Surg*. 2011;127:2198–2205.
29. Rozen WM, Ashton MW, Pan WR, et al. Raising perforator flaps for breast reconstruction: the intramuscular anatomy of the deep inferior epigastric artery. *Plast Reconstr Surg*. 2007;120:1443–1449.
30. Bottero L, Lefaucheur JP, Fadhul S, et al. Electromyographic assessment of rectus abdominis muscle function after deep inferior epigastric perforator flap surgery. *Plast Reconstr Surg*. 2004;113:156–161.
31. Duchateau J, Decléty A, Lejour M. Innervation of the rectus abdominis muscle: implications for rectus flaps. *Plast Reconstr Surg*. 1988;82:223–228.
32. Galli A, Adami M, Berrino P, et al. Long-term evaluation of the abdominal wall competence after total and selective harvesting of the rectus abdominis muscle. *Ann Plast Surg*. 1992;28:409–413.
33. Hammond DC, Larson DL, Severinac RN, et al. Rectus abdominis muscle innervation: implications for TRAM flap elevation. *Plast Reconstr Surg*. 1995;96:105–110.
34. Hartrampf CR Jr. Abdominal wall competence in transverse abdominal island flap operations. *Ann Plast Surg*. 1984;12:139–146.
35. Moon HK, Taylor GI. The vascular anatomy of rectus abdominis musculocutaneous flaps based on the deep superior epigastric system. *Plast Reconstr Surg*. 1988;82:815–832.
36. Davies F, Gladstone RJ, Stibbe EP. The anatomy of the intercostal nerves. *J Anat*. 1932;66(pt 3):323–333.
37. Yap LH, Whiten SC, Forster A, et al. The anatomical and neurophysiological basis of the sensate free TRAM and DIEP flaps. *Br J Plast Surg*. 2002;55:35–45.
38. Rozen WM, Tran TM, Ashton MW, et al. Refining the course of the thoracolumbar nerves: a new understanding of the innervation of the anterior abdominal wall. *Clin Anat*. 2008;21:325–333.
39. Rozen WM, Ashton MW, Murray ACA, et al. Avoiding denervation of rectus abdominis in DIEP flap harvest: the importance of medial row perforators. *Plast Reconstr Surg*. 2008;122:710–716.
40. Rozen WM, Ashton MW, Kiil BJ, et al. Avoiding denervation of rectus abdominis in DIEP flap harvest II: an intraoperative assessment of the nerves to rectus. *Plast Reconstr Surg*. 2008;122:1321–1325.
41. Rozen WM, Tran TMN, Barrington MJ, et al. Avoiding denervation of the rectus abdominis muscle in DIEP flap harvest III: a functional study of the nerves to the rectus using anesthetic blockade. *Plast Reconstr Surg*. 2009;124:519–522.