

The effect of alendronate treatment on cortical thickness of the proximal femur in postmenopausal women

Maryam Mobini¹, Leyla Dehghan², Gholamali Yosefi³, Alireza Mohammadpour⁴
Rohollah Abdi⁵

Received: 1 January 2015

Accepted: 27 July 2015

Published: 15 February 2016

Abstract

Background: Bisphosphonates (BPs) are used extensively for managing the osteoporosis. There are some controversies on atypical fractures of femur that associated with increase in cortical thickness (CT) and BPs' use. In this study, the effects of alendronate consumption were studied on femoral CT as a predictor for atypical fracture.

Methods: Forty nine post-menopausal women aged 50-70 years with osteopenia-osteoporosis who were treated with alendronate 70 mg/week for at least one year were compared to 49 controls for CT in subtrochanteric region of femur by hip dual-energy X-ray absorptiometry (DXA) scans and hip X-ray. CT and its ratio were measured at 3.5 and 4.0 cm below the tip of the greater trochanter (GT) and 0.5 cm below lesser trochanter (LT) in DXA and at 9.5 and 10.5 cm of GT and 1 cm of LT in X-ray.

Results: In this study, 98 women participated whose mean age and age at menopause were 60 (17±5.6) and 49 (40±2.7) years, respectively. Duration of BP consumption in alendronate group was 1.76±1.38 (1-10) years. No difference was seen in the mean of CT and its ratio between the alendronate and control groups in BMD scan or X-ray. The best correlation between two imaging modalities was in cortical ratio in 3.5 cm of GT in BMD scan and 9.5 cm of GT in X-ray.

Conclusion: Alendronate treatment did not appear to increase femoral CT throughout the detection limits of BMD scan or X-ray.

Keywords: Osteoporosis, Femoral cortical thickness, Alendronate, Atypical fracture.

Cite this article as: Mobini M, Dehghan L, Yosefi Gh, Mohammadpour A, Abdi R. The effect of alendronate treatment on cortical thickness of the proximal femur in postmenopausal women. *Med J Islam Repub Iran* 2016 (15 February). Vol. 30:328.

Introduction

Bisphosphonates (BPs) are inorganic pyrophosphate analogs that accumulate on the bone surface and inhibit bone resorption by osteoclast apoptosis. They are used extensively for managing the osteoporosis with considerable clinical benefits in the reduction of fragility fractures. However, rare associations of subtrochanteric atypical femoral fractures have been reported post marketing, often after long term BP therapy (1-4).

Atypical fractures of femoral shaft or subtrochanteric area were accounted for <0.1% of total fracture admissions (5) and are strongly associated with BPs but they are rather uncommon (6). These fractures occur after a low energy trauma and they have a typical simple transverse or oblique radiographic pattern, with focal or generalized increase in cortical thickness, cortical beaking, and medial spiking and they may be bilateral (2,7,8). Lower age, probably due to the high physical activity, unknown

¹. (Corresponding author) Rheumatologist, Associate Professor, Diabetes Research Center, Mazandaran University of Medical Sciences, Sari, Iran. mmobini50@yahoo.com

². Internist, Division of Internal Medicine, Imam Khomeini Hospital, Mazandaran University of Medical Sciences, Sari, Iran. ali3abbaspor1@gmail.com

³. Nuclear Medicine Specialist, Valiasr Hospital, Mazandaran University of Medical Sciences, Ghaemshahr, Iran. usefi547@gmail.com

⁴. Biostatistician, Associate Professor, Diabetes Research Center, Mazandaran University of Medical Sciences, Sari, Iran. mohammadpour2002@yahoo.com

⁵. Radiologist, Associate Professor, Mazandaran University of Medical Sciences, Sari, Iran. sian_abdi@yahoo.com

genetic factors, thicker cortex and long duration of BP use, suboptimal 25-OHD level, and bone density in the non-osteoporotic range might play important roles (6, 9). It is suggested that the pathogenesis of these fractures are related to the profound osteoclast inhibition and the resulting suppression of the bone turnover and bone remodeling (10,11).

Long term use of BPs may cause insufficiency fractures due to the depressed bone remodeling, reduction of mechanical properties under cyclic loading conditions and oversuppression of bone turnover leading to microdamages and reduced bone strength (3,12,13).

In some case reports and series, the patients' ages differed from 46 to 76 years (3, 4) and the duration of BP usage varied from 3 to 16 years (4,13,14). Other studies evaluated older osteoporotic patients (10) with long term alendronate more than 5 years (3,10) but there are some reports in which atypical fractures happened earlier than 5 years (4, 14, 15). The comparison between BMD scan and pelvic X-ray has not been done either (10).

A large number of patients receive long term BP treatment, therefore, recognition of the side effects, especially atypical fractures are very important. In this study, we compared osteopenic/osteoporotic postmenopausal women in two groups according to receiving alendronate for femoral cortical thickness in BMD and plain pelvic Xray as a predictor for atypical fracture.

Methods

In this historical cohort study, 49 osteopenic or osteoporotic out patients who were treated by alendronate for at least one year were compared to 49 controls for cortical thickness in subtrochanteric and proximal portion of femur in a rheumatology clinic in Mazandaran, north of Iran, in 2013- 14. The sample size based on random sampling method was calculated according to results of Unnanuntana study for mean and SD of CT in cases and controls (10), with power and confidence level of 90% and 95%, re-

spectively. Approval was obtained from the Ethics Committee of Mazandaran University of Medical Sciences.

All participants were post-menopausal women aged 50-70 years, diagnosed with osteopenia or osteoporosis according to bone mineral densitometry (BMD) (by lunar prodigy, USA, GE Company). Osteopenia and osteoporosis were defined as T-Score between -1to -2.5 and T-Score< -2.5, respectively.

Patients who were treated with other BPs (other than alendronate) or raloxifen, became menopause before 45 years of age, those with hyperthyroidism, hyperparathyroidism, inflammatory rheumatologic disorders such as rheumatoid arthritis, inflammatory bowel diseases, glucocorticoid using, and cigarette smoking were excluded from the study. Patients with body mass index (BMI) lower than 18.5 or higher than 30 were also excluded. Controls were postmenopausal women meeting similar criteria but without history of alendronate consumption. Data collected for each patient included demographic information and osteoporosis related data. Cortical thickness in subtrochanteric area and proximal of fe-

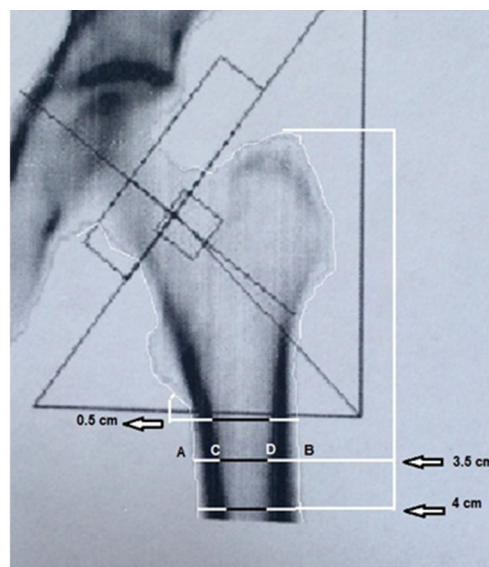


Fig.1. A DXA scan shows measurements were obtained at 3.5 cm and 4.0 cm from the tip of the greater trochanter and 0.5 cm of lesser trochanter. Cortical thickness was calculated by subtracting the medullary diameter from the femoral shaft diameter ($AB - CD$). The cortical thickness ratio was defined as the percentage of the cortical thickness to its femoral shaft diameter $[(AB - CD)/AB]$.

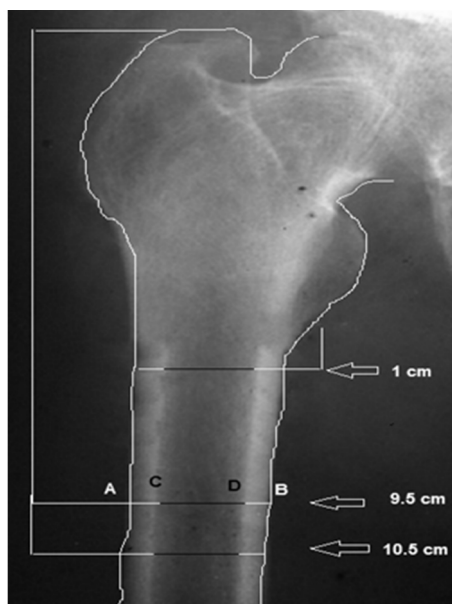


Fig. 2. A plain pelvic Xray shows measurements were obtained at 9.5 cm and 10.5 cm from the tip of the greater trochanter and 1 cm of lesser trochanter. Cortical thickness was calculated by subtracting the medullary diameter from the femoral shaft diameter (AB - CD). The cortical thickness ratio was defined as the percentage of the cortical thickness to its femoral shaft diameter [(AB - CD)/AB].

mural shaft were measured in 3.5 and 4 cm of greater trochanter (GT) and 0.5 cm under smaller trochanter (LT) in BMD and in 9.5 and 10.5 cm of GT and 1 cm under LT in plain pelvic graphs (Shimadsu, Japan) according to accommodation of size in this Xray of a patient.

Diameter of femur, cortical thickness, medullary canal diameter and cortical thickness ratio was measured in these regions (Figures 1 and 2).

Statistical analysis was performed by t-

test and Chi square tests for comparing quantitative and qualitative variables in two groups, respectively. Descriptive statistics were performed to determine the changes in cortical thickness and percent change in cortical thickness using SPSS version 20. $p < 0.05$ was considered significant.

Results

In this historical cohort study 98 osteopenic/osteoporotic post-menopausal women were compared in two groups (n=49 patients per group) for femoral cortical thickness according to alendronate usage. Their mean±SD age and age at menopause was 60.2 ± 5.60 and 49.4 ± 2.70 years, respectively. Duration of BP consumption in alendronate group was 1.76 ± 1.38 (1-10) years. Patients were considered osteopenic and osteoporotic if their T-Score was ≤ -1 (42.85%) and ≤ -2.5 (46.9%) in lumbar spine and ≤ -1 (47.95%) and ≤ -2.5 (6.1%) in hip. There were no significant differences between the two groups in demographic and baseline data parameters in osteopenic or osteoporotic patients except for calcium supplementation in alendronate group ($p < 0.05$).

Demographic and baseline data of patients and some OP related characteristics are shown in Tables 1 and 2.

We observed no differences in mean of cortical thickness and cortical thickness ratio between the alendronate and control groups neither in BMD scan nor in X-ray ($p < 0.05$).

Table 1. Demographic and baseline characteristics of participants.

Variables	Alendronate group	Controls	p
Age	61.06±5.3	59.3±5.8	0.12
BMI	26.45± 2.8	26.2± 2.7	0.61
Age at menopause	49.0±2.6	49.81±2.8	0.13
Walking (h/day)	2.52±2.9	2.50±2.6	1
History of calcium using (years)	2.33± 3.3	0.52±0.7	0.00
Serum calcium (mg/dl)	9.13±0.5	9.01±0.3	0.09
Alkaline phosphatase (u/l)	208.40±44.9	215.92±38.8	0.38
Level of 25 OH D (ng/ml)	31.04±9.3	30.22±10.9	0.69
Serum creatinine(mg/dl)	0.81±0.1	0.87±0.2	0.08
BMD in hip (g/cm ²)	0.86±0.1	0.86±0.1	0.78
T score in hip	-1.16±0.9	-1.08± 0.9	0.68
BMD in spine	0.89± 0.1	0.92± 0.1	0.32
T score in spine(g/cm ²)	-2.40± 1	-2.15± 1	0.23

Table 2. Some osteoporosis related characteristics of participants.

Variables	Alendronate group	Controls	p
History of fragility fracture (N,%)	3 (6.1%)	4 (6.8%)	0.70
Family history of fragility fracture (N,%)	7 (12.9%)	3 (6.1%)	0.20
Thigh pain (N,%)	2 (3.4%)	4 (6.8%)	0.40
Proton pump inhibitor user (N,%)	4 (6.8%)	5 (10.2%)	0.73

Table 3. DXA scan and plain measurements of femoral cortex

Measurement	Alendronate group	Controls	p
3.5 cm below GT (DXA)			
Femoral shaft diameter (mm)	12.45±0.9	12.37± 0.9	0.64
Medullary canal diameter (mm)	5.98± 0.9	6.02±0.9	0.86
Cortical thickness (mm)	6.46± 0.7	6.35± 0.8	0.47
Cortical thickness ratio (%)	52.02± 5.6	51.34± 6.08	0.56
0.5 cm below LT (DXA)			
Femoral shaft diameter (mm)	12.86±0.8	12.68± 0.8	0.29
Medullary canal diameter (mm)	6.90±0.9	6.91± 0.9	0.96
Cortical thickness (mm)	5.96±0.57	5.76± 0.52	0.07
Cortical thickness ratio (%)	46.50±5.0	45.55± 4.5	0.32
9.5 cm below GT (in plane Xray)			
Femoral shaft diameter (mm)	33.08± 3.2	33.52± 2.8	0.47
Medullary canal diameter (mm)	19.64± 3.3	19.47± 2.9	0.79
Cortical thickness (mm)	13.41± 2.3	14.04± 1.8	0.14
Cortical thickness ratio (%)	40.70± 6.6	42.03± 5.42	0.27
1 cm below LT (in plane X ray)			
Femoral shaft			
diameter (mm)	34.08± 3.1	34.51± 2.71	0.47
Medullary canal diameter (mm)	21.8± 3.1	22.06± 3.1	0.69
Cortical thickness (mm)	12.27± 1.7	12.44± 1.8	0.63
Cortical thickness ratio (%)	36.19± 5.2	36.18± 5.7	0.99

The cortical thickness parameters in DXA pelvic X-ray are demonstrated in Table 3. Results of measurements in 4 cm of GT in DXA and 10.5 cm in X-ray were similar to 3.5 and 9.5 cm, respectively, which are not listed in the table. Correlations of these results between X-ray and densitometry are shown in Table 4.

Discussion

In this study, we evaluated the effect of alendronate on cortical thickness of the proximal femur and compared the differences in cortical thickness between osteoporotic patients with or without alendronate therapy in BMD and X-ray.

The results suggest that alendronate treatment did not increase femoral cortex

thickening within the detection limits of BMD scan or X-ray. On the other hand, a significant correlation was observed between BMD scan and x-ray especially in cortical thickness ratio: 3.5 cm (DXA) and 9.5 cm (X-ray) below GT.

There are several case reports and series that have indicated an association between long-term treatment with BPs, and the development of atypical low-energy subtrochanteric or femoral shaft fractures (1-4,14). Postmenopausal osteoporosis is commonly treated with BPs especially alendronate. It is hypothesized that long term BP therapy results in oversuppression of bone turnover, leading to an accumulation of microdamage (11) and increased susceptibility of bone to fracture from low-

Table 4. Correlation of DXA and plain measurements of femoral cortex

Region	Correlation	p
Cortical thickness: 3.5 cm (DXA) and 9.5 cm (Xray) below GT	0.31	0.002
Cortical thickness ratio: 3.5 cm (DXA) and 9.5 cm (Xray) below GT	0.69	<0.001
Cortical thickness: 4 cm (DXA) and 10.5 cm (Xray) below GT	0.29	0.003
Cortical thickness ratio: 4 cm (DXA) and 10.5 cm (Xray) below GT	0.64	<0.001
Cortical thickness: 0.5 cm (DXA) and 1 cm (Xray) below LT	0.26	<0.001
Cortical thickness ratio: 0.5 cm (DXA) and 1 cm (Xray) below LT	0.60	<0.001

energy injury due to changes of structural components that reduce mechanical properties under cyclic loading conditions (12). An in vitro study showed strong inhibitory effect of alendronate on human mesenchymal stem cell mediated osteogenesis by suppressing cell proliferation, osteoblast differentiation, and function (16).

Common features of atypical fractures include prodromal pain, occurrence with minimal or no trauma, a thickened diaphyseal cortex and transverse fracture pattern (17). The term cortical thickening refers to focal cortical thickening, caused by the callus reaction at the site of a fatigue fracture or to a general cortical thickness of the diaphyseal femoral shaft (6).

In a case-control study by Koeppen et al femoral cortical thickness index in 5 cm below the lesser trochanter in X-ray, were compared in 59 atypical and 218 ordinary fractures. The results did not demonstrate any significant difference between the two groups and similarly, there was no significant difference in patients with or without BP treatment or between the ipsi- and contralateral femurs in patients with an atypical fracture (6). Also, Giusti et al found a significantly higher cortical thickness index at 5 cm below the lesser trochanter in 10 patients with atypical fracture (18). Unnanuntana et al evaluated changes in cortical thickness and cortical thickness ratio at the subtrochanteric region of the proximal femur (at 3.5 and 4.0 cm under the tip of the greater trochanter) in baseline and latest hip BMD scan in 86 patients (at least 5 years alendronate treatment) and 45 controls. They observed no differences in mean changes of cortical thickness and percent changes of cortical thickness between the two groups and found that cortical thickness changed less than 1 mm in more than 90% of the patients with long-term alendronate treatment (10).

There are two points that differentiate this study from the later. First, in older studies, cortical thickness was evaluated by X-ray (6, 18) or BMD scan (10) only, but in this study BMD scan and X-ray were compared

for evaluation of a reliable correlation of these modalities and three regions in femur were also evaluated.

We observed a low correlation of CT between DXA and X-ray (0.26-0.31) and a moderate correlation of CT ratio between DXA and X-ray (0.6-0.7). This might be due to some individual differences in femur anatomy or imaging techniques. So, future investigations are suggested to clarify whether CT ratio is a more reliable index than CT alone.

Second, former studies evaluated patients with long term alendronate consumption (10). This could cause a false idea that in present study, duration of alendronate usage was too short, however, there are some investigations reporting these fractures in younger patients or shorter duration of treatment (3,6). So, our study included post-menopausal patients aged 50-70 years of old with shorter duration of BP treatment (more than one year).

There are some limitations to this study. The first and perhaps the main limitation was on our measurements from two-dimensional DXA scans and X-ray. The cortical margin of the DXA image was not well defined which might have affected the selection of measurement points.

Also, the measured points we used for each patient may represent different locations of the subtrochanteric region because of height or normal variations. However, we tried to measure three regions for better evaluation of cortical thickness. There are some reports indicating atypical fractures associated with less than 5 years alendronate therapy, so, in present study we evaluated patients with shorter duration of treatment. Although we believe further prospective studies are needed to determine the annual rate of cortical changes for longer periods. Finally, data on alendronate treatment were obtained retrospectively; therefore, we do not have accurate details on adherence and compliance to those treatments.

Apparently, alendronate treatment does not cause thickened femoral cortices at the

subtrochanteric region in BMD or plain pelvic X-ray. Percent changes in cortical thickness were similar in patients with or without a history of alendronate use. BPs have a role in reducing the risk of fracture, however, concerns about their association and femoral insufficiency fractures should not preclude the use of these agents in the treatment of osteoporosis. For example, in the United States, hip fracture rates have declined by 30% coincident with bisphosphonate use (19). On the other hand, there are some reports about atypical fractures associated with other anti-osteoporotic agents such as denosumab (20,21). Kim et al. found no significant association between bisphosphonate use and subtrochanteric or diaphyseal femur fractures compared with raloxifene/calcitonin (22).

Further investigations are required to determine the pathogenesis and other risk factors or predictors of atypical femoral insufficiency fractures in patients receiving long-term bisphosphonates.

Conclusion

Alendronate treatment did not appear to increase femoral CT throughout the detection limits of BMD scan or X-ray

Acknowledgement

The authors gratefully acknowledge the financial support of the Mazandaran University of Medical Sciences. This paper is a part of a thesis conducted by Dr Leyla Dehghan for internal medicine specialty.

Conflict of interest

The authors have no conflict of interest.

References

1. Alshahrani F, Kendler D. Femoral fractures in osteoporotic patients on bisphosphonates. A case report. *J Clin Densitom* 2012;15(3):380-4.
2. Ballas EG, Mavrogenis AF, Karamanis E, Kokkalis ZT, Mitsiokapa E, Koulalis D, et al. Low-energy femoral shaft fractures after long-term alendronate therapy: report of seven cases. *Eur J Orthop Surg Traumatol* 2015;25(1): 181-7.
3. Cakmak S, Mahirogullari M, Keklikci K, Sari E, Erdik B, Rodop O. Bilateral low-energy sequen-

tial femoral shaft fractures in patients on long-term bisphosphonate therapy. *Acta Orthop Traumatol Turc* 2013;47(3):162-72.

4. Mobini M. Alendronate-Related Femoral Fracture in a premenopausal glucocorticoid treated patient. *Caspian J Intern Med* 2014;5(1):46-8.

5. Warren C, Gilchrist N, Coates M, Frampton C, Helmore J, McKie J, et al. Atypical subtrochanteric fractures, bisphosphonates, blinded radiological review. *ANZ surg* 2012;82(12):908-12.

6. Koeppen VA, Schilcher J, Aspenberg P. Atypical fractures do not have a thicker cortex *Acta Orthop* 2012;23:2893-6.

7. Somford MP, Geurts GF, den Teuling JW, Thomassen BJ, Draijer WF. Long-term alendronate use not without consequences? *Int J rheumatol* 2009;2009:253432.

8. Zafeiris CP, Stathopoulos IP, Kourkoumelis G, Gkikas E, Lyritis GP. Simultaneous bilateral atypical femoral fractures after alendronate therapy. *J Musculoskelet Neuronal Interact* 2012;12(4):262-4.

9. Markman LH, Allison MB, Rosenberg ZS, Vieira RL, Babb JS, Tejwani NC, et al. A retrospective review of patients with atypical femoral fractures while on long-term bisphosphonates: including pertinent biochemical and imaging studies. *Endocr Pract* 2013;19(3):456-61.

10. Unnanuntana A, Ashfaq K, Ton QV, Kleimeyer JP, Lane JM. The effect of long-term alendronate treatment on cortical thickness of the proximal femur. *Clin Orthop Relat Res* 2012;470(1):291-8.

11. Mashiba T, Hirano T, Turner C, Forwood M, Johnston C, Burr D. Suppressed bone turnover by bisphosphonates increases microdamage accumulation and reduces some biomechanical properties in dog rib. *J Bone Miner Res* 2000;15:613-20.

12. Bajaj D, Geissler JR, Allen MR, Burr DB, Fritton JC. The resistance of cortical bone tissue to failure under cyclic loading is reduced with alendronate. *Bone* 2014;64:57-64.

13. Dandinoglu T, Akarsu S, Karadeniz M, Tekin L, Aribal S, Kiralp MZ. Can long-term bisphosphonate use causes low-energy fractures? A case report. *Ostoporos Int* 2014;25(2):773-6.

14. Kao CM, Huang PJ, Chen CH, Chen SJ, Cheng YM. Atypical femoral fracture after long-term alendronate treatment: report of a case evidenced with magnetic resonance imaging. *Kaoshing J Med Sci* 2012;28(10):555-8.

15. Huang HT, Kang L, Huang PJ, Fu YC, Lin SY, Hsieh CH, et al. Successful teriparatide treatment of atypical fracture after long-term use of alendronate without surgical procedure in a postmenopausal woman: a case report. *Menopause* 2012;19(12):1360-3.

16. Patntirapong S, Singhatanadgit W, Arphavasins S. Alendronate-induced atypical bone fracture: evidence that the drug inhibits osteogenesis. *J Clin Pharm Ther* 2014;39(4):349-53.

17. Rizzoli R, Åkesson K, Bouxsein M, Kanis JA,

Napoli N, Papapoulos S, et al. Subtrochanteric fractures after long-term treatment with bisphosphonates: a European Society on Clinical and Economic Aspects of Osteoporosis and Osteoarthritis, and International Osteoporosis Foundation Working Group Report. *Osteoporos Int* 2011;22:373-90.

18. Giusti A, Hamdy N, Dekkers O, Ramautar S, Dijkstra S, Papapoulos S. Atypical fractures and bisphosphonate therapy: a cohort study of patients with femoral fracture with radiographic adjudication of fracture site and features. *Bone* 2011;48:966-71.

19. Edwards BJ, Bunta AD, Lane J, Odvina C, Rao DS, Raisch DW, et al. Bisphosphonates and nonhealing femoral fractures: analysis of the FDA Adverse Event Reporting System (FAERS) and international safety efforts: a systematic review from

the Research on Adverse Drug Events And Reports (RADAR) project. *J Bone Joint Surg Am* 2013; 95(4):297-307.

20. Thompson RN, Armstrong CL, Heyburn G. Bilateral atypical femoral fractures in a patient prescribed denosumab- a case report. *Bone* 2014;61:44-7.

21. Drampalos E, Skarpas G, Barbounakis N, Michos I. Atypical femoral fractures bilaterally in a patient receiving denosumab. *Acta Orthop* 2014; 85(1):3-5.

22. Kim S, Schneeweiss S, Katz J, Levin R, Solomon D. Oral Bisphosphonates and Risk of Subtrochanteric or Diaphyseal Femur Fractures in a Population-Based Cohort. *J Bone Miner Res* 2011; 26(5):993-1001.