

Received: 2018.01.24
Accepted: 2018.04.11
Published: 2018.05.09

Application of a 'Baseball' Suture Technique in Uterine Myomectomy Following Laparoscopic Enucleation of Uterine Leiomyoma (Fibroid)

Department of Gynecologic Oncology, Sun Yat-sen Memorial Hospital, Sun Yat-sen University, Guangzhou, Guangdong, P.R. China

Authors' Contribution:
Study Design A
Data Collection B
Statistical Analysis C
Data Interpretation D
Manuscript Preparation E
Literature Search F
Funds Collection G

B **Lingling Xie***
E **Yunyun Liu***
D **Dongyan Wang**
F **Changhao Liu**
B **Hui Zhou**
A **Zhongqiu Lin**
A **Huaiwu Lu**

* These authors contributed equally to this work

Corresponding Author: Huaiwu Lu, e-mail: luhuaiwu@163.com

Source of support: This study was supported by National Natural Science Foundation of China (No. 81602290)

Background: The aim of this study was to evaluate the safety and efficacy of a 'baseball' suture technique for uterine myomectomy incision closure in laparoscopic surgical enucleation of uterine leiomyoma (fibroid).





Material/Methods: The study included 20 patients who underwent laparoscopic myomectomy with a 'baseball' suture technique, compared with 20 patients who underwent laparoscopic myomectomy with a standard suture method. Clinical characteristics, perioperative and follow-up data were compared between the two groups.

Results: For the study group, compared with the standard or control group, had a significantly reduced operation time (60.15 ± 9.97 min vs. 71.85 ± 9.74 min) and suturing time (18.05 ± 4.71 min vs. 28.35 ± 3.13 min) (both $p < 0.05$), significantly less intraoperative blood loss (93.25 ± 19.62 ml vs. 121.50 ± 24.87 ml) ($p < 0.05$) and significantly less reduction in postoperative hemoglobin levels (8.9 ± 1.97 g/L vs. 11.15 ± 2.23 g/L) ($p < 0.05$). There were no statistically significant differences between the two groups in duration of the use of the indwelling drainage tube, drainage volume, or time to recovery of gastrointestinal function (all, $p > 0.05$). Following surgery, blood transfusion was given to one patient in the study group and two patients in the control group. One patient from each group had a fever. There was no significant difference in pregnancy outcomes between the two groups.

Conclusions: The 'baseball' suture technique for closure of the uterine incision is a safe and effective method for use in laparoscopic myomectomy. However, the long-term recovery outcomes require further study.

MeSH Keywords: **Laparoscopy • Suture Techniques • Uterine Myomectomy**

Full-text PDF: <https://www.medscimonit.com/abstract/index/idArt/909143>

 2953  4  2  23



Background

Uterine leiomyoma (fibroid) is the most common benign tumor in the reproductive system of women of childbearing age, with a prevalence of between 30–35% [1]. Myomectomy is the treatment of choice for women who have symptoms and who wish to preserve their future fertility. During the last two decades, there have been rapid developments in minimally invasive surgical methods for myomectomy, and currently, a variety of endoscopic techniques are now used, including laparoscopy [2], hysteroscopy [3], and robotic-assisted surgery [4,5]. These new minimally invasive surgical techniques have several advantages for the patients, including smaller abdominal surgical wound, more rapid recovery, and shorter hospital stay [2]. However, effective control of intraoperative blood loss remains an important challenge. Intraoperative injections of oxytocin and pituitrin can reduce blood loss during laparoscopic uterine myomectomy by enhancing vascular contraction of the uterus, but may achieve only a limited hemostatic effect [6,7]. The key factor in the reduction of blood loss during myomectomy is the rapid and effective closure of the uterine wound following enucleation of the uterine leiomyoma [8,9].

The traditional suture method for laparoscopic myomectomy is interrupted or continuous suturing from the bottom to the top of the enucleation cavity [10]. For relatively large and deep myomas, layer-on-layer suturing is required, through which the enucleation cavity is closed, initially with interrupted sutures, followed by closure of the uterine incision with continuous sutures. In this process, the increased time required for suturing or inappropriate suturing might lead to prolonged overall operation time, increased blood loss, the postoperative formation of a hematoma, secondary infection, and even the need for a second surgery due to intra-abdominal bleeding [11]. Since 2014, our department has developed and used a new 'baseball' pattern of suturing technique for suturing and closing the uterine incision following myomectomy.

The aim of this study was to evaluate the safety and efficacy of the 'baseball' suture technique for closure of the uterine myomectomy incision in laparoscopic surgical enucleation of uterine leiomyoma (fibroid) and to compare the findings with patients who had undergone laparoscopic myomectomy with a standard suture method.

Material and Methods

Patients and ethical approval

From January 2014 to November 2015, 20 women who underwent laparoscopic myomectomy using the 'baseball' suture technique in the Department of Gynecologic Oncology of Sun

Yat-sen Memorial Hospital were included as the study group. Twenty women who had undergone laparoscopic myomectomy with a standard suture method were included as a comparative control group and were selected retrospectively from the hospital clinical database, who met the same inclusion criteria as the study population. The size of the uterine leiomyoma (fibroid) was used as a matching criterion. All the surgical procedures were performed at the same center, by the same surgeon, Dr. Huaiwu Lu. This study was approved by the local Ethics Committee and was performed in accordance with local ethical standards. Informed consent was obtained from all participants included in the study.

Inclusion criteria

Study participants were women of reproductive age who required preservation of their future fertility, with a single uterine intramural leiomyoma, who had symptoms related to the presence of uterine leiomyoma. The other inclusion criteria included: a leiomyoma that ranged in diameter from between 5–8 cm; a sonographically diagnosed free myometrial margin (distance between the deeper part of the uterine leiomyoma and the endometrial cavity) of 0.5 cm or more; a preoperative hemoglobin level of ≥ 80 g/L and no intraoperative blood transfusion; no other gynecological diseases detected on preoperative ultrasound; and no previous history of pelvic or abdominal surgery or pelvic inflammation.

Operative techniques

All patients received prophylactic antibiotics 30 minutes before surgery. Endotracheal general anesthesia was used. The patient was placed in the lithotomy position, and an indwelling urinary catheter was inserted. Four port puncture sites were made in the lower abdomen, and a laparoscope was inserted via the umbilical port. After the uterine leiomyoma was located, a single dose of 6 U of pituitrin was injected into the uterine body. Then, an incision was made at the most prominent site on the leiomyoma, followed by bipolar electrocoagulation on the top of the incision until the tissue turned pale. The seromuscular layer of the uterus was cut, using a monopolar electrocautery tool until the core of the uterine leiomyoma was reached. After the leiomyoma was enucleated by a combination of blunt and sharp dissection, the small vessels with noticeable bleeding were coagulated via bipolar electrocoagulation. The enucleation cavity was closed, using the 'baseball' suture technique for the 20 patients in the study group (Figure 1).

As shown in Figure 1.A, in the 'baseball' pattern of suturing, a 2-0 absorbable suture was made on the top of the incision and tied with a knot. Then, the needle was inserted into the bottom of the enucleation cavity and passed through the left

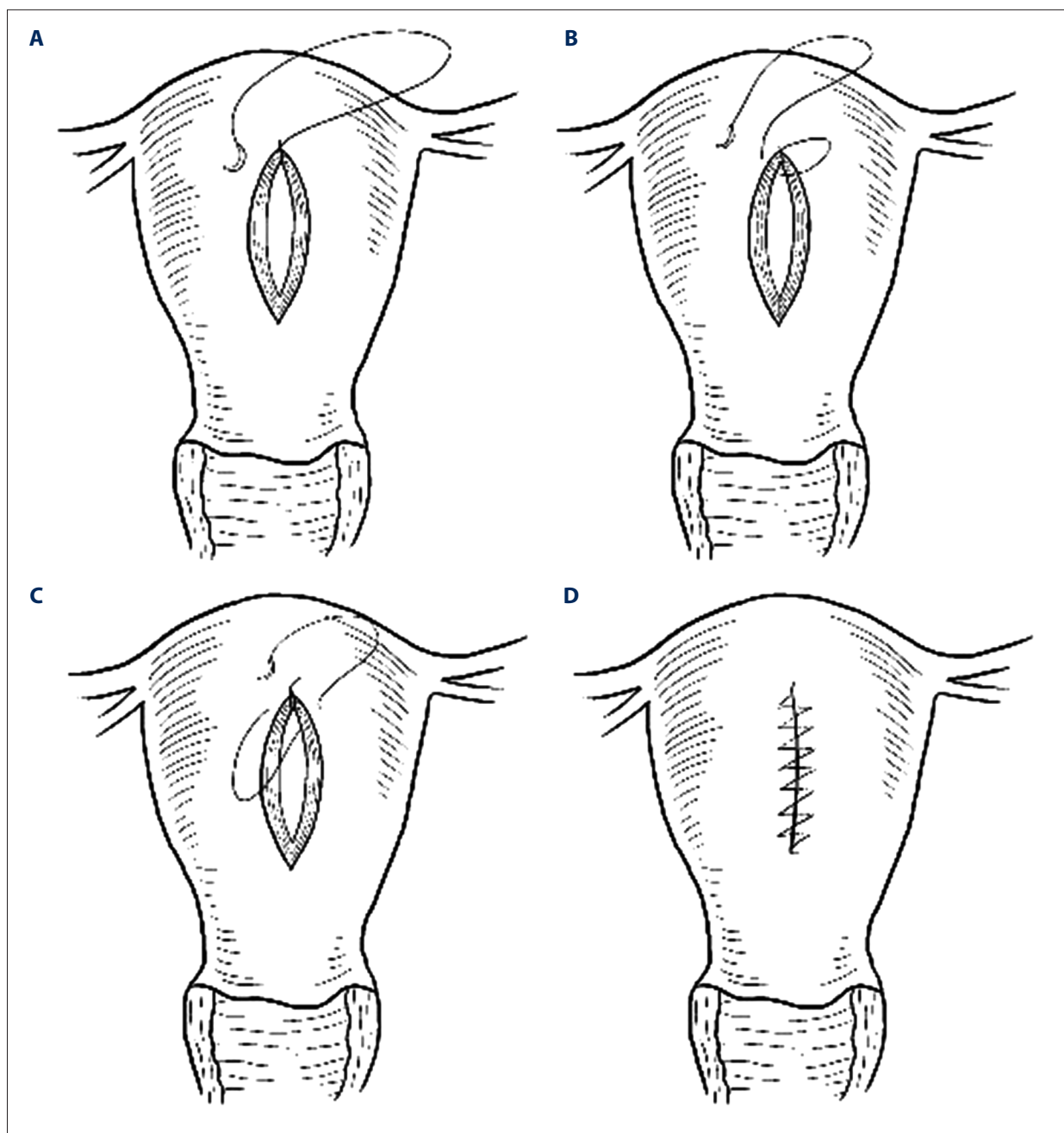


Figure 1. Demonstration of the 'baseball' suture technique for uterine myomectomy. **(A)** The first stitch is made with a 2-0 absorbable suture at the top of the incision and tied with a knot. **(B)** Next, the suture needle is shown to be inserted into the bottom of the cavity, which results from enucleation of the uterine leiomyoma, and the needle is passed through the left side of the incision. **(C)** After the suture is pulled tight, the suture needle is again inserted into the bottom of the enucleation cavity and passed through the right side of the incision. **(D)** The final appearance of the sutured uterine incision, which resembles the stitches on a 'baseball.'

side of the incision (Figure 1B). After the suture was pulled tight, the needle was again inserted into the bottom of the enucleation cavity and passed from the right side of the incision (Figure 1C). The stitches were spaced evenly at between 0.5–1.0 cm intervals. The same procedure was repeated alternately at

the two sides until the end of the incision, where the suture was secured and tied with a knot. Figures 1D and 2 show the appearance of the sutured uterine incision, which resembles the stitches on a baseball.

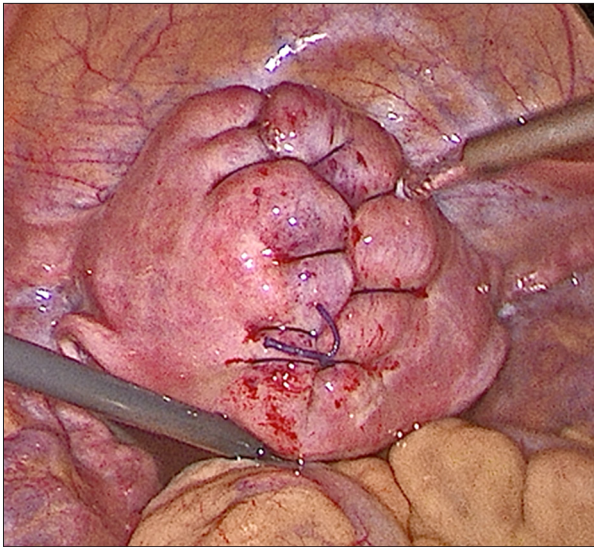


Figure 2. The appearance of the sutured uterine myomectomy incision, which resembles the stitches on a 'baseball.' The 'baseball' suture technique is shown to result in good uterine integrity.

In the control group, the traditional suture method had been used, with interrupted suturing of the myometrium at the uterine incision to close the enucleation cavity using a 2-0 absorbable suture, followed by continuous suturing of the seromuscular layer of the uterus. After the suture was finished, an Interceed® absorbable adhesion barrier was inserted to reduce postoperative adhesion formation.

The clinical data collected in this study included operation time, suturing time of the uterine incision (the duration from the initial insertion of the needle to the moment the suture was cut after incision closure), intraoperative blood loss (the post-closure volume of blood accumulating in the suction device before pelvic rinsing, recorded within 5 ml), the pre-operative hemoglobin level, the difference in the hemoglobin level before and 24 hours after surgery, the wound drainage volume (recorded within 5 ml), the duration of the indwelling urinary

catheter, the time to recover of bowel function after surgery, and any complications associated with surgery.

Patient follow-up

All patients underwent clinical follow-up with transvaginal ultrasound at one-month and three-months following surgery. Pregnancy data were obtained by follow-up telephone calls to the patients.

Statistical analysis

Data were analyzed using Student's t-test, the chi-squared (χ^2 test), Fisher's exact test, and the Mann-Whitney U test. Statistical analysis was performed using SPSS version 19.0 software. A p-value of <0.05 was considered as statistically significant.

Results

From January 2014 to November 2015, in the Department of Gynecologic Oncology of Sun Yat-sen Memorial Hospital, 28 patients with a single symptomatic intramural uterine leiomyoma were assessed for eligibility for inclusion in the study. There were 20 patients who met the study inclusion criteria and were included in the 'baseball' suture technique study group. A further 20 patients were retrospectively selected for the control group using the same inclusion criteria. The size of the uterine leiomyoma was used as a matching criterion. The clinical characteristics of both groups, the study group, and the control group, are shown in Table 1. Both groups showed no significant differences regarding the dimension of the leiomyoma, measured by preoperative ultrasound.

The comparative clinical findings between the study group and the control group are summarized in Table 2. In the study group, compared with the control group, the operation time was significantly reduced (60.15 ± 9.97 min vs. 71.85 ± 9.74 min), and the suturing

Table 1. Clinical characteristics between the 2 study groups.

	Experimental group	Control group	P
Age (Y)	33.30±3.84	34.35±3.53	0.374
Menstrual disorder	15	16	0.705 [#]
Pressure symptom	6	5	0.723 [#]
Pelvic pain	2	3	1.000 ^{##}
Myoma size (cm)	5.95±0.999	5.95±0.999	1.000
Preoperative hemoglobin(g/L)	95.25±11.08	95.15±13.02	0.979

[#] χ^2 test; ^{##} Fisher's exact test.

Table 2. Comparison of intraoperative data among the 2 study groups.

	Experimental group	Control group	P
Operative time (min)	60.15±9.97	71.85±9.74	0.001
Suture time (min)	18.05±4.71	28.35±3.13	0.000
Estimate blood loss (ml)	93.25±19.62	121.50±24.87	0.000
Hemoglobin drop (g/L)	8.9±1.97	11.15±2.23	0.002
Drainage indwelling time (d)	1.25±0.44	1.40±0.50	0.324
Volume of drainage (ml)	101.45±20.49	103.75±17.98	0.708
Gastrointestinal function recovery time (d)	1.4±0.50	1.5±0.51	0.537

Table 3. Operation related complications between the 2 study groups.

	Experimental group	Control group	P
Conversion to open surgery	0	0	NS
Transfusion	1	2	1.000 [#]
Postoperative bleeding	0	0	NS
Hematoma	0	0	NS
Fever	1	1	1.000 [#]
Re-operation	0	0	NS
Pelvic infection	0	0	NS
Urinary infection	0	0	NS

[#] Fisher's exact test; NS – not significant.

Table 4. Pregnancy outcome between the 2 study groups.

	Experimental group	Control group	P
Term delivery	12 (60.0%)	9 (45.0%)	0.527 [#]
Premature delivery	2 (10.0%)	3 (15%)	1.000 ^{##}
Spontaneous abortion	1 (5.0%)*	0 (0%)	1.000 ^{##}
In pregnancy	2 (10.0%)	1 (5.0%)	1.000 ^{##}
Ectopic pregnancy	0 (0%)	1 (5.0%)	1.000 ^{##}
Not pregnant or not intend to pregnant	4 (20.0%)	6 (30.0%)	0.716 ^{##}
Uterine rupture	0	0	NS

* Case 5 had one spontaneous abortion 1 year after surgery and now are in pregnant. [#] χ^2 test; ^{##} Fisher's exact test; NS – not significant.

time was significantly reduced (18.05±4.71 min vs. 28.35±3.13 min) (p<0.05). The study group, compared with the control group, had significantly less intraoperative blood loss (93.25±19.62 ml vs. 121.50±24.87 ml) (p<0.05), and a significantly less drop in hemoglobin (8.9±1.97 g/L vs. 11.15±2.23 g/L) (p<0.05). There were no significant differences between the study group and the control group for the duration of the indwelling catheter, drainage volume, and time to recovery of bowel function (p>0.05).

The comparative findings of the operative complications between the study group and the control group are summarized in Table 3. In both the study group and the control group, no change from laparoscopy to laparotomy (laparotomic conversion) or intraoperative complications occurred. Blood transfusion was given to one patient in the study group and two patients in the control group following surgery. One patient from each of the two groups had a fever following surgery. There

were no significant differences between the study group and the control group for postoperative hemorrhage, hematoma formation, ileus, secondary surgery, pelvic infection or urinary infection between the groups, and there was no incidence of uterine rupture.

Table 4 summarizes the pregnancy outcomes in the patients studied. All patients underwent transvaginal ultrasound examinations at one month and three months following surgery, and no postoperative complications or abnormalities were found. For women who wanted to conceive, pregnancy advice was given at follow-up, including advice regarding whether or not to choose an elective cesarean section for future delivery. Details of pregnancy were obtained using telephone calls. There was no significant difference between the two groups in pregnancy outcomes.

Discussion

This study included 20 patients who underwent laparoscopic myomectomy for uterine leiomyoma (fibroid) with a 'baseball' suture technique, compared with 20 patients who underwent laparoscopic myomectomy with a traditional suture method at a single center between January 2014 to November 2015. When compared with the technique of abdominal myomectomy that includes laparotomy, laparoscopic myomectomy has several advantages, including a smaller abdominal incision, more rapid patient recovery, and improved cosmetic appearance of the incisions, and is an ideal surgical treatment for women who wish to preserve their uterus and future fertility [12,13]. However, laparoscopic myomectomy is not performed under direct vision and has certain limitations. A key challenge of laparoscopic myomectomy for surgical removal of solitary uterine leiomyoma is the control of bleeding of the uterus after opening the enucleation cavity. In the past two decades, several methods have been used to reduce intraoperative blood loss, including intraoperative injection of oxytocin and/or pituitrin, ligation of the uterine arteries, and temporary uterine artery occlusion, but these methods do not always achieve satisfactory outcomes [6,7,14,15]. Therefore, a key factor in the control of intraoperative blood is the rapid and effective closure of the uterine surgical incision site.

The most common suture method used in laparoscopic myomectomy is interrupted suturing or continuous suturing of the seromuscular layer, using a 'figure of eight'-shaped method of suture closure of the enucleation cavity, all of which methods are not rapid closure methods. In both China and other countries, gynecologists have attempted to improve the efficiency of the suturing procedure in laparoscopic myomectomy, including improvements in suture materials and techniques. A barbed suture material has recently been developed in the

USA (Covidien Ltd. and Johnson & Johnson Company), which have been shown in recent studies to make the suture procedure easier and faster [16,17]. Also, Angioli et al. showed that the use of the Covidien V-Loc™ absorbable barbed suture for use in laparoscopic myomectomy reduced intraoperative blood loss because of a shorter operation time and suturing time [18]. However, the high price of the barbed suture material prevents its routine clinical use, and it is also possible that the suture barbs might cause injury to the bowel [19].

The use of improved and more rapid methods of surgical suture knot tying in laparoscopic myomectomy have also been reported, such as extra-abdominal suture pulling and knot tying techniques, which can avoid tangling and maintain the tension of the suture, including the 'Puller,' invented by Kim et al. [20].

The third approach to improving laparoscopic myomectomy is to improve the surgical suturing technique. Yuen et al. proposed a modified incision suturing method that, following complete enucleation of the leiomyoma, includes the use of an absorbable suture pulled through the abdominal wall through a puncture hole after the incision stitch is made, followed by continuous running sutures of the uterine incision while a surgical assistant constantly pulls the suture to maintain tension [21]. Yuen et al. believed that this method could overcome the difficulties in the cooperation of the principal surgeon and the assistant while using a single endoscope [21]. Tanase et al. proposed a 'bottom-up' suture technique in which the uterine leiomyoma is only partially enucleated to allow an attachment of the leiomyoma to the bottom of the enucleation cavity, followed by suturing from the bottom of the enucleation cavity while the leiomyoma is pulled aside to expose the suturing site [22]. Finally, the leiomyoma is completely enucleated after the bottom of the enucleation cavity is closed, which is a method that has been proposed to reduce blood loss and reduce the formation of dead space [22].

In the present study, when compared with the traditional suture method used in our center, the 'baseball' suture technique showed at least five main advantages. First, the technique was shown to be simple to perform, and required only single-layer sutures from the bottom of the enucleation cavity, avoiding the need for layer-by-layer suturing and the tying of multiple knots. Second, the 'baseball' suture technique reduced the formation of dead space, as the suture needle was inserted through the myotomy incision, which ensured that the suture needle reached the bottom of the enucleation cavity each time. Third, the suturing time and total operation time were reduced using 'baseball' suture technique. Fourth, this technique resulted in complete closure of the uterine incision. The fifth main advantage of the 'baseball' suture technique was that it restored the integrity of the uterus using a single suturing procedure, which meant that multiple suture

layers and tying of multiple knots were not required, and the operation time was reduced.

In this study, the 'baseball' suture technique significantly reduced the time required for surgical suturing and the total operation time by an average of 10 minutes, when compared with the control group, indicating the improved efficacy of the study technique. The reduction in the duration of the surgical procedure had several beneficial effects, including reduced intraoperative blood loss, and a reduced fall in hemoglobin levels postoperatively. The main reasons for the reduced blood loss associated with the 'baseball' suture technique were that the enucleation cavity was closed more quickly and the method resulted in compression-induced hemostasis from the edges of the myometrial surgical incision site into the enucleation cavity. Conversely, the traditional suture method can lead to slow bleeding from the needle holes due to insufficient compression, necessitating the repeated use of electrocoagulation and suturing for hemostasis. Although patient follow-up in the present study was only short-term, the uterus is more likely to undergo improved recovery of its integrity and reduced development of postoperative adhesions with no need to trim the redundant tissue of the seromuscular margins of the uterine incision. Also, the closed incision exposed only the sutured serosal surface of the uterus, which is likely to reduce the risk of postoperative adhesions.

However, the use of the 'baseball' suture technique for uterine myomectomy incision closure in laparoscopic surgical enucleation of uterine leiomyoma has certain limitations. A major challenge of the technique is that the suturing process from the incision to the seromuscular layer from the right side involves the surgeon operating in a counterclockwise direction, which might be a difficult technique for the surgeon to learn. This study also addressed the question whether the 'baseball' suture technique increased the incidence of operation-associated complications. Comparison between the study group using the 'baseball' suture technique and the control group did not show any statistically significant differences in duration of the use of an indwelling catheter, drainage volume, or return of normal bowel function following surgery. The findings of this study supported that the 'baseball' suture technique was effective and did not increase postoperative bleeding or affect the recovery of bowel function. Also, one patient in the

study group and two patients in the control group received blood transfusions due having a hemoglobin level of <70 g/L, and one patient from each of the groups had a fever following surgery, but with no significant differences between the study group and the control group. No patient in either group experienced postoperative bleeding, hematoma, pelvic infection, or urinary tract infection, supporting that the 'baseball' suture technique did not increase the risk of surgical complications.

Because this study included women of reproductive age, postoperative fertility and pregnancy outcomes were also evaluated following the 'baseball' suture technique, with the use of follow-up phone calls. There were no significant differences between the two study groups as to term delivery, rates of premature delivery, spontaneous abortion, and ectopic pregnancy. Although a previously reported study showed that, following laparoscopic myomectomy, uterine rupture was reported as 3.7% of women [23], in the present study there were no cases of postoperative uterine rupture. This finding might have been due to the limited study size, but the finding does support that the 'baseball' suture technique used in this study was safe and effective for laparoscopic myomectomy.

This study had several limitations, including the small number of patients study and the short duration of postoperative patient follow-up. The patients recruited to the study were not randomized, and the study was not controlled. However, strict patient inclusion criteria were used, and the two groups of patients studied were matched based on the size of the uterine leiomyoma to reduce study bias.

Conclusions

This observational clinical study has shown that the 'baseball' suture technique for laparoscopic uterine myomectomy, following enucleation of uterine leiomyoma, is a safe and effective suture method. However, the long-term recovery outcomes following this surgical technique require further investigation by large-scale, long-term, controlled clinical studies.

Conflict of interest

None.

References:

- Buttram VC Jr, Reiter RC: Uterine leiomyomata: Etiology, symptomatology, and management. *Fertil Steril*, 1981; 36(4): 433-45
- Gobern JM, Rosemeyer CJ, Barter JF et al: Comparison of robotic, laparoscopic, and abdominal myomectomy in a community hospital. *JSLs*, 2013; 17(1): 116-20
- ACOG Committee on Practice Bulletins-Gynecology. ACOG practice bulletin. Surgical alternatives to hysterectomy in the management of leiomyomas. Number 16, May 2000 (replaces educational bulletin number 192, May 1994). *Int J Gynaecol Obstet*, 2001; 73(3): 285-93
- Quaas AM, Einarsson JI, Srouji S et al: Robotic myomectomy: A review of indications and techniques. *Rev Obstet Gynecol*, 2010; 3(4): 185-91
- Lonnerfors C: Robot-assisted myomectomy. *Best Pract Res Clin Obstet Gynaecol*, 2018; 46: 113-19

6. Wang CJ, Lee CL, Yuen LT et al: Oxytocin infusion in laparoscopic myomectomy may decrease operative blood loss. *J Minim Invasive Gynecol*, 2007; 14(2): 184–88
7. Frederick J, Fletcher H, Simeon D et al: Intramyometrial vasopressin as a haemostatic agent during myomectomy. *Br J Obstet Gynaecol*, 1994; 101(5): 435–37
8. Dubuisson JB, Chapron C: Laparoscopic myomectomy today. A good technique when correctly indicated. *Hum Reprod*, 1996; 11(5): 934–35
9. Landi S, Zaccoletti R, Ferrari L et al: Laparoscopic myomectomy: Technique, complications, and ultrasound scan evaluations. *J Am Assoc Gynecol Laparosc*, 2001; 8(2): 231–40
10. Fujimoto A, Morimoto C, Hosokawa Y et al: Suturing method as a factor for uterine vascularity after laparoscopic myomectomy. *Eur J Obstet Gynecol Reprod Biol*, 2017; 211: 146–49
11. Sizzi O, Rossetti A, Malzoni M et al: Italian multicenter study on complications of laparoscopic myomectomy. *J Minim Invasive Gynecol*, 2007; 14(4): 453–62
12. Stoica RA, Bistriceanu I, Sima R et al: Laparoscopic myomectomy. *J Med Life*, 2014; 7(4): 522–24
13. Glaser LM, Friedman J, Tsai S et al: Laparoscopic myomectomy and morcellation: A review of techniques, outcomes, and practice guidelines. *Best Pract Res Clin Obstet Gynaecol*, 2018; 46: 99–112
14. Alborzi S, Ghannadan E, Alborzi S et al: A comparison of combined laparoscopic uterine artery ligation and myomectomy versus laparoscopic myomectomy in treatment of symptomatic myoma. *Fertil Steril*, 2009; 92(2): 742–47
15. Ji L, Jin L, Hu M: Laparoscopic myomectomy with temporary bilateral uterine artery occlusion compared with traditional surgery for uterine myomas: Blood loss and recurrence. *J Minim Invasive Gynecol*, 2018; 25: 434–39
16. Alessandri F, Remorgida V, Venturini PL et al: Unidirectional barbed suture versus continuous suture with intracorporeal knots in laparoscopic myomectomy: A randomized study. *J Minim Invasive Gynecol*, 2010; 17(6): 725–29
17. Einarsson JI, Chavan NR, Suzuki Y et al: Use of bidirectional barbed suture in laparoscopic myomectomy: Evaluation of perioperative outcomes, safety, and efficacy. *J Minim Invasive Gynecol*, 2011; 18(1): 92–95
18. Angioli R, Plotti F, Montera R et al: A new type of absorbable barbed suture for use in laparoscopic myomectomy. *Int J Gynaecol Obstet*, 2012; 117(3): 220–23
19. Burchett MA, Mattar SG, McKenna DT: Iatrogenic intestinal and mesenteric injuries with small bowel volvulus following use of barbed suture during laparoscopic myomectomy. *J Laparoendosc Adv Surg Tech A*, 2013; 23(7): 632–34
20. Kim ML, Cho YJ, Kim JM: Simplifying laparoscopic running suture line utilizing "Puller" technique: Demonstration in laparoscopic myomectomy. *Surg Endosc*, 2013; 27: 1846
21. Yuen LT, Hsu LJ, Lee CL et al: A modified suture technique for laparoscopic myomectomy. *J Minim Invasive Gynecol*, 2007; 14(3): 318–23
22. Tanase Y, Ikuma K, Matsumoto T: Novel technique for total laparoscopic myomectomy: The "bottom-up suture". *Asian J Endosc Surg*, 2011; 4(3): 150–52
23. Kim MS, Uhm YK, Kim JY et al: Obstetric outcomes after uterine myomectomy: Laparoscopic versus laparotomic approach. *Obstet Gynecol Sci*, 2013; 56: 375–81