Sirenomelia and severe caudal regression syndrome

Mohammed Z. Seidahmed, *FRCP, FRCPCH,* ***Omer B. Abdelbasit,*** *FRCPCH,* ***Khalid A. Alhussein,*** *MD,*
Abeer M. Miqdad, *MD,* ***Mohammed I. Khalil,*** *MRCOG,* ***Mustafa A. Salih,*** *Dr Med Sci, FRCPCH.*

ABSTRACT

الأهداف: وصف لحالات متلازمة حورية البحر والحالات الشديدة من متلازمة اضمحلال الجزء الذيلي من العمود الفقري وذلك لتسجيل معدل انتشار متلازمة حورية البحر ومقارنة نتائجنا مع الأبحاث الأخرى.

الطريقة: حصلنا على معلومات استرجاعية من السجلات الطبية للأطفال المشخصين بمتلازمة حورية البحر ومتلازمة اضمحلال الجزء الذيلي من العمود الفقري من السجلات الطبية لأمهاتهم من عام 1989م إلى عام 2010م في مستشفى قوى الأمن، الرياض، المملكة العربية السعودية. تم التحقق من التشخيص من قبل اختصاصي أمراض الحوامل خلال فترة حول الولادة واختصاصي عناية مركزة حديثي ولادة واختصاصي علوم الأمراض العصبية عند الأطفال واختصاصي علوم الأشعة. لقد حُددت الحالات كجزء من دراسة عيوب الأنبوب العصبي خلال تلك الفترة. تمت مراجعة المقال باستخدام محرك البحث MEDLINE.

النتائج: خلال فترة الدراسة (22 عام)، كان العدد الاجمالي من الولادات 124933 ومن بينهم تم تحديد 4 مرضى مصابين بمتلازمة حورية البحر و2 مريضين لديهم حالة شديدة من متلازمة اضمحلال الجزء الذيلي من العمود الفقري. كل مرضى متلازمة حورية البحر كان لديهم شريان سري وحيد ولم يكن أي منهم طفل لأم مصابة بداء السكري. مريض واحد كان أحد التوأمين ومريض آخر كان واحد من 3 توائم. لقد كان المريضين المصابين بمتلازمة الاضمحلال الذيلي للعمود الفقري اختين وأمهم عانت من الداء السكري نمط II وبدانة مرضية وتعالج بالأنسولين ولم يكن لدى أي منهم شريان سري وحيد . تتضمن التشوهات المرافقة الأخرى لمتلازمة حورية البحر: غياب عظم الكعبرة والإبهام و السبابة (عند أحد المرضى)، ومتلازمة بوتر وأضلاع مشوهة وصغر مقلة العين وأحد أمراض القلب الخلقية ونقص تصنع الرئة وفتق الحجاب الخلقي.

الخاتمة: إن معدل انتشار متلازمة حورية البحر هو 3.2 لكل 100000 والتي هي عالية مقارنة مع معدلات الانتشار العالمية البالغة 1 لكل 100000. كلا الحالتين المصابتين بمتلازمة اضمحلال الجزء الذيلي من العمود الفقري كانتا طفلتين لأم مصابة بداء السكري نمط II مع ضبط سيء وهذا يدعم العلاقة القوية بين متلازمة اضمحلال الجزء الذيلي من العمود الفقري والداء السكري عند الأم.

Objective: To describe cases of sirenomelia and severe caudal regression syndrome (CRS), to report the prevalence of sirenomelia, and compare our findings with the literature.

Methods: Retrospective data was retrieved from the medical records of infants with the diagnosis of sirenomelia and CRS and their mothers from 1989 to 2010 (22 years) at the Security Forces Hospital, Riyadh, Saudi Arabia. A perinatologist, neonatologist, pediatric neurologist, and radiologist ascertained the diagnoses. The cases were identified as part of a study of neural tube defects during that period. A literature search was conducted using MEDLINE.

Results: During the 22-year study period, the total number of deliveries was 124,933 out of whom, 4 patients with sirenomelia, and 2 patients with severe forms of CRS were identified. All the patients with sirenomelia had single umbilical artery, and none were the infant of a diabetic mother. One patient was a twin, and another was one of triplets. The 2 patients with CRS were sisters, their mother suffered from type II diabetes mellitus and morbid obesity on insulin, and neither of them had a single umbilical artery. Other associated anomalies with sirenomelia included an absent radius, thumb, and index finger in one patient, Potter's syndrome, abnormal ribs, microphthalmia, congenital heart disease, hypoplastic lungs, and diaphragmatic hernia.

Conclusion: The prevalence of sirenomelia (3.2 per 100,000) is high compared with the international prevalence of one per 100,000. Both cases of CRS were infants of type II diabetic mother with poor control, supporting the strong correlation of CRS and maternal diabetes.

Saudi Med J 2014; Vol. 35 Supplement 1: S36-S43

From the Division of Neonatology (Seidahmed, Abdelbasit, Alhussein), Pediatrics Department, the Obstetric and Gynecology Department (Khalil), Security Forces Hospital, and the Division of Pediatric Neurology (Salih), Department of Pediatrics, King Saud University, Riyadh, Kingdom of Saudi Arabia.

Received 20th July 2014. Accepted 28th October 2014.

Address correspondence and reprint request to: Dr. Mohammed Z. Seidahmed, Consultant Neonatologist, Department of Pediatrics, Security Forces Hospital, Riyadh 11481, Kingdom of Saudi Arabia. E-mail: zainsidahmed@hotmail.com

OPEN ACCESS

Sirenomelia, best defined by Stevenson[1] as "a limb anomaly in which the normally paired lower limbs are replaced by a single midline limb," is an extremely rare congenital malformative disorder with a prevalence of approximately one per 100,000.[2] It constitutes a spectrum of anomalies affecting primarily the musculoskeletal, genitourinary, and gastrointestinal systems. Sirenomelia is reported to be more frequent among one of 2 monozygotic twins.[3] It is considered by some authors as the severe end of a spectrum of caudal regression syndrome (CRS) ranging from ectopic anus to sirenomelia.[4,5] A single midline lower limb, and an aberrant abdominal umbilical artery (persistent vitelline artery), have been considered the chief anatomic findings that distinguish sirenomelia from CRS, otherwise, they share common features. The pathophysiology of CRS and sirenomelia is controversial. Sirenomelia, known as mermaid syndrome is thought to result from "vascular steal." In contrast, CRS is hypothesized to arise from primary deficiency of caudal mesoderm. Duesterhoeft et al[6] reported 5 cases with 4 similar cases from the literature[7,8] of nonsirenomelic CRS that exhibited an aberrant abdominal umbilical artery similar to that typically associated with sirenomelia. Their report lends support for a caudal regression-sirenomelia spectrum with a common pathogenetic basis, and they suggested that abnormal umbilical artery anatomy may be the consequence, instead of the cause of deficient caudal mesoderm. We report these cases to highlight the pathogenetic differences between CRS and sirenomelia guided by review of the literature, and to emphasize the importance of strict diabetic control before and during pregnancy.

Methods. This study included the retrospective analysis of data collected from the medical records of infants diagnosed with sirenomelia and severe CRS and their mothers between 1989 and 2010 (22 years), at the Security Forces Hospital (SFH), Riyadh, Saudi Arabia. The cases were identified as part of a study of neural tube defects during that period. A literature search was conducted using MEDLINE. Approval from the Educational Committee at SFH was obtained prior to data collection.

Disclosure. Authors have no conflict of interests and work was not supported of funded by any drug company. Prof. Mustafa A. Salih was supported by the Deanship of Scientific Research, King Saud University, Riyadh, Saudi Arabia through research group project number RGP-VPP-301.

Results. During the study period we identified 4 cases of sirenomelia, and 2 cases of severe CRS. The clinical details are summarized in **Table 1**. Patient one was delivered by cesarean section (C/S) at 36 weeks. The mother, 30-year-old gravida 2 para1+0, was not diabetic and her glucose tolerance test (GTT) was normal. There was no family history of note or relevant medications. Antenatal ultrasound (U/S) showed twin pregnancy. Twin one was normal, but twin 2 showed intrauterine growth restriction (IUGR), pericardial effusion, enlarged left heart, and abnormal spine and limbs. Birth weight was 1,000 gm (below the 3rd percentile), length was 20 cm (below the 3rd percentile), and the head circumference was 25 cm (below the 3rd percentile). Examination showed dysmorphic features (**Figure 1A**) manifesting as short neck, beaked nose with anteverted nostrils, and low set ears. The left upper limb was abnormal with redundant skin over a short forearm (**Figure 1B**), and was associated with an absent left radius, absent thumb and index fingers. The lower limbs were fused with a right-sided hypoplastic limb ending in a foot-like structure, while on the left side there was a prominent bony structure (**Figure 1C**). No anus or genitalia were identified, and there was a single umbilical artery. The back showed a mass (? meningeocele) at the lower end (**Figure 1D**). A skeletal survey (**Figure 1E**) revealed dextroscoliosis of the lumbosacral spine, absent radius, and only 3 metacarpal bones in the upper left limb. There was a single femur and tibia (type VI sirenomelia, Stocker and Heifetz).[9] Chromosome analysis showed 46XX. The other twin was a normal female. They were monochorionic diamniotic. The baby died after one hour.

Patient 2 was also delivered by C/S at 36 weeks due to breech presentation. The mother was a 32-year-old, gravida 7 para 6+0. The father was 40 years old, and the parents were first cousins. There was no family history of note. The mother was not diabetic, and her GTT during pregnancy was normal. Antenatal U/S revealed single viable fetus, breech, oligohydramnios, and IUGR. Due to severe oligohydramnios, the bladder, stomach, and spine could not be assessed. Kidneys were not visualized. (Potter's syndrome). Birth weight was 1,380 gm (below the 3rd percentile). There were dysmorphic features consisting of low set ears, bilateral microphthalmia, and short neck (**Figure 2A**). The lower limbs were fused ending with a single clubbed foot with one big toe, the back showed a small dimple at the end (**Figure 2B**), and there were no genitalia or anus. There was a single umbilical artery. The baby died within one hour. A skeletal survey revealed thin crowded ribs, sacral agenesis, partially fused femurs (**Figure 2C**). An x-ray of

Table 1 - Clinical data from 4 patients with sirenomelia, and 2 patients with caudal regression.

No.	Maternal age (years)	Gravida	Gestational age (weeks)	Gender	Twin	Maternal diabetes	Skeletal	Renal	Urogenital	Imperforate anus	Single umbilical artery	Other major malformations
1	30	2	36	F (46xx)	Yes	No	Single femur and tibia, no fibulae, absent left radius, and absent thumb and index bones (type VI sirenomelia)	NA	Absent genitalia, no bladder	Yes	Yes	Potter's facies, absent left radius, thumb, and index finger
2	32	7	36	undefined	No	No	2 femurs, 2 tibiae and single fibula (type II sirenomelia)	Absent kidneys, oligo-hydramnios	Absent genitalia, no bladder	Yes	Yes	Microphthalmia, Potter's facies
3	23	1	31	undefined	No	No	Fused lower limbs	Absent kidneys, oligo-hydramnios	Absent genitalia	Yes	Yes	Hypoplastic lungs, 2 chamber heart, Potters facies
4	24	1	35	M	Triplet 3	No	Fused lower limbs	NA	Rudimentary male genitalia	Yes	Yes	Diaphragmatic hernia, lung hypoplasia
5	28	3	Term	F	No	Yes	Hypoplastic sacrum spinal cord terminated at L3-tethered cord bilateral DDH	Normal	Normal	No	No	No
6	3	7	Term	F	No	Yes	Absent lumbosacral portion of spinal column, spinal cord terminated at T12 level, hypoplastic iliac bones fused superiorly	Left crossed ectopia, VUR (grade II)	Normal	No	No	Neurodevelopmental delay, VSD, PDA

DDH - developmental dysplasia of the hip, VUR - vesicoureteric reflux, VSD - ventricular septal defect, PDA - patent ductus arteriosus

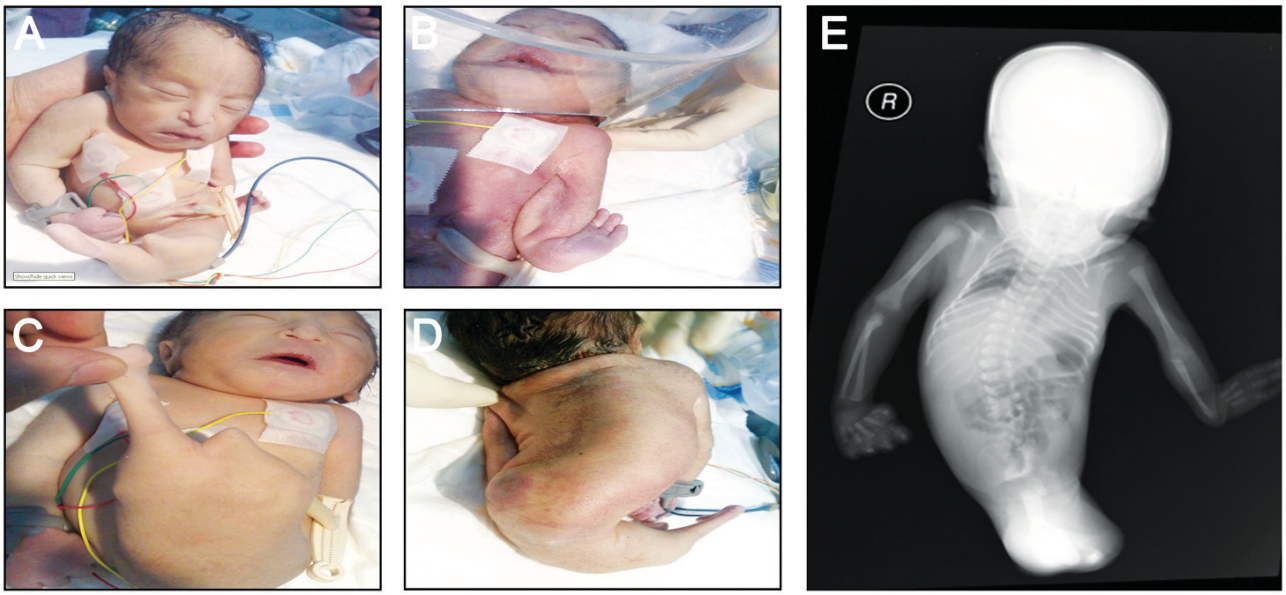

Figure 1 - Patient 1 showing: **A)** Note the short neck, beaked nose, low set ears, and fused lower limbs. **B)** There was absent left radius, absent left thumb, and index fingers. **C)** Fused lower limbs-hypoplastic right leg and toe. **D)** The back: note scoliosis and tapering of lower part of the body with meningocele. **E)** Skeletal survey showing dextroscoliosis of lumbosacral spine, absent left radius and only 3 metacarpal bones.

the lower limbs (**Figure 2D**) showed 2 tibiae and one fibula (type IV Stocker and Heifetz classification).[9]

Patient 3 was delivered normally, as 31-weeks preterm, to a 23-year-old primigravida who had primary infertility for 5 years (male factor). Antenatal screen was negative, she was not diabetic, her GTT during pregnancy was normal, and there was no history of relevant illnesses or medications. Antenatal U/S at 25 weeks revealed single viable fetus with severe oligohydramnios associated with absent kidneys, bladder, and stomach. Repeated U/S at 31 weeks showed IUGR, severe reduction of fetal movements, abnormal heart anatomy with only 2 chambers, pericardial effusion, hypoplastic lungs, and abnormal spine and lower limbs. The baby was delivered as breech, grossly malformed with beaked nose, low set ears, squashed face (Potter's features), with fused lower limbs. No genitalia or anus could be identified. There was a mass on the lumbosacral area (? meningeocele) and single umbilical artery. The baby was diagnosed as sirenomelia and Potter's syndrome (photographs not available) and survived only for few minutes after birth.

Patient 4 was one of triplets delivered by cesarean section at 35 weeks of gestation. Mother was 24-years-old with primary infertility who underwent left salpingo-oophorectomy and wedge resection of the right ovary. She was found to have twisted hemorrhagic ovarian cyst on the left and right polycystic ovary. She was diagnosed as Stein Leventhal syndrome. She had tubal fertilization and conceived triplets. This was triplet 3 who was found to have multiple anomalies consisting of fused lower limbs, imperforate anus, hypoplastic male genitalia, absent testicles, single umbilical artery, bilateral lung hypoplasia, and diaphragmatic hernia. Birth weight was 1200 gm (below the 5th centile). He expired within one hour.

Patient 5 is currently aged 14 years. She was delivered normally at term. Mother was a 28-year-old gravida 3 para 2+0 with poorly controlled type II diabetes mellitus and morbid obesity (body mass index [BMI] = 42). Her glycosylated hemoglobin was (HbA1C) was 10-14% during pregnancy. There was no relevant family history. Labor was difficult with shoulder dystocia resulting in right Erb's Palsy. Birth weight was 3,290 gm (50th centile), and length was 49 cm (50th centile). She had no facial dysmorphism, but had severe deformity of the lower limbs with fixed flexion of both hips and limitation of abduction. Both knees were held in fixed extension and there were dimples on both sides of the hips. The lower limbs were hypoplastic, fusiform, tapering to wasted legs, and the feet were small with smooth dermal ridges. Movements were minimal, and reflexes were absent. She had a neurogenic bladder and

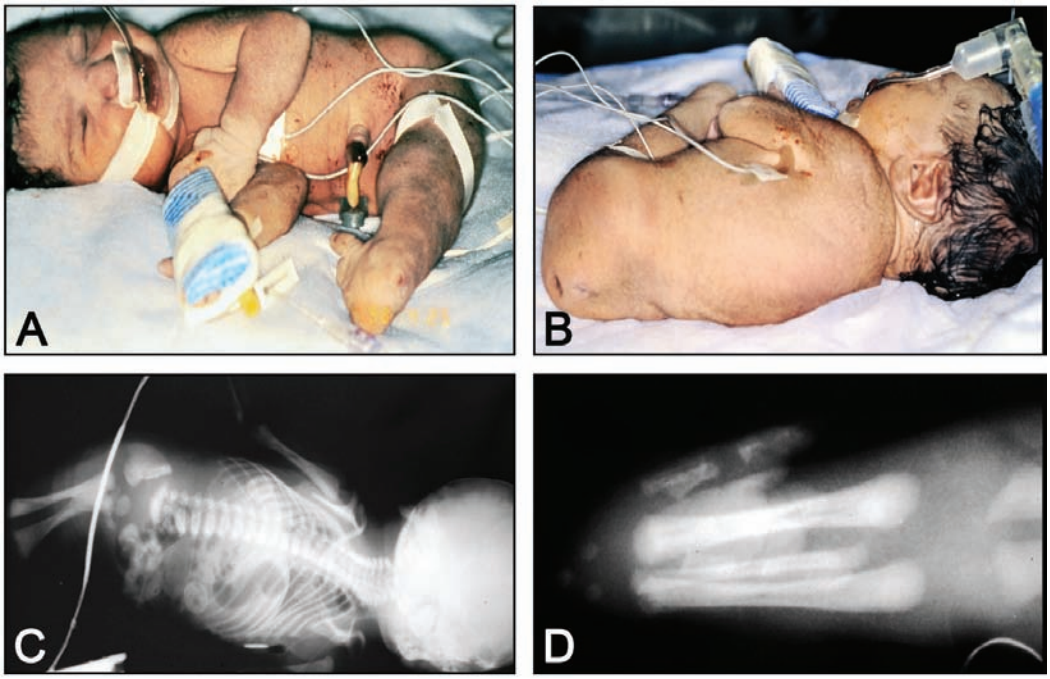

Figure 2 - Patient 2 showing: **A)** Note bilateral microphthalmia, fused lower limbs, single foot with one toe. **B)** The back showing fused buttock with a small dimple (? anal verge). Note low set ear. **C)** X-ray whole body. Note thin crowded ribs, sacral agenesis and the 2 femurs. **D)** X-ray lower limb showing 2 femurs, 2 tibiae, and one fibula (type II sirenomelia).

Figure 3 - Patient 5 MRI of spine showing hypoplastic sacrum, spinal cord terminating at L3 level (type II caudal regression syndrome), thickened filum terminale and tethered cord (arrow).

incontinence. Genitalia were normal female. A spine MRI (**Figure 3**) revealed hypoplastic sacrum, spinal cord terminated at L3 level (type II CRS, Renshaw)[10] with wedge shaped deformity. The filum terminale was thickened and the cord was tethered. Bilateral hip dysplasia was also noticed. She was diagnosed as CRS.

Patient 6 is a 4-year-old female, sister of patient 5. The mother was 38 years of age, still had poorly controlled diabetes and high HbA1C, on insulin. The baby was delivered by C/S at term, birth weight was 2,110 gm (below the 5th percentile), and length was 36 cm (below the 3rd percentile). She showed similar phenotypic features as her sister, but more severe lower limb deformities with absent movements. She had neurodevelopmental delay. She also had associated cardiac involvement, and ECHO revealed a ventricular septal defect and patent ductus arteriosus. Currently, she is a bottom shuffler and uses her upper limbs for crawling. She developed a fracture of the left femoral shaft. A skeletal survey and 3D-CT of the spine (**Figures 4A, 4B, & 4C**) showed the absence of the lumbosacral portion of the spinal column with abrupt termination of the spinal cord at T12 with significant narrowing of the spinal cord (type III CRS, Renshaw).[10] The posterior

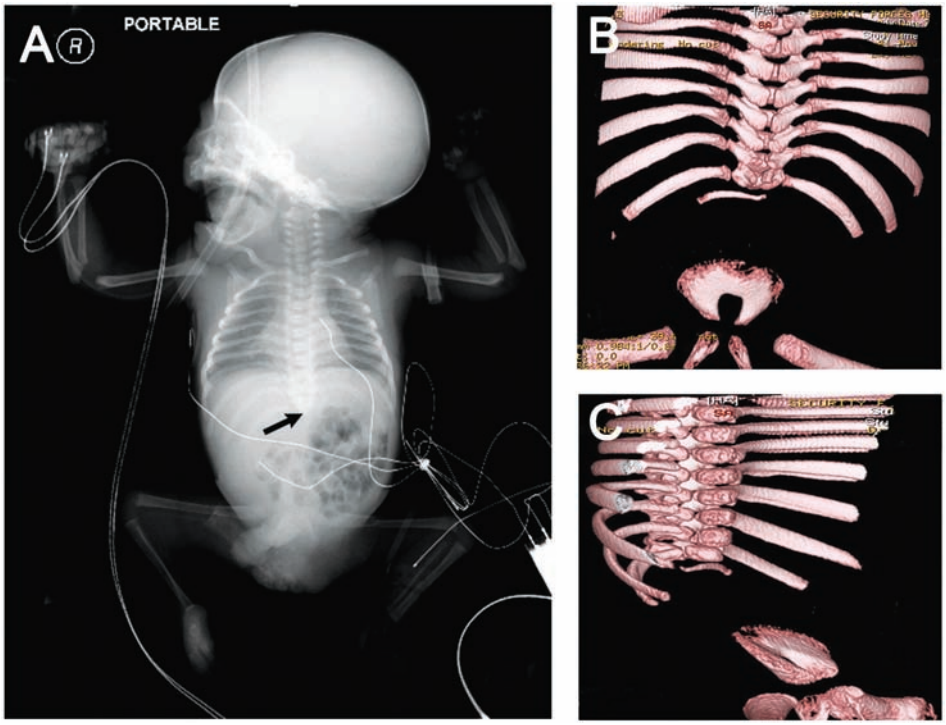

Figure 4 - Patient 6 imaging showing: **A)** Whole body X-ray. Note absent lumbosacral spine (arrow) and hypoplastic lower limbs compared to upper part of the body. **B & C)** 3D – computed tomography scan of spine. The spinal column terminates at T12. The iliac bones are hypoplastic and fused superiorly (type III caudal regression syndrome).

abdominal and paraspinal musculature were atretic below the T12 level with only a fibrotic band between the T12 spinous process and the iliac bones, which were hypoplastic and fused superiorly at the midline. A renal U/S showed low-lying right kidney fused with low-lying malrotated left kidney, and fused left crossed ectopia. Her renal functions were normal. Micturating cystourethrogram showed Grade II vesicoureteric reflux on the right side. She was diagnosed as a severe form of CRS.

Discussion. The syndrome of caudal regression was first used by Duhamel[4] in a paper presented to a meeting of the British Association of Pediatric Surgeons in 1960 to describe a spectrum of congenital malformations, which consist of anomalies of the rectum, the urinary, and genital systems, the lumbosacral spine, and the lower limbs. The most severe end of the spectrum is the fusion of the lower limbs and the major organ malformations, known as sirenomelia or mermaid syndrome, while the mildest end is imperforate anus. A debate still exists to whether CRS and sirenomelia are separate entities or whether they represent parts of a pathogenic spectrum. Duhamel[4] endorsed a CRS-sirenomelia spectrum that encompasses variable severities of "an embryonal defect in the formation of the caudal region."

In contrast, Jones[11] segregated sirenomelia from CRS and asserted that the 2 are unrelated pathogenetically. Apart from fusion of the lower extremities, a distinctive anatomic feature of sirenomelia is an umbilical artery that arises aberrantly from the abdominal aorta, called "persistent vitelline artery".[12] This aberrant vessel is the basis for the hypothesis that sirenomelia results from "vascular steal" with diversion of the blood away from the caudal embryo through the ectopic umbilical artery.[13] Our 4 cases of sirenomelia reported in this paper support this "vascular steal" theory as all of them exhibited single umbilical artery.

However, the "vascular steal" theory as being specific for sirenomelia was refuted by reports of 9 cases of non-sirenomelic CRS associated with an aberrant abdominal umbilical artery, giving further support for a CRS-sirenomelia spectrum, with a common pathogenetic basis.[6-8] A pathogenetic link between sirenomelia and CRS is indicated by a family with 5 affected individuals, 3 with CRS, and 2 with sirenomelia.[14] There is also a report of discordant monozygotic twins, one with sirenomelia and the other with anal atresia.[15] Abnormal umbilical arteries are not an invariable feature of sirenomelia since rare examples of normal umbilical arteries have been reported with sirenomelia.[16]

One of our patients with sirenomelia (patient 3) was a monozygotic twin, whereas another was one of monozygotic triplets (patient 4). This supports the reports of the high rate of monozygotic twinning quoted for sirenomelia, accounting for 10-15% of occurrences in monozygotic twin births.[3] There is an association between sirenomelia and/or CRS and VACTERL (vertebral, anal, cardiac, tracheo-esophageal fistula, renal, and limb).

Two of our patients (one and 3) had 5 of the components of VACTERL without trachea-esophageal fistula, which might have been missed as the babies died within one hour of birth. The severity of the component defects in sirenomelia, especially in the gastrointestinal and genitourinary systems can explain the presence of the component defects of VACTERL. Szumska et al 2008,[17] noted that mutation PcsK5 in the mouse produced VACTERL - caudal regression - Currarino syndrome - like malformations. Castori et al[18] reported the association of sirenomelia and VACTERL in the offspring of a woman with diabetes. Lhuaire et al[19] reported a case of sirenomelia associated with VACTERL with Thomas syndrome. Sirenomelia as part of VACTERL association was reported in 3 cases by Charlier et al.[20] Moosa et al[21] reported 4 cases of sirenomelia/CRS associated with VACTERL, which supports the theory that these entities maybe different manifestations of a single pathogenetic process. Our cases also support this theory.

Classification of sirenomelia. Stocker and Heifetz[9] classified sirenomelia in 7 types: I, all thigh and leg bones present. II, single fibula. III, absent fibulae. IV, partially fused femurs, fused fibulae. V, partially fused femurs, absent fibulae. VI, single femur, single tibia. VII, single femur absent tibiae.

It is noteworthy that 2 of our patients (patients 5 and 6) were sisters with severe CRS, their mother had morbid obesity and poorly controlled type II diabetes with high levels of HbA1C 10-14% during pregnancy. None of the patients with sirenomelia were associated with maternal diabetes (**Table 1**). This finding supports the reports that sirenomelia is rarely associated with maternal diabetes.[20] Kucera[22] and Mills[23] reported 200 fold increased risk of CRS with maternal diabetes. Zaw and Stone[24] described an unusual case of CRS affecting only one of a set of monozygotic twins suggesting that as yet undefined factors other than hyperglycemia are operating in its pathophysiology.

The teratogenic insult in diabetic embryopathy occurs from the third to seventh weeks of gestation at the initiation of organogenesis.[25] In rats. uncontrolled diabetes produced lumbosacral malformations only

during the period of organ differentiation.[26] The fetus appears to be vulnerable to hyperglycemic insult during this period of organogenesis as maternal insulin does not cross the placenta and fetal insulin is not produced before the eighth week of development.[27] Therefore, stable and good diabetic control in the periconceptional period and throughout pregnancy, particularly during the early trimester, is of paramount importance to prevent congenital malformations.[23] The mother of the 2 patients with CRS (patients 5 and 6) had type II diabetes mellitus and morbid obesity with HbAIC ranging from 10-14% during both pregnancies. The degree of CRS was more severe in the second patient (patient 6), with complete absence of the lumbosacral segment (**Figure 4**). This is due to the long standing poor diabetic control. Miller et al[28] found no major anomalies if the HbAIC was less than 6.9%, and significantly lower incidence if HbAIC was less than 8.5%. Green et al[29] observed a 3% risk of major malformations with HbAIC of 9.3%, and 40% with HbAIC more than 14.4%. Therefore, there is convincing evidence that preconception counseling reduces the incidence of congenital anomalies in women with diabetes mellitus.

Classification of caudal regression syndrome. Renshaw[10] classified the spectrum of CRS into 5 types based on type of defect and articulation between bones. Type 1 has total or partial unilateral sacral agenesis; type II has variable lumbar and total sacral agenesis and the ilia articulates with the sides of the lowest vertebra; type III has variable lumbar and total sacral agenesis and the caudal end plate of the lowest vertebra rests above fused ilia or an iliac amphiarthrosis; type IV has fusion of soft tissues in both lower limbs; and type V, also known as sirenomelia, has fused bones of lower limbs.

The association of absent radius, thumb, and index finger in one of our patients (patient one) with sirenomelia is interesting, it opposes the caudal blastogenesis theory and supports the "vascular steal" theory or other genetic factors playing a role. Lynch and Wright[30] reported a case where the mother had diabetes and the infant had sirenomelia with renal agenesis and an absent right radius similar to our patient (patient one) who also had absent thumb and index finger. Taori[31] reported a case of sirenomelia with absent radii bilaterally, and absent thumb. Halder et al[32] described a case of sirenomelia sequence associated with craniorachischisis totalis, limb reduction, and primitive heart. The left upper limb showed ill defined hypoplastic humerus, which ended at the midshaft, a limb reduction defect indicating chronic vascular insufficiency. Santra et al[33] also reported a case of sirenomelia with hypoplastic right radius and ulna and absent carpal metacarpal and phalangeal bones, whereas Kulkarni et al[34] reported a case of sirenomelia with radial dysplasia.

Based on these reports and our patient (patient one), we hypothesize that the underlying pathogenetic cause of sirenomelia is a vasculopathy of varying degrees of vascular involvement, especially considering that all the associated defects were reduction defects. Autopsy is helpful in determination of the extent of these associated defects, but due to cultural norms and beliefs autopsy is not practiced in some countries.

A large epidemiologic study by Orioli et al[2] described the prevalence, associated malformations, and maternal characteristics among cases with sirenomelia. Data originated from 19 birth defect surveillance system members of the international clearing house for Birth Defects Surveillance and Research.[2] A total of 249 cases with sirenomelia were identified among 25,290,172 births, giving prevalence of 0.98 per 100,000. At the SFH, Riyadh, Saudi Arabia during the study period 1989-2010 (22 years), we identified 4 cases of sirenomelia out of total births of 124,933 with a prevalence of 3.2 per 100,000, which is 3 times higher than the internationally quoted prevalence of one in 100,000. This high rate may be related to genetic factors.

In conclusion, the prevalence of sirenomelia at SFH Riyadh is high compared with the international prevalence. This may be due to the high consanguineous marriages in Saudi Arabia with underlying genetic predisposition and other factors like maternal diabetes mellitus, which is strongly associated with CRS for which strict control is required preconceptionally and during pregnancy. With the advances of molecular technologies, the genetic basis of these disorders can be unraveled. Further research with animal models are needed to identify the underlying pathogenetic process of these disorders.

Acknowledgments. *We thank Bing Borromeo of the Department of Pediatrics for manuscript preparation, and Mandy Sarmiento from Medical Photography, Academic and Health Education Department at Security Forces Hospital, Riyadh, Kingdom of Saudi Arabia.*

References

1. Stevenson RE. Limbs. In: Stevenson RE, Hall JG, editors. Human malformations and related anomalies. 2nd ed. New York (NY): Oxford University Press; 2006. p. 835-925.
2. Orioli IM, Amar E, Arteaga-Vazquez J, Bakker MK, Bianca S, Botto LD, et al. Sirenomelia: an epidemiologic study in a large dataset from the International Clearinghouse of Birth Defects Surveillance and Research, and literature review. ***Am J Med Genet C Semin Med Genet*** 2011; 157C: 358-373.

3. Valenzano M, Paoletti R, Rossi A, Farinini D, Garslaschi G, Fulcheri E. Sirenomelia. Pathological features, antenatal ultrasonographic clues, and a review of current embryogenic theories. ***Hum Reprod Update*** 1999; 5: 82-88.
4. Duhamel B. From the mermaid to anal imperforation: The syndrome of caudal regression. ***Arch Dis Child*** 1961; 36: 152-154.
5. Swischuk LE. Radiology of the Newborn and Young Infant. 3rd ed. Baltimore (MD): Williams & Wilkins; 1981.
6. Duesterhoeft SM, Ernst LM, Siebert JR, Kapur RP. Five cases of caudal regression with an aberrant abdominal umbilical artery: Further support for a caudal regression-sirenomelia spectrum. ***Am J Med Genet Part A*** 2007; 143A: 3175-3184.
7. Perez-Aytes A, Montero L, Gomez J, Paya A. Single aberrant umbilical artery in a fetus with severe caudal defects: Sirenomelia or caudal dysgenesis. ***Am J Med Genet*** 1997; 69: 409-412.
8. Chaurasia BD. Single umbilical artery with caudal defects in human fetuses. ***Teratology*** 1974; 9: 287-297.
9. Stocker JT, Heifetz SA. Sirenomelia. A morphological study of 33 cases and review of the literature. ***Perspect Pediatr Pathol*** 1987; 10: 7-50.
10. Renshaw S. Sacral agenesis. ***J Bone Joint Surg*** 1978; 60: 373-383.
11. Jones KL. Smith's Recognizable Patterns of Human Malformation. Philadelphia (PA): WB Saunders Co; 1997.
12. Jones KL. Smith's Recognizable Patterns of Human Malformation. Philadelphia (PA): Elsevier Saunders; 2006. p. 728-729.
13. Stevenson RE, Jones KL, Phelan MC, Jones MC, Barr M Jr, Clericuzio C, et al. Vascular steal: the pathogenetic mechanism producing sirenomelia and associated defects of the viscera and soft tissues. ***Pediatrics*** 1986; 78: 451-457.
14. Rudd NL, Klimek ML. Familial caudal dysgenesis: evidence for a major dominant gene. ***Clin Genet*** 1990; 38: 170-175.
15. Akbiyik F, Balci S, Akkoyun I, Aktaş D, Cakmak O. Type 1 sirenomelia in one of male twins, with imperforate anus in the other male twin. ***Clin Dysmorphol*** 2000; 9: 227-229.
16. Opitz JM, Zanni G, Reynolds JF Jr, Gilbert-Barness E. Defects of blastogenesis. ***Am J Med Gent*** 2002; 115: 269-286.
17. Szumska D, Pieles G, Essalmani R, Bilski M, Mesnard D, Kaur K, et al. VACTERL/caudal regression/Currarino syndrome-like malformations in mice with mutation in the proportion convertase PcsK5. ***Genes Dev*** 2008; 22: 1465-1477.
18. Castori M, Silvestri E, Cappellacci S, Binni F, Sforzolini GS, Grammatico P. Sirenomelia and VACTERL association in the offspring of a woman with diabetes. ***Am J Med Genet A*** 2010; 152A: 1803-1807.
19. Lhuaire M, Jestin A, Boulagnon C, Loock M, Doco-Fenzy M, Gaillard D, et al. Sirenomelia: a new type, showing VACTERL association with Thomas syndrome and a review of literature. ***Birth Defects Res A Clin Mol Teratol*** 2013; 97: 123-132.
20. Charlier P, Valat AS, Boute O, Petit S, Chafiotte C, Huynh-Charlier I, et al. [Sirenomelia as a part of VACTERL association: a study of three cases]. ***Ann Pathol*** 2008; 28: 176-181. French.
21. Moosa S, Lambie LA, Krause A. Sirenomelia: four further cases with discussion of associated upper limb defects. ***Clin Dysmorphol*** 2012; 21: 124-130.
22. Kucera J. Rate and type of congenital anomalies among offspring of diabetic women. ***J Reprod Med*** 1971; 7: 73-92.
23. Mills JL. Malformations in infants of diabetic mothers. ***Teratology*** 1982; 25: 385-394.
24. Zaw W, Stone DG. Caudal Regression Syndrome in twin pregnancy with type II diabetes. ***J Perinatol*** 2002; 22: 171-174.
25. Mills JL, Baker L, Goldman AS. Malformations in infants of diabetic mothers occur before the seventh gestational week. Implications for treatment. ***Diabetes*** 1979; 28: 292-293.
26. Baker L, Egler JM, Klein SH, Goldman AS. Meticulous control of diabetes during organogenesis prevents congenital lumbosacral defects in rats. ***Diabetes*** 1981; 30: 955-959.
27. Steinke J, Driscoll SG. The extractable insulin content of pancreas from fetuses and infants of diabetic and control mothers. ***Diabetes*** 1965; 14: 573-578.
28. Miller E, Hare JW, Cloherty JP, Dun PJ, Gleason RE, Soeldner JS, et al. Elevated maternal hemoglobin A1c in early pregnancy and major congenital anomalies in infants of diabetic mothers. ***N Engl J Med*** 1981; 304: 1331-1334.
29. Greene MF, Hare JW, Cloherty JP, Benacerraf BR, Soeldner JS. First-trimester hemoglobin A1c and risk for major malformation and spontaneous abortion in diabetic pregnancy. ***Teratology*** 1989; 39: 225-231.
30. Lynch SA, Wright C. Sirenomelia, limb reduction defects, cardiovascular malformation, renal agenesis in an infant born to a diabetic mother. ***Clin Dysmorphol*** 1997; 6: 75-80.
31. Taori KB, Mitra K, Ghonga NP, Gandhi RO, Mammen T, Sahu J. Sirenomelia sequence (mermaid): Report of three cases. ***Indian J Radiol Imaging*** 2002; 12: 399-401.
32. Halder A, Pahi J, Chaddha V, Agarwal SS. Sirenomelia sequence associated with craniorachischisis totalis, limb reduction and primitive heart. ***Indian Pediatrics*** 2001; 38: 1041-1045.
33. Santra G, Pandit N, Sinha PK, Das MK. Sirenomelia. ***N Z Med J*** 2011; 124: 91-95.
34. Kulkarni ML, Abdul Manaf KM, Prasannakumar DG, Kulkarni PM. Sirenomelia with radial dysplasia. ***Indian J Pediatr*** 2004; 71: 447-449.