

Primary sacrococcygeal chordoma with unusual skeletal muscle metastasis

Lisa Vu, MD, and Tamara Miner Haygood, PhD, MD

Chordomas are rare neoplasms that do not often metastasize. Of the small percent that do metastasize, they involve skeletal muscle very infrequently. Only a few cases of skeletal muscle metastases have been reported in the literature. We report an unusual case of a patient with a primary sacrococcygeal chordoma who experienced a long period of remission but who subsequently developed recurrence and multiple metastatic lesions to skeletal muscles including the deltoid, triceps, and pectineus.

Case report

A 50-year-old gentleman initially presented with chronic pelvic pain. Clinical workup included an MRI, which demonstrated a large sacrococcygeal mass. The 10-cm mass was surgically removed, and pathology revealed a chordoma with negative margins. Postoperative adjuvant radiation therapy was delivered to the region. Immediate posttreatment MRI demonstrated no residual or recurrent tumor, and the patient was placed under routine surveillance.

After a quiescent 7 years, an MRI of the pelvis obtained for routine followup revealed recurrent disease extending from the midline sacrum into the right gluteus maximus muscle. The recurrent tumor, surgically removed, measured 13 cm with negative margins. Given the full dose of radiation already delivered to the site, no further radiation treatment was offered. The patient underwent continued surveillance.

One year later, the patient developed two additional masses in the right upper thigh. These masses were resected, with the largest measuring up to 6cm. Pathology again confirmed chordomas. Within the following year, additional thigh chordomas recurred and were resected. At about the same time, the patient also developed a palpable,

small, subcentimeter nodule in the left occipital scalp. The lesion was excised and proven to be a chordoma. A few months later, the patient felt new nodularity in the same region. MRI of the brain revealed a T2-hyperintense, mildly enhancing nodule with restricted diffusion in the left occipital scalp (Fig. 1). This was presumed also to represent a metastatic lesion.

The patient was treated with a number of varying chemotherapy regimens but continued to demonstrate disease progression. MRI of the pelvis continued to show an enlarging solid and cystic right gluteal mass extending from the midline sacrococcygeal region. Imaging also demonstrated a metastatic implant in the right pectineus muscle (Fig. 2).

The patient continued on chemotherapy but still developed additional metastatic lesions. Most recently in his course, he noticed palpable nodules in his right upper extremity. MRI revealed two T2-hyperintense, avidly enhancing nodules, one in the anterior deltoid muscle and one in the medial head of the triceps (Figs. 3 and 4). These lesions are presumed to represent further distant metastases, given the already proven metastatic disease.

Discussion

Chordomas are rare neoplasms that arise from remnants of the notochord (1, 2). They account for only 2-4% of primary bone malignancies. These tumors primarily arise from the sacrococcygeal region (50%), spheno-occipital region (35%), and other spinal segments (15%). Though typically slow-growing and with a relatively low rate of metastasis, they often have a poor outcome due to their local aggressiveness, with the primary tumor recurring after treatment in 46-70% of patients (2). Given their delicate areas of involvement, complete surgical resection can be

Citation: Vu L, Haygood TM, Primary sacrococcygeal chordoma with unusual skeletal muscle metastasis. *Radiology Case Reports*. (Online) 2014;9(4):921.

Copyright: © 2014 The Authors. This is an open-access article distributed under the terms of the Creative Commons Attribution-NonCommercial-NoDerivs 2.5 License, which permits reproduction and distribution, provided the original work is properly cited. Commercial use and derivative works are not permitted.

The authors are affiliated with the University of Texas MD Anderson Cancer Center, Houston TX. Contact Dr. Vu at lvu1@mdanderson.org

Competing Interests: The authors have declared that no competing interests exist.

DOI: 10.2484/rcr.v9i4.921

Primary sacrococcygeal chordoma with unusual skeletal muscle metastasis

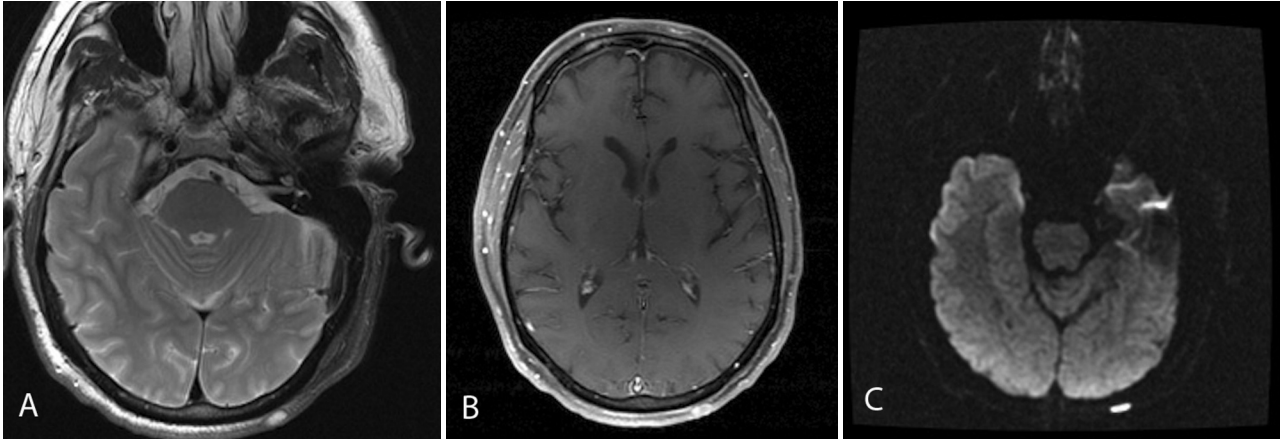


Figure 1. A. Axial FLAIR MR image through the brain shows a subcentimeter, hyperintense, superficial lesion in the left scalp. B. Axial T1-weighted, postcontrast image shows mild heterogeneous postcontrast enhancement. C. Axial diffusion-weighted image indicates restricted diffusion.

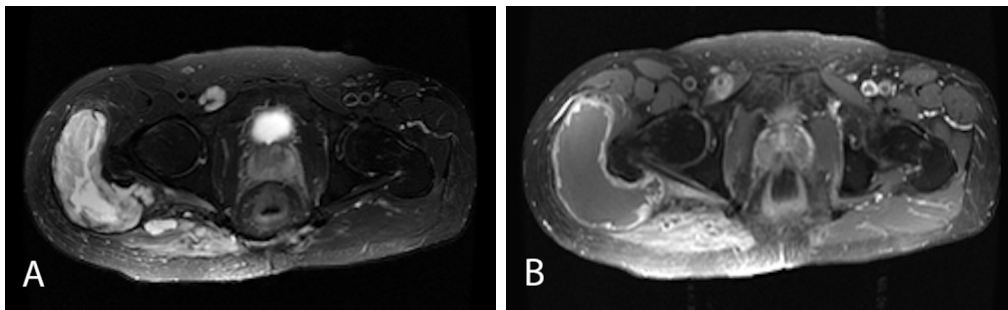


Figure 2. A. Axial T2: Hyperintense, T2 infiltrative mass extends into the right gluteus maximus with solid and cystic components and an additional lesion situated within the right pectineus muscle. B. Axial T1 postcontrast: The right gluteus maximus lesion demonstrates rim enhancement around the cystic components and more solid enhancement in the medial aspect of the muscle. The lesion in the pectineus avidly enhances.

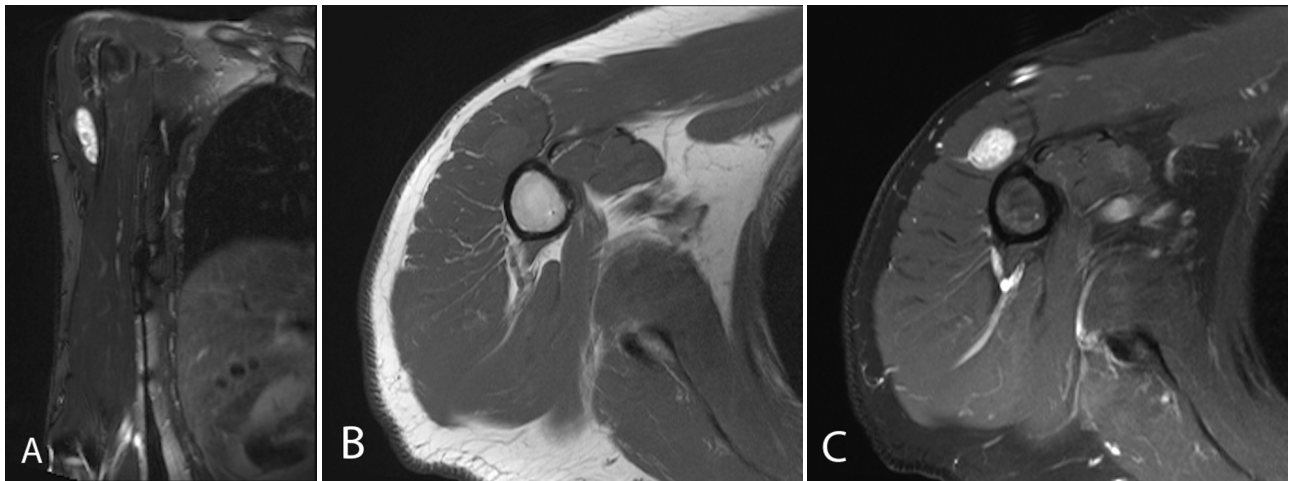


Figure 3. A. Coronal, T2-weighted, fat-saturated sequence demonstrates a hyperintense ovoid lesion in the anterior deltoid muscle. B. It is isointense to muscle on the axial T1-weighted sequence. C. Heterogeneous enhancement is demonstrated on the axial, T1-weighted, fat-suppressed, postcontrast image.

Primary sacrococcygeal chordoma with unusual skeletal muscle metastasis

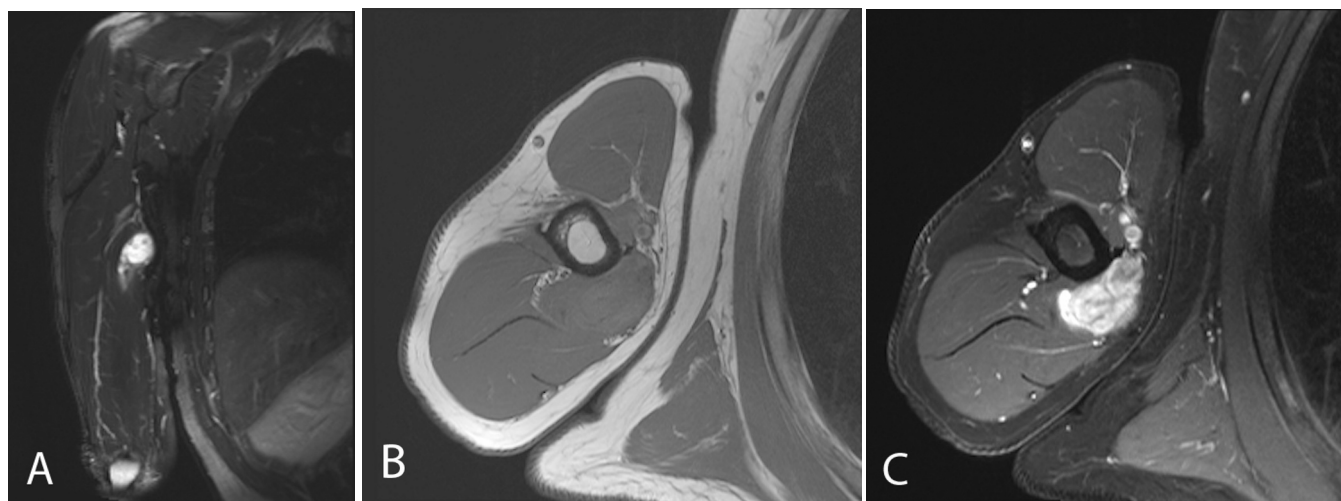


Figure 4. A. The coronal T2-weighted sequence demonstrates a near-homogeneous, hyperintense lesion in the medial head of the triceps. B. The lesion is predominantly isointense to muscle on the axial T1-weighted sequence. C. It demonstrates heterogeneously avid enhancement on the axial, postcontrast, T1-weighted, fat-saturated image.

Author	Publication date	Sites of metastasis
Stewart et al (8)	Sept 1921	superficial flat muscles of the back
Chalmers et al (9)	August 1960 and 1972	triceps, brachialis, biceps, thenar muscle, extensor carpi radialis brevis, deltoid, gluteus maximus, and quadriceps
Wang et al (10)	July 1968	unspecified skeletal muscles
Whitaker et al (11)	May 1969	peroneus longus and deltoid
Yarom et al (12)	March 1970	temporal muscle, pectoralis major, psoas
Kishimoto et al (13)	2012	several patients with nine unspecified sites to muscle

difficult. Treatment is radical surgical resection and/or radiation treatment. Currently, systemic chemotherapy has not been shown to be effective (3). In a study by McMaster et al. that studied 361 cases of first primary chordoma from 1973 through 1995, the mean survival was reported to be 6.29 years, and the 5- and 10-year survival rates were 67% and 40% (4). Similarly, in a study by Smoll et al., analysis of over 1,000 patients from 1973 to 2009 indicated a relative survival of 72% and 39% at 5 and 20 years, respectively (5).

Metastases from chordomas have been reported to occur in anywhere from 5 to 43% of patients. In a study by Kishimoto et al., about 25% of 198 patients demonstrated metastases (1). Given the rarity of the lesion, the nature of its metastasis is not fully known. The limited literature most commonly cites metastatic implants more frequently in the lung, skin, subcutaneous tissue, and bone (1-3, 6). Skeletal muscle involvement is very uncommon and has been reported only in a few cases in the literature (Table).

In general, skeletal muscles have been considered an uncommon site for metastasis from any primary tumor. Though recent data does suggest that skeletal muscle metastases may not be as infrequent as previously projected, the more commonly reported cases involve primary tumors from lung, breast, kidney, and melanoma (7). Given the limited reports of skeletal muscle metastasis specifically from chordomas, it appears that though muscle involvement from other primary tumors may not be as rare as once thought, those from chordomas are still quite unusual. Our case illustrates another uncommon example of metastasis to skeletal muscle.

References

1. Kishimoto R, Omatsu T, Hasegawa A, Imai R, Kandatsu S, Kamada T. Imaging characteristics of metastatic chordoma. *Jpn J Radiol.* 2012 May; 30:509-516. [\[PubMed\]](#)
2. Sung, MS, Lee GK, Kang HS, Kwon ST, Park JG, Suh JS, Cho GH, Lee SM, Chung MH, Resnick D. Sacrococcygeal chordoma: MR imaging in 30 patients. *Skeletal Radiol.* 2005; 34:87-94. [\[PubMed\]](#)
3. Stacchiotti S, Casali PG. Systemic therapy options for unresectable and metastatic chordomas. *Curr Oncol Rep.* 2011 May; 13: 323-330. [\[PubMed\]](#)
4. McMaster ML, Goldstein AM, Bromley CM, Ishibe N, Parry DM. Chordoma: incidence and survival pat-

Primary sacrococcygeal chordoma with unusual skeletal muscle metastasis

- terns in the United States, 1973-1995. *Cancer Causes Control*. 2001 Jan;12(1):1-11. [\[PubMed\]](#)
5. Smoll NR, Gautschi OP, Radovanovic I, Schaller K, Weber DC. Incidence and relative survival of chordomas: The standardized mortality ratio and the impact of chordomas on a population. *Cancer* June 2013; 119(11):2029-37. [\[PubMed\]](#)
 6. Vergara G, Belinchon B, Valcarcel F, Veiras M, Zapta I, Torre A. Metastatic disease from chordoma. *Clin Transl Oncol*. 2008 April; 10:517-521. [\[PubMed\]](#)
 7. Haygood, TM, Wong J, Cha Lin J, Li S, Matamoros A, Costelloe CM, Yeung H, Sandler CM, Nunez RF, Kumar R, Madewell JE. Skeletal muscle metastases: a three-part study of a not-so-rare entity. *Skeletal Radiol*. 2012; 41:899-909. [\[PubMed\]](#)
 8. Stewart M. J. Malignant sacrococcygeal chordoma. *J Pathol*. 1922 Sept; 25: 40-62. doi: 10.1002
 9. Chalmers J and Coulson, WF: A Metastasising chordoma. *J Bone Joint Surg Br*. 1960 Aug; 42B(3): 556-559. [\[PubMed\]](#)
 10. Chalmers J and Heard BE. A metastasing chordoma: a further note. *J Bone Joint Surg*. 1972 Aug; 54B(3): 526-529. [\[PubMed\]](#)
 11. Wang CC and James AE, Chordoma: Brief review of the literature and report of a case with widespread metastases. *Cancer* 1968; 22: 162-167. [\[PubMed\]](#)
 12. Whitaker RH and Cast IP. Prolonged survival in a case of sacrococcygeal chordoma with metastasis. *Brit J Surg* May 1969. 56(4): 392-395. [\[PubMed\]](#)
 13. Yarom, Rena and Horn . Sacrococcygeal chordoma with unusual metastasis. *Cancer*. March 1970. 25: 659-662 [\[PubMed\]](#)