

Plasmacytoid variant of urothelial carcinoma: Diagnostic challenges and role of immunohistochemistry

Zeeba S. Jairajpuri, Safia Rana, Manal Ashraf Ali, Sujata Jetley

Department of Pathology, Hamdard Institute of Medical Sciences and Research, Jamia Hamdard, New Delhi, India

ABSTRACT

Plasmacytoid carcinoma of the urinary bladder or plasmacytoid urothelial carcinoma (PUC) is rare and only recently described a histological variant of transitional cell carcinoma. The morphological resemblance of PUC to other malignancies is a source of diagnostic dilemmas and often misdiagnosis. Immunohistochemistry plays a pivotal role in narrowing the differential diagnosis and reaching to a conclusive diagnosis. A diagnosis of PUC usually carries a dismal prognosis. Hence, correct diagnosis is important. We report here a 52-year-old male with a plasmacytoid variant of urothelial carcinoma.

Key words: Bladder, plasmacytoid, urothelial carcinoma

Submission: 16-08-2014 **Accepted:** 20-04-2015

INTRODUCTION

Urothelial carcinoma of the urinary bladder and renal pelvis are known to have a propensity for divergent differentiation. They form the second most common urological malignancy in males, comprising of a group of histopathologically different tumors and encompasses different rare forms. The World Health Organization (WHO) Classification (2004) recognizes and describes several variant morphologies.^[1] Such divergent tumors, which are extremely rare and difficult to characterize histologically, are challenging for pathologists and may have similar unfavorable clinical courses as well.^[2]

Plasmacytoid carcinoma of the urinary bladder or plasmacytoid urothelial carcinoma (PUC) is one such rare and only recently described a histological variant of transitional cell carcinoma. It is an aggressive variant and may be confused with plasmacytoma and lymphoma,^[3] a high index

of suspicion for both urologist and pathologist is essential to avoid a misdiagnosis. We report here an interesting case of plasmacytoid carcinoma of the urinary bladder in a 52-year-old male, which posed diagnostic difficulties on histopathology.

CASE REPORT

A 52-year-old male patient presented to the urology outpatient department with a history of decreased urine passage along with burning, hematuria and pain lower back and abdomen. History of loss of appetite, vomiting was also elicited, he also gave a history of smoking and alcohol consumption. Patient was advised an ultrasonogram (USG) along with biochemical and hematological investigation. Routine examination of urine was done which revealed few red blood cells. No atypical or malignant cells are seen in three consecutive specimen of urine for cytology. His renal function tests were markedly deranged, with blood urea 346 mg/dl, serum creatinine 25 mg/dl and deranged electrolytes. His blood pressure was raised 230/100 mmHg and fundoscopy showed hypertensive retinopathy. USG showed features of cystitis with hypoechoic areas extending into the thickened bladder wall with features of pyelonephritis. An infective pathology was offered as diagnosis on imaging. A clinical diagnosis of bilateral obstructive uropathy due to tumor with chronic kidney disease was made, and the patient was put on hemodialysis and cystoscopy planned at a later date. Cystoscopy findings were of a growth with small fronds/papillae, prominent at the bladder neck with a very rigid thickened bladder wall.

Address for correspondence: Prof. Sujata Jetley,
Department of Pathology, Hamdard Institute of Medical Sciences and Research, Hamdard Nagar, New Delhi - 110 062, India.
E-mail: sujatajetley@gmail.com

Access this article online	
Quick Response Code:	Website: www.ijabmr.org
	DOI: 10.4103/2229-516X.165368

Trans urethral resection of the bladder tumor was done and sent for histopathological evaluation. The microscopic evaluation showed a high-grade tumor arranged in discohesive cords and sheet with plasmacytoid features and prominent retraction artifact [Figure 1] penetrating through the entire bladder wall into the serosa. Histopathological features of the malignant epithelial cells were uncommon and lead to a differential diagnosis of undifferentiated transitional carcinoma, metastatic or primary lymphoma plasmacytoma, lymphoepithelioma-like bladder carcinoma and a plasmacytoid variant of bladder tumor. Immunohistochemistry was done for CD138, cytokeratin (CK) CK7, leukocyte common antigen (LCA), κ and λ light chain, with positivity for CK7, CD138 [Figures 2 and 3] and negative for other markers. Based on these findings, a final histopathological diagnosis of PUC was made. The patient was advised to undergo palliative cystectomy, however he is lost to follow-up.

DISCUSSION

An increasing experience in recent years with urothelial carcinomas has been the identification of several unusual variants. The recognition of these lesions is important in determining the clinical outcome and defining relevant therapeutic modalities, as well as the awareness, may be critical in avoiding diagnostic misinterpretations.^[4] The plasmacytoid variant of urothelial carcinoma is a relatively newer recognized variant described in the latest WHO classification of urothelial carcinomas.^[1] The clinical, pathological and immunohistochemical data of this particular variant is limited.^[5] However it is known to be an aggressive tumor seen in the elderly patients^[6] with hematuria as the presenting symptom, as seen in the present case, however in addition our patient had obstructive uropathy. The most common presenting symptom for diagnosis is hematuria, generally accompanied by urgency, frequent micturition and/or lower abdominal pain.

The histopathological evaluation shows the characteristic cytological features plasmacytoid appearance of the tumor cells, which are polygonal and round cells with eccentric nuclei in the abundant cytoplasm.^[7] Nested and discohesive pattern of tumor clusters is seen with single cell files and cords infiltrating deep into the bladder wall.^[8] Our case also showed similar findings. Several authors have described similar morphological features.^[4,9] The nuclear features vary from hyperchromatic to vesicular with evenly distributed chromatin and variability in the prominence of nucleoli. Prominent retraction artifact around each tumor cell may also be seen.^[3,5] Retraction artifacts were seen in the present case too.

The morphological resemblance of PUC to other malignancies is a source of diagnostic dilemmas and often misdiagnosis.

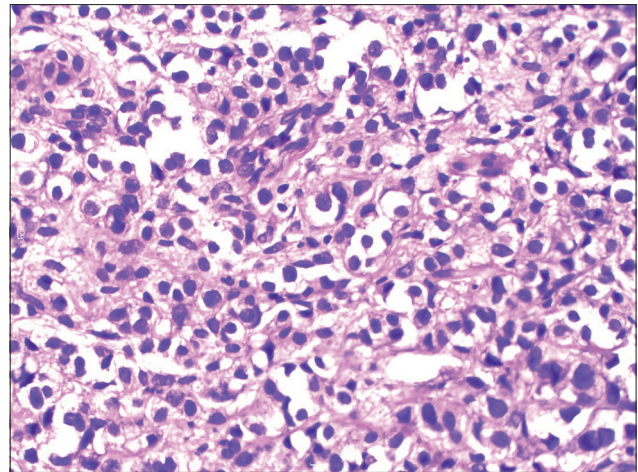


Figure 1: High grade tumor arranged in discohesive cords and sheets with plasmacytoid features and prominent retraction artifact reaching up to the serosa (H and E, x40)

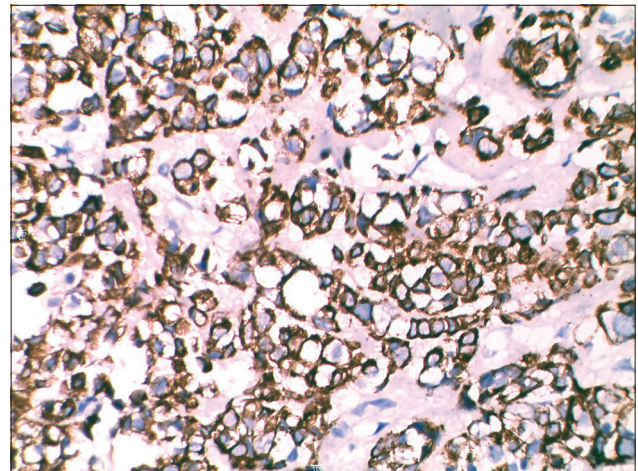


Figure 2: Tumor cells showing positivity for CD138 (immunohistochemistry, x40)

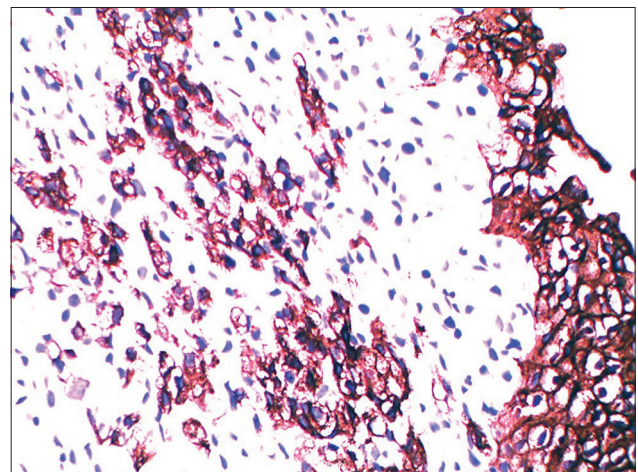


Figure 3: Tumor cells showing positivity for cytokeratin 7 (immunohistochemistry, x40)

Amongst the differential diagnosis for PUC ranging from benign to malignant lesions, common ones are cystitis with plasma cell

infiltration along with plasma cell-derived neoplasms including large B-cell lymphomas and plasmacytomas, lymphomas, lymphoepitheliomas and metastatic carcinoma also are a source of diagnostic difficulties.^[5] Striking plasmacytoid morphology is seen in the metastatic disease from breast and stomach as well as melanoma and rhabdomyosarcoma and may pose a diagnostic challenge.^[5] Other neoplasms that may have plasmacytoid cells include medullary carcinoma, myoepithelial carcinoma, and carcinoid.^[6] Mucin-containing cells that may mimic true signet ring cells may be focally present in PUC.^[3,4]

In view of the varied differential diagnosis, it becomes imperative to get immunohistochemical work-up done with relevant markers to narrow the possibilities. An appropriate panel of antibodies is employed, CK and CK7 are important to identify the epithelial origin of transitional cell type. CD138 a marker for plasma cells is positive in both plasmacytoma and PUC, κ and λ light chain markers are used to differentiate between the two lesions, PUC is positive for CD138 but negative for light chains as seen in the present case also.^[4,5,9] However some authors have shown CD138 to be expressed by other tissues other than plasma cells or plasma cell-derived neoplasms, including diffuse large B-cell lymphomas and Hodgkin lymphomas and even nonhematopoietic tissues such as stromal cells and various types of carcinomas.^[10-12] Hence, CD138 should not be used in isolation as evidence of a plasma cell neoplasm as it may lead to an erroneous diagnosis.^[10] Immunoreaction for MUC1 in PUC representing focal positivity for intracytoplasmic mucin has also been described by authors.^[3] Mucin secreting cells resembling signet-ring cells were not seen in our case, and so the MUC1 immunohistochemical marker was not considered in this panel.

A broad panel of antibodies, including CK, LCA and/or T-and B-cell markers along with HMB45, S-100 protein may be necessary if the initial differential diagnosis is wide.^[7] More so, in differentiating PUC from metastatic carcinoma, plasmacytoid carcinomas are positive for CK7, CK20 and for uroplakin3. Additional antibodies that may be useful in excluding tumors originating from other sites include gross cystic disease fluid protein-15 for breast carcinoma, thyroid transcription factor-1 for lung carcinoma, and prostate-specific antigen for prostatic adenocarcinoma.^[8]

Prognosis of PUC is poor, a biopsy usually reveals a high-grade tumor infiltrating the lamina propria and muscularis, with high potential of metastasis and because of the rarity of the disease, the treatment is not well defined. However, since the majority of patients have advanced disease at diagnosis radical cystectomy and adjuvant chemotherapy is advised.^[3]

CONCLUSION

Plasmacytoid variant of urothelial carcinoma represents an uncommon tumor, from diagnostic, therapeutic and prognostic point of view. Awareness of this rare variant when dealing with urogenital tract carcinoma is important in order to avoid misdiagnosis. The differential diagnosis is wide and often clinical characteristics do not differentiate them from other bladder tumors. Histopathological diagnosis may be difficult at times, thus leaving this rare entity undetected. Immunohistochemistry is an invaluable diagnostic tool and a broad panel of antibodies is needed to reach to a conclusive diagnosis. A diagnosis of PUC usually carries a dismal prognosis. Hence, recognition of this rare variant by the pathologist is necessary for appropriate treatment to be instituted.

REFERENCES

1. Lopez-Beltran A, Suater G, Gasser T, Hartmann A, Schmitz-Drager BJ, Helpap B, *et al.* Infiltrating urothelial carcinoma. In: Eble JN, Sauter G, Epstein JI, Sesterhenn IA, editors. Pathology and Genetics of Tumors of Urinary System and Male Genital Organs. Lyon: IARC Press; 2004. p. 93-109.
2. Lopez-Beltran A, Cheng L. Histologic variants of urothelial carcinoma: Differential diagnosis and clinical implications. *Hum Pathol* 2006;37:1371-88.
3. Nabbout P, Furr J, Paari M, Slobodov G. Plasmacytoid urothelial carcinoma of the bladder metastatic to the stomach: A case report. *Case Rep Urol* 2012;2012:715951.
4. Nigwekar P, Amin MB. The many faces of urothelial carcinoma: An update with an emphasis on recently described variants. *Adv Anat Pathol* 2008;15:218-33.
5. Rahman K, Menon S, Patil A, Bakshi G, Desai S. A rare case of plasmacytoid urothelial carcinoma of bladder: Diagnostic dilemmas and clinical implications. *Indian J Urol* 2011;27:144-6.
6. Zukerberg LR, Harris NL, Young RH. Carcinomas of the urinary bladder simulating malignant lymphoma. A report of five cases. *Am J Surg Pathol* 1991;15:569-76.
7. Wang Z, Lu T, Du L, Hu Z, Zhuang Q, Li Y, *et al.* Plasmacytoid urothelial carcinoma of the urinary bladder: A clinical pathological study and literature review. *Int J Clin Exp Pathol* 2012;5:601-8.
8. Nicolas MM, Sanchez-Salazar AJ, Guo CC. Plasmacytoid carcinoma of the urinary bladder. *Basic Appl Pathol* 2010;3:105-8.
9. Coyne JD, Sim E. Urothelial neoplasia with plasmacytoid morphology. *Histopathology* 2006;48:200-1.
10. Nigwekar P, Tamboli P, Amin MB, Osunkoya AO, Ben-Dor D, Amin MB. Plasmacytoid urothelial carcinoma: Detailed analysis of morphology with clinicopathologic correlation in 17 cases. *Am J Surg Pathol* 2009;33:417-24.
11. O'Connell FP, Pinkus JL, Pinkus GS. CD138 (syndecan-1), a plasma cell marker immunohistochemical profile in hematopoietic and nonhematopoietic neoplasms. *Am J Clin Pathol* 2004;121:254-63.
12. Lopez-Beltran A, Requena MJ, Montironi R, Blanca A, Cheng L. Plasmacytoid urothelial carcinoma of the bladder. *Hum Pathol* 2009;40:1023-8.

How to cite this article: Jairajpuri ZS, Rana S, Ali MA, Jetley S. Plasmacytoid variant of urothelial carcinoma: Diagnostic challenges and role of immunohistochemistry. *Int J App Basic Med Res* 2015;5:217-9.

Source of Support: Nil. **Conflict of Interest:** None declared.