

[CASE REPORT]

Cytomegalovirus Hemorrhagic Cystitis in a Malignant Glioma Patient Treated with Temozolomide

Ryutaro Furukawa¹, Hirokuni Homma², Tomohiro Inoue²,
Hajime Horiuchi³ and Kazuhiro Usui¹

Abstract:

Temozolomide, a key drug in the treatment of malignant glioma, can cause profound lymphopenia and various opportunistic infectious diseases. A 79-year-old woman with anaplastic oligodendroglioma developed a fever and gross hematuria after 8 weeks of standard radiotherapy with concomitant temozolomide treatment. A cytomegalovirus (CMV) antigen test for pp65 antigenemia was positive (137 cells per 75,800 leukocytes), and the findings from a urine cytology test were consistent with CMV-induced hemorrhagic cystitis. She was treated with ganciclovir, and her condition improved. CMV monitoring is needed when patients develop symptoms related to opportunistic infections during temozolomide treatment for malignant glioma.

Key words: malignant glioma, temozolomide, cytomegalovirus, hemorrhagic cystitis

(Intern Med 57: 3047-3050, 2018)

(DOI: 10.2169/internalmedicine.1005-18)

Introduction

Patients with high-grade malignant glioma are treated with surgical resection followed by radiation plus concomitant and adjuvant temozolomide. Temozolomide is an oral alkylating agent that produces myelotoxic effects (1). When administered in combination with corticosteroids, which are routinely used to control the mass effect of tumors and peritumoral edema, temozolomide often induces profound lymphopenia. Deficiency in cell-mediated immunity leads to a variety of opportunistic infectious diseases.

We herein report a case of opportunistic cytomegalovirus infection, the manifestation of which was hemorrhagic cystitis, in a patient with anaplastic oligodendroglioma.

Case Report

A 79-year-old woman presented with worsening headache, an altered mental state, and left hemiparesis. Magnetic resonance imaging (MRI) showed an ill-defined mass in the right frontal lobe of the brain (Fig. 1). She underwent surgical resection, and the tumor was pathologically diagnosed as

anaplastic oligodendroglioma [The 2016 World Health Organization Classification (2)]. Standard 6-week radiotherapy (60 Gy/30 Fr) and concomitant temozolomide (75 mg/m²/day) were started after surgery. She received dexamethasone 2 mg/day to control the peritumoral edema and trimethoprim-sulfamethoxazole (80-400 mg once a day) for prophylaxis against pneumocystis pneumonia.

At 8 weeks after the initiation of radiotherapy and concomitant temozolomide treatment, the patient developed a high fever, abdominal pain, gross hematuria and diarrhea. The blood count showed lymphopenia; the absolute lymphocyte count was 330/mm³, and the CD4⁺ T-cell count was 77/mm³. The cytomegalovirus (CMV) IgM index was negative, the IgG index was positive (8.2), and a CMV antigen test for pp65 antigenemia was positive (137 cells per 75,800 leukocytes). Urine cytology showed a large number of neutrophils with a small number of degenerated atypical cells (Fig. 2). Cystoscopy was not performed due to the risk of perforation. Urine culture was negative for bacteria. Although she had diarrhea, colonoscopy did not show CMV colitis, and a fecal culture was negative for bacteria causing enterocolitis. No retinitis was noted on an ophthalmological examination. Computed tomography showed no evidence of

¹Division of Respiriology, NTT Medical Center Tokyo, Japan, ²Department of Neurosurgery, NTT Medical Center Tokyo, Japan and ³Department of Diagnostic Pathology, NTT Medical Center Tokyo, Japan

Received: February 13, 2018; Accepted: March 7, 2018; Advance Publication by J-STAGE: May 18, 2018

Correspondence to Dr. Ryutaro Furukawa, rfurukawa-ky@umin.ac.jp

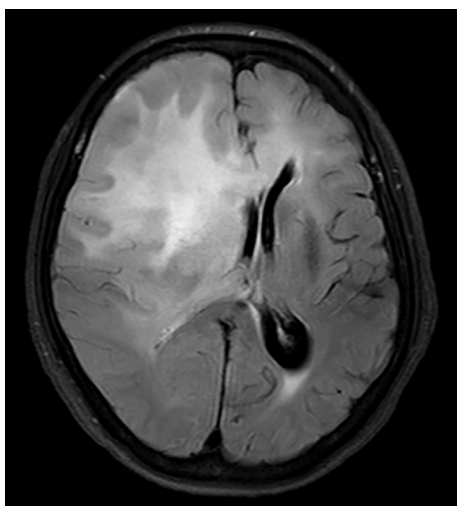


Figure 1. Magnetic resonance imaging (FLAIR) showed an ill-defined mass in the right frontal lobe of the brain that was pathologically diagnosed as anaplastic oligodendroglioma.

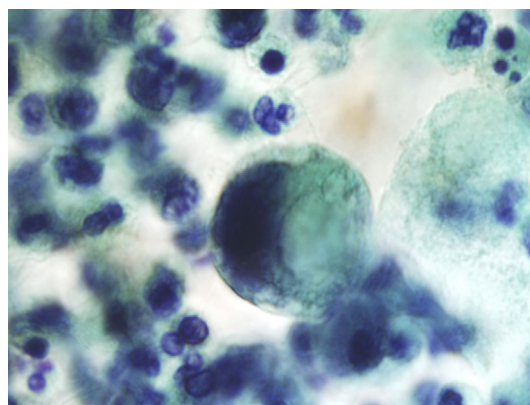


Figure 2. Urine cytology (light green staining) showed a large number of neutrophils with a small number of degenerated atypical cells.

other complications, such as viral pneumonia. We examined her cerebrospinal fluid, which showed no signs of meningitis. CMV-DNA was not detected in her cerebrospinal fluid by polymerase chain reaction.

We diagnosed her condition as CMV viremia with hemorrhagic cystitis. Intravenous ganciclovir (5 mg/kg twice a day) was administered for 14 days, and gross hematuria and diarrhea improved during the treatment. A CMV antigenemia assay was negative once ganciclovir treatment had finished. The CMV IgM index turned positive (7.05), and the IgG index increased (10.6) at 4 weeks after the first test. At 8 weeks after the completion of concomitant temozolomide treatment, the absolute lymphocyte count increased to 910/mm³; however, the CD4⁺ T-cell count remained as low as 74/mm³. Her general condition worsened. She did not receive further treatment for her brain tumors and was transferred to a nursing care hospital.

Discussion

We reported a case of CMV infection with hemorrhagic cystitis that developed during temozolomide therapy for anaplastic oligodendroglioma.

Malignant glioma is one of the most common primary brain tumors and is treated with a combination of surgery, radiation, temozolomide, and systemic corticosteroids (1).

Temozolomide is an orally administered alkylating drug that is well-tolerated by glioma patients; however, its myelotoxic effect can be severe and long-lasting. A prospective study showed that grade III-IV lymphopenia (absolute lymphocyte count <500 cells/mm³) and CD4 lymphopenia (CD4 lymphocyte count <200 cells/mm³) occurred in 40% of patients with high-grade astrocytoma (3), and another study reported that lymphopenia remained throughout a 48-week observation period (4).

In addition, we must consider that patients with brain tu-

mors routinely receive corticosteroids to control the mass effect of tumors and peritumoral edema. The systemic administration of corticosteroids causes lymphopenia. The number of T cells tends to be more strongly affected than the number of B cells (5).

It is difficult to differentiate the effects of temozolomide from those of corticosteroids on the immunological condition in patients with brain tumors. One study on melanoma patients treated with temozolomide showed that 60% of patients developed lymphopenia (6). Since these patients did not receive routine corticosteroids, the findings indicated that temozolomide itself had potential myelotoxic effects. Temozolomide causes severe lymphopenia, and corticosteroids probably augment the effect.

Various opportunistic infections have been reported as complications of temozolomide therapy, including pneumocystis pneumonia (7), reactivation of hepatitis B virus infection (8), aspergillosis (9), cryptococcal meningitis (10), disseminated strongyloidiasis (11), and CMV infection (12-17). Routine prophylaxis against pneumocystis pneumonia is advised for patients being treated with temozolomide (7); however, no recommendation has been made for prophylaxis against other infectious diseases.

CMV infections frequently occur among patients with human immunodeficiency virus (HIV) infections and organ transplant recipients. In most cases, CMV infections occur in patients with a CD4 cell count <50 cells/mm³ (18). The most common manifestations of CMV infections are retinitis, gastrointestinal diseases (e.g. gastritis, colitis, esophageal ulcers), and pneumonitis.

Our patient developed gross hematuria, and we diagnosed her condition as CMV-induced hemorrhagic cystitis. She did not have risk factors of hemorrhagic cystitis, such as coagulation disorders, antithrombotic use, hepatic disorders, diabetes mellitus, and abnormalities in the urinary tract. Some chemotherapeutic drugs can cause hemorrhagic cystitis. Cyclophosphamide, for example, causes hemorrhagic cystitis by the urinary excretion of acrolein, a hepatic metabolite of cyclophosphamide (19). Temozolomide and its analog dacar-

bazine have also been reported to cause hemorrhagic cystitis in a few case reports (20, 21). In drug-induced hemorrhagic cystitis, urothelial cells often demonstrated an increase in the size of the nucleus and also become bizarrely shaped (22). It is not possible to morphologically differentiate drug-induced hemorrhagic cystitis from viral-induced condition by urine cytology, so an examination of the suspected virus is needed to rule out the possibility of viral infection.

A few case reports have shown the clinical course of CMV cystitis in patients with conditions associated with the severe malfunction of cell-mediated immunity [i.e. HIV infection (23), kidney transplantation (24), and peripheral blood stem cell transplantation (25)]. CMV infection has been reported to be a risk factor for late-onset hemorrhagic cystitis during the course of allogeneic hematopoietic stem cell transplantation (26). Our case suggested that temozolomide treatment combined with corticosteroids can induce severe immunodeficiency, similar to that observed in patients with HIV infection or organ transplantation recipients.

Seven cases of CMV infection have been reported in patients using temozolomide (12-17). The mean age was 59 years (range: 45-70 years). Three cases were men, and four were women. At the development of CMV infection, their absolute lymphocyte count ranged from 60 to 703, and their CD4⁺ T-cell count ranged from 36 to 260. The reported manifestations of CMV infections are various and include pneumonitis (12, 16), colitis (12, 13), colonic pseudotumor (15), transverse myelitis (13), and hepatitis (17).

Neither routine screening nor preemptive therapy for CMV infections is recommended among patients using temozolomide, partly because of the small number of reported cases. However, physicians must recognize that malignant glioma treatment can induce severe CD4⁺ T-cell lymphopenia, and that patients have an increased risk of CMV infection both during and after treatment with temozolomide.

In summary, we reported a case of CMV infection that manifested as hemorrhagic cystitis in a patient with malignant glioma. Combination therapy with temozolomide and corticosteroids can cause severe immunodeficiency and result in various opportunistic infections. When administering standard malignant glioma treatment, physicians should pay close attention to signs and symptoms that might be associated with CMV-induced hemorrhagic cystitis, such as gross hematuria.

The authors state that they have no Conflict of Interest (COI).

References

- Stupp R, Mason WP, Van Den Bent MJ, et al. Radiotherapy plus concomitant and adjuvant temozolomide for glioblastoma. *N Engl J Med* **352**: 987-996, 2005.
- Louis DN, Perry A, Reifenberger G, et al. The 2016 World Health Organization classification of tumors of the central nervous system: a summary. *Acta Neuropathol* **131**: 803-820, 2016.
- Grossman SA, Ye X, Lesser G, et al. Immunosuppression in patients with high-grade gliomas treated with radiation and temozolomide. *Clin Cancer Res* **17**: 5473-5480, 2011.
- Campian JL, Piotrowski AF, Ye X, et al. Serial changes in lymphocyte subsets in patients with newly diagnosed high grade astrocytomas treated with standard radiation and temozolomide. *J Neurooncol* **135**: 1-9, 2017.
- Olmes MJ, Kotliarov Y, Biancotto A, et al. Effects of systemically administered hydrocortisone on the human immune. *Sci Rep* **6**: 23002, 2016.
- Su YB, Sohn S, Krown SE, et al. Selective CD4⁺ lymphopenia in melanoma patients treated with temozolomide: a toxicity with therapeutic implications. *J Clin Oncol* **22**: 610-616, 2004.
- Yu SK, Chalmers AJ. Patients receiving standard-dose temozolomide therapy are at risk of *Pneumocystis carinii* pneumonia. *Clin Oncol* **19**: 631-632, 2007.
- Fujimoto Y, Hashimoto N, Kinoshita M, et al. Hepatitis B virus reactivation associated with temozolomide for malignant glioma: a case report and recommendation for prophylaxis. *Int J Clin Oncol* **17**: 290-293, 2012.
- Ikeda T, Suzuki J, Norizuki M, et al. Cutaneous invasive aspergillosis in a patient with glioblastoma receiving long-term temozolomide and corticosteroid therapy. *J Infect Chemother* **23**: 253-255, 2017.
- Choi JD, Powers CJ, Vredenburgh JJ, Friedman AH, Sampson JH. Cryptococcal meningitis in patients with glioma: a report of two cases. *J Neurooncol* **89**: 51-53, 2008.
- Aregawi D, Lopez D, Wick M, Scheld WM, Schiff D. Disseminated strongyloidiasis complicating glioblastoma therapy: a case report. *J Neurooncol* **94**: 439-443, 2009.
- Meije Y, Lizasoain M, García-Reyne A, et al. Emergence of cytomegalovirus disease in patients receiving temozolomide: report of two cases and literature review. *Clin Infect Dis* **50**: e73-e76, 2010.
- Schwarzberg AB, Stover EH, Sengupta T, et al. Selective lymphopenia and opportunistic infections in neuroendocrine tumor patients receiving temozolomide. *Cancer Invest* **25**: 249-255, 2007.
- Yaman E, Coskun U, Ozturk B, et al. Opportunistic cytomegalovirus infection in a patient receiving temozolomide for treatment of malignant glioma. *J Clin Neurosci* **16**: 591-592, 2009.
- Jesus A De, Grossman SA, Paun O. Cytomegalovirus associated colonic pseudotumor: a consequence of iatrogenic immunosuppression in a patient with primary brain tumor receiving radiation and temozolomide. *NIH Public Access* **94**: 445-448, 2013.
- Douzinis EE, Flevari K, Andrianakis I, Betrosian AP. Oral atovaquone for the treatment of severe *Pneumocystis jirovecii* pneumonia in a patient with glucose-6-phosphate dehydrogenase deficiency. *Scand J Infect Dis* **42**: 76-78, 2010.
- Okita Y, Narita Y, Miyakita Y, Ohno M, Nagai S, Shibui S. Management of cytomegalovirus infection in a patient with malignant glioma treated with temozolomide and steroids. *Intern Med* **51**: 2967-2971, 2012.
- Whitley RJ, Jacobson MA, Friedberg DN, et al. Guidelines for the treatment of cytomegalovirus diseases in patients with AIDS in the era of potent antiretroviral therapy: recommendations of an international panel. *International AIDS Society-USA. Arch Intern Med* **158**: 957-969, 1998.
- Lee G, Romih R, Zupančič D. Cystitis: From urothelial cell biology to clinical applications. *Biomed Res Int* **2014**: 473536, 2014.
- Mohammadianpanah M, Shirazi M, Mosalaei A, Omidvari S, Ahmadloo N. Hemorrhagic cystitis in a patient receiving conventional doses of dacarbazine for metastatic malignant melanoma: case report and review of the literature. *Clin Ther* **29**: 1161-1165, 2007.
- Islam R, Isaacson BJ, Zickerman PM, Ratanawong C, Tipping SJ.

- Hemorrhagic cystitis as an unexpected adverse reaction to temozolomide: case report. *Am J Clin Oncol* **25**: 513-514, 2002.
22. Stella F, Battistelli S, Marcheggiani F, et al. Urothelial cell changes due to busulfan and cyclophosphamide treatment in bone marrow transplantation. *Acta Cytol* **34**: 885-890, 1990.
23. Studemeister A. Cytomegalovirus-induced hemorrhagic cystitis in AIDS patient treated successfully with valganciclovir. *AIDS* **16**: 1437-1438, 2002.
24. Ersan S, Yorukoglu K, Sert M, et al. Unusual case of severe late-onset cytomegalovirus-induced hemorrhagic cystitis and ureteritis in a renal transplant patient. *Ren Fail* **34**: 247-250, 2012.
25. Sahu KK, Prakash G, Khadwal A, Varma SC, Malhotra P. A rare case of hemorrhagic cystitis in allogeneic hematopoietic stem cell transplant patient. *Indian J Hematol Blood Transfus* **32**: 196-200, 2016.
26. Han TT, Xu LP, Liu DH, et al. Cytomegalovirus is a potential risk factor for late-onset hemorrhagic cystitis following allogeneic hematopoietic stem cell transplantation. *Am J Hematol* **89**: 55-61, 2014.

The Internal Medicine is an Open Access journal distributed under the Creative Commons Attribution-NonCommercial-NoDerivatives 4.0 International License. To view the details of this license, please visit (<https://creativecommons.org/licenses/by-nc-nd/4.0/>).

© 2018 The Japanese Society of Internal Medicine
Intern Med 57: 3047-3050, 2018