



## Case report

## Nocardia beijingensis brain abscesses in an HIV-infected individual



Jolie Guevara Keenan\*, Sunita Mohapatra

Mount Sinai Hospital, 1500 South Fairfield Avenue, Chicago, Illinois 60608, United States

## ARTICLE INFO

## Article history:

Received 5 February 2017

Received in revised form 12 March 2017

Accepted 13 March 2017

## Keywords:

Nocardia

Beijingensis

HIV/AIDS

Brain abscess

Trimethoprim/sulfamethoxazole

Seizures

Alcohol withdrawals

Toxoplasmosis

Meropenem

## ABSTRACT

We describe a case of a 50-year-old Hispanic man diagnosed with HIV/AIDS who presented with a generalized tonic clonic seizure and ring enhancing cerebral lesions on imaging. He was initially treated for CNS toxoplasmosis but presented to the hospital with another tonic clonic seizure despite prescribed therapy. Brain biopsy was performed which revealed *Nocardia beijingensis*. He was treated with intravenous meropenem and trimethoprim/sulfamethoxazole for six weeks followed by long term oral trimethoprim/sulfamethoxazole with radiographic and clinical improvement.

© 2017 The Authors. Published by Elsevier Ltd. This is an open access article under the CC BY-NC-ND license (<http://creativecommons.org/licenses/by-nc-nd/4.0/>).

## Case report

A 50-year-old Hispanic man diagnosed with HIV/AIDS in 2008 presented to the Emergency Department for a generalized tonic clonic seizure. He was non-compliant with HAART therapy and had a history of alcohol abuse with multiple admissions for alcohol intoxication and withdrawal seizures. He admitted to drinking heavily three days prior to admission. He had not taken his HAART medications for quite some time, though was prescribed a regimen of emtricitabine/tenofovir, darunavir, ritonavir, raltegravir, and azithromycin from a local HIV care provider. On physical examination his blood pressure was 112/70 mmHg, heart rate of 88 beats/min, respiratory rate of 18 breaths/min, and temperature of 37.2 degrees Celsius. He had clear breath sounds with good air entry bilaterally, no crackles, no wheezes, and no dullness to percussion. His abdomen was soft and not distended. No skin lesions were visible. He was alert and oriented with fluent speech, pupils were equally reactive to light, and muscular strength was 5/5 in all extremities. His hemoglobin was 13.2 mg/dl, white count was 8.1 cells/mm<sup>3</sup>, and his platelets were 132 cells/mm [3]. A comprehensive metabolic profile was unremarkable. His chest radiograph was normal. A contrasted CT of the brain showed

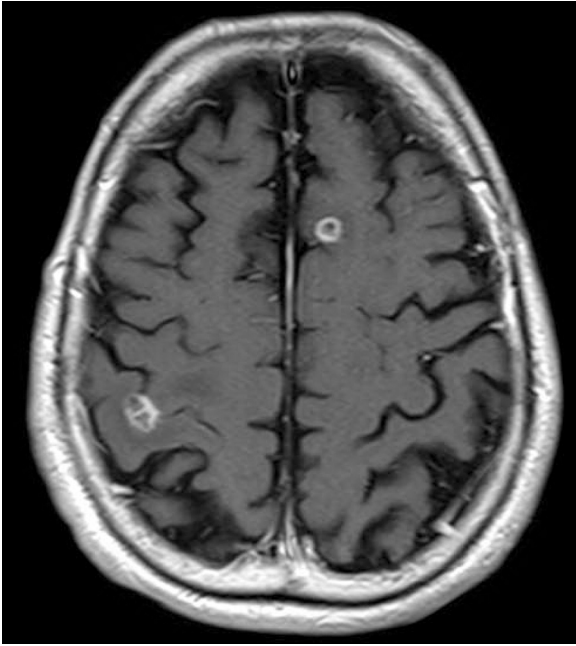
multiple ring enhancing lesions which were better visualized on the contrast MRI of the brain (Figs. 1 and 2).

At the time of initial presentation, the patient's CD4 count was 30 cells/mm<sup>3</sup>, with an HIV viral load of 57,184 copies. A toxoplasma IgG serology and titers for neurocystercosis were negative. According to the patient, he was allergic to trimethoprim/sulfamethoxazole manifesting as pruritic rash. He was treated for presumed CNS infection due to toxoplasmosis despite negative serology since he was severely immunocompromised. Toxoplasma-specific IgG antibody levels in AIDS patients are often low, but occasionally no specific IgG antibodies can be detected [1]. He was prescribed with pyrimethamine 75 mg daily, clindamycin 600 mg Q6 IV, and leucovorin 25 mg daily for six weeks. The patient was discharged four days after admission and recommended to follow up with his HIV care provider.

Approximately six weeks after the first admission, the patient again presented to the emergency room with an episode of generalized tonic clonic seizure. He admitted to not following up at the HIV center and stated that he only took his medications for CNS toxoplasmosis for two days. Physical examination showed that his blood pressure was 126/80 mmHg, heart rate of 98 beats/min, respiratory rate of 15 breaths/min, and a temperature of 37.4 °C. His breath sounds were clear with good air entry, no wheezing, no crackles, and no dullness to percussion. The patient was confused and was only able to follow simple commands. His pupils were equally reactive to light but he had left visual neglect. He also exhibited spastic movements with passive range of motion of both

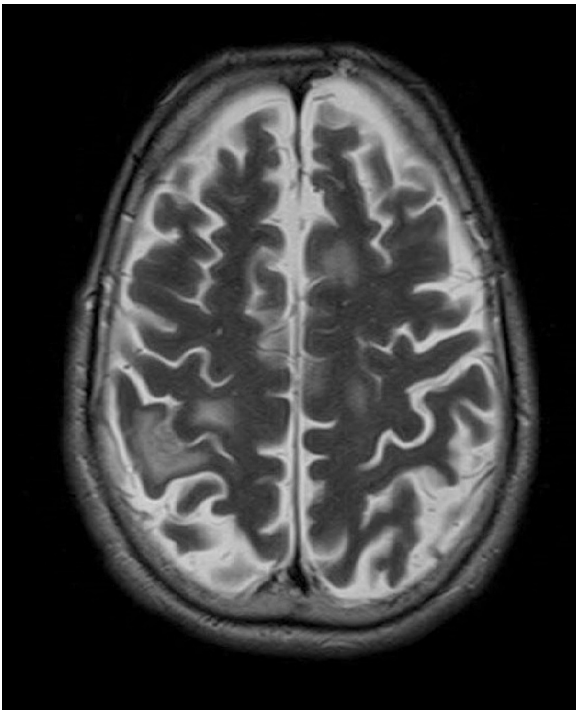
\* Corresponding author.

E-mail address: [jolie\\_guevara@yahoo.com](mailto:jolie_guevara@yahoo.com) (J.G. Keenan).

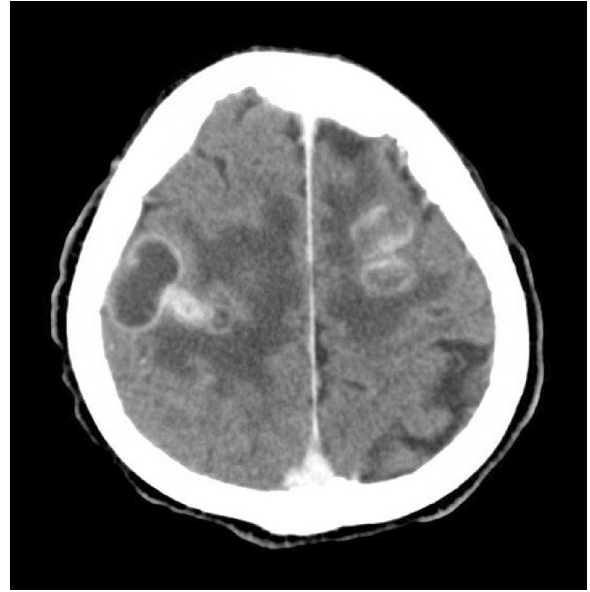


**Fig. 1.** MRI T1 axial of the brain on initial presentation.

upper and lower extremities. He had difficulty performing the finger to nose test. His hemoglobin was 11.5 mg/dl, his white count was 7.5 cells/mm<sup>3</sup>, and his platelets were 172 cells/mm<sup>3</sup>. A repeat contrasted CT of the brain (Figs. 3 and 4) showed significant interval increase in size and number of ring enhancing lesions associated with surrounding edema. His original CNS toxoplasmosis medications were re-started as well as dexamethasone for brain edema. Neurosurgery was consulted but a plan for a brain biopsy was deferred with the recommendation of an adequate trial of CNS toxoplasma therapy first.



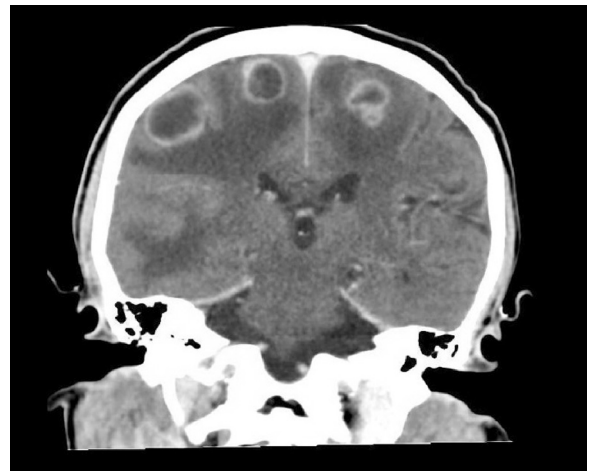
**Fig. 2.** MRI T2 axial of the brain on initial presentation.



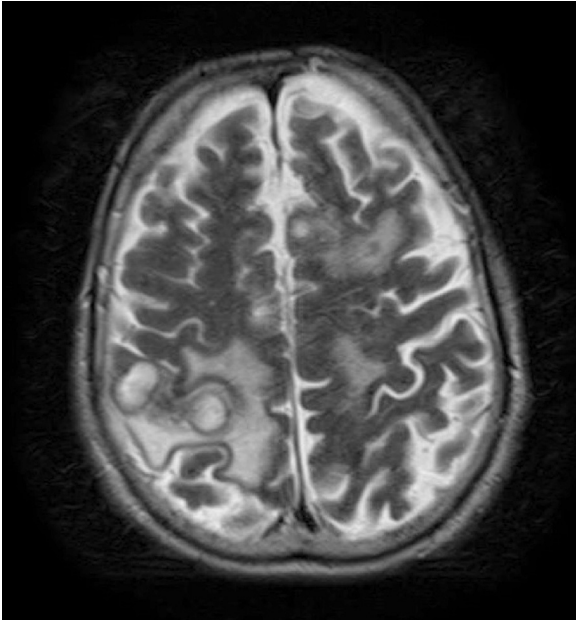
**Fig. 3.** Axial CT scan of the brain with contrast six weeks after initial presentation. There is an interval increase in the number and size of the lesions with surrounding vasogenic edema.

The patient remained hospitalized due to social issues and after three weeks of inpatient CNS toxoplasmosis treatment with pyrimethamine 75 mg daily, clindamycin 600 mg Q6 IV, and leucovorin 25 mg daily, the patient exhibited another tonic clonic seizure. He underwent an MRI of the brain with contrast (Figs. 5 and 6) which showed an increase in size and edema of previous lesions despite being on toxoplasmosis treatment for three weeks.

Due to ongoing seizures, a brain biopsy was reconsidered and undertaken. Gram staining of the biopsy showed many gram positive filamentous rods (Figs. 7 and 8). The patient was started on imipenem 500 mg Q6 IV and amikacin 500 mg Q12 IV for double coverage while waiting for identification and sensitivities. Amikacin was initially used given the historical allergy to trimethoprim/sulfamethoxazole. Further investigations showed that the patient had received trimethoprim/sulfamethoxazole at an outside hospital with no recorded allergy. Thus, he underwent a trimethoprim/sulfamethoxazole challenge which resulted in negative signs and symptoms of inflammation. His antibiotic



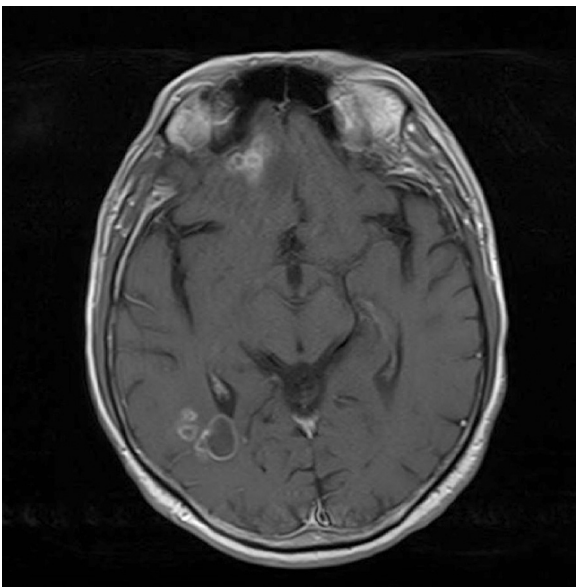
**Fig. 4.** Coronal CT scan of the brain with contrast six weeks after initial presentation. There is an interval increase in the number and size of the lesions with surrounding vasogenic edema.



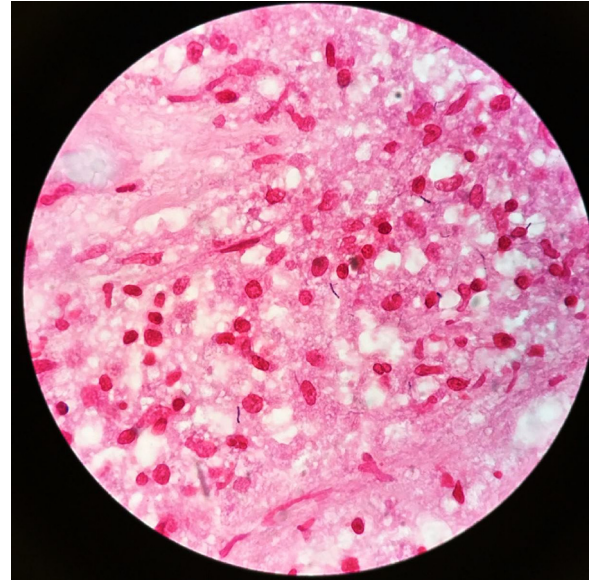
**Fig. 5.** T2 MRI of the brain after three weeks of inpatient toxoplasmosis treatment; nine weeks after initial presentation.

regimen was then changed to trimethoprim/sulfamethoxazole 400 mg Q8 IV and imipenem 500 mg Q6 IV. Culture eventually grew *Nocardia beijingensis* sensitive to trimethoprim/sulfamethoxazole and resistant to imipenem. The patient was discharged to a long term care hospital for intravenous trimethoprim/sulfamethoxazole 400 mg Q8 IV and meropenem 2 g Q8 IV for six weeks. He was continued on oral trimethoprim 160 mg/sulfamethoxazole 800 mg twice daily for at least one year. Prior to discharge, HAART was reinitiated.

The patient had been followed as outpatient with improvement of symptoms. His most recent viral load is 29 copies with a CD4 count of 55 cells/mm<sup>3</sup>. Repeat imaging studies show near resolution of his CNS lesions (Fig. 9).



**Fig. 6.** T1 MRI of the brain after three weeks of inpatient toxoplasmosis treatment; nine weeks after initial presentation.

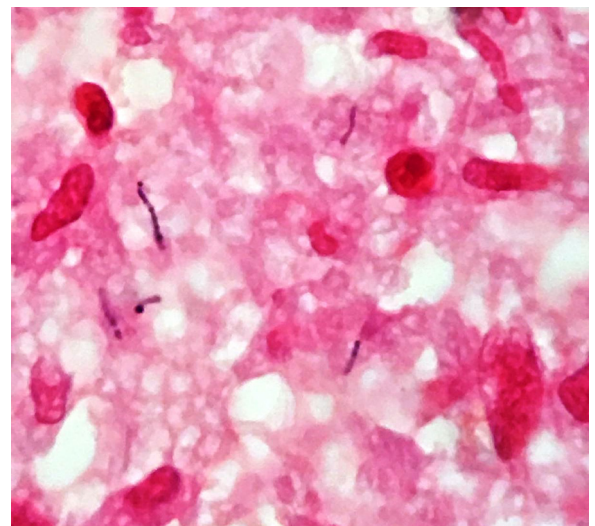


**Fig. 7.** Nocardia noting the gram positive filamentous rods.

## Discussion

*Nocardia* are aerobic, gram positive, catalase positive, slightly acid-alcohol-fast, non motile, non spore forming filamentous actinomycetes that are phylogenetically diverse [2,3]. It was first described by a French veterinarian [4] in 1888 as an uncommon gram positive bacteria causing severe infection. It is an opportunistic pathogen most commonly affecting immunocompromised patients, although there are reports of nocardiosis in immunocompetent patients as well [5,6,7]. Patients at highest risk are those with HIV infection, malignancy, on chronic glucocorticoid treatment, and solid transplant patients [2,6].

In HIV-positive individuals, *Nocardia* is a well known opportunistic pathogen usually presenting as primary cutaneous, primary pulmonary nocardiosis [6], or as a disseminated disease [8]. *Nocardia* has the ability to disseminate to any organ including the lung, lymph nodes, and brain. Neurologic involvement presents as a gradual increase in headaches, nausea, vomiting, seizures, or altered mentation. In a study by Tan et al. [3], of the 113 patients with *Nocardia* infection, seven presented with a brain abscess



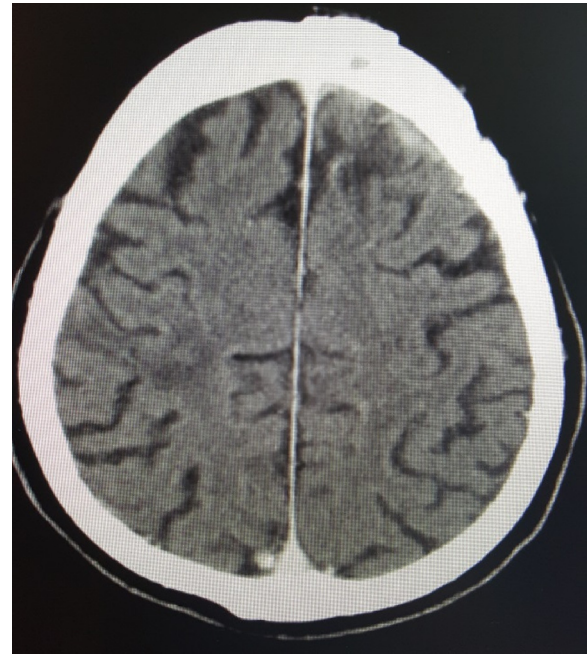
**Fig. 8.** Nocardia noting the beading characteristic of the filamentous rods.

together with pulmonary involvement. In patients presenting with brain lesions it is important to consider a neoplastic disease, tuberculous infection, and nocardiosis [9].

*Nocardia beijingensis* was discovered in a mud sample from a sewage ditch at Xishan mountain in Beijing, China in 2001 [10]. The first few cases outside of East Asia were reported in 2011 in France [8,11], in 2014 in the United States [6], and in 2015 in Israel [5]. Two of the case reports presented with lung involvement in immunocompetent patients [5,6], and two in HIV positive patients with a high viral load and a CD4 count of 39 cells/mm [8,11]. Although we did not perform a CT of the chest to rule out any pulmonary involvement, our patient's chest radiograph was clear and he did not exhibit any signs and symptoms of respiratory involvement. To our knowledge, this is the first case of *Nocardia beijingensis* presenting as brain abscesses with no pulmonary involvement in a patient with HIV/AIDS.

It is imperative to identify *Nocardia* beyond the genus level because each species has its own clinical spectrum of disease, sensitivity, and resistance patterns to different antibiotics [2]. Gene sequencing has been vital for differentiating *Nocardia* species which have varying antimicrobial susceptibilities [12]. No randomized controlled trials are currently available to guide treatment of *Nocardia* due to its rarity. Clinicians mostly rely on expert opinions which have used sulfonamides as the first line treatment for *Nocardia* [5]. It has been the antimicrobial of choice to treat nocardiosis despite bacteriostatic activity [13]. Alternative antimicrobial agents include imipenem, meropenem, ceftriaxone, cefotaxime, minocycline, moxifloxacin, levofloxacin, linezolid, tigecycline, and amoxicillin-clavulanic acid [13]. *Nocardia beijingensis* has been reported to be highly sensitive to imipenem, tobramycin, and kanamycin [12]. However, our patient's particular strain was resistant to imipenem. Due to his anecdotal allergy to trimethoprim/sulfamethoxazole, we initially treated with imipenem and amikacin combination therapy [13]. His regimen was switched to IV trimethoprim/sulfamethoxazole and IV meropenem for six weeks once the susceptibility studies came back and the patient did not have any allergic reactions to the trimethoprim/sulfamethoxazole challenge. He continued the oral form of trimethoprim/sulfamethoxazole two tablets daily thereafter for at least 12 months. If our patient had true allergic reactions to trimethoprim/sulfamethoxazole, any two of the above mentioned alternative antimicrobial agents may be used. Dual coverage should be continued until clinical improvement and *Nocardia* species identification with antimicrobial susceptibilities have been reported [13]. Although the duration of treatment is not standardized, at least six months of treatment is necessary for pulmonary and disseminated nocardiosis due to *Nocardia*'s relapsing nature [6]. Patients who are immunosuppressed and those with CNS disease should receive at least 12 months of antimicrobial therapy [13]. If the patient does not improve with medical therapy, stereotactic aspiration should be performed to confirm the diagnosis and decompress the lesions. If the lesions continue to enlarge within two weeks or they fail to decrease in size after at least four weeks of therapy, a craniotomy can be performed to excise the abscess. However if the abscesses are not surgically accessible, repeat aspiration and drainage can be performed, although the outcomes are less than ideal [14,15].

In summary, it is important to think of *Nocardia* as an opportunistic pathogen with significant morbidity and mortality in immunocompromised patients presenting with brain lesions. *Nocardia* needs to be identified down to the species level given its varied antimicrobial susceptibilities. Dual coverage with trimethoprim/sulfamethoxazole and another agent is recommended until clinical improvement and antimicrobial susceptibility is confirmed. In the event of an allergic reaction to the first line agent, alternative antimicrobials may be used. Long term



**Fig. 9.** Axial CT scan of the brain with contrast post treatment for *Nocardia beijingensis*; 26 weeks after initial presentation. There is notable resolution of the lesions.

treatment is advised for cerebral and disseminated nocardiosis. If the lesions do not decrease within four weeks of treatment or continue to enlarge despite maximum antimicrobial coverage, surgical aspiration and drainage may be considered. Early recognition of this potentially fatal infection is imperative.

#### Conflict of interest

Written informed consent was obtained from the patient for publication of this case report and accompanying images. A copy of the written consent is available for review by the Editor-in-Chief of this journal on request.

#### References

- [1] Center for Disease Control and Prevention Laboratory identification of parasitic disease of public health concern: Toxoplasmosis. 2015. [Accessed 02.02.2017] <http://www.cdc.gov/dpdx/toxoplasmosis/dx.html/>.
- [2] Montoya J. Laboratory diagnosis of toxoplasma *gondii* infection and toxoplasmosis. *J Infect Dis* 2002;185: S1.
- [3] Tan C. Clinical and microbiological characteristics of nocardiosis including those caused by emerging nocardia species in Taiwan, 1998–2008. *Clin Microbiol Infect* 2010;16(7):966–72.
- [4] Nocard M. Note sur la maladie des boeufs de la Guadeloupe: connue sous le nom de farcin. *Annales de l'Institut Pasteur* 1888;2:293–302.
- [5] Abdel-Rahman N, Izhakain S, Wasser W, Fruchter O, Kramer M. Endobronchial enigma: a clinically rare presentation of *Nocardia beijingensis* in an immunocompetent patient. *Case Rep Pulmonol* 2015;1–6.
- [6] Crozier J, Andhavarapu S, Brumble L, Sher T. First report of *Nocardia beijingensis* infection in an immunocompetent host in the United States. *J Clin Microbiol* 2014;7:2730–2.
- [7] Gonzales AV. Second report of a *Nocardia beijingensis* infection in the United States: nodular scleritis with in vitro imipenem resistance. *Digital J Ophthalmol* 2016;22.
- [8] Martinaud C, Verdonk C, Bousquet A, MacNab C, Vaylet F, Soler C, et al. Isolation Of *Nocardia beijingensis* from a pulmonary abscess reveals human immunodeficiency virus infectio. *J Clin Microbiol* 2011;7:2748–50.
- [9] Naqui R, Ahsan H, Azeemuddin M. Cerebral nocardiosis. *J Pak Med Assoc J PMA* 2011;61:697–9.
- [10] Wang L, Zhang Y, Lu Z, Shi Y, Liu Z, Maldonado L, et al. *Nocardia beijingensis* species, a novel isolate from soil. *Int J Syst Evol Microbiol* 2001;5:1783–8.

- [11] Flateau C, Jurado V, Lemaître N, Loiez C, Wallet F, Saiz-Jimenez C, et al. First case of cerebral abscess due to a novel *Nocardia* species in an immunocompromised patient. *J Clin Microbiol* 2012;2:696–700.
- [12] Kageyama A, Poonwan N, Yazawa K, Mikami Y, Nishimur K. *Nocardia beijingensis* is a pathogenic bacterium to humans: the first infectious cases in Thailand and Japan. *Mycopathologia* 2004;157:155–61.
- [13] Nocardiosis Wilson J. Updates and clinical review. *Mayo Clin Proc* 2012;87:403–7.
- [14] Mamelak A, Obana W, Flaherty J, Rosenblum M. Nocardial brain abscess: treatment strategies and factors influencing outcome. *Neurosurgery* 1994;35:622–31.
- [15] Phoompoung P, Koomanachai P. *Nocardia beijingensis* brain abscess in an HIV infected patient: a first case report and literature review. *Southeast Asian J Trop Med Public Health* 2016;47:1020–5.