



OPEN ACCESS

## CASE REPORT

Treatment of severe hypocalcaemia due to osteoblastic metastases in a patient with post-thyroidectomy hypoparathyroidism with  $^{153}\text{Sm}$ -EDTMP

Eva Kassi, Ifigeneia Kapsali, Michalis Kokkinos, Helen Gogas

National and Kapodistrian  
University of Athens - Faculty of  
Medicine, Athens, Greece

**Correspondence to**  
Professor Helen Gogas,  
hgogas@hol.gr

Accepted 4 May 2017

**SUMMARY**

Symptomatic hypocalcaemia is an uncommon finding in patients with malignant tumours. We describe a patient with advanced metastatic breast cancer who developed severe hypocalcaemia caused by the combination of osteoblastic metastases and a permanent postoperative hypoparathyroidism. The patient failed to be treated with the conventional replacement therapy and was submitted effectively to radionuclide therapy with  $^{153}\text{Sm}$ .

**BACKGROUND**

Breast cancer is the most common malignancy in women.<sup>1</sup> Approximately 70% of patients with breast cancer have bone metastases, with up to one third having lung and liver metastases.<sup>1</sup> Hypercalcaemia due to metastasis in bone is also very common in advanced breast cancer.<sup>1</sup> On the other hand, symptomatic hypocalcaemia is uncommon appearing in almost 1.5% of patients with malignant tumours.<sup>2</sup> The treatment of severe hypocalcaemia is a difficult clinical problem in such cases.

Herein, we describe a 73-year-old patient with metastatic breast cancer, who developed extreme hypocalcaemia caused by the combination of rapid expansion of osteoblastic metastases and insufficient parathyroid response due to a permanent postoperative hypoparathyroidism. Although large doses of elementary intravenous calcium and per os (po) along with alfacalcidol and cholecalciferol were administered, the corrected calcium level remained low. The patient was scheduled for administration of radioactive samarium [ $^{153}\text{Sm}$ EDTMP] and few weeks later the serum calcium level was restored to normal.<sup>3</sup> In case of persistent hypocalcaemia, the administration of radionuclide therapy with  $^{153}\text{Sm}$ EDTMP could be an effective option.

**CASE PRESENTATION**

A 73-year-old woman was admitted to our hospital with symptomatic hypocalcaemia on June 2016. Her symptoms was muscle cramps, numbness, tingling sensation in the perioral area and impaired intellectual capacity. Physical examination revealed positive Chvostek and Trousseau signs. On the cardiac examination, bradycardia was present along with a QT prolongation on the ECG.

In 2005, she was diagnosed with breast cancer and she was submitted to total mastectomy. Chemotherapy (four cycles of epirubicin and paclitaxel and three cycles of CMF: cyclophosphamide, methotrexate and 5FU), radiation therapy and hormonal therapy with tamoxifen were given after mastectomy. In 2007, she was submitted to total thyroidectomy due to toxic multinodular goitre and a permanent postoperative hypoparathyroidism was developed as a postoperative complication. The patient was receiving replacement therapy with levothyroxin 100 µg/day, calcium carbonate 2 gr/day, cholecalciferol 1600 IU/day, alfacalcidol 2 µg/day, po.

The patient remained stable for several years until December 2015 (7 months prior to her admission), when liver and bone metastases were detected. Chemotherapy with paclitaxel and carboplatin was started and on March 2016 (3 months prior to her admission), zoledronic acid (ZA, 4 mg intravenously) was added to standard therapy in order to reduce the development of bone metastases and to improve disease outcome.<sup>4</sup>

**INVESTIGATIONS AND DIFFERENTIAL DIAGNOSIS**

Results from the laboratory investigation on admission as well as the biochemical profile of the patient 7 months before are shown in table 1. A firm cause of the hypocalcaemia could not be identified. She was properly taking her medicines providing adequate amounts of calcium while there was no malabsorption of calcium since <5% of the oral calcium intake was excreted via the faeces. She was almost vitamin D sufficient. The plasma parathyroid hormone (PTH) level was inappropriately low in line with permanent hypoparathyroidism, but she was also taking the active metabolite of vitamin D. Serum magnesium and albumin levels were normal, and tumour lysis syndrome was excluded due to normal serum levels of potassium, uric acid and low-normal levels of phosphorus.

Evaluation of bone turnover markers revealed a predominant increase of bone formation markers: CTX=0.79 (1 ng/mL), NTX=38 (6.2–19 nM), PINP=551 (16–74 ng/dL), BAP =>120 (14.2–42.7 U/L), BGP (osteocalcin)=72.6 (15–46 ng/mL).



CrossMark

**To cite:** Kassi E, Kapsali I, Kokkinos M, et al. *BMJ Case Rep* Published Online First: [please include Day Month Year]. doi:10.1136/bcr-2017-219354

**Table 1** Biochemical data 7 months before admission, on admission, on discharge and 14 days after administration of <sup>153</sup>Sm-EDTMP in a patient with breast cancer, osteoblastic skeletal metastases and permanent hypoparathyroidism

	7 months prior to admission and 4 months prior to the administration of zoledronic acid	On admission	Discharge	Two weeks after administration of <sup>153</sup> Sm-EDTMP
Ca (8.6–10.2 mg/dL)	8*	6.2*	7.3*	9.7*
P (2.5–4.5 mg/dL)	2.5	2.8	3	4.1
Alb (3.4–4.8 g/dL)	4.2	4.1	4.1	3.9
Crea (0.6–1.1 mg/dL)	0.7	0.8	0.7	0.8
PTH (8–76 pg/mL)	2.4	1.2		
ALP (48–141 U/L)	72	209	176	128
AST/ALT/γGT	26/20/12	23/18/9	22/16/8	24/19/9
25(OH)D <sub>3</sub> (>30 ng/dL)	24	27		
1.25(OH)D <sub>3</sub> (18–80 pg/mL)		85		
Mg (1.6–2.4 md/dL)		1.6	1.8	1.8
24 hours urine Ca (<250 mg)		160		

\*Corrected for albumin calcium levels.

γGT, gamma-glutamyl transpeptidase; Alb, albumin; ALP, alkaline phosphatase; ALT, alanine aminotransferase; AST, aspartate aminotransferase; Ca, calcium; Crea, creatine; Mg, magnesium; P, phosphorus.

A Tc<sup>99m</sup> bone scanning revealed diffusely increased radiotracer uptake in the thoracolumbar spine skull, sternum, ribs and pelvis and poor visualisation of the kidneys, consistent with a superscan (figure 1). The latter along with the predominance of the bone formation over bone resorption markers and the low urinary calcium excretion led to the diagnosis of hypocalcaemia due to extensive osteoblastic metastases.

**TREATMENT**

After starting intravenous calcium elemental 2700 mg along with alfacalcidol 4 μgr, calcium carbonate 4 gr, elemental Mg 120 mg, po daily and cholecalciferol 70 000 IU once, serum calcium levels increased several days later (7.3 mg/dL) (table 1). Patient discharge instructions were calcium citrate 4.8 gr in six divided doses, cholecalciferol 1200 IU, alfacalcidol 4 μgr, elemental Mg 60 mg po, per day.

Despite this treatment, serum calcium falls back to level that causes intense symptoms. Thus, intravenous administration of

elemental Ca 500 mg was added three times per week. Serum calcium remained close to levels such as 7–7.3 mg/dL and treatment with <sup>153</sup>Sm-EDTMP was decided.<sup>3</sup>

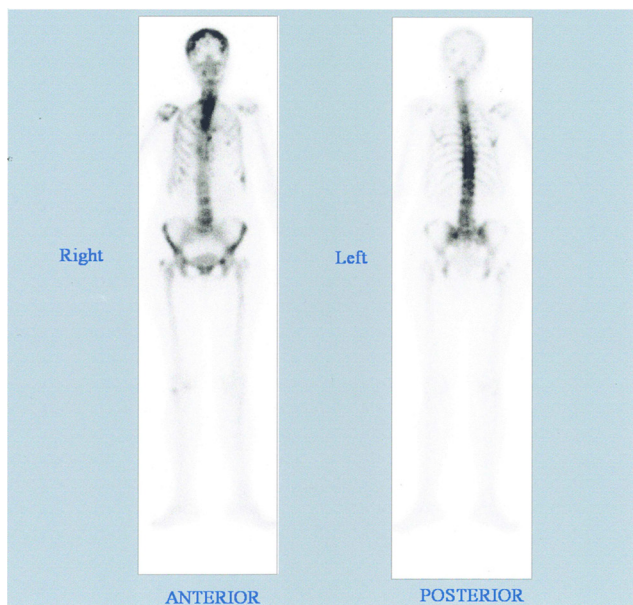
Figure 2 shows the corrected for albumin serum calcium trend.

**OUTCOME AND FOLLOW-UP**

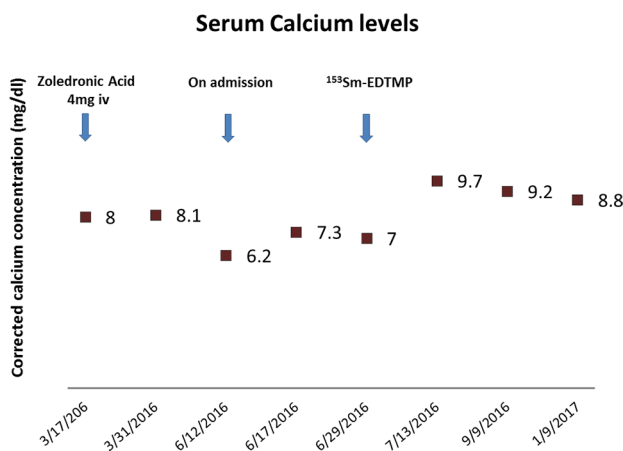
Fourteen days after administration of <sup>153</sup>Sm-EDTMP, the biochemical analysis of the patient was improved (table 1, figure 2) while the recommended dosage regimens were modified: calcium citrate 2.4 gr, cholecalciferol 800 IU, alfacalcidol 2 μgr, elemental Mg 60 mg, po. The patient remained stable until the 6-month follow-up (January 2017) where a CT showed diffuse metastases in the liver and a solitary lesion in the spleen.

**DISCUSSION**

Symptomatic hypocalcaemia is a highly unusual feature of malignant disease. In a total of 7000 patients with cancer, only 1.6% was reported to have hypocalcaemia.<sup>2</sup> Increased calcium utilisation by extensive osteoblastic skeletal metastasis remains the primary cause of hypocalcaemia.<sup>2</sup> Actually, the presence of bone metastases increases the prevalence of hypocalcaemia to 5%–13%.<sup>5</sup>



**Figure 1** Tc<sup>99m</sup> bone scanning consistent with superscan.



**Figure 2** The corrected for albumin serum calcium trend.

The most common malignant neoplasm which can cause hypocalcaemia is the prostate cancer with bone metastases (osteoblastic metastases are more frequent compared with osteoclastic ones).<sup>3</sup> Very rarely, the presence of bone metastases is associated with hypocalcaemia in breast cancer.<sup>6</sup>

In our patient, the main cause of hypocalcaemia seems to be the excessive influx of calcium into the skeleton due to the increased osteoblastic activity. However, symptomatic hypocalcaemia in patients with osteoblastic metastases is a rare event, so that increased osteoblastic activity alone could be not able to induce and maintain a hypocalcaemic state, especially if the compensatory mechanisms work sufficiently in order to restore this hypocalcaemia. In our case, the patient has pre-existing postoperative, permanent hypoparathyroidism along with osteoblastic metastases. The serum PTH level was in fact inappropriately low, in view of the severity of the hypocalcaemia, confirming the absence of the parathyroid glands' function. Thus, the feedback mechanism with regulation of PTH release by low serum calcium concentrations was not possible. In the literature, there are few cases with hypocalcaemia due to osteoblastic and/or mixed metastases and hypoparathyroidism in patients with breast cancer, most of them summarised in the article by Bergkamp *et al.*<sup>7</sup> In most cases, the hypoparathyroidism is attributed to (1) direct suppression of PTH secretion by the action of antineoplastic drugs (adriamycin, doxorubicin, cytarabin, vinblastin), (2) functional hypoparathyroidism caused by hypomagnesaemia (doxorubicin, cytarabin), (3) metastatic infiltration of the parathyroid glands; this is a common autopsy finding (6%–12%) especially in breast cancer but in order to lead to a clinical manifestation, it must be occupied at least 70% of parathyroid tissue—a rare situation and (4) previous irradiation of the neck region.<sup>7</sup>

In all cases, hypocalcaemia was treated symptomatically with high calcium doses intravenous or/and po, the active metabolite of vitamin D po and magnesium intravenous or po. In cases that the cause was metastases in bone or in parathyroid, patients improved their clinical and biochemical features with the continuation of chemotherapy. In few cases where toxic effects of chemotherapy on parathyroid glands were suspected, the chemotherapy was replaced with good results. To our knowledge, this is the first report of persistent hypocalcaemia due to osteoblastic metastases and permanent postoperative hypoparathyroidism.

The ZA is used for the treatment of the skeletal-related events.<sup>4</sup> Furthermore, this drug is very useful to treat the hypercalcaemia of malignancy.<sup>4</sup> However, it is known that ZA may cause hypocalcaemia by the inhibition of the activity of osteoclasts.<sup>8</sup> In most cases, ZA causes hypocalcaemia during the first days following intravenous infusion.<sup>9</sup> According to Black *et al.*<sup>10</sup> transient and asymptomatic hypocalcaemia occurred 9–11 days after the first intravenous administration of 5 mg ZA in osteoporotic patients. Kreutle *et al.*<sup>11</sup> reported four cases with osteoblastic metastases, where hypocalcaemia occurred between 4th and 11th day after the most recent bisphosphonate dose. Among the risk factors contributing to the development of hypocalcaemia after ZA administration, in patients with bone metastasis, is the pretreatment hypocalcaemia, the co-administration of corticosteroids and multiple bone metastasis (>3),<sup>12</sup> although the latter has not been confirmed by Zuradelli *et al.*<sup>13</sup>

However, it is interesting to mention that nitrogen-containing bisphosphonates such as ZA at lower concentrations have been suggested to exert a stimulatory effect on osteoblast activity enhancing the differentiation and activity of osteoblasts.<sup>14</sup> These effects are translated in the in vivo environment as increased bone

mineralisation that could additionally contribute to the persistence of hypocalcaemia in our patient. In our patient, 4 mg ZA intravenous was given once, 3 months prior to her admission to our hospital with hypocalcaemia. Of note, as it is shown in figure 2 that calcium levels remained stable even nearby after the ZA infusion, presumably due to the absence of other contributing factors such as malnutrition, renal insufficiency and vitamin D deficiency.<sup>11</sup>

Radionuclide therapy is widely used for pain palliation due to skeletal metastasis. Although our patient was not suffered from bone pain, the administration of <sup>153</sup>Sm-EDTMP (37 MBq/kg) was decided.<sup>15</sup> <sup>153</sup>Sm is radiolabelled to a polyphosphonic acid (EDTMP) and adsorbed onto the hydroxyapatite surface of metabolically active bone.<sup>15</sup> The selective uptake of bone-seeking radiopharmaceuticals depends on the degree of the osteoblastic response of metastatic tissue.<sup>15</sup> Actually, increased bone turnover can lead to enhanced incorporation of <sup>153</sup>Sm-EDTMP at metastatic sites, compared with normal bone; this leads to deliver a high, targeted local radiation dose.<sup>15</sup>

Our patient had no contraindications to take radionuclide therapy, and <sup>153</sup>Sm-EDTMP was well tolerated and led to normalisation of calcium levels as early as 14 days after its administration, and this was sustained 6 months later. Although an early post-therapy imaging to confirm selective tracer uptake would be useful, this was not performed, according to the choice of our patient. A possible mechanism is the apoptosis of the osteoblasts nearby the surface of metabolically active bone and thus the discontinuation of the excessive calcium influx to skeleton.

### Learning points

- ▶ Severe hypocalcaemia is a rare complication of malignant disease with osteoblastic bone metastases.
- ▶ It can be prevented by closely monitoring the serum calcium and vitamin D<sub>3</sub> levels.
- ▶ In case of persistent hypocalcaemia due to co-existence of permanent hypoparathyroidism, the administration of radionuclide therapy with <sup>153</sup>Sm-EDTMP could be an effective option.

**Contributors** HG was the clinician responsible for the medical treatment of patient. IK, MK and EK were taking care of the patient during the hospitalization. EK and IK wrote the manuscript. All authors read, edited and approved the case report.

**Competing interests** None declared.

**Patient consent** Obtained.

**Provenance and peer review** Not commissioned; externally peer reviewed.

**Open Access** This is an Open Access article distributed in accordance with the Creative Commons Attribution Non Commercial (CC BY-NC 4.0) license, which permits others to distribute, remix, adapt, build upon this work non-commercially, and license their derivative works on different terms, provided the original work is properly cited and the use is non-commercial. See: <http://creativecommons.org/licenses/by-nc/4.0/>

© BMJ Publishing Group Ltd (unless otherwise stated in the text of the article) 2017. All rights reserved. No commercial use is permitted unless otherwise expressly granted.

### REFERENCES

- 1 Jung K, Lein M. Bone turnover markers in serum and urine as diagnostic, prognostic and monitoring biomarkers of bone metastasis. *Biochim Biophys Acta* 2014;1846:425–38.
- 2 Blomqvist CP. A hospital survey of hypocalcaemia in patients with malignant disease. *Acta Med Scand* 1986;220:167–73.
- 3 Riveros HA, Almodóvar LO, Danés CF, *et al.* Hungry bone syndrome: persistent hypocalcaemia related to osteoblastic bone metastases of prostate cancer. *J Palliat Med* 2013;16:1496–7.

## Unexpected outcome (positive or negative) including adverse drug reactions

- 4 Coleman R, Cameron D, Dodwell D, *et al*. Adjuvant zoledronic acid in patients with early breast cancer: final efficacy analysis of the AZURE (BIG 01/04) randomised open-label phase 3 trial. *Lancet Oncol* 2014;15:997–1006.
- 5 Riancho JA, Arjona R, Valle R, *et al*. The clinical spectrum of hypocalcaemia associated with bone metastases. *J Intern Med* 1989;226:449–52.
- 6 Wiegand MC, Burshell A, Jaspan J, *et al*. Case report: clinical hypocalcemia: the endocrine conference of the Alton Ochsner Medical Institutions and Tulane University Medical Center. *Am J Med Sci* 1994;308:255–8.
- 7 Bergkamp F, Van Berkel A, van der Linden P, *et al*. Unexpected prolonged extreme hypocalcaemia and an inadequate PTH response in a patient with metastatic breast carcinoma. 2003;61:371–5.
- 8 Freedman DB, Shannon M, Dandona P, *et al*. Hypoparathyroidism and hypocalcaemia during treatment for acute leukaemia. *Br Med J* 1982;284:700–2.
- 9 Do WS, Park JK, Park MI, *et al*. Bisphosphonate-induced severe hypocalcemia - a case report. *J Bone Metab* 2012;19:139–45.
- 10 Black DM, Delmas PD, Eastell R, *et al*. Once-yearly zoledronic acid for treatment of postmenopausal osteoporosis. *N Engl J Med* 2007;356:1809–22.
- 11 Kreutle V, Blum C, Meier C, *et al*. Bisphosphonate induced hypocalcaemia - report of six cases and review of the literature. *Swiss Med Wkly* 2014;144:w13979.
- 12 Hanamura M, Iwamoto T, Soga N, *et al*. Risk factors contributing to the development of hypocalcemia after zoledronic acid administration in patients with bone metastases of solid tumor. *Biol Pharm Bull* 2010;33:721–4.
- 13 Zuradelli M, Masci G, Biancofiore G, *et al*. High incidence of hypocalcemia and serum creatinine increase in patients with bone metastases treated with zoledronic acid. *Oncologist* 2009;14:548–56.
- 14 Ho JW. Bisphosphonate stimulation of osteoblasts and osteoblastic metastasis as a mechanism of hypocalcaemia. *Med Hypotheses* 2012;78:377–9.
- 15 Fischer M, Kampen WU. Radionuclide therapy of bone metastases. *Breast Care* 2012;7:100–7.

Copyright 2017 BMJ Publishing Group. All rights reserved. For permission to reuse any of this content visit <http://group.bmj.com/group/rights-licensing/permissions>.  
BMJ Case Report Fellows may re-use this article for personal use and teaching without any further permission.

Become a Fellow of BMJ Case Reports today and you can:

- ▶ Submit as many cases as you like
- ▶ Enjoy fast sympathetic peer review and rapid publication of accepted articles
- ▶ Access all the published articles
- ▶ Re-use any of the published material for personal use and teaching without further permission

For information on Institutional Fellowships contact [consortiasales@bmjgroup.com](mailto:consortiasales@bmjgroup.com)

Visit [casereports.bmj.com](http://casereports.bmj.com) for more articles like this and to become a Fellow