

Case report

Cladribine treatment for Erdheim–Chester disease involving the central nervous system and concomitant polycythemia vera: A case report

Suguru Tamura,¹⁾ Keisuke Kawamoto,¹⁾ Hiroaki Miyoshi,²⁾ Takaharu Suzuki,^{1,2)} Takayuki Katagiri,¹⁾ Takuya Kasami,¹⁾ Hiroki Nemoto,¹⁾ Shukuko Miyakoshi,¹⁾ Hironori Kobayashi,¹⁾ Yasuhiko Shibasaki,¹⁾ Masayoshi Masuko,¹⁾ Kengo Takeuchi,³⁾ Koichi Ohshima,²⁾ Hirohito Sone,¹⁾ and Jun Takizawa¹⁾

Erdheim–Chester disease (ECD), a rare form of non-Langerhans cell histiocytosis, is characterized by the infiltration of foamy CD68⁺ and CD1a⁺ histiocytes into multiple organ systems. Central nervous system (CNS) involvement has recently been reported to be a poor prognostic factor when treating ECD with interferon alpha. We report the case of a 66-year-old Japanese patient with ECD involving the CNS who harbored the *BRAF* V600E mutation and also concomitantly developed polycythemia vera with the *JAK2* V617F mutation. We confirmed 2-chlorodeoxyadenosine (cladribine) therapy to be effective for the patient in this case.

Keywords: Erdheim–Chester disease, polycythemia vera, *JAK2*, *BRAF*, cladribine

INTRODUCTION

Histiocytoses comprise a broad-spectrum group of rare tumors characterized by the proliferation of histiocytes.^{1,2} They are generally classified as Langerhans cell histiocytosis (LCH) or non-LCH.^{3,4} Erdheim–Chester disease (ECD), which is a rare form of non-LCH, is characterized by the infiltration of foamy CD68⁺ and CD1a⁺ histiocytes into multiple organ systems.¹ The clinical manifestation and course of ECD depend on the disease extent and distribution. In particular, extensive central nervous system (CNS) involvement is one life-threatening progression. Although the pathogenesis of LCH and ECD is unknown, a somatic mutation in the *BRAF* V600E gene was recently identified in LCH and ECD, suggesting that both diseases are neoplasms and share common progenitor cells.⁵⁻⁷

Interferon alpha (IFN α) has been the most extensively studied treatment for patients with ECD and has been utilized as its first-line treatment.^{1,8,9} However, CNS involvement is reported to be a poor prognostic factor when treating ECD

with IFN α due to the blood–brain barrier.¹⁰ On the other hand, therapy with 2-chlorodeoxyadenosine (cladribine), a purine analog, was reported to be effective for LCH harboring the *BRAF* V600E mutation with CNS involvement.¹¹

Polycythemia vera (PV) is a classic Philadelphia chromosome-negative myeloproliferative neoplasm (MPN) primarily characterized by increased red blood cell production.¹²⁻¹⁴ One of the most well-known pathogeneses of PV is characterized by mutations in the Janus kinase 2 (*JAK2*) gene, such as the *JAK2* V617F mutation and the *JAK2* exon 12 mutation.^{15,16}


Although there has been no previous report of a patient with ECD exhibiting PV at diagnosis, we treated a patient diagnosed with the very rare concomitant development of ECD harboring the *BRAF* V600E mutation with CNS involvement, and PV with the *JAK2* V617F mutation. Based on previous case reports, we started cladribine therapy.^{11,17} This case confirmed cladribine to be an effective therapy for ECD harboring the *BRAF* V600E mutation with CNS involvement.

Received: April 13, 2018. Revised: August 2, 2018. Accepted: August 13, 2018. J-STAGE Advance Published: October 10, 2018
DOI:10.3960/jslrt.18015

¹⁾Department of Hematology, Endocrinology and Metabolism, Faculty of Medicine, Niigata University, Niigata, Japan, ²⁾Department of Pathology, School of Medicine, Kurume University, Kurume, Japan, ³⁾Pathology Project for Molecular Targets, Cancer Institute, Japanese Foundation for Cancer Research, Tokyo, Japan

Corresponding author: Jun Takizawa, M.D., Ph.D., Department of Hematology, Endocrinology and Metabolism, Niigata University Faculty of Medicine 1-757 Asahimachi-dori, Niigata, Niigata 951-8510, Japan. E-mail: juntaki@med.niigata-u.ac.jp

Copyright © 2018 The Japanese Society for Lymphoreticular Tissue Research

 This work is licensed under a Creative Commons Attribution-NonCommercial-ShareAlike 4.0 International License.

CASE REPORT

A 66-year-old Japanese man had been diagnosed with central diabetes insipidus based on laboratory analysis, urinary analysis, and magnetic resonance imaging (MRI) of the head, and had begun treatment with desmopressin acetate (DDAVP, Desmopressin®). Four years after this diagnosis, he presented to our hospital for gradual exacerbation of systemic bone pain. MRI of the head revealed a left lateral ventricular mass (35 mm × 20 mm), and systemic computed tomography (CT) demonstrated swelling of the posterior pituitary gland, ground-glass opacity of both lungs, abnormal aorta wall, and swelling of both kidneys and the pancreas (Figure 1 a-e). Biopsy of the lateral ventricular mass was performed for diagnosis, but discrimination between ECD and Rosai–Dorfman disease (RDD) was difficult due to an insufficient amount of the specimen. However, high integration in the long bones, scapulae, and ribs was noted by technetium-99 (^{99m}Tc) bone scintigraphy, suggesting ECD (Figure 2). Therefore, we additionally performed a biopsy of the left tibia. Hematoxylin and eosin (H&E) staining and immunohistochemistry (IHC) revealed an increase in atypical histiocytes and foamy cells, as well as CD1a (-), S100 (-), CD68 (+), and the *BRAF* V600E mutation (+) (Figure 3). From the above results, we diagnosed the patient with ECD. On laboratory examination of peripheral blood, his white blood cell count was 11,700/μL, hemoglobin was 18.8 g/dL, hematocrit was 55.1%, and the platelet count was 262,000/μL. Additionally, serum erythropoietin was 2.9 mIU/mL, and the *JAK2* V600F mutation was positive based on polymerase chain reaction (PCR) analysis of the bone marrow. Thus, we further diagnosed this patient with ECD harboring the *BRAF* V600E mutation with CNS involvement and concomitant PV with the *JAK2* V617F mutation. It was speculated that the central diabetes insipidus was caused by the lesion on the posterior pituitary gland, which was one of the ECD lesions. Subsequently, the patient began cladribine therapy (one cycle, 0.12 mg/kg, day 1–5 q4w). After four cycles of cladribine therapy, a slight volume reduction of the left ventricular and posterior pituitary masses was found on CT, and the patient exhibited stable disease (SD) based on the NCCN Clinical Practice Guidelines in Oncology (NCCN Guidelines®, Figure 1 f-j). The treatment was terminated at the end of five cycles because the patient developed systemic herpes zoster virus infection. Severe bone marrow suppression (≥ grade 3) was not observed during the treatment period. Although central diabetes insipidus was not improved by cladribine therapy, the patient maintained SD. However sixteen months after the last cladribine course, he presented with recurrent fever. CT revealed swelling and hydronephrosis of the left kidney. After retreatment with two cycles of cladribine, he achieved partial remission because his swollen kidney had decreased in size to that before progression on CT, but was not normalized. Exacerbation and/or complications of PV, such as thrombosis and bleeding, have not been observed.

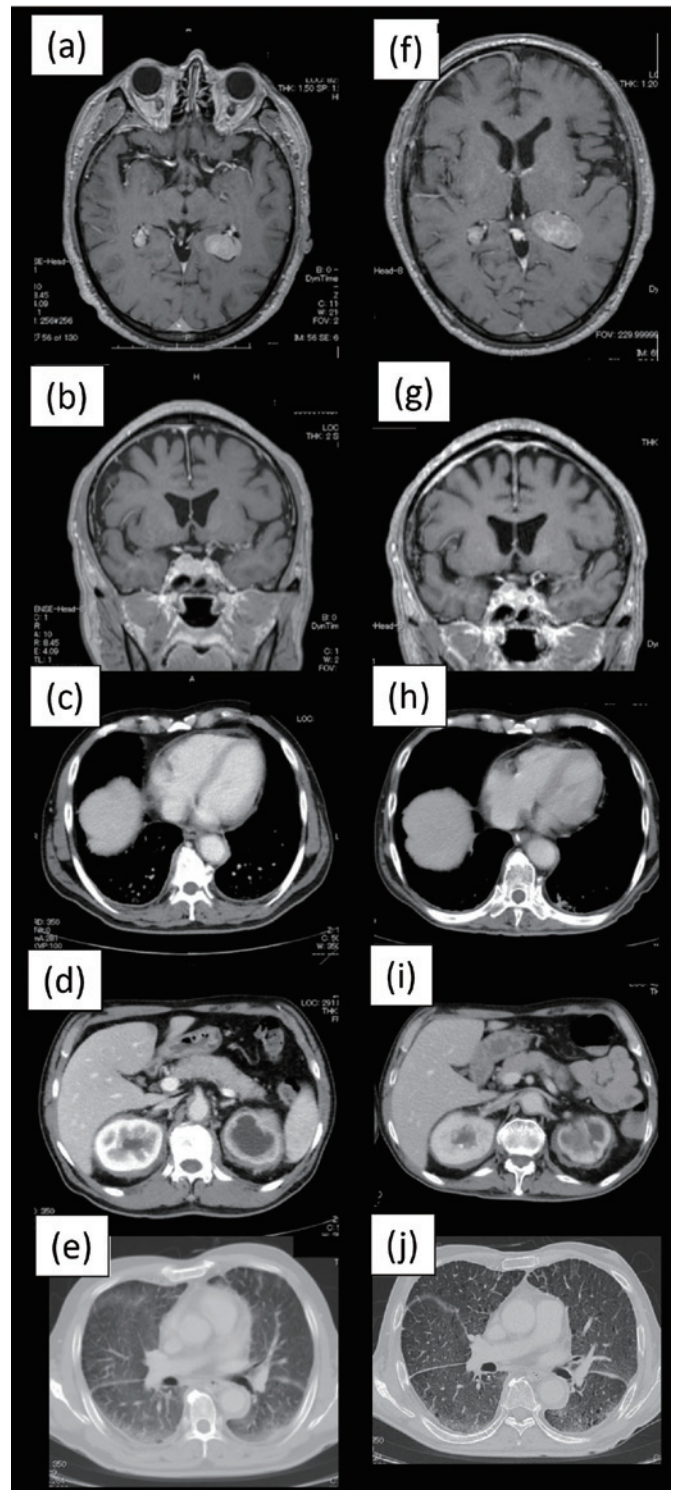


Fig. 1. Magnetic resonance imaging (MRI) of the head, and computed tomography (CT) of the chest and abdomen at the time of diagnosis (a-e) and after treatment (f-j). (a, f) A left ventricular mass is observed. (b, g) Swelling of the posterior pituitary gland. (c, h) Abnormalities in the aorta wall. (d, i) Swelling is observed in both kidneys and the pancreas. (e, j) Ground-glass opacity is observed in both lungs. We judged the patient to have stable disease (SD) because there were no differences between the pretreatment and posttreatment radiographic findings.

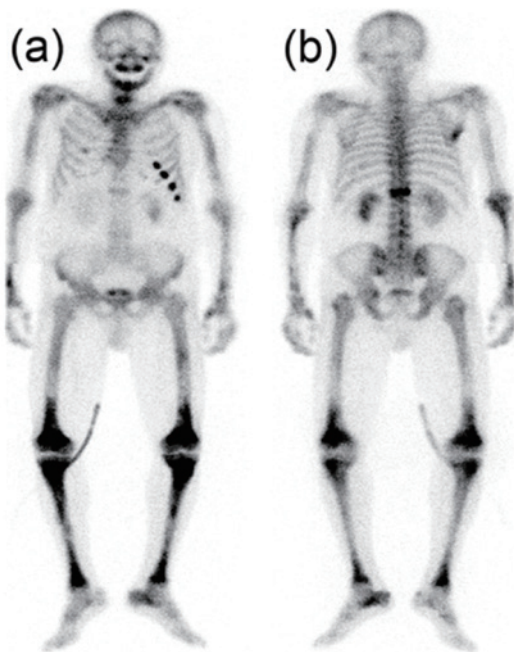


Fig. 2. Technetium 99 (^{99m}Tc) bone scintigraphy. (a) Anterior. (b) Posterior. ^{99m}Tc bone scintigraphy shows high integration in the long bones, scapulae, and ribs.

DISCUSSION

Our case suggests that cladribine therapy is an effective therapy for ECD harboring the *BRAF* V600F mutation with CNS involvement in terms of inhibiting disease progression. In addition, the patient also developed PV with the *JAK2* V617F mutation concomitantly.

Although this patient was diagnosed with central diabetes insipidus in another hospital before admission to our hospital, the cause of the central diabetes insipidus has not been determined. One reason for this may be that ECD has been poorly understood because less than 500 patients with ECD have been previously reported.³ On the other hand, CNS lesions, including on the pituitary gland, have been reported to be frequent development sites for histiocytosis.^{2,18,19} In particular, central diabetes insipidus has been reported to be present in the early stage of ECD.²⁰ Although ECD is a very rare disease, clinicians should be aware of this disorder when CNS lesions, including pituitary lesions, and/or pituitary hormone abnormalities, such as diabetes insipidus, are suggested.

Our patient demonstrated concomitant development of ECD harboring the *BRAF* V600E mutation and PV with the *JAK2* V617F mutation. Although polycythemia was initially considered as a result of exacerbated diabetes insipidus, PV was confirmed based on erythropoietin values and PCR analysis of the bone marrow.^{2,18,19} We were unable to verify the *BRAF* V600E mutation by IHC in megakaryocytes in addition to the *JAK2* V617F mutation because the amount of remaining specimen was too small. Although the

coexistence of *JAK2* V617F and *BRAF* V600E mutations was not confirmed in the same cell, we report this very rare case of a patient with comorbid ECD harboring both the *BRAF* V600E mutation and PV with the *JAK2* V617F mutation. To the best of our knowledge, only one case has been reported other than ours.²¹ On the other hand, LCH and ECD have been proposed to be redefined as inflammatory myeloid neoplasia because the ERK signaling pathway at the essential stage of myeloid differentiation has been suggested as a driver of LCH.²² In addition, LCH and ECD have recently been suggested to have common myeloid progenitor cells.²³ These results indicate the presence of *JAK2* V617F and *BRAF* V600E mutations in common progenitor cells; however, further studies are required to detect progenitor cells.

In this case, we considered cladribine to be effective for ECD with CNS involvement harboring the *BRAF* V600F mutation because the patient maintained SD for a long period (approximately 36 months), even though the median survival of ECD is reported to be approximately 2 years.¹⁷ Additionally, severe bone marrow suppression was not observed during treatment. Therefore, cladribine therapy may be a relatively safe treatment for elderly patients with ECD. We selected cladribine therapy based on previous reports. First, CNS involvement was reported to be a poor prognostic factor when treating ECD with IFN α .¹⁰ Second, cladribine therapy was effective for LCH with CNS involvement harboring the *BRAF* V600E mutation.¹¹ These results combined with ours suggest that cladribine is effective for histiocytoses harboring the *BRAF* V600E mutation. Although the diffusion rate of IFN α through the blood–brain barrier is very low (0.08–0.12%),²⁴ cladribine reportedly penetrates the blood–brain barrier, reaching a cerebrospinal fluid/plasma concentration of approximately 25% of the plasma level.²⁵ In contrast, vemurafenib, a novel selective *BRAF* inhibitor, has recently been reported to be effective for several malignancies harboring *BRAF* V600E mutations.^{26–29} However, the distribution of vemurafenib is speculated to be severely restricted by the blood–brain barrier.³⁰ Our experience suggests that cladribine is an optimal treatment for ECD patients with CNS involvement because of its blood–brain barrier permeability. However, large-scale prospective studies are needed to confirm the efficacy of cladribine for ECD with CNS involvement.

Thus, this report suggests that cladribine therapy is more optimal than current therapies for ECD patients with CNS involvement harboring *BRAF* V600E mutations. As severe bone marrow suppression was not observed, it may be a particularly effective treatment for elderly patients. Additionally, this report also described an effective course of treatment for a patient with the very rare concomitant development of ECD and PV. Although ECD is very rare, it should be suspected when CNS lesions and/or diabetes insipidus are present.

CONFLICT OF INTEREST

The authors declare that they have no conflict of interest.

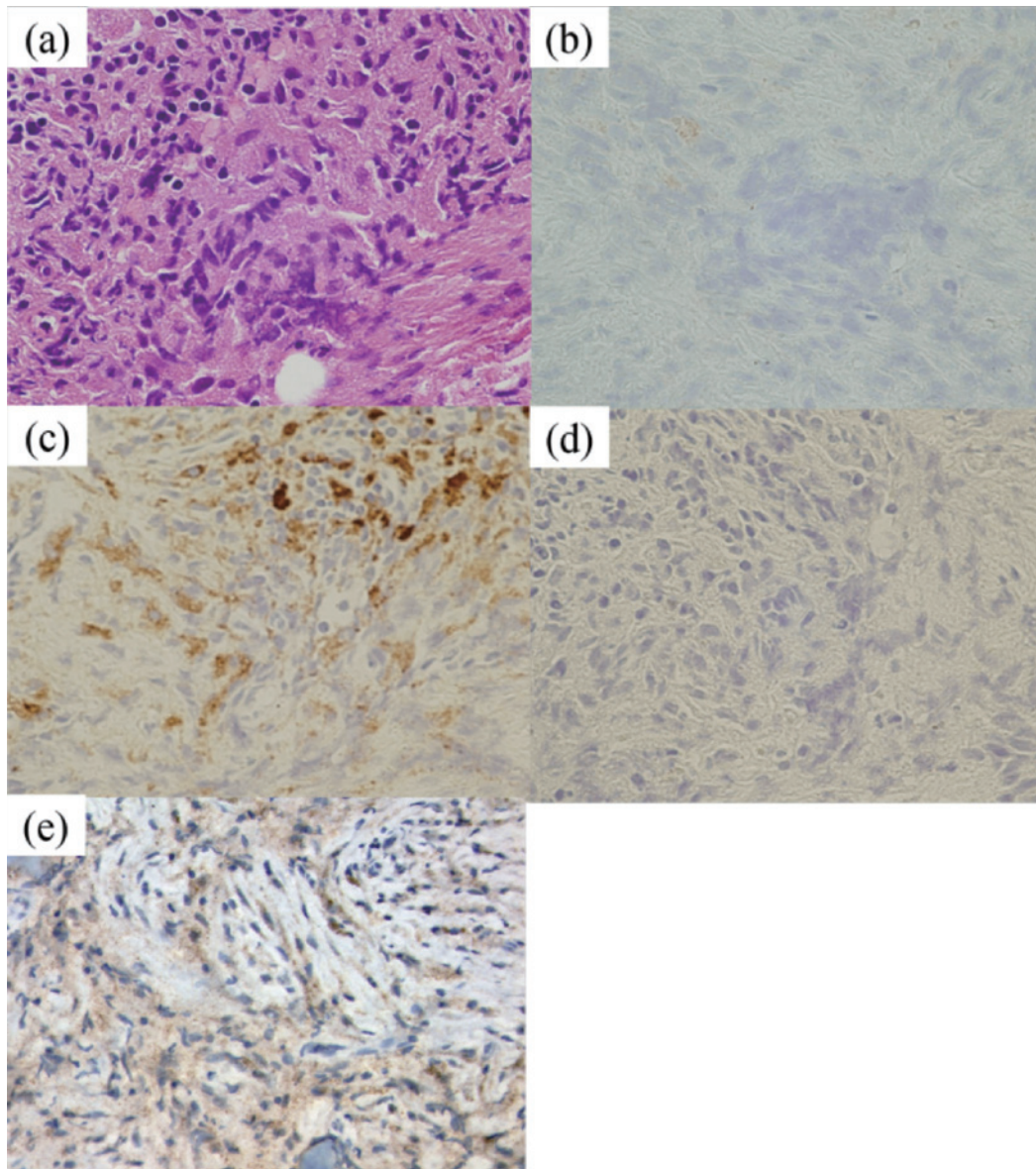


Fig. 3. Hematoxylin and eosin (H&E) staining, and immunohistochemistry (IHC) of the left tibia biopsy. (a) H&E staining. (b) Negative expression of CD1a. (c) Positive expression of CD68. (d) Negative expression of S-100. (e) Positive expression of the *BRAF* V600E mutation detected by IHC.

REFERENCES

- 1 Haroche J, Arnaud L, Amoura Z. Erdheim–Chester disease. *Curr Opin Rheumatol.* 2012; 24 : 53-59.
- 2 Arnaud L, Gorochov G, Charlotte F, *et al.* Systemic perturbation of cytokine and chemokine networks in Erdheim–Chester disease: a single-center series of 37 patients. *Blood.* 2011; 117 : 2783-2790.
- 3 Haroche J, Arnaud L, Cohen-Aubart F, *et al.* Erdheim–Chester Disease. *Rheum Dis Clin North Am.* 2013; 39 : 299-311.
- 4 Badalian-Very G, Vergilio JA, Fleming M, Rollins BJ. Pathogenesis of Langerhans cell histiocytosis. *Annual Review of Pathology: Mechanisms of Disease.* 2013; 8 : 1-20.
- 5 Badalian-Very G, Vergilio JA, Degar BA, *et al.* Recurrent *BRAF* mutations in Langerhans cell histiocytosis. *Blood.* 2010; 116 : 1919-1923.
- 6 Hervier B, Haroche J, Arnaud L, *et al.*; French Histiocytoses Study Group. Association of both Langerhans cell histiocytosis and Erdheim–Chester disease linked to the *BRAF*V600E mutation. *Blood.* 2014; 124 : 1119-1126.
- 7 Badalian-Very G. A common progenitor cell in LCH and ECD. *Blood.* 2014; 124 : 991-992.
- 8 Braiteh F, Boxrud C, Esmaeli B, Kurzrock R. Successful treatment of Erdheim–Chester disease, a non-Langerhans-cell histiocytosis, with interferon- α . *Blood.* 2005; 106 : 2992-2994.
- 9 Suzuki HI, Hosoya N, Miyagawa K, *et al.* Erdheim–Chester disease: multisystem involvement and management with interferon- α . *Leuk Res.* 2010; 34 : e21-e24.
- 10 Arnaud L, Hervier B, Néel A, *et al.* CNS involvement and treatment with interferon- α are independent prognostic factors in Erdheim–Chester disease: a multicenter survival analysis of 53 patients. *Blood.* 2011; 117 : 2778-2782.

- 11 Baumann M, Cerny T, Sommacal A, Koeberle D. Langerhans cell histiocytosis with central nervous system involvement-complete response to 2-chlorodeoxyadenosine after failure of tyrosine kinase inhibitor therapies with sorafenib and imatinib. *Hematol Oncol.* 2012; 30 : 101-104.
- 12 Thiele J, Kvasnicka HM, Orazi A, *et al.* Polycythaemia vera. In: Swerdlow SH, Campo E, Harris NL, *et al.* (eds): WHO Classification of Tumours of Haematopoietic and Lymphoid Tissues. Revised 4th ed, Lyon, IARC Press. 2017; pp.39-43.
- 13 Hensley B, Geyer H, Mesa R. Polycythemia vera: current pharmacotherapy and future directions. *Expert Opin Pharmacother.* 2013; 14 : 609-617.
- 14 Passamonti F. How I treat polycythemia vera. *Blood.* 2012; 120 : 275-284.
- 15 Levine RL, Pardanani A, Tefferi A, Gilliland DG. Role of JAK2 in the pathogenesis and therapy of myeloproliferative disorders. *Nat Rev Cancer.* 2007; 7(9): 673-683.
- 16 Tefferi A. Mutations galore in myeloproliferative neoplasms: would the real Spartacus please stand up? *Leukemia.* 2011; 25 : 1059-1063.
- 17 Myra C, Sloper L, Tighe PJ, *et al.* Treatment of Erdheim-Chester disease with cladribine: a rational approach. *Br J Ophthalmol.* 2004; 88 : 844-847.
- 18 Kurtulmus N, Mert M, Tanakol R, Yarman S. The pituitary gland in patients with Langerhans cell histiocytosis: a clinical and radiological evaluation. *Endocrine.* 2015; 48 : 949-956.
- 19 Toro Galván S, Planas Vilaseca A, Michalopoulou Alevras T, *et al.* Endocrine changes in histiocytosis of the hypothalamic-pituitary axis. *Endocrinol Nutr.* 2015; 62 : 72-79.
- 20 Adam Z, Balsíková K, Krejčí M, *et al.* [Central diabetes insipidus in adult patients--the first sign of Langerhans cell histiocytosis and Erdheim-Chester disease. Three case studies and literature review]. *Vnitřní lékařství.* 2010; 56 : 138-148.
- 21 Iurlo A, Dagna L, Cattaneo D, *et al.* Erdheim-Chester disease with multiorgan involvement, following polycythemia vera: A case report. *Medicine (Baltimore).* 2016; 95(20): e3697.
- 22 Berres ML, Merad M, Allen CE. Progress in understanding the pathogenesis of Langerhans cell histiocytosis: back to Histiocytosis X? *Br J Haematol.* 2015; 169 : 3-13.
- 23 Haroche J, Ablu O. Uncommon histiocytic disorders: Rosai-Dorfman, juvenile xanthogranuloma, and Erdheim-Chester disease. *Hematology Am Soc Hematol Educ Program.* 2015; 2015 : 571-578.
- 24 Smith RA, Norris F, Palmer D, Bernhardt L, Wills RJ. Distribution of alpha interferon in serum and cerebrospinal fluid after systemic administration. *Clin Pharmacol Ther.* 1985; 37 : 85-88.
- 25 Liliemark J. The clinical pharmacokinetics of cladribine. *Clin Pharmacokinet.* 1997; 32 : 120-131.
- 26 Chapman PB, Hauschild A, Robert C, *et al.*; BRIM-3 Study Group. Improved survival with vemurafenib in melanoma with BRAF V600E mutation. *N Engl J Med.* 2011; 364 : 2507-2516.
- 27 Kopetz S, Desai J, Chan E, *et al.* Phase II pilot study of vemurafenib in patients with metastatic BRAF-mutated colorectal cancer. *J Clin Oncol.* 2015; 33: 4032-4038.
- 28 Haroche J, Cohen-Aubart F, Emile JF, *et al.* Reproducible and sustained efficacy of targeted therapy with vemurafenib in patients with BRAF(V600E)-mutated Erdheim-Chester disease. *J Clin Oncol.* 2015; 33 : 411-418.
- 29 Samuel J, Macip S, Dyer MJS. Efficacy of vemurafenib in hairy-cell leukemia. *N Engl J Med.* 2014; 370 : 286-288.
- 30 Mittapalli RK, Vaidyanathan S, Sane R, Elmquist WF. Impact of P-glycoprotein (ABCB1) and breast cancer resistance protein (ABCG2) on the brain distribution of a novel BRAF inhibitor: vemurafenib (PLX4032). *J Pharmacol Exp Ther.* 2012; 342 : 33-40.