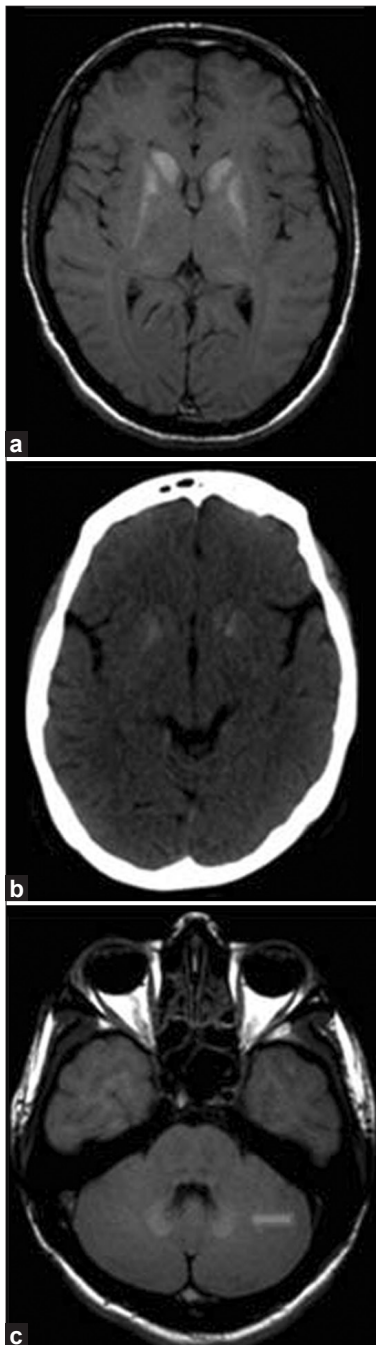


# Hypoparathyroidism

Sir,

A 20-year-old female presented with seizures, spasmodic contractions and paresthesia of limbs of the left side and



**Figure 1:** (a) Axial T1 weighted magnetic resonance image showing symmetrical hyperintensities in the bilateral basal ganglia. (b) Computed tomography (CT) image of the same patient showing evidence of calcification in the basal ganglia. (c) Axial T1 weighted image showing symmetric hyperintense signal in bilateral dentate nuclei, which also showed evidence of calcification in CT sections

ataxic gait of 3 years duration. Carpopedal spasm was present. Trousseau's and Chovstek's signs were positive. Cerebellar signs were positive. Biochemical analysis revealed hypocalcemia (1.3 mmol/L; normal range 2.10–2.60 mmol/L), hyperphosphatemia (2.5 mmol/L; normal range 0.8–1.5 mmol/L) and low Parathyroid hormone level (0.6 pmol/L; normal range 1.5–7.6 pmol/L). Imaging [Figure 1] revealed intracranial calcification. Hypocalcemia results in increased neuromuscular excitability, which manifests as tetany, paresthesia, seizures, organic brain syndrome or calcium deposition leading to cataract or intracranial calcification. Supplementation with calcium and 1,25-dihydroxy vitamin D is helpful in preventing seizures and progression to extrapyramidal disorders.<sup>[1,2]</sup>

Idiopathic hypoparathyroidism is an infrequent condition of unknown etiology. Accepted criteria for its diagnosis are (a) low serum calcium, (b) high serum inorganic phosphates and (c) exclusion of renal insufficiency, steatorrhea, chronic diarrhea, alkalosis and rickets and osteomalacia. The classic findings in a patient with hypoparathyroidism are a rounded expressionless face, a shorter height than average and cataract. Dental hypoplasia and aplasia develop depending upon the age at the time of onset of the disease. In idiopathic hypoparathyroidism, basal ganglia calcification and extrapyramidal syndromes are more frequently seen, and symptoms are earlier in onset. In pseudohypoparathyroidism, there is ineffective parathormone action rather than a failure of parathyroid hormone production. However, it shares several clinical features with hypoparathyroidism.<sup>[3]</sup>

Hypocalcemia increases the neuromuscular excitability, which may result in tetany. Lower degrees of neuromuscular excitability may lead to latent tetany, which can be elicited by Chovstek's and Trousseau's signs. Chovstek's sign is demonstrated by tapping the skin over the facial nerve anterior to the external auditory meatus, and results in ipsilateral contraction of the facial muscles. Trousseau's sign is produced by inflating a sphygmomanometer to 20 mmHg above the systolic blood pressure for 3–5 min, which results in ischemia of nerves in the upper arm leading to thumb adduction, metacarpophalangeal joint flexion and interphalangeal joint extension.<sup>[1,2]</sup>

Paramdeep Singh, Kavita Saggar,  
Parambir Sandhu

Department of Radiodiagnosis,  
Dayanand Medical College and Hospital,  
Ludhiana, Punjab, India

**Address for correspondence:**

Dr. Paramdeep Singh,  
E-mail: paramdeepdoctor@gmail.com

## References

1. Sztriha L, Punnose J, Prais V, El-Khider A, Chandran P, Al Suhaili AR. Idiopathic hypoparathyroidism with basal ganglia calcification, epilepsy and interictal hyperperfusion. *J Child Neurol* 1998;13: 189-92.
2. Abe S, Tojo K, Ichida K, Shigematsu T, Hasegawa T, Morita M, *et al.* A rare case of idiopathic hypoparathyroidism with varied neurological manifestations. *Intern Med* 1996;35:129-34.
3. Potts TJ. Diseases of the parathyroid gland and other hyper and hypocalcemic disorder. In: Harrison's principles of internal medicine, 14<sup>th</sup> ed. New York: McGraw Hill; 1998;2:2241-3.

Access this article online	
<b>Quick Response Code:</b>	<b>Website:</b> www.asianjns.org
	<b>DOI:</b> 10.4103/1793-5482.95702