



Contents lists available at ScienceDirect

International Journal of Surgery Case Reports

journal homepage: www.casereports.com

Herniation of the colon through the foramen of Winslow—A case report

Lucia E. Duinhouwer^{a,*}, Eva Deerenberg^{a,2}, Elena Rociu^b, R.T.J. Kortekaas^a^a Department of Surgery, Franciscus Gasthuis & Vlietland, The Netherlands Kleiweg 500, 3045 PM Rotterdam, The Netherlands^b Department of Radiology, Franciscus Gasthuis & Vlietland, Rotterdam, The Netherlands

ARTICLE INFO

Article history:

Received 16 March 2016

Received in revised form 27 April 2016

Accepted 27 April 2016

Available online 4 May 2016

Keywords:

Herniation

Laparoscopic surgery

Bowel ischemia

Abdominal surgery

ABSTRACT

INTRODUCTION: Herniation of the bowel through the foramen of Winslow is a rare condition presenting with acute abdominal pain. Diagnostic delay often results in high morbidity and mortality.

CASE PRESENTATION: A patient presented with right sided acute abdominal pain. Computed tomography showed herniation of the ascending colon through the foramen of Winslow which could be reversed laparoscopically without the need for bowel resection. There were no postoperative complications and no recurrences have occurred to date.

DISCUSSION: Bowel herniation through the foramen of Winslow is very rare, comprising only 8% of all internal herniations. Historically, the majority of cases was diagnosed intra-operatively and bowel resection was necessary because of ischemia. With the introduction of computed tomography, the diagnosis can be made earlier, possibly resulting in a lower morbidity and mortality rate.

CONCLUSION: Herniation through the foramen of Winslow is a rare condition. Patients will present with sudden onset abdominal pain. Early imaging helps to recognize the diagnosis and could prevent bowel ischemia.

© 2016 The Authors. Published by Elsevier Ltd on behalf of IJS Publishing Group Ltd. This is an open access article under the CC BY-NC-ND license (<http://creativecommons.org/licenses/by-nc-nd/4.0/>).

1. Introduction

Herniation of the bowel through the foramen of Winslow is rare, comprising only 8% of all internal herniations [1,2]. Most cases describe a herniation of a small bowel loop (63%), the caecum and ascending colon (30%) or the transverse colon (7%) [1]. In addition, cases have been reported of herniation of the gall bladder [3,4], a small bowel diverticulum [5] or a Meckel's diverticulum [6]. The incidence of herniation through the foramen of Winslow is higher in men (ratio 2.5:1), with a peak incidence between 20 and 60 years of age [7]. Predisposing factors are an enlarged foramen, mobile small bowel loops due to an extended mesentery, an enlarged right liver lobe [8] and changes in intra-abdominal pressure [9]. Patients present with pain in the upper abdomen, sometimes combined with nausea, vomiting and icterus. Due to the nonspecific nature of the signs and symptoms, the diagnosis is mostly not considered in the differential diagnosis of a patient presenting with acute abdom-

inal pain. Unfortunately, the condition soon turns irreversible and diagnostic delay results in historical high morbidity and mortality rates [1]. Due to the widespread use of computed tomography (CT) and subsequent earlier diagnosis, it is expected that mortality rates will be reduced. This case report presents a patient with herniation of the colon through the foramen of Winslow, which was reversed laparoscopically without the need for bowel resection.

2. Case presentation

A 32-year old woman presented at the emergency department with sudden onset of abdominal pain since 6 h. The pain started in the upper right quadrant of the abdomen, then shifted to the lower right quadrant. The patient never experienced these complaints before. There was no dysuria or hematuria. The menstrual cycle was regular and there was no abnormal vaginal discharge. Medical history revealed hemithyroidectomy for a benign node, postpartum hemorrhage and endoscopic resection of an ovarian cyst left. Her general practitioner had started Omeprazol after the initiation of symptoms. Upon physical examination, there was no abdominal distension. There were symptoms of tenderness paraumbilical and in the right abdomen. The only abnormality in the laboratory findings was a leukocyte count of $12.1 \times 10^9/L$ (normal value $4.3\text{--}10.0 \times 10^9/L$). The differential diagnosis, was appendicitis, gastro-enteritis, ectopic pregnancy, ovarian torsion, rupture or bleeding of an ovarian cyst, cholecystitis or cholecystolithiasis. The

* Corresponding author.

E-mail addresses: lduinhouwer@erasmusmc.nl (L.E. Duinhouwer), e.deerenberg@erasmusmc.nl (E. Deerenberg), e.rociu@franciscus.nl (E. Rociu), r.kortekaas@franciscus.nl (R.T.J. Kortekaas).¹ Present address: Department of Surgery, IJsselland Ziekenhuis, Capelle aan den IJssel, The Netherlands.² Present address: Department of Surgery, Erasmus Medisch Centrum, Rotterdam, The Netherlands.

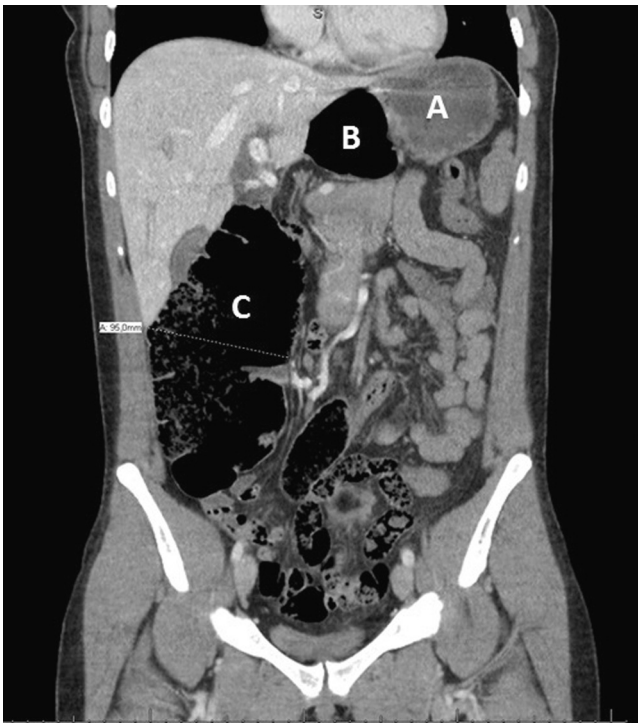


Fig. 1. Coronal image of the computed tomography scan showing a dilated ascending colon with a herniation of the hepatic flexure between liver and stomach. (A) Stomach. (B) Omental bursa with herniated and distended colon loop. (C) Distended ascending colon.

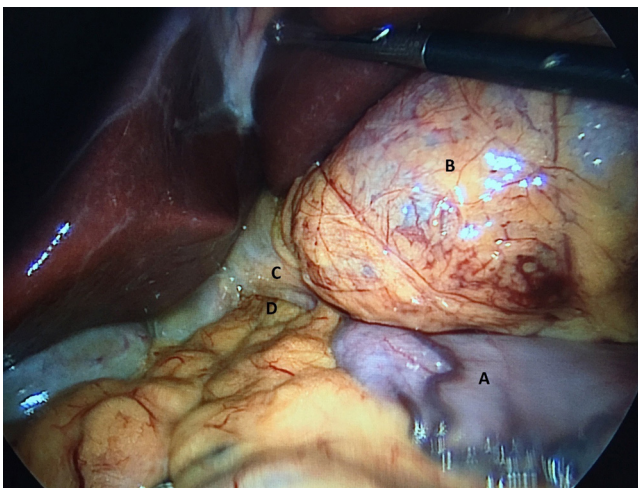


Fig. 2. Laparoscopic image showing the herniation through the foramen of Winslow and the distended colon loop in the omental bursa. (A) Stomach. (B) Omental bursa with herniated and distended colon loop. (C) Hepatoduodenal ligament. (D) Foramen of Winslow.

pregnancy test was negative. The appendix could not be identified by ultrasound as obscured by unusual amount of intraabdominal air. Abdominal computed tomography (Fig. 1) showed the unusual amount of air was severe dilation of the ascending colon (up to 9.5 cm diameter), extending behind the hepatoduodenal ligament with consequent displacement of stomach and pancreas. No signs of perforation were seen.

Laparoscopy was performed, showing herniation of dilated colon through foramen of Winslow, below the hepatoduodenal ligament (Fig. 2). Inspection of the abdomen showed a distended ascending colon and some distended small bowel loops. The herniated colon was reduced and appeared viable. A very low amount of

intra-abdominal fat was present and all vital structures surrounding Winslow's foramen were in sight (vena cava, portal vein and common bile duct). Therefore, it was not considered safe to close the foramen with stitches or tackers. There were no postoperative complications and, so far, no recurrences have occurred after 6 months of follow up.

3. Discussion

The foramen of Winslow is delineated anteriorly by the hepatoduodenal ligament, posteriorly by the inferior vena cava, superiorly by the caudate lobe of the liver and inferiorly by the duodenum [10]. Herniations through the foramen are very rare and comprise only 8% of all internal herniations [1,2]. In 1834, Bladin described the first case and since then, around 200 cases have been reported. As patients often present with nonspecific symptoms, the differential diagnosis is broad and should consist of gastro intestinal pathology (appendicitis, diverticulitis, gastro-enteritis, bowel ischemia, inflammatory bowel disease, peptic ulcer), pancreatitis, gall bladder pathology (cholesterolithiasis, choledocholithiasis, cholecystitis) and in women gynaecological pathology (ectopic pregnancy, ovarian torsion, ruptured or bleeding ovarian cyst). However, most of these diagnosis can either be diagnosed or ruled out by blood tests and simple additional imaging, such as an ultrasound. When these diagnoses are ruled out, rare diagnoses such as herniation of the bowel should be considered.

In earlier reports, 90% of the cases has been diagnosed intra-operatively [11]. However, as computed tomography becomes the routine diagnostic work up, herniation of the bowel will more often be detected pre-operatively. A search of all cases described over the past 5 years identified 21 cases (Table 1 [12–31]) of intestinal herniation through the foramen of Winslow reported over the last 5 years. Only 3 cases (14%) were diagnosed intra-operatively. In all other cases, the diagnosis was known prior to surgery, using computed tomography in all but 1 case, where magnetic resonance imaging was used in a pregnant patient. On contrast enhanced CT scans, dilated right colon coursing posteriorly to the hepatoduodenal ligament combined with the a lateral displacement of the stomach is described as typical for the diagnosis of herniation through the foramen of Winslow [2].

In 2011, van Daele et al. [31] reported the first laparoscopic management of herniation through the foramen of Winslow. Since then, 8 other cases have been described in which a laparoscopic approach was safe and feasible, even if bowel resection was necessary. Therefore it is recommended to always start laparoscopically in case of the pre-operative diagnosis of bowel herniation through the foramen of Winslow.

As mentioned earlier, most cases describe a herniation of small bowel loops (63%), the caecum and ascending colon (30%) or the transverse colon (7%) [1], while there are cases describing herniation of the gall bladder [3], a small bowel diverticulum [5] or a Meckel's diverticulum [6]. This compares well to our current literature overview, showing herniation of mostly small bowel loops (67%) although often combined with herniation of the caecum or ascending colon (63%). The authors found 1 case describing herniation of the transverse colon in the past years [29]. In all cases described, patients were discharged in good health soon after surgery, resulting in a mortality rate of 0%. In the present case, the patient was discharged early and in good health. So far, no recurrences have occurred, even though the foramen was not closed, because of the high risk of iatrogenic injury to the bile ducts, portal veins and hepatic artery. In addition, inflammatory post-operative adhesions may obliterate the foramen, preventing the need of further surgical closure. In current literature, there is no consensus on trying to prevent recurrent herniations by foramen closure, cae-

Table 1
Overview of current literature.

Article	Herniated bowel	Time of diagnosis	Surgery	Decompression	Bowel resection	Prevention of recurrence
Daher et al. [12]	Terminal ileum, caecum, appendix	P	LS	Yes	No	Caecopexy
Garg et al. [13]	Terminal ileum, caecum, appendix	P	LS	No	No	Foramen closure, appendectomy, caecopexy
Nazarian et al. [14]	Terminal ileum	I	LT	No	Terminal ileum resection	No
Ozsoy et al. [15]	Terminal ileum, caecum	I	LT	No	Terminal ileum resection	Right colonic fixation
Makarawo et al. [16]	Caecum	P	LT	No	No	Caecopexy
Harnsberger et al. [17]	Terminal ileum, caecum	P	LS	Yes	Right hemicolectomy	Foramen closure
Sikiminywa-Kambale et al. [18]	Caecum and ascending colon	P	LT	No	Right hemicolectomy	No
Ryan et al. [19]	Right colon	P	LS	No	No	No
May et al. [20]	Small intestine	P	LS	No	No	Foramen closure
Puig et al. [21]	Terminal ileum, caecum and right colon	P	LT	No	Right hemicolectomy	No
Lin et al. [22]	Terminal ileum	P	LS	No	No	No
Yamashiro et al. [23]	Ileum	P	LS	No	Ileum resection	No
Huang et al. [24]	Terminal ileum	P	LT	No	Ileum resection	No
Patel et al. [25]	Terminal ileum, caecum	P	LT	No	No	Foramen closure, caecum and small bowel fixation
Adachi et al. [26]	Ileum	P	LT	No	No	Foramen closure
Powel-Brett et al. [27]	Caecum	I	LT	Yes	Right hemicolectomy	No
Gonzalez Conde et al. #1 [28]	Mid-ileum	P	LT	No	No	Interposing the colon hepatic flexure in the foramen
Gonzalez Conde et al. #2 [28]	Terminal ileum, caecum, appendix, ascending colon	P	LT	No	No	Right colonic fixation
Clough et al. [29]	Transverse colon	P	LS	No	No	No
MacDonald et al. [30]	Caecum, appendix, ascending and proximal transverse colon	P	LT	No	No	Foramen closure
v Daele et al. [31]	Caecum, right colon	P	LS	No	No	No

P: pre-operatively, I: intra-operatively; LS: laparoscopy, LT: laparotomy.

copy or sometimes even bowel resection as is seen in Table 1 as well. However, no recurrences have been reported either.

4. Conclusion

Herniation through the foramen of Winslow is a rare condition. Patients will present with sudden onset abdominal pain. Early imaging helps to recognize the diagnosis and could prevent bowel ischemia.

Conflict of interest

The authors have no conflicts of interest to disclose.

Funding

There was no funding for this research.

Ethical approval

For a case reports, no official approval of the ethics committee is required. The patient did give informed consent for writing the case report.

Consent

Informed consent was obtained from the patient for publication of this case report and accompanying images. A copy of the written consent is available for review by the Editor-in-Chief of this journal on request.

Author contribution

L.E. Duinhouwer: was involved in patient care and wrote the first version of the manuscript.

E. Deerenberg: was involved in patient care and contributed to writing the manuscript.

E. Rociu: was involved in patient care and contributed to writing the manuscript.

R.T.J. Kortekaas: was involved in patient care and contributed to writing the manuscript.

All author approve the last version of the manuscript.

Guarantor

L.E. Duinhouwer and R.T.J. Kortekaas

References

- [1] A.B. Osvaldt, D.F. Mossman, V.P. Bersch, L. Rohde, Intestinal obstruction caused by a foramen of Winslow hernia, *Am. J. Surg.* 196 (August (2)) (2008) 242–244.
- [2] L.C. Martin, E.M. Merkle, W.M. Thompson, Review of internal hernias: radiographic and clinical findings, *AJR Am. J. Roentgenol.* 186 (March (3)) (2006) 703–717.
- [3] C.A. Mc, Herniation of the gallbladder through the foramen of Winslow, *Br. J. Surg.* 38 (January (151)) (1951) 386–387.
- [4] K. Numata, Y. Kunishi, Y. Kurakami, K. Tsuchida, T. Yoshida, T. Osaragi, et al., Gallbladder herniation into the lesser sac through the foramen of Winslow: report of a case, *Surg. Today* 43 (October (10)) (2013) 1194–1198.
- [5] P.A. Roberts, Hernia through the foramen of Winslow, *Guys Hosp. Rep.* 102 (3) (1953) 253–264.
- [6] T.H. Cullen, Herniation of an acutely inflamed Meckel's diverticulum through the foramen of Winslow, *Arch. Midx. Hosp.* 4 (October (4)) (1954) 278–279.
- [7] T.L. Tran, P.C. Pitt, Hernia through the foramen of Winslow: a report of two cases with emphasis on plain film interpretation, *Clin. Radiol.* 40 (May (3)) (1989) 264–266.
- [8] D. Selcuk, F. Kantarci, G. Ogut, U. Korman, Radiological evaluation of internal abdominal hernias, *Turk. J. Gastroenterol.* 16 (June (2)) (2005) 57–64.
- [9] S.S. Forbes, W.J. Stephen, Herniation through the foramen of Winslow: radiographic and intraoperative findings, *Can. J. Surg.* 49 (October (5)) (2006) 362–363.
- [10] H. Gray, *Anatomy of the Human Body*, Barthleby.com, New York, USA, 1918.
- [11] B.D. Newsom, J.S. Kukora, Congenital and acquired internal hernias: unusual causes of small bowel obstruction, *Am. J. Surg.* 152 (September (3)) (1986) 279–285.
- [12] R. Daher, L. Montana, J. Abdullah, A. d'Alessandro, E. Chouillard, Laparoscopic management of foramen of Winslow incarcerated hernia, *Surg. Case Rep.* 2 (December (1)) (2016) 9.
- [13] S. Garg, G. Flumeri-Perez, S. Perveen, G. DeNoto, Laparoscopic repair of foramen of Winslow hernia, *Int. J. Angiol.* 25 (March (1)) (2016) 64–67.
- [14] S. Nazarian, D. Clegg, S. Chang, J. Kuriakose, Difficult diagnosis: internal herniation of the terminal ileum through the foramen of Winslow into the lesser sac, *BMJ Case Rep.* 2015 (2015).
- [15] M. Ozsoy, T. Ozkececi, M. Akici, M. Kalkan, A. Katirag, S. Yilmaz, Internal herniation through the foramen of Winslow: a rare cause of bowel obstruction, *ANZ J. Surg.* (April) (2015).
- [16] T. Makarawo, F.I. Macedo, M.J. Jacobs, Cecal bascule herniation into the lesser sac, *World J. Clin. Cases* 2 (December (12)) (2014) 903–906.
- [17] C.R. Harnsberger, E.C. McLemore, R.C. Broderick, H.F. Fuchs, P.T. Yu, M. Berducci, et al., Foramen of Winslow hernia: a minimally invasive approach, *Surg. Endosc.* 29 (August (8)) (2015) 2385–2388.
- [18] P. Sikiminywa-Kambale, A. Anaye, D. Roulet, E. Pezzetta, Internal hernia through the foramen of Winslow: a diagnosis to consider in moderate epigastric pain, *J. Surg. Case Rep.* 2014 (6) (2014).
- [19] J. Ryan, S. Jin, J. Frank, R. Jacobs, Internal herniation of the caecum through the foramen of Winslow, *ANZ J. Surg.* 84 (1–2) (2014) 95–96, Jan–Feb.
- [20] A. May, N. Cazeneuve, C. Bourbao-Tournois, Acute small bowel obstruction due to internal herniation through the Foramen of Winslow: CT diagnosis and laparoscopic treatment, *J. Visc. Surg.* 150 (November (5)) (2013) 349–351.
- [21] C.A. Puig, J.B. Lillegard, J.E. Fisher, H.J. Schiller, Hernia of cecum and ascending colon through the foramen of Winslow, *Int. J. Surg. Case Rep.* 4 (10) (2013) 879–881.
- [22] W.C. Lin, C.H. Lin, Y.P. Lo, Y.H. Liao, Rapid pre-operative diagnosis of ileal hernia through the foramen of Winslow with multi-detector computed tomography, enabling successful laparoscopic reduction, *S. Afr. J. Surg.* 51 (February (1)) (2013) 35–37.
- [23] T. Yamashiro, H. Ikeda, A. Fujikawa, K. Hashimoto, T. Morimoto, K. Miyakawa, et al., Internal hernia through the foramen of Winslow: the narrowed portal vein sign on abdominal CT, *Emerg. Radiol.* 20 (June (3)) (2013) 247–250.
- [24] W.C. Huang, C.Y. Fu, Images in clinical medicine. Hernia through the foramen of Winslow, *N. Engl. J. Med.* 367 (August (5)) (2012) e7.
- [25] V. Patel, R. Newton, S. Wakely, K. Rajaratnam, S. Ramesh, Caecal herniation through the foramen of Winslow: a rare cause of bowel obstruction, *Updates Surg.* 65 (3) (2013 Sep) 241–244.
- [26] K. Adachi, S. Yokoro, Image of the month: internal hernia through foramen of Winslow, *Arch. Surg.* 147 (3) (2012 Mar) 293–294.
- [27] S.F. Powell-Brett, J.T. Royle, T. Stone, R.G. Clarke, Caecum herniation through the Foramen of Winslow, *J. Surg. Case Rep.* 2012 (12) (2012).
- [28] R. Gonzalez Conde, P. Pardo Rojas, E. Valeiras Dominguez, C. Perez Lopez, R. Santos Lloves, F.J. Gomez Lorenzo, Correct preoperative diagnosis of herniation through the Foramen of Winslow: two case reports, *Hernia* 17 (3) (2013 Jun) 409–414.
- [29] A.D. Clough, G.S. Smith, S. Leibman, Laparoscopic reduction of an internal hernia of transverse colon through the foramen of Winslow, *Surg. Laparosc. Endosc. Percutan. Tech.* 21 (August (4)) (2011) e190–1.
- [30] K. MacDonald, S. Hayward, M. Nixon, A. Holbrook, Internal herniation through the foramen of Winslow during pregnancy: mR findings [corrected], *Abdom. Imaging* 36 (June (3)) (2011) 318–320.
- [31] E. Van Daele, M. Poortmans, T. Vierendeels, P. Potvlieghe, W. Rots, Herniation through the foramen of Winslow: a laparoscopic approach, *Hernia* 15 (August (4)) (2011) 447–449.

Open Access

This article is published Open Access at sciendo.com. It is distributed under the IJSCR Supplemental terms and conditions, which permits unrestricted non commercial use, distribution, and reproduction in any medium, provided the original authors and source are credited.