

# Rare case of EBV-induced colitis in an immunocompetent individual

Catherine Choi ,<sup>1</sup> Qi Yu,<sup>2</sup> Pratik Q Deb,<sup>3</sup> Weizheng Wang<sup>2</sup>

**To cite:** Choi C, Yu Q, Deb PQ, *et al.* Rare case of EBV-induced colitis in an immunocompetent individual. *BMJ Open Gastro* 2020;**7**:e000360. doi:10.1136/bmjgast-2019-000360

Received 14 January 2020

Revised 12 February 2020

Accepted 17 February 2020

## SUMMARY

Epstein-Barr virus (EBV) is a member of the herpes virus family and affects people worldwide. EBV-infected colitis can occur in patients in immunocompromised states. However, EBV-induced colitis in immunocompetent patients is extremely rare. A 34-year-old man with a prior history of possible intussusception, and who underwent a right hemicolectomy, presented with abdominal pain and rectal bleeding. Laboratory investigations were unremarkable, and the patient underwent a colonoscopy, which showed EBV-infected colitis. Both infectious and inflammatory bowel disease (IBD) workups were negative. The patient's symptoms were resolved with supportive therapy. A repeat colonoscopy showed normal colonic mucosa with an absence of EBV infection. Without evidence of IBD or infectious aetiologies, EBV-associated colitis is a rare finding in an immunocompetent patient.

## BACKGROUND

Epstein-Barr virus (EBV) is a member of the herpes virus family and affects patients worldwide.<sup>1</sup> While more than 90% of adults have been infected with EBV over the course of their lives, they remain asymptomatic, and most primary infections occur in infants and children.<sup>2</sup> As manifestations of EBV in the gastrointestinal tract almost always occur in states of immunodeficiency, EBV-induced colitis in immunocompetent individuals is extremely rare. Furthermore, previous reports of colonic infection by EBV in immunocompetent patients have been often associated with inflammatory bowel disease (IBD). The development of EBV-associated lymphoproliferative disorder (LPD) has even been known to occur in severely immunodeficient states, such as in those with congenital or acquired cellular immunodeficiencies.<sup>2</sup> Patients with EBV-associated LPD display symptoms of infectious mononucleosis for a minimum of 3 months, including fever, hepatosplenomegaly, lymphadenopathy, liver dysfunction and a high load of serum viral EBV-DNA.<sup>3</sup> Here, we report a case of a young, healthy, incarcerated man who developed EBV-induced colitis without any signs of IBD.

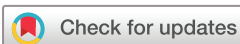## CASE PRESENTATION

A 34-year-old man, with a history of possible intussusception and a patient-reported right hemicolectomy, presented to the emergency department for abdominal pain and rectal bleeding. The patient reported having epigastric pain for 2 days, which was constant, sharp, and became intermittently worse. The pain occurred in 15 min episodes before self-resolving. The patient described the pain as 'pinch and pull at times'. He noticed maroon-coloured blood in his stool on the day of presentation. He had undergone abdominal surgery in 2014 for reasons which he could not recall, and also experienced similar pain in 2017, which he referred to as having been 'intussusception'. The review of systems was significant for 15-pound weight loss in 1 month, epigastric pain, rectal bleeding, and decreased appetite. The remainder of the review of systems was negative. On physical examination, the patient was in no acute distress and had generalised abdominal tenderness without rigidity or guarding.

## INVESTIGATIONS

Laboratory studies showed unremarkable complete blood count, basic metabolic panel, and liver function tests. An HIV screen from the initial presentation was negative. CT imaging of the abdomen showed mural thickening of the distal transverse colon. With a history of weight loss, as well as the observations of mural thickening in the distal transverse colon from imaging, the decision was made to proceed with a colonoscopy to determine the aetiology of the abdominal pain and rectal bleeding. The initial differential diagnosis was focused on infectious, inflammatory, or neoplastic origins.

A colonoscopy showed areas of colitis, which was worse on the right side compared with the left. The colitis was non-continuous, with scattered erosions, demonstrated in [figure 1](#). A biopsy of the right colon showed active chronic colitis. A lymphocyte stain was positive for EBV. An EBV infection was



© Author(s) (or their employer(s)) 2020. Re-use permitted under CC BY-NC. No commercial re-use. See rights and permissions. Published by BMJ.

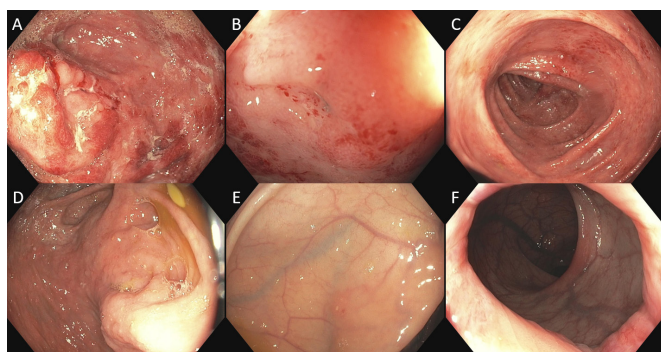
<sup>1</sup>Department of Medicine, Rutgers New Jersey Medical School, Newark, New Jersey, USA

<sup>2</sup>Gastroenterology and Hepatology Division, Department of Medicine, Rutgers New Jersey Medical School, Newark, New Jersey, USA

<sup>3</sup>Department of Pathology, Immunology & Laboratory Medicine, Rutgers New Jersey Medical School, Newark, New Jersey, USA

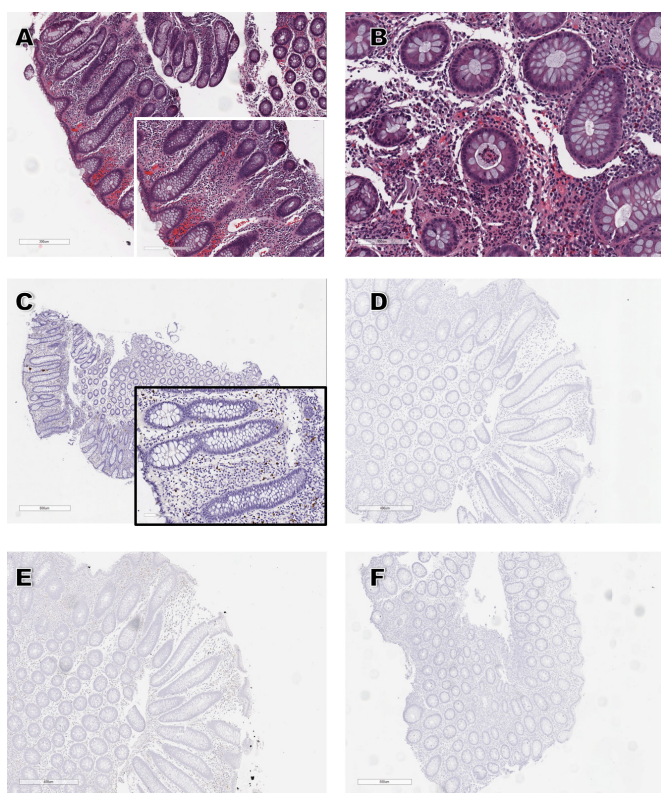
## Correspondence to

Dr Weizheng Wang;  
wangww@njms.rutgers.edu



**Figure 1** Colonoscopy images showing areas of non-continuous colitis with scattered erosions. (A) Colitis of cecum, (B) non-continuous colitis, (C) colitis of transverse colon, (D–F) repeat colonoscopy images showing the resolution of previous colitis in the 3-month follow-up.

detected in the biopsy sample of left colon by in situ hybridisation for Epstein-Barr virus-encoded small RNAs. Immunohistochemistry was negative for herpes simplex type 1 and 2, and cytomegalovirus (CMV). The histology and



**Figure 2** (A) Photomicrograph showing colonic mucosa with lymphocytic infiltration (H&E, 100X); inset showing the predominance of lymphocytes, neutrophils, and plasma cells in the lamina propria. (B) Photomicrograph showing colonic mucosa with neutrophilic cryptitis in the background of the preserved crypt architecture that is characteristic of infectious colitis (H&E, 400X). (C) Photomicrograph showing Epstein-Barr virus-infected cells in the lamina propria (chromogenic in situ hybridisation, 100X). (D, E, F) Photomicrographs showing no infection with (D) HSV1, (E) HSV2, (F) CMV (immunohistochemistry, 100X). CMV, cytomegalovirus; HSV, herpes simplex virus.

immunochemistry are further demonstrated in [figure 2](#). Notably, the antibody profile of serologic EBV was not tested. An informed consent was obtained from the patient for the case report.

## TREATMENT

A proton pump inhibitor was administered daily. The patient was started on ciprofloxacin and metronidazole two times per day for 5 days and was advised to avoid non-steroidal anti-inflammatory drugs.

## OUTCOME AND FOLLOW-UP

During the 3-month follow-up visit, the patient reported a significant improvement in abdominal pain. However, he was still experiencing persistent watery stools, without blood or mucus. A repeat colonoscopy with colon biopsies showed no evidence of EBV or CMV, as confirmed by immunohistochemistry.

## DISCUSSION

EBV is one of eight known viruses of the herpes virus family and is one of the most common viruses that affects the human population worldwide.<sup>1</sup> EBV infection is acquired early in life and carriers often remain asymptomatic. Many conditions can disturb the delicate EBV-host balance, and thereby cause the pathogenic manifestation of a latent EBV infection by transforming the balance from a latent to an active state of infection.<sup>4</sup> Patients in immunosuppressed or chronic inflammatory states, such as those taking immunosuppressant medications or patients with IBD, are at risk for developing EBV-induced colitis. Patients with IBD are at particular risk, as they have chronically inflamed colonic mucosa and often take immunosuppressant medications to control their disease. A study by Ryan *et al*<sup>5</sup> compared EBV viral load in patients with normal gastric and colonic mucosa to those with IBD, and showed that EBV DNA levels are proportionally elevated in inflamed gastrointestinal mucosa compared with normal mucosa. However, the actual role of EBV infection in the pathophysiology and the course of IBD still remain unclear.<sup>4</sup> While the observed increase in EBV viral load and the higher number of infiltrating B lymphocytes present in inflamed gastric and colonic mucosa in IBD patients may suggest EBV as a mere bystander, it may also suggest that EBV plays a role in the pathogenesis of gastritis and colitis by dysregulating immune response.<sup>4 5</sup> In addition, microscopic colitis (MC) is also present in inflammatory gut disorders, and EBV infection is almost always detectable in the colonic biopsies of patients with MC, as demonstrated by Rizzo *et al*.<sup>4</sup> Although further studies are warranted to clarify the role of EBV in inflammatory gut disorders, it has been proposed that EBV may induce immune alterations in the colon, and therefore plays a potential role in the pathogenesis of these diseases.<sup>5</sup>

The molecular detection of EBV-encoded RNA transcripts by in situ hybridisation remains the gold standard in the identification of EBV in biopsies.<sup>6 7</sup> However,

the identification of EBV in a colonic biopsy does not always indicate that EBV infection plays a pathological role. Therefore, it is important to distinguish the infectious status of EBV (ie, whether the virus is in the lytic or latent phase of its life cycle). In our patient, we were not sure if his signs and symptoms were EBV-related because EBV could have been in the latent phase and not have pathological roles in colitis. In addition, the antibody profile of serologic EBV was not tested. However, there were no endoscopic signs of IBD or other evidences of an immunocompromised state, and the subsequent colonic biopsy from repeat colonoscopy showed no evidence of EBV infection after the resolution of his signs and symptoms. Therefore, we made a presumed diagnosis of EBV-induced colitis. In his follow-up, the patient remained disease-free, and has since remained in a healthy state.

The presenting symptoms of this patient were diarrhoea and rectal bleeding. As IBD can manifest with similar signs and symptoms, IBD was thus initially suspected in this particular patient with EBV-induced colitis. With the higher prevalence of EBV colitis in immunosuppressed patients, EBV-induced colitis can be the first indication of IBD or an immunosuppressed state. In patients with IBD who fail to respond to standard IBD therapy, superimposed or simultaneous infections should be considered, especially when starting immunomodulators.<sup>1</sup>

While there have been previous case reports of EBV-induced colitis in immunocompetent patients, in most cases, these were the result of superimposed infections in the setting of IBD. Notably, there was a recent case report of a 61-year-old woman with EBV-induced colitis, which manifested as haemorrhage.<sup>8</sup> This particular patient did not have immunosuppressive conditions, but he had completed a high dose of corticosteroid course; he was thought to be in a relatively immunocompetent state.<sup>8</sup> Thus, this is an extremely rare case of EBV-induced colitis in a young, immunocompetent man who developed EBV-induced colitis while incarcerated, and which resolved after supportive care. Infectious and IBD workups were negative, and a repeat colonoscopy showed normal

colonic mucosa with an absence of EBV infection. Therefore, this is thought to be a case of localised EBV-induced colitis, which responded to supportive therapy.

**Contributors** CC reviewed the literature and wrote the manuscript. QY edited the manuscript. WW designed the manuscript. PD provided the pathology slides and annotated the figures.

**Funding** The authors have not declared a specific grant for this research from any funding agency in the public, commercial or not-for-profit sectors.

**Competing interests** None declared.

**Patient consent for publication** Obtained.

**Provenance and peer review** Not commissioned; externally peer reviewed.

**Data availability statement** Data sharing not applicable as no data sets generated and/or analysed for this study. No data are available. None.

**Open access** This is an open access article distributed in accordance with the Creative Commons Attribution Non Commercial (CC BY-NC 4.0) license, which permits others to distribute, remix, adapt, build upon this work non-commercially, and license their derivative works on different terms, provided the original work is properly cited, appropriate credit is given, any changes made indicated, and the use is non-commercial. See: <http://creativecommons.org/licenses/by-nc/4.0/>.

#### ORCID iD

Catherine Choi <http://orcid.org/0000-0003-4310-8575>

#### REFERENCES

- 1 Afzal M, Nigam GB. Ebv colitis with ulcerative colitis: a double whammy. *BMJ Case Rep* 2018;2018. doi:10.1136/bcr-2018-224963. [Epub ahead of print: 29 Jun 2018].
- 2 Karlitz JJ, Li ST, Holman RP, et al. Ebv-Associated colitis mimicking IBD in an immunocompetent individual. *Nat Rev Gastroenterol Hepatol* 2011;8:50–4.
- 3 Zheng X, Xie J, Zhou X. Epstein-Barr virus associated T-cell lymphoproliferative disease misdiagnosed as ulcerative colitis: a case report. *Int J Clin Exp Pathol* 2015;8:8598–602.
- 4 Rizzo AG, Orlando A, Gallo E, et al. Is Epstein-Barr virus infection associated with the pathogenesis of microscopic colitis? *J Clin Virol* 2017;97:1–3.
- 5 Ryan JL, Shen Y-J, Morgan DR, et al. Epstein-Barr virus infection is common in inflamed gastrointestinal mucosa. *Dig Dis Sci* 2012;57:1887–98.
- 6 Nissen LHC, Nagtegaal ID, de Jong DJ, et al. Epstein-Barr virus in inflammatory bowel disease: the spectrum of intestinal lymphoproliferative disorders. *J Crohns Colitis* 2015;9:398–403.
- 7 Bertalot G, Villanacci V, Gramegna M, et al. Evidence of Epstein-Barr virus infection in ulcerative colitis. *Dig Liver Dis* 2001;33:551–8.
- 8 Denicola RP, Coben R, Katz L, et al. Acute gastrointestinal hemorrhage due to Epstein-Barr virus colitis. *ACG Case Rep J* 2019;6:e00238.