

## Original Article

# Immunological Analysis of Vestibular Schwannoma Patients

Oleg Borysenko<sup>1</sup> , Oleg Melnykov<sup>2</sup> , Alexandra Prilutskaya<sup>3</sup> , Marin Buracovschi<sup>4</sup> <sup>1</sup>Department of Ear Microsurgery and Otoneurosurgery, Institute of Otolaryngology, Kiev, Ukraine<sup>2</sup>Department of Pathophysiology and Immunology, Institute of Otolaryngology, Kiev, Ukraine<sup>3</sup>Department of Pathophysiology and Immunology, Institute of Otolaryngology, Kiev, Ukraine<sup>4</sup>Department of Otorhinolaryngology, State University of Medicine and Pharmacy "Nicolae Testemițanu", Chisinau, Republic of Moldova

ORCID IDs of the authors: O.B. 0000-0003-0125-2990, O.M. 0000-0002-1261-8647, A.P. 0000-0002-8415-575X, M.B. 0000-0001-8939-5886.

Cite this article as: Borysenko O, Melnykov O, Prilutskaya A, Buracovschi M. Immunological analysis of vestibular schwannoma patients. *J Int Adv Otol.* 2023;19(1):1-4.

**BACKGROUND:** Vestibular schwannoma is a benign intracranial tumor of the vestibulocochlear nerve. Although it is a well-known pathology, growth factors and cytokine changes in vestibular schwannoma patients have not been totally elucidated. The objective of our study was to evaluate the concentration changes of transforming growth factor beta1, vascular endothelial growth factor, immunoglobulins A, M, and carcinoembryonic antigen in vestibular schwannoma patients.

**METHODS:** In our study, we performed an immunological analysis of 35 patients with vestibular schwannoma of different stages. According to the evolution of vestibular schwannoma, 20 patients did not show tumor growth, but 15 patients had a growing tumor.

**RESULTS:** The level of vascular endothelial growth factor in the blood serum of study groups exceeded the control values by 8 times and transforming growth factor beta1 by 1.65. Increased values of immunoglobulin A and immunoglobulin M were observed in patients with intracanal, second, and third stages of tumor, compared with the control group. Carcinoembryonic antigen was found to be of increased values in patients with intracanal and third-stage vestibular schwannoma, in comparison to the control group.

**CONCLUSION:** Growth factors such as vascular endothelial growth factor and transforming growth factor beta1 can play a significant role in the genesis of vestibular schwannoma. In vestibular schwannoma patients, their investigation is appropriate both in the process of monitoring and in the assessment of treatment effectiveness. Immunoglobulins M and A can be used as additional markers of vestibular schwannoma, especially in tumor growth. Carcinogenic embryonic antigen has high values only in the late stages of vestibular schwannoma development.

**KEYWORDS:** Carcinoembryonic antigen, immunoglobulin A, immunoglobulin M, transforming growth factor beta1, vascular endothelial growth factor, vestibular schwannoma

## INTRODUCTION

Acoustic neuroma or vestibular schwannoma (VS) is a benign intracranial tumor of the vestibulocochlear nerve. There are 2 types of VS: unilateral sporadic VS that constitutes 95% of all VSs, and VS associated with neurofibromatosis type 2, a dominantly inherited disorder.<sup>1</sup> Vestibular schwannoma evolves through an abnormal growth and hyperproliferation of Schwann cells along the vestibulocochlear nerve that leads to the compression and displacement of surrounding neural tissues, ultimately affecting vital midbrain structures. It represents 8%-10% of all intracranial tumors and 75%-80% of neoplasms localized in the cerebellopontine angle.<sup>2</sup> The evolution and proliferation mechanisms of VS have not been totally elucidated so far, being tumors that show continuous growth, followed by stagnation or even regression.<sup>3</sup> According to pathogenesis, VS develops as a result of various mutations in the NF2 gene (neurofibromin 2) located on chromosome 22q12.2. This gene encodes a protein called merlin or schwannomin, which in its active state acts as a tumor suppressor gene.<sup>4</sup> Merlin inhibits cell growth and proliferation by acting on several cell compartments. In VS, the inactivation of merlin disrupts the mechanisms of nerve fiber regeneration, resulting in the activation of a number of cytokines and growth factors that promote cell proliferation.<sup>4-6</sup> Cytokines act as regulators of immune responses and inflammation and are produced by a wide range of cells, including immune cells, endothelial cells, fibroblasts, and other stromal cells.<sup>7</sup> Cytokines that are involved in cell proliferation/differentiation signaling processes are considered growth factors.<sup>8</sup> One of the

growth factors that play an important role in the evolution of VS is the vascular endothelial growth factor (VEGF). Vascular endothelial growth factor contributes to VS growth by inducing angiogenesis through endothelial cell proliferation and migration as a result of binding to high-affinity receptors VEGFR-1 and VEGFR-2 located on vascular endothelial cells.<sup>6</sup> Another growth factor that is involved in VS growth is the transforming growth factor  $\beta$ 1 (TGF- $\beta$ 1). It causes cell proliferation as a result of binding to the receptors TGF- $\beta$ R1 and TGF- $\beta$ R2. It has been elucidated that these factors have a high concentration in VS tumors.<sup>9</sup> Other cytokines like immunoglobulins and carcinoembryonic antigen (CEA) also have high values in VS.<sup>9-12</sup>

The objective of our study was to evaluate the blood concentration changes of VEGF in association with TGF- $\beta$ 1 and changes of immunoglobulins A, M, and CEA in patients with different stages of VS.

**METHODS**

A total of 35 adult patients with sporadic VS were included in the study between 2018 and 2020. The group of patients consisted of 13 women and 22 men aged between 21 and 70 years (mean age 51.6 years). Patients with neurofibromatosis type 2 or with any other additional tumors were excluded from the study. In order to evaluate VS proliferation by the levels of TGF- $\beta$ 1, VEGF, CEA, and IgA with IgM, patients were divided into 2 groups: a group with signs of tumor growth and another group in which VS did not grow. The criteria for tumor growth were supported by the results of magnetic resonance imaging that showed an enlargement of tumors of 1 mm in 2 dimensions or 2 mm in 1 dimension during a period of 6 months. The monitoring period of patients started from at least 6 months up to 2 years. Tumor growth was determined by 2 experienced radiologists, blinded to each other’s magnetic resonance assessments and clinical information. According to House classification, in no growth tumor group, most of tumors were intracanalicular and of the first stage (7 patients with intracanalicular VS, 10 patients with first stage VS, and 3 patients with second stage VS), but in growth tumor group, most of tumors were of the first and second stage (4 patients with intracanalicular VS, 5 patients with first stage VS, 5 patients with second stage VS, and 1 patient with third stage VS). Patients were divided into 4 groups according to the stage of VS. A total of 10 healthy patients formed the control group. The current study was performed with the consent of the Institutional Ethics Committee Approval (protocol no. 18/21-1).

**Immunological Analysis**

Blood was collected in the morning from a peripheral vein. It was collected on an empty stomach in order not to influence in any way the cytokine level. Serum obtained by centrifugation was kept for up to

3 months in 1.5 mL Eppendorf tubes under a temperature of  $-25^{\circ}\text{C}$  in a freezer (Indesit, Italy). Blood serum with hemolysis was not examined. The concentration of TGF- $\beta$ 1 and VEGF in the serum of VS patients was determined by enzyme-linked immunosorbent assay (ELISA) using Euroimmun (Austria) and DRG (Germany) reagent kits. Carcinoembryonic antigen was determined by ELISA using CanAg reagent kits (Sweden). Immunoglobulins A and M were determined using the abovementioned analyzer on sets of reagents OOO «Хема медика» (Russian Federation). The Stat Fax 2100 reader (USA) was used as an analyzer.

**Statistical Analysis**

Paired Student's *t*-test was used to assess the differences between the control and study group with a *P* value  $< .05$  and  $< .001$  as the level of statistical significance. Statistical data processing was performed using statistical software program version 6.0 (Primer of Biostatistics—sixth edition, Stanton A. Glantz, McGraw-Hill Companies, Calif, USA).

**RESULTS**

Table 1 shows TGF- $\beta$ 1 and VEGF values. According to the data in the table, a high degree of reliability ( $P < .001$ ) in the study of these 2 growth factors was obtained as a result of a mixed group evaluation (all stages of tumor growth) relative to control. The level of VEGF in the serum exceeded the control values by 8 times and TGF- $\beta$ 1 by 1.65. During the study of these indicators according to clinical stages, no significant changes were observed, except for values obtained from the third stage group when determining the level of VEGF ( $P < .05$ ), although a tendency for elevated concentration of TGF- $\beta$ 1 and VEGF was found in almost every group.

The concentration of growth factors in patients from the growth tumor group in comparison to the no growth tumor group revealed the fact that only the level of TGF- $\beta$ 1 was significantly ( $P < .05$ ) higher in the tumor growth group than in the no tumor growth group (Figure 1).

The obtained data about the concentration of IgM and IgA in the serum of patients with VS are presented in Table 2. The data in the table show that significant ( $P < .001$ ) changes in IgM concentration were observed in groups of patients with intracanalicular, second, and third-stage tumors in comparison with the control group.

The CEA levels in the represented groups are shown in Figure 2. The aforementioned data demonstrate that, despite a

**Table 1.** Serum Concentration of Growth Factors TGF- $\beta$ 1 and VEGF in Different Stages of VS in Comparison to the Control Group

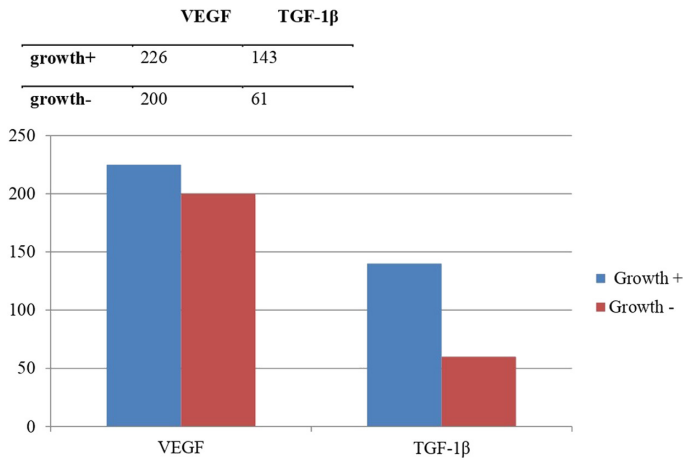
Groups	Number of Cases	VEGF, pg/mL	TGF- $\beta$ 1, ng/mL
Control	10	26.6 $\pm$ 3.8	80.6 $\pm$ 7.0
Intracanalicular	11	253.9 $\pm$ 29.3**	47.9 $\pm$ 10.2*
Stage I	10	138.0 $\pm$ 35.5	132.2 $\pm$ 20.5
Stage II	8	165.5 $\pm$ 16.3**	111.5 $\pm$ 12.8
Stage III	6	190.0 $\pm$ 28**	97.5 $\pm$ 25.5

TGF- $\beta$ 1, transforming growth factor beta1; VEGF, vascular endothelial growth factor; VS, vestibular schwannoma.

\* $P < .05$ ; \*\* $P < .001$  (before control).

**MAIN POINTS**

- High serum levels of vascular endothelial growth factor and transforming growth factor beta1 (TGF- $\beta$ 1) can be indicative of vestibular schwannoma (VS).
- High serum levels of TGF- $\beta$ 1 may serve as a factor predicting the growth of VS.
- Immunoglobulins M and A may serve as additional indicators of the presence of VS.



**Figure 1.** Level of growth factors in the tumor growth group vs. the no tumor growth group.

**Table 2.** Serum Concentration of IgM and IgA in Different Stages of VS in Comparison to the Control Group

Groups	Number of Cases	IgM, g/L	IgA, g/L
Control	10	1.5 ± 0.15	1.8 ± 0.2
Intracanalicular	11	2.4 ± 0.2**	2.9 ± 0.3*
Stage I	10	2.1 ± 0.3	2.2 ± 0.15
Stage II	8	2.5 ± 0.3**	1.65 ± 0.5
Stage III	6	2.6 ± 0.3*	2.9 ± 0.4*

IgA, immunoglobulin A; IgM, immunoglobulin M; VS, vestibular schwannoma. \* $P < .05$ ; \*\* $P < .001$  (before control).

consistent propensity for high CEA concentration at practically all stages of VS, significant deviations in the serum concentration of CEA in the serum of patients with VS were not seen in comparison to the control group.

**DISCUSSION**

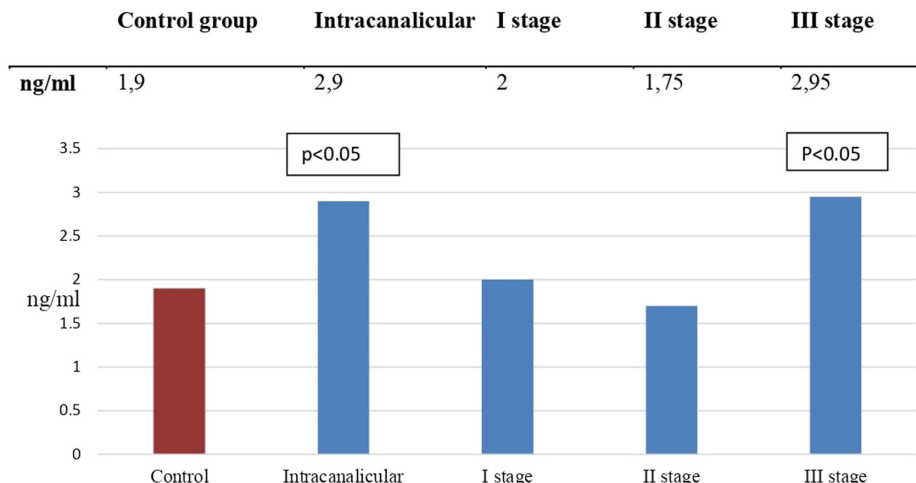
Cytokines and growth factors play an important role in the evolution of VS. Vascular endothelial growth factor is one of the growth factors that has a significant high expression in neoplasms of the nervous system and has a major impact on tumor angiogenesis and progression by inducing migration and proliferation of endothelial cell.<sup>13,14</sup>

Cayé-Thomasen et al.<sup>15</sup> after studying VSs of 18 operated patients, found out that VEGF levels in VS patients positively correlate with tumor growth rate, which is supposed to be involved in VS proliferation. Koutsimpelas et al.<sup>16</sup> after studying surgical specimens of 17 patients with sporadic VS, determined that VEGF and bFGF (basic fibroblast growth factor) expression in VS correlates with tumor volume. Also Koutsimpelas et al.<sup>17</sup> after performing a tissue microarray analysis of 182 operated VSs, found significantly higher VEGF levels in recurrent tumors and preoperatively irradiated tumors, a fact that proves the crucial role of VEGF in VS growth. Dilwali et al.<sup>18</sup> determined that VEGF and HGF (hepatocyte growth factor) levels in VS were significantly higher than in healthy nerve tissues. Zhang et al.<sup>19</sup> pointed out that anti-VEGF treatment with anti-VEGF antibody bevacizumab in association with radiotherapy or immunotherapy with VEGF receptor peptide vaccination in neurofibromatosis type 2 improved VS results. Tamura et al.<sup>20</sup> came to the same conclusion, after studying the treatment results with bevacizumab of 7 patients with progressive schwannomas.

Transforming growth factor beta1, another growth factor that is a multifunctional regulatory protein, has several pleiotropic functions in various tissues.<sup>21</sup> According to Bizzarri et al.<sup>22</sup> the release of TGF- $\beta$ 1 by VS cells was correlated with VS cell replication. It was assumed that TGF- $\beta$ 1 was responsible for the proliferation of VS. Also, Taurone et al.<sup>9</sup> after performing an immunohistochemical analysis of 10 human healthy vestibular nerves and 10 schwannoma samples, suggested that TGF- $\beta$ 1, through an upregulation of VEGF expression, indirectly supports the angiogenesis process, finally contributing to VS growth.

According to our study, higher serum concentration of VEGF and TGF- $\beta$ 1 was found in VS patients in comparison to healthy individuals. High level of VEGF, above maximum values in the control group, was found in 83% of cases and a high level of TGF- $\beta$ 1 was found in 57% of cases. Transforming growth factor beta1 was significantly elevated in the group where VS growth was clinically and instrumentally proven. This fact can be explained by the presence of bigger size tumors in growth tumor group.

The role of immunoglobulins in the evolution of VS is supported by studies which established the fact that IgA, IgG, and IgM levels are moderately or highly increased in VSs,<sup>10,11</sup> although Thomsen et al.<sup>23</sup> did not find any significant values of these cytokines in VS.



**Figure 2.** Concentration of carcinoembryonic antigen in patients with different stages of vestibular schwannoma in comparison to the control group.

Our results showed high IgM values in all VS cases in comparison to the control group, but high values of IgA were found only in the intracanalicular and third-stage groups.

According to Celis-Aguilar et al.<sup>12</sup> high levels of CEA correlate with brain tumors, especially in VS associated with hearing loss, but our study did not show any significant deviations of CEA serum concentration in VS patients in comparison to control group.

Despite the aforementioned results, we would like to point out the limitations of the study. The low number of patients with VS who were investigated in order to determine the serum level of the above-mentioned indicators is a shortcoming that may affect the value of the obtained data. Also, as a limitation, has to be considered the fact that "Wait and Scan" monitoring of patients lasted up to 2 years. Thus, the growth of VS was determined over a short period of time. Also, even if the measurement of the tumor growth was made by 2 experienced specialists in radiology, it was not made according to actual standards for tumor growth. Therefore, because of the presented limitations and despite the obtained results, a lot of further research needs to be done in this field.

## CONCLUSION

Growth factors such as VEGF and TGF-β1 can play a significant role in the genesis of VS and their investigation is appropriate both in the process of monitoring patients with VS and in the assessment of treatment effectiveness. Immunoglobulins M and A can be used as additional markers of VS, especially in tumor growth. A steady increase in their concentration is a prognostically unfavorable sign of VS. High CEA serum concentrations were found only in the late stages of VS development.

**Ethics Committee Approval:** Ethical committee approval was received from the Ethics Committee of Institute of Otolaryngology named after prof. Kolo-mychenko A.I. of the NAMS of Ukraine (Approval No: 18/21-1).

**Informed Consent:** Informed consent was obtained from each patient included in the study.

**Peer-review:** Externally peer-reviewed.

**Author Contributions:** Concept – O.B.; Design – O.B., O.M.; Supervision – O. B.; Materials – A.P., M.B.; Data Collection and/or Processing – A.P.; Analysis and/or Interpretation – O.M., A.P.; Literature Review – M.B.; Writing Manuscript – M.B.; Critical Review – O.B.

**Acknowledgments:** The authors would like to thank colleagues of the department of ear microsurgery and otoneurosurgery and from the department of pathophysiology and immunology.

**Declaration of Interests:** The authors declare that they have no conflict of interest.

**Funding:** The authors declared that this study has received no financial support.

## REFERENCES

- Roosli C, Linthicum FH Jr, Cureoglu S, Merchant SN. What is the site of origin of cochleovestibular schwannomas? *Audiol Neurootol*. 2012;17(2):121-125. [\[CrossRef\]](#)
- Tallan EM, Harner SG, Beatty CW, Scheithauer BW, Parisi JE. Does the distribution of Schwann cells correlate with the observed occurrence of acoustic neuromas? *Am J Otol*. 1993;14(2):131-134.
- Tikka T, Yiannakis CP, Stapleton E, et al. Spontaneous vestibular schwannoma regression: a case-control study. *Otol Neurotol*. 2018;39(10):e1118-e1124. [\[CrossRef\]](#)
- Sass H, Cayé-Thomasen P. Contemporary molecular biology of sporadic vestibular schwannomas: a systematic review and clinical implications. *J Int Adv Otol*. 2018;14(2):322-329. [\[CrossRef\]](#)
- Helbing DL, Schulz A, Morrison H. Pathomechanisms in schwannoma development and progression. *Oncogene*. 2020;39(32):5421-5429. [\[CrossRef\]](#)
- Zhang Y, Long J, Ren J, Huang X, Zhong P, Wang B. Potential molecular biomarkers of vestibular schwannoma growth: progress and prospects. *Front Oncol*. 2021;11:731441. [\[CrossRef\]](#)
- Dinareello CA. Proinflammatory cytokines. *Chest*. 2000;118(2):503-508. [\[CrossRef\]](#)
- Stone WL, Leavitt L, Varacallo M. Physiology. *Growth Factor*. In: *StatPearls* [internet]. Treasure Island (FL): StatPearls Publishing; 2021.
- Taurone S, Bianchi E, Attanasio G, et al. Immunohistochemical profile of cytokines and growth factors expressed in vestibular schwannoma and in normal vestibular nerve tissue. *Mol Med Rep*. 2015;12(1):737-745. [\[CrossRef\]](#)
- Manjula S, Aroor AR, Raja A, Rao SN, Rao A. Serum immunoglobulins in brain tumours. *Acta Neurochir (Wien)*. 1992;115(3-4):103-105. [\[CrossRef\]](#)
- Yüceer N, Arasil E, Temiz C. Serum immunoglobulins in brain tumours and lumbar disc diseases. *NeuroReport*. 2000;11(2):279-281. [\[CrossRef\]](#)
- Celis-Aguilar E, Lassaletta L, Torres-Martin M, et al. The molecular biology of vestibular schwannomas and its association with hearing loss: a review. *Genet Res Int*. 2012;2012:856157. [\[CrossRef\]](#)
- Zhang N, Chen J, Ferraro GB, et al. Anti-VEGF treatment improves neurological function in tumors of the nervous system. *Exp Neurol*. 2018;299(B):326-333. [\[CrossRef\]](#)
- Carmeliet P. VEGF as a key mediator of angiogenesis in cancer. *Oncology*. 2005;69(suppl 3):4-10. [\[CrossRef\]](#)
- Cayé-Thomasen P, Baandrup L, Jacobsen GK, Thomsen J, Stangerup SE. Immunohistochemical demonstration of vascular endothelial growth factor in vestibular schwannomas correlates to tumor growth rate. *Laryngoscope*. 2003;113(12):2129-2134. [\[CrossRef\]](#)
- Koutsimpelas D, Stripf T, Heinrich UR, Mann WJ, Brieger J. Expression of vascular endothelial growth factor and basic fibroblast growth factor in sporadic vestibular schwannomas correlates to growth characteristics. *Otol Neurotol*. 2007;28(8):1094-1099. [\[CrossRef\]](#)
- Koutsimpelas D, Bjelopavlovic M, Yetis R, et al. The VEGF/VEGF-R axis in sporadic vestibular schwannomas correlates with irradiation and disease recurrence. *ORL J Otorhinolaryngol Relat Spec*. 2012;74(6):330-338. [\[CrossRef\]](#)
- Dilwali S, Roberts D, Stankovic KM. Interplay between VEGF-A and cMET signaling in human vestibular schwannomas and Schwann cells. *Cancer Biol Ther*. 2015;16(1):170-175. [\[CrossRef\]](#)
- Zhang N, Gao X, Zhao Y, Datta M, Liu P, Xu L. Rationally combining anti-VEGF therapy with radiation in NF2 schwannoma. *J Rare Dis Res Treat*. 2016;1(2):51-55.
- Tamura R, Fujioka M, Morimoto Y, et al. A VEGF receptor vaccine demonstrates preliminary efficacy in neurofibromatosis type 2. *Nat Commun*. 2019;10(1):5758. [\[CrossRef\]](#)
- Chen HY, Ho YJ, Chou HC, et al. The role of transforming growth factor-beta in retinal ganglion cells with hyperglycemia and oxidative stress. *Int J Mol Sci*. 2020;21(18):6482. [\[CrossRef\]](#)
- Bizzarri M, Filipo R, Valente MG, et al. Release of transforming growth factor beta-1 in a vestibular schwannoma cell line. *Acta Otolaryngol*. 2002;122(7):785-787. [\[CrossRef\]](#)
- Thomsen J, Saxtrup O, Tos M. Spinal proteins in patients with acoustic neuromas. *ORL J Otorhinolaryngol Relat Spec*. 1982;44(2):66-71. [\[CrossRef\]](#)