

follow-up when considering the possibility of local tumor recurrence. In addition, the plantar location impairs the nutrition of the grafts, which often evolve with partial or even total necrosis.

SIH has been considered a more effective method of repairing when compared to FTSG, although it requires a longer healing time.<sup>2,4</sup> It is indicated for areas more susceptible to pressure since the local inherent trauma of these sites tends to impair the viability of grafts and flaps.<sup>4</sup> We can also point excellent cosmetic results since they do not evolve with blackening, which facilitates the clinical follow-up of these patients. Also, since it does not require donor area excision, SIH does not leave additional scars, as opposed to skin grafts and flaps.<sup>1,2</sup> However, the disadvantage is that SIH requires longer healing time, with more medical visits.

Jung et al.<sup>2</sup> demonstrated that patients in the SIH group showed better results than patients submitted to skin graft repair when considering the occurrence of infections, seroma, and necrosis.<sup>2</sup> In our experience, SIH has been a method that is practical, low-cost, and unlikely to present infectious complications.

In this letter, we presented two examples of possible surgical approaches for AM management, showing that, despite its longer recovery, SIH produces excellent cosmetic and functional results,<sup>2</sup> with minimal morbidity and lower complication rates.<sup>1</sup> Such findings encouraged us to initiate a prospective study to evaluate a larger number of patients with clinical outcomes similar to those reported in this study. In conclusion, our findings suggest that SIH approach has a potential role in the surgical treatment of the AM, which should be considered by surgeons.

### Financial support

None declared.

### Author's contributions

Lívia Mesquita Zyman: Approval of the final version of the manuscript; elaboration and writing of the manuscript; critical review of the literature; critical review of the manuscript.

José Antônio Jabur da Cunha: Approval of the final version of the manuscript; conception and planning of the study; obtaining, analyzing and interpreting the data;

effective participation in research orientation; intellectual participation in propaedeutic and/or therapeutic conduct of the cases studied; critical review of the manuscript.

Andrea Ortega Gimenez: Elaboration and writing of the manuscript.





Marcus Maia: Obtaining, analyzing and interpreting the data; critical review of the manuscript.

### Conflicts of interest

None declared.

### References

1. Schoenfeld J, Wirth P, Helm T. Mohs micrographic surgery and secondary intention healing of a plantar melanoma *in-situ*. *Dermatol Online J*. 2017;23, pii: 13030/qt7d02z4f7.
2. Jung JY, Roh HJ, Lee SH, Nam K, Chung KY. Comparison of secondary intention healing and full-thickness skin graft after excision of acral lentiginous melanoma on foot. *Dermatol Surg*. 2011;37:1245–51.
3. Maia M, Russo C, Ferrari N, Ribeiro MCSA. Acral lentiginous melanoma: a challenge for early diagnosis. *An Bras Dermatol*. 2003;78:553–60.
4. Oh BH, Lee SH, Nam KA, Lee HB, Chung KY. Comparison of negative pressure wound therapy and secondary intention healing after excision of acral lentiginous melanoma on the foot. *Br J Dermatol*. 2013;168:333–8.
5. Maia M, Ferrari N, Russo C, Ribeiro MCSA, Santos ABO. Reflections regarding the epidemiology of cutaneous melanoma in Brazil. *An Bras Dermatol*. 2002;77:163–70.

Lívia Mesquita Zyman \*,  
José Antônio Jabur da Cunha ,  
Andrea Ortega Gimenez , Marcus Maia 

*Clinic of Dermatology, Department of Medicine, Santa Casa de Misericórdia de São Paulo, São Paulo, SP, Brazil*

\* Corresponding author.

*E-mail: liviamz@msn.com* (L.M. Zyman).

Received 10 September 2018; accepted 10 January 2019

<https://doi.org/10.1016/j.abd.2019.09.019>  
0365-0596/

© 2019 Sociedade Brasileira de Dermatologia. Published by Elsevier España, S.L.U. This is an open access article under the CC BY license (<http://creativecommons.org/licenses/by/4.0/>).

## Multiple fibroepitheliomas of Pinkus after radiotherapy<sup>☆,☆☆</sup>

*Dear Editor,*

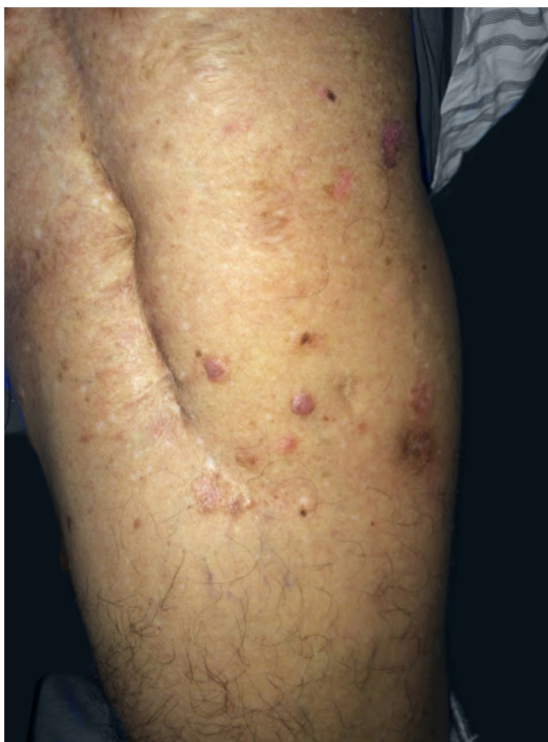
Fibroepithelioma of Pinkus (FEP), also known as fibroepithelial basal cell carcinoma, is a rare cutaneous neoplasm. It

has a frequency that ranges from 0.2% to 1.4% in a series of basal cell carcinomas.<sup>1,2</sup> Its etiopathogenesis is controversial; some authors consider it a variant of basal cell carcinoma, and others, as a variant of trichoblastoma.<sup>2</sup> However, there are studies that suggest a significant influence of previous exposure to radiotherapy.<sup>1,3</sup> Based on clinical suspicion, the peculiar and unmistakable histopathology confirms the diagnosis.<sup>2</sup> The present study reports the case of man exhibiting neoplastic cutaneous lesions, restricted to the site in the left thigh where radiotherapy had been previously administered for bone tumor.

The patient was 69 years old, male, white, and with a history of bone tumor in the left femur at the age of

<sup>☆</sup> How to cite this article: Badaró BA, Diniz LM, Negris Neto E, Lucas EA. Multiple fibroepitheliomas of Pinkus after radiotherapy. *An Bras Dermatol*. 2019;94:633–5.

<sup>☆☆</sup> Study conducted at the Hospital Universitário Cassiano Antônio Moraes, Universidade Federal do Espírito Santo, Vitória, ES, Brazil.

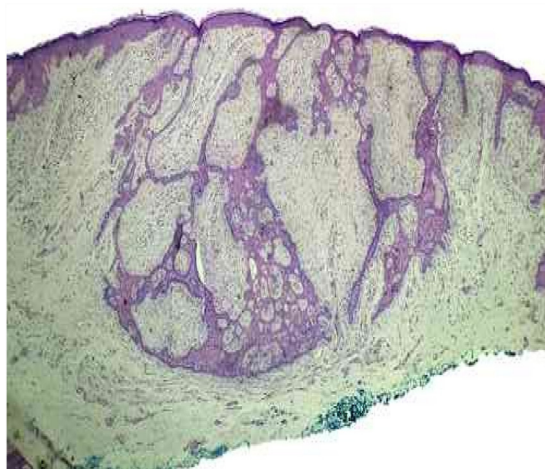

**Figure 1** Presence of translucent erythematous papules, discreetly raised red-brown plaques adjacent to the surgical scar in the left thigh. Anterolateral view.

17 years. He had undergone a surgical intervention and adjuvant radiotherapy. Years later, he noticed the appearance of red-brown, asymptomatic, slowly evolving papules, restricted to the skin adjacent to the surgical scar, in the area previously subjected to radiotherapy. In 2016, the patient sought dermatological treatment. He exhibited discreetly raised translucent erythematous plaques with pigmented inferior borders, located on the upper lateral aspect of the left thigh. He also exhibited some translucent erythematous papules, located near the surgical scar (Fig. 1). The histopathological study of the excised plaque from the upper left thigh exhibited neoplastic basaloid cells infiltrating the dermis, with anastomoses that had a cord-like appearance, accompanied by surrounding desmoplasia, and compatible with FEP (Fig. 2). All other lesions in the irradiated area were excised and submitted to histopathological examination, maintaining the diagnosis of FEP characterized by multiple lesions.

FEP affects non-photoexposed areas, commonly in the inguinal and lumbosacral regions.<sup>1,2</sup> It occurs in individuals aged between 40 and 60 years,<sup>1</sup> with a discrete predominance in women (54%).<sup>2</sup> It is clinically characterized by single or multiple lesions, such as papules or plaques, which are normochromic/brownish, cupuliform, or sessile.<sup>1,2</sup> The case reported diverges with respect to sex (male); however, it is similar regarding location (non-photoexposed area), age (69 years), and clinical manifestation (multiple discreetly raised erythematous plaques and red-brown papules).

The etiopathogenesis of FEP is controversial.<sup>2</sup> Some authors classify it as a variant of basal cell carcinoma, and others as a variant of trichoblastoma.<sup>1</sup> Evidence in the



**Figure 2** Epithelial proliferation infiltrating the dermis, with anastomoses that had a cord-like appearance, accompanied by surrounding desmoplasia (hematoxylin & eosin,  $\times 4$ ).

literature remains difficult to classify, in some aspects favoring basal cell carcinoma, and, in others, trichoblastoma.<sup>2</sup> However, it has been argued that there is an association between FEP and previous exposure to radiotherapy,<sup>1,3</sup> as in the case reported, in which the patient's neoplastic lesions were restricted to the previously irradiated region. In a literature review, four articles were found referring to the association between FEP and previously irradiated skin areas.<sup>1,3-5</sup>

The histopathological features are fundamental for diagnosis. They are described as peculiar and unmistakable, evidencing thin anastomosing strands of basaloid cells, surrounded by abundant stroma, which form a uniform border with the underlying dermis, resembling a honeycomb.<sup>1,2</sup> These characteristics were found in the present case.

The evolution of FEP is slow. It exhibits low local aggression and little risk of metastasis.<sup>1,2</sup> Excisions of the lesions are recommended and these procedures are almost always curative, given that topical treatments are ineffective.<sup>1</sup> Patients should attend dermatological follow-up appointments for early diagnosis and treatment of new lesions.

In the presented case, the patient had multiple FEP lesions excised and is attending regular follow-up appointments at the dermatology service.

This case is reported to emphasize the possibility of other etiologies of basal cell carcinomas, such as previous radiotherapy.

### Financial support

None declared.

### Author's contributions

Bruna Anjos Badaró: Conception and planning of the study; elaboration and writing of the manuscript; obtaining, analyzing and interpreting the data; critical review of the literature; critical review of the manuscript.

Lucia Martins Diniz: Approval of the final version of the manuscript; conception and planning of the study; effective

participation in research orientation; intellectual participation in propaedeutic and/or therapeutic conduct of the cases studied; critical review of the literature; critical review of the manuscript.

Ernesto Negris Neto: Obtaining, analyzing and interpreting the data; intellectual participation in propaedeutic and/or therapeutic conduct of the cases studied.

Elton Almeida Lucas: Obtaining, analyzing and interpreting the data; effective participation in research orientation; intellectual participation in propaedeutic and/or therapeutic conduct of the cases studied.

## Conflicts of interest





None declared.

## Acknowledgements

To the teachers, resident colleagues and patients of the Dermatology Service of Hospital Universitário Cassiano Antonio Moraes.

## References

1. Holcomb MJ, Motaparthi K, Grekin SJ, Rosen T. Fibroepithelioma of Pinkus induced by radiotherapy. *Dermatol Online J.* 2012;18:5.
2. Haddock ES, Cohen PR. Fibroepithelioma of Pinkus revisited. *Dermatol Ther (Heidelb).* 2016;6:347–62.
3. Hartschuh W, Schulz T. Merkel cell hyperplasia in chronic radiation-damage skin: its possible relationship to fibroepithelioma of Pinkus. *J Cutan Pathol.* 1997;24:477–83.
4. Cahuzac P, Hermier C, Thivolet J. Premalignant fibroepithelial tumors of Pinkus and previous irradiation: report of a survey of 20 patients. *Ann Dermatol Venereol.* 1982;109:355–7.
5. Colomb D, Drevon JP, Kirkorian M, Gho A. The carcinogenic role of earlier X-ray irradiation of multiple epitheliomas of the back: critical study of 15 personal cases. *Ann Dermatol Venereol.* 1985;112:13–9.

Bruna Anjos Badaró <sup>a,\*</sup>, Lucia Martins Diniz <sup>a,b</sup>,  
Ernesto Negris Neto <sup>a</sup>, Elton Almeida Lucas <sup>c</sup>

<sup>a</sup> *Service of Dermatology, Hospital Universitário Cassiano Antônio Moraes, Universidade Federal do Espírito Santo, Vitória, ES, Brazil*

<sup>b</sup> *Department of Clinical Medicine – Dermatology, Universidade Federal do Espírito Santo, Vitória, ES, Brazil*

<sup>c</sup> *Service of Dermatopathology, Hospital Universitário Cassiano Antônio Moraes, Universidade Federal do Espírito Santo, Vitória, ES, Brazil*

\*Corresponding author.

E-mail: [brunaanjosbadaro@hotmail.com](mailto:brunaanjosbadaro@hotmail.com) (B.A. Badaró).

Received 29 October 2018; accepted 13 January 2019

<https://doi.org/10.1016/j.abd.2019.09.020>  
0365-0596/

© 2019 Published by Elsevier España, S.L.U. on behalf of Sociedade Brasileira de Dermatologia. This is an open access article under the CC BY license (<http://creativecommons.org/licenses/by/4.0/>).