

# A Case Report of Aneurysmal Bone Cyst with Pathologic Fracture of Proximal Femur Managed with Enbloc Excision and Autologous Non-vascularized Fibular Graft

Shaligram Purohit<sup>1</sup>, Balgovind S Raja<sup>1</sup>, Nandan A Marathe<sup>1</sup>, Prakash K George<sup>1</sup>

## Learning Point of the Article:

Treatment of destructive and aggressive lesions in Aneurysmal bone cysts often involves en bloc resection of the tumor creating large bone defects which can be successfully managed with non-vascularized fibular autograft and cancellous graft with DCS providing good long term functional outcome.

## Abstract

**Introduction:** Aneurysmal bone cyst (ABC) is typically a benign, expansile, and cystic lesion of the bone that can be locally aggressive characterized by vascular gaps separated by fibrous septae. Treatment modalities available are sclerosing agents, arterial embolization, surgical excision, curettage with or without bone grafting, and adjuvant radiotherapy.

**Case Report:** We report a rare case of ABC with pathologic fracture in the proximal femur in a 15-year-old female patient, treated with en bloc excision, bone grafting with non-vascularized fibular strut graft and stabilized with a 95° dynamic condylar screw plate system. Follow-up at 24 months showed incorporation of the fibular graft and full union.

**Conclusion:** Structural support and autologous bone grafting in giant ABC in young individuals would yield adequate results.

**Keywords:** Aneurysmal bone cyst, Femur Tumor fibula strut graft, en bloc excision.

## Introduction

Aneurysmal bone cyst (ABC) is a benign, expansible, and cystic lesion of the bone that can be locally aggressive characterized by vascular gaps separated by fibrous septae [1]. The term aneurysmal seems to relate to the blowout distension, and the word cyst reflects the fact that the tumor presents as a blood-filled cavity. It is usually situated in metaphysis of long bones, and the incidence is high in the first two decades with more than 95% seen in the first three decades [2].

The proximal femur is the most commonly involved bone, but all bones can be affected by it [2]. Histologically, the ABC can be of three types: Conventional/vascular type (that is rapidly growing extensive lesion), solid type, and a mixed type. The treatment modalities described for ABC are curettage, curettage with or without bone grafting, sclerosing agents, arterial

embolization, adjuvant radiotherapy, demineralized bone matrix applications, and segmental or en bloc resections. En bloc resection has the lowest recurrence rate as low as 0% [3].

## Case Report

We report a case of a 15-year-old girl who presented with pain in the right groin region following a history of trivial fall. She was unable to weight bear on the right side subsequently. She had an unremarkable medical and family history. Clinical examination revealed mild diffuse swelling of the right hip region with tenderness on deep palpation and restricted range of motion at the right hip joint. Skin overlying was normal without any redness or dilated veins. The patient was investigated and radiographs revealed a geographic lytic expansile lesion with septae with thin sclerotic margins involving the proximal

Access this article online

Website:  
www.jocr.co.in

DOI:  
10.13107/jocr.2020.v10.i01.1632

## Author's Photo Gallery



Dr. Shaligram Purohit



Dr. Balgovind S Raja



Dr. Nandan A Marathe

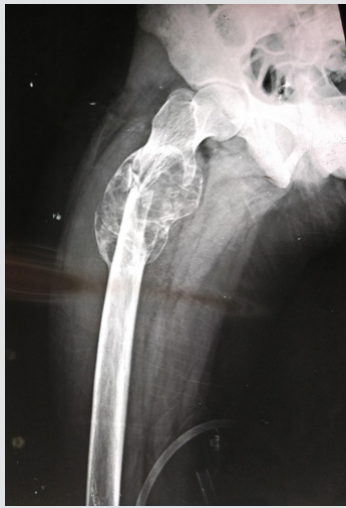

Dr. Prakash K George

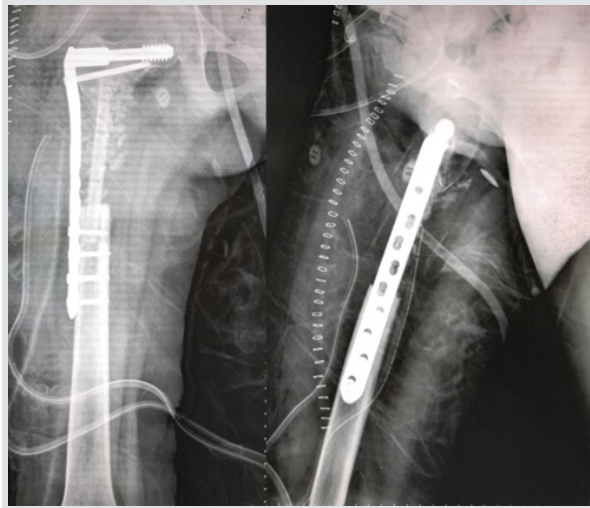
<sup>1</sup>Department of Orthopaedics, Seth Gordhandas Sunderdas Medical College and King Edward Memorial Hospital, Mumbai, Maharashtra, India

### Address of Correspondence:

Dr. Prakash K George,  
Department of Orthopaedics, Seth Gordhandas Sunderdas Medical College and King Edward Memorial Hospital, Room 305, RMO Hostel, KEM Hospital, Parel, Mumbai - 400012, Maharashtra, India.  
E-mail: drprakashkgeorge@gmail.com



**Figure 1:** Aneurysmal bone cyst in the proximal femur with pathologic fracture.



**Figure 2:** Post-operative radiograph: En bloc excision of tumor was performed and grafting with cancellous bone graft and non-vascularized fibula done.

18 months was allowed. Follow-up at 24-month post-surgery revealed 1cm shortening of the affected limb with no deformities and a hip joint with a normal range of motion (Fig. 3). Radiographs revealed a fully incorporated fibular graft with no lesion recurrence (Fig. 4).

**Discussion**

ABCs are locally aggressive lesions of the bone characterized by blood-filled cavities lined by fibroblast and histiocytes. The incidence of pathologic fractures is about 8% [1]. Primary ABCs are those, which arise de novo. Secondary ABCs are the ones, which

arise in conjunction with other lesions such as fibrous dysplasia, chondromyxoid fibroma, non-ossifying fibroma, osteoblastoma, chondrosarcoma, osteosarcoma, simple bone cyst, and metastatic carcinoma [2]. The present case was consistent with primary ABC.

metaphyseal region of the right femur along with pathologic fracture in the subtrochanteric region (Fig. 1). Magnetic resonance imaging also indicated the presence of an ABC in the proximal third of the right femur. Biopsy through the lateral approach confirmed the diagnosis of ABC. Selective arterial embolization was initially planned to devascularize the tumor, but lower limb angiogram revealed the tumor to be relatively avascular.

A lateral approach to the tumor was performed and the lesion was excised en bloc with 1cm of normal bone on either end. The Richard screw was first passed into the femoral neck and head followed by wide excision of the tumor. It resulted in a gap of around 10 cm in the proximal femur. A non-vascularized fibula strut graft of 11 cm was harvested from the ipsilateral side and was augmented with cancellous autologous iliac bone graft. A dynamic condylar screw (DCS) plate system consisting of 8-hole titanium plate with distal four bicortical screws was used to stabilize it (Fig. 2).

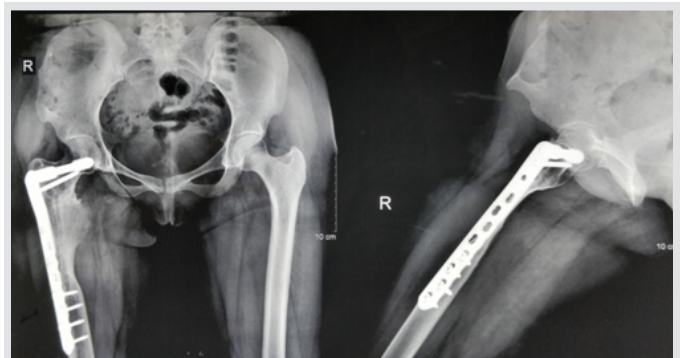She was kept non-weight-bearing for 14-month post-operative and mobilized non-weight-bearing with a walker until the bone graft had incorporated radiologically. Partial weight-bearing was started at 14-month post-surgery and full weight-bearing at

The optimal treatment for ABCs is still debatable. The en bloc resection until date provides the best outcome and lowest relapse rates for ABC but has the highest morbidity rate with complications of massive hemorrhage, increased risk of infection, shortening of the limb, growth defects, and muscular hypotonia [4]. Other treatment options include sclerosing substances and bone substitutes, which are less effective than conventional curettage [5]. Embolization is done with an aim to devascularize the tumor and can reduce the intra- and post-operative complications of open surgery. Sclerosing therapy is not indicated in cases where there is cortical break [6].

Ours were a rare case, wherein the resection of the tumor resulted in a large defect. The dilemma present was whether to reconstruct the proximal femur with allograft or whether to reconstruct the joint with tumor prosthesis. Vascularized bone grafts are considered as the best method to replace large bone defects due to their ability for faster incorporation and



**Figure 3:** Clinical photo showing good functional outcome.



**Figure 4:** Full incorporation of the graft with no recurrence at 2-year follow-up.

remodeling, but it is a rather technically demanding procedure [7]. Our choice was to use non-vascularized autologous fibular strut bone graft and cancellous bone grafts as they are technically easier to harvest and provide excellent structural bone support [8, 9]. The option of tumor prosthesis was discarded due to the salvageable hip joint and possibility of discrepancy in limb length during growth. In the present case, the final construct obtained was stable and allowed progressive weight-bearing without graft failure and recurrence.

Literature on the treatment strategies on pathologic fractures of the proximal femur secondary to ABC is limited. Jaffe and Dunham in their case report treated similar case with curettage, cortical fibular autograft, and dynamic hip screw [3]. However, the patient later developed avascular necrosis of the femoral head and required total hip replacement [3].

The current case reveals a successful treatment in proximal femoral ABC with a pathologic fracture. En bloc resection with 1cm of bone from both the ends with non-vascularized strut grafting augmented with autologous iliac cancellous graft and

fixation with DCS system provided good functional and oncological outcome.

### Conclusion

The treatment in ABC should be individualized for each patient. The dilemma of the optimal treatment in pathologic fractures in cases associated with the destructive and aggressive lesion exists in ABC. Large defects associated with en bloc resection of the tumor can be successfully managed with non-vascularized fibular autograft and cancellous graft with DCS.

### Clinical Message

En bloc excision removes the risk of recurrence. Medial fibular structural support is obtained with fibular bone grafting, thus giving long-lasting fruitful outcome.

### References

1. Vergel De Dios AM, Bond JR, Shives TC, McLeod RA, Unni KK. Aneurysmal bone cyst. A clinicopathologic study of 238 cases. *Cancer* 1992;69:2921-31.
2. Bonakdarpour A, Levy WM, Aegerter E. Primary and secondary aneurysmal bone cyst: A radiological study of 75 cases. *Radiology* 1978;126:75-83.
3. Cole WG. Treatment of aneurysmal bone cysts in childhood. *J Pediatr Orthop* 1986;6:326-9.
4. Güven M, Demirel M, Ozler T, Başsorgun IC, Ipek S, Kara S. An aggressive aneurysmal bone cyst of the proximal humerus and related complications in a pediatric patient. *Strategies Trauma Limb Reconstr* 2012;7:51-6.
5. Dubois J, Chigot V, Grimard G, Isler M, Garel L. Sclerotherapy in aneurysmal bone cysts in children: A review of 17 cases. *Pediatr Radiol* 2003;33:365-72.
6. Szendrői M, Cser I, Kónya A, Rényi-Vámos A. Aneurysmal bone cyst. A review of 52 primary and 16 secondary cases. *Arch Orthop Trauma Surg* 1992;111:318-22.
7. Ghert M, Colterjohn N, Manfrini M. The use of free vascularized fibular grafts in skeletal reconstruction for bone tumors in children. *J Am Acad Orthop Surg* 2007;15:577-87.
8. Ulici A, Nahoi C, Carp M, Fodor I, Dinu C. Surgical treatment of an aneurysmal bone cyst with avascular bone graft. *Chirurgia (Bucur)* 2017;112:172-7.
9. Grzegorzewski A, Pogonowicz E, Sibinski M, Marciniak M, Synder M. Treatment of benign lesions of humerus with resection and non-vascularised, autologous fibular graft. *Int Orthop* 2010;34:1267-72.

**Conflict of Interest:** Nil

**Source of Support:** Nil

**Consent:** The authors confirm that Informed consent of the patient is taken for publication of this case report

### How to Cite this Article

Shaligram P, Balgovind S R, Nandan A M, Prakash K G. A Case Report of Aneurysmal Bone Cyst with Pathologic Fracture of Proximal Femur Managed with Enbloc Excision and Autologous Non-vascularized Fibular Graft. *Journal of Orthopaedic Case Reports* 2020 Jan-Feb;10(1): 51-53.