

## REFERENCES

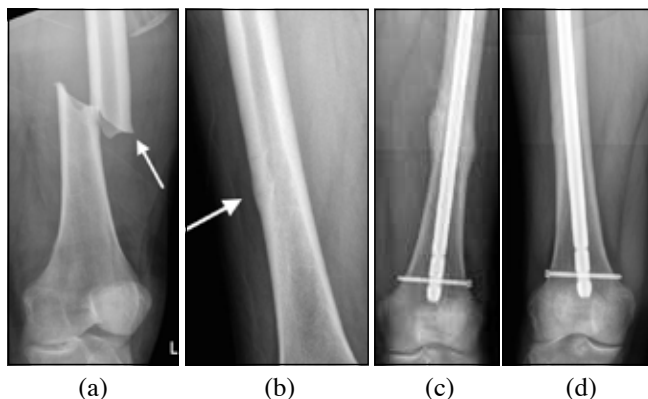
1. Baek R-M, Kim B-K, Jeong J-H, Ahn T, Park M and Han J, The effect of age at surgery and compensatory articulation on speech outcome in submucous cleft palate patients treated with double-opposing Z-plasty: A 10-year experience. *J Plast Reconstr Aesthet Surg*. 2017; 70(5): 646-52.
2. Martin S, Damkat-Thomas L, Foster P, Hayden C, O'Connor E, Hill C. The rise of the submucous cleft - A single centre review over 15 years. Annual Scientific Conference; 2017 Apr 5-7; Gateshead, Newcastle, UK. Craniofacial Society of Great Britain and Ireland. p. 35.

## AN 'ATYPICAL' ATYPICAL FEMORAL FRACTURE

## Editor,

A 75 year-old-male was admitted after sustaining a left femoral shaft fracture. He reported severe pain in his left thigh whilst descending steps followed by a sudden 'giving way' causing him to fall. Closer questioning revealed that he had been experiencing pain in his left thigh for approximately 8 weeks prior to the event but had no pain in the right thigh. His medical history included hypertension, hypothyroidism, reflux oesophagitis, type II diabetes mellitus and hypercholesterolaemia. Long-term medications included omeprazole, metformin and levothyroxine.

Left femur radiographs demonstrated a fracture at the junction of the middle and distal thirds with a short oblique pattern and localised periosteal thickening of the lateral cortex in keeping with an atypical femoral fracture [AFF] (**Figure 1a**). Admission blood and urine tests, including tumour markers, were unremarkable. A chest, abdomen and pelvic CT scan did not reveal any abnormality. Radiographs of the right femur demonstrated an incomplete fracture at the junction of the middle and distal thirds with focal thickening of the lateral cortex (**Figure 1b**). Antegrade intramedullary nailing was performed on the fractured side followed by prophylactic nailing on the contralateral side one week later. Metabolic bone assessment revealed a normal serum level of calcium, phosphate, parathormone and bone alkaline phosphatase with a slightly reduced vitamin D level, raised



**Fig 1.** (a) Anteroposterior radiograph (AP) of left femur- note short oblique fracture pattern with 'beaking' of the lateral cortex (white arrow); (b) AP radiograph of right femur demonstrating incomplete fracture with thickening of the lateral cortex (white arrow); (c) AP radiograph of left femur demonstrating complete union; (d) AP radiograph of right femur demonstrating complete union.

resorptive bone markers (C-terminal telopeptide, CTX) and low-level bone formation markers (N-terminal propeptide of type-I procollagen, P1NP). Bone densitometry was normal. Radiological fracture union was evident on both sides after approximately 10 months (**Figure 1c and d**).

AFF's are defined as atraumatic or low-trauma fractures located between the subtrochanteric and supracondylar regions of the femur and have characteristic clinical and radiological features.<sup>1</sup> The American Society for Bone and Mineral Research (ASBMR) have proposed a set of specific criteria in order to identify AFF's with the requisition that at least four 'major criteria' should be observed.<sup>2</sup> In this case, there was no trauma, the fracture line originated at the lateral cortex with a transverse orientation, no comminution was present and there was localised periosteal thickening of the lateral cortex at the fracture site thus fulfilling the diagnostic criteria for an AFF.

The exact pathogenesis of AFF's is unknown. Bisphosphonate use is a key risk factor for AFF occurrence.<sup>2,3</sup> Other risk factors include genu varum, femoral bowing, collagen diseases and bone disorders characterized by low bone turnover, such as hypophosphatasia or pycnodysostosis.<sup>4</sup> Kim et al.<sup>5</sup> identified increased use of a proton-pump inhibitor (PPI) in AFF patients. The contralateral femur is affected in approximately 28 % of cases<sup>2</sup> and radiographic assessment is recommended even in the absence of symptoms. Intramedullary nailing is the treatment of choice for both complete and incomplete AFF's.<sup>4</sup>

This case highlights firstly, that AFF's can occur in the absence of anti-resorptive bone therapy, femoral malalignment or disorders of low bone turnover and secondly, the importance of assessment of the contralateral femur. Long-term use of a PPI may have been a contributory factor to the AFF's however mechanisms remain undetermined.

Dr Richard Arneill, Mr Matthew Arneill, Mr Neville W Thompson, Dr David Armstrong\*

Department of Trauma and Orthopaedics, Altnagelvin Hospital, 700 Glenshane Road, Londonderry BT47 6SB

\*Department of Rheumatology, Altnagelvin Hospital, 700 Glenshane Road, Londonderry BT47 6SB

Correspondence: Mr Neville W Thompson, Department of Trauma and Orthopaedics, Altnagelvin Hospital, 700 Glenshane Road, Londonderry BT47 6SB (neville.thompson@westerntrust.hscni.net)

## REFERENCES:

1. Shane E, Burr D, Ebeling PR, Abrahamsen B, Adler RA, Brown TD, *et al*. Atypical subtrochanteric and diaphyseal femoral fractures: report of a task force of the American Society for Bone and Mineral Research. *J Bone Miner Res*. 2010; **25**(11):2267-94.
2. Shane E, Burr D, Abrahamsen B, Adler RA, Brown TD, Cheung AM *et al*. Atypical subtrochanteric and diaphyseal femoral fractures: second report of a task force of the American Society for Bone and Mineral Research: AFF task force report. *J Bone Miner Res*. 2014; **29**(1):1-23.
3. Thompson RN, Phillips JRA, McCauley SH, Elliott JR, Moran CG, *et al*. Atypical femoral fractures and bisphosphonate treatment: experience in two large United Kingdom teaching hospitals. *J Bone Joint Surg Br*. 2012;**94**(3): 385-90.



UMJ is an open access publication of the Ulster Medical Society (<http://www.ums.ac.uk>).

The Ulster Medical Society grants to all users on the basis of a Creative Commons Attribution-NonCommercial-ShareAlike 4.0 International Licence the right to alter or build upon the work non-commercially, as long as the author is credited and the new creation is licensed under identical terms.

4. Toro G, Ojeda-Thies C, Calabro G, Toro G, Moretti A, Guerra GM, et al. Management of atypical femoral fracture: a scoping review and comprehensive algorithm. *BMC Musculoskel Dis.* 2016;**17**: 227-30.
5. Kim D, Sung YK, Cho SK, Han M, Kim YS. Factors associated with atypical femoral fracture. *Rheumatol Int.* 2016;**36**(1): 65-71.

## PREVENTION OF PRESSURE ULCERS IN NASAL BRIDGE DURING NON-INVASIVE MECHANICAL VENTILATION. DISCUSSION OF RESULTS

### Editor,

We would like to discuss the results achieved in the study by Bishopp et al. recently published in *Ulster Medical Journal* in which strategies for skin care during non-invasive mechanical ventilation were suggested.<sup>1</sup> The discussion of this study refers to a limited protective benefit of hyperoxygenated fatty acids in a study carried out by our team and also suggested that our sample was too limited to draw conclusions.<sup>2</sup>

We would like to refute the suggestion that our study, "Preventing facial pressure in patients under non-invasive mechanical ventilation: a randomized control trial" has a small sample size.<sup>2</sup> Our study had a methodology with calculation of statistical sample size<sup>3</sup>, declared in the article and in previous protocols, by a previous piloting with 40 patients (10 in each group). The piloting allowed a pre-analysis for the size calculation of the effect estimated in 15.8%.

In the case of our clinical trial, the result of the number of the sample calculated is 152 patients in total among the four study groups, making replacement of the losses as can be seen in Fig. 1 of our article. The sample has been calculated so that the results can be considered, assuming the size of the effect described, a statistical power of 80% ( $\beta = 0.20$ ) and a confidence level of 95% ( $\alpha = 0.05$ ).

For all these reasons, we consider it important to emphasise our results and suggest care strategies based on the application of hyperoxygenated fatty acids and /or essential oils every 4-6 hours in the contact areas of the interface during non-invasive mechanical ventilation, following advice in recent results published on the same line.<sup>2,4</sup>

Peña-Otero, D.<sup>a</sup>; Eguillor-Mutiloa, M.<sup>b</sup>; Moro-Tejedor, MN<sup>c</sup>; Medina-Torres, M.<sup>d</sup>; García-Pozo, A<sup>e</sup>

- a. RN, MSc, MRes, PhD, Professor. Hospital Sierrallana, Cantabria; Nursing Group, Gregorio Marañón Health Investigation Institute (IiSGM), Madrid, Spain. Orcid.org/0000-0001-6896-2984
- b. RN, MSc. University General Hospital Marqués de Valdecilla, Cantabria, Spain. Orcid.org/0000-0003-1228-1869
- c. RN, MSc, MRes, PhD. University General Hospital Gregorio Marañón, Madrid; Red Cross Nursing College, Universidad Autónoma de Madrid; Nursing Group, Gregorio Marañón Health Investigation Institute (IiSGM), Madrid, Spain. Orcid.org/0000-0002-2677-7454
- d. RN. University General Hospital Gregorio Marañón, Madrid; Nursing Group, Gregorio Marañón Health Investigation Institute (IiSGM), Madrid, Spain. Orcid.org/0000-0002-1770-7075

- e. RN, MSc, MRes, PhD. University General Hospital Gregorio Marañón, Madrid; Nursing Group, Gregorio Marañón Health Investigation Institute (IiSGM), Madrid, Spain. Orcid.org/0000-0003-4739-226X

### REFERENCES:

1. Bishopp A, Oakes A, Antoine-Pitterson P, Chakraborty B, Comer D, Mukherjee R. The preventative effect of hydrocolloid dressings on nasal bridge pressure ulceration in acute non-invasive ventilation. *Ulster Med J.* 2019;**88**(1):17-20.
2. Otero DP, Dominguez DV, Fernandez LH, Magariño AS, González VJ, Klepzing JV, et al. Preventing facial pressure ulcers in patients under non-invasive mechanical ventilation: A randomised control trial. *J Wound Care.* 2017;**26**(3):128-36.
3. Borkowf CB, Johnson LL, Albert PS. Power and sample size calculations. In: Gallin JI, Ognibene FP, Johnson LL, editors. *Principles and practice of clinical research.* 4th ed. Boston: Academic Press; 2018. p. 359-72.
4. Viveiros A, Nóbrega J, Santos L, Peña-Otero D, CA, Ribeiro, L, et al. Pressure injury on the face of patients undergoing noninvasive ventilation, hospitalized in the intensive care unit. *Med Sci.* 2019;**23**(96):155-8.

## PREVENTION OF PRESSURE ULCERS IN NASAL BRIDGE DURING NON-INVASIVE MECHANICAL VENTILATION. DISCUSSION OF RESULTS. AUTHORS' RESPONSE TO PEÑA-OTERO ET AL.

### Editor,

We would like to thank Peña-Otero et al. for their attention to our paper on the preventative effect of hydrocolloid dressings on nasal bridge pressure ulceration in acute NIV in the UMJ<sup>1</sup>. It was not our intention to demean by any means the study by Otero et al.<sup>2</sup> by mentioning that it was a small sample study. We have used the expression 'small sample sizes' generically referring to two other papers<sup>3,4</sup> without any indication of the power analysis involved alongside the paper by Otero et al.<sup>2</sup> However, we would like to take this opportunity to clarify our standpoint on the question of sample size calculation in Otero et al.<sup>2</sup>. A total sample size of 152 is determined to detect an effect size of 15.8% for the stated size and power. But this sample size is valid for comparing 76 subjects in 2 groups to be able to draw the conclusion that hyperoxygenated fatty acids (HOFA) is responsible for the preventative effect rather than split over 4 groups. The pairwise comparisons as stated in Otero et al.<sup>2</sup> require a larger sample size in each group to achieve the required power of 0.8. However, we strongly feel that the study in Otero et al.<sup>2</sup> is a significant study in the area of prevention of nasal bridge pressure ulceration and we are indebted to them for a pioneering research in the field of the practical application of NIV.

Abigail Bishopp<sup>1</sup>, Pearlene Antoine-Pitterson<sup>1</sup>, Biman Chakraborty<sup>2</sup>, David Comer<sup>1</sup>, Rahul Mukherjee<sup>1</sup>

1. Department of Respiratory Medicine & Physiology, Birmingham Heartlands Hospital, Bordesley Green East, Birmingham, B9 5SS, UK
2. School of Mathematics, University of Birmingham, Edgbaston, Birmingham, B15 2TT, UK

Corresponding author: Dr Rahul Mukherjee

E-mail: rahul.mukherjee@heartofengland.nhs.uk

