



Contents lists available at ScienceDirect

## International Journal of Surgery Case Reports

journal homepage: [www.casereports.com](http://www.casereports.com)

## Rhinolith mimicking a toothache

Sandra Girgis<sup>a,\*</sup>, Leo Cheng<sup>b,1</sup>, Darren Gillett<sup>a,2</sup><sup>a</sup> Homerton University Hospital NHS Foundation Trust, UK<sup>b</sup> Homerton University Hospital NHS Foundation Trust, Barts Health NHS Trust, Mercy Ships, UK

## ARTICLE INFO

## Article history:

Received 26 February 2015

Received in revised form 17 May 2015

Accepted 27 June 2015

Available online 10 July 2015

## Keywords:

Rhinolith

Toothache

Symptoms

## ABSTRACT

**INTRODUCTION:** A rhinolith is a calcified mass formed as a result of solidification of mucous foreign objects and gradual accretion of mineral salts. Toothache is not known to be the typical presenting symptom, and to our knowledge, has yet to be reported.

**CASE REPORT:** A 42-year old female referred by her general dental practitioner with a four month history of constant pain of the unrestored upper right central incisor tooth. Incidentally, she also gave a one year history of right-sided sinonasal congestion and intermittent blood stained rhinorrhea.

**DISCUSSION:** Rhinoliths are uncommon and rarely encountered in clinical practice. This is due to the fact that they remain asymptomatic, and undetected for many years. They may present as incidental radio-opaque lesions in the nasal maxillary antrum on routine dental panoramic radiographs.

**CONCLUSION:** Rhinolith should be part of the differential diagnosis of atypical anterior maxillary dental pain in the absence of obvious clinical dental pathology.

© 2015 The Authors. Published by Elsevier Ltd. on behalf of Surgical Associates Ltd. This is an open access article under the CC BY-NC-ND license (<http://creativecommons.org/licenses/by-nc-nd/4.0/>).

## 1. Introduction

A rhinolith is a calcified mass formed as a result of solidification of mucous foreign objects and gradual accretion of mineral salts, namely calcium and magnesium [1,2]. Rhinoliths are uncommon clinical entities due to the asymptomatic long-standing nature of these lesions. Toothache is not known to be the typical presenting symptom of a rhinolith, and to our knowledge, has yet to be reported.

## 2. Case report

A 42-year old Bengali female referred by her general dental practitioner with a four month history of constant pain of the unrestored upper right central incisor. She denied any trauma, and felt the tooth appeared to be 'slanting'. Incidentally, she gave a one year history of right-sided sinonasal congestion and intermittent blood stained rhinorrhea (discharge from the nasal mucous membrane). She was not aware of foreign body or other sinonasal concerns other

than hyosmia (diminished sense of smell)/cacosmia (imagining of unpleasant odours).

Medically, she was fit and well with no known allergies. On clinical examination of the upper right central incisor, the tooth appeared to be unrestored, non-mobile, with evidence of buccal sulcus tenderness.

A plain dental panoramic tomograph (DPT) revealed a radio-opaque lesion that appeared to be both in the right nasal cavity and right maxillary sinus, Fig. 1.

A subsequent computed tomography (CT) scan then confirmed a densely calcified mass within the right nasal cavity with mucosal thickening, closely related to the turbinate, demonstrating expansion of the lateral nasal wall, Fig. 2.

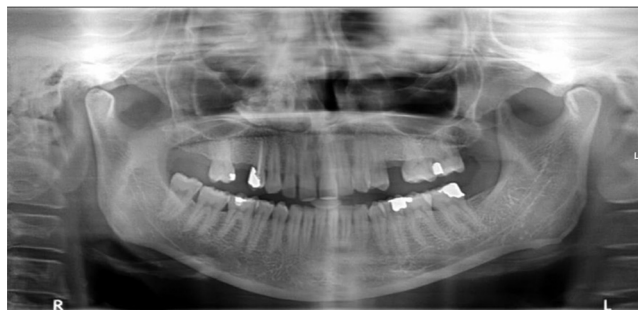

Fig. 1. Dense opacity projected over medial inferior aspect of right maxillary sinus.

\* Corresponding author at: Oral and Maxillofacial Head and Neck Surgery Department, UK.

E-mail addresses: [sandra.girgis@nhs.net](mailto:sandra.girgis@nhs.net) (S. Girgis), [leo.cheng@bartshealth.nhs.uk](mailto:leo.cheng@bartshealth.nhs.uk), [leo.cheng@homerton.nhs.uk](mailto:leo.cheng@homerton.nhs.uk) (L. Cheng), [darren.gillett@homerton.nhs.uk](mailto:darren.gillett@homerton.nhs.uk) (D. Gillett).

<sup>1</sup> Present address: Oral and Maxillofacial Consultant, Oral and Maxillofacial Head and Neck Surgery Department, UK.

<sup>2</sup> Present address: Ear Nose and Throat Department, UK.

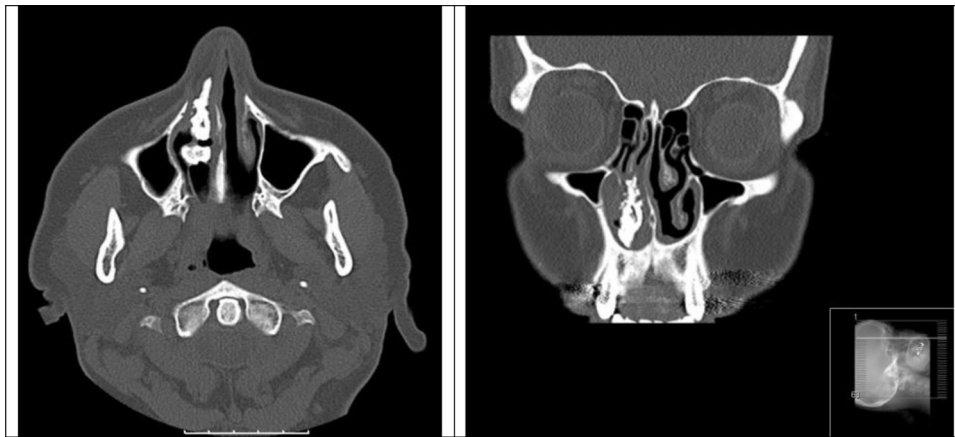

Fig. 2. CT images confirming the rhinolith.

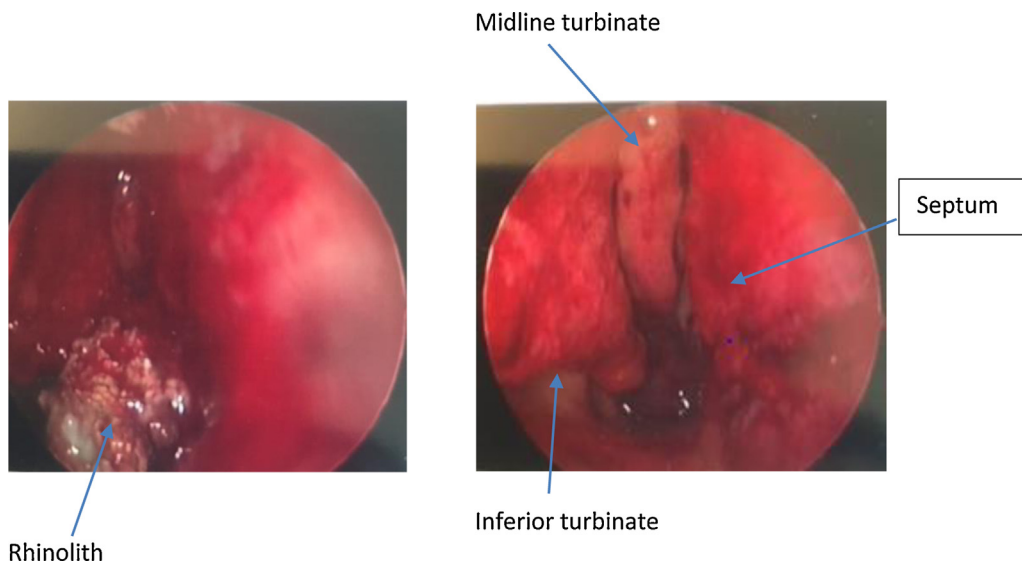


Fig. 3. Intra-operative images of the EUA.

Appropriate referral was made to our ENT colleague who carried out examination under general anaesthetic (EAU) and surgical removal of the rhinolith, Fig. 3.

The patient experienced immediate improvement, and has remained asymptomatic twelve month post-operatively.

### 3. Discussion

Rhinolithiasis, first described by Bartholin in 1654 and originate from the Greek ‘rhino’ (meaning nose) and ‘lithos’ (meaning stone) [3].

A rhinolith is a calcified mass formed within the nasal cavity due to the solidifications of mucus, debris, or foreign objects by gradual accretion of mineral salts. They are uncommon and rarely encountered in clinical practice [4]. This is due to the asymptomatic nature which often remains unnoticed and undetected for many years, until eventual presentation in later years [1–2,5]. The longest asymptomatic rhinolith cited in the literature is one which has been present for 80 years [6]. Nasal foreign bodies are more frequently seen in children and appear to be more common in women [7].

On presentation, the typical symptoms are unilateral nasal obstruction, foul smelling purulent nasal discharge and epistaxis, crusting, swelling of nose or face, anosmia, epiphora and headache

[4]. They may also present as incidental radio-opaque lesions in the nasal maxillary antrum on routine DPT radiograph [8,9].

The pathogenesis of rhinolith remains unclear and they can be exogenous, or endogenous, depending on the nucleus it has encrusted. Exogenous rhinolith occurs around a foreign subject such as a stone, cotton, or bead, and endogenous rhinolith occurs around body tissues, such as a tooth [10]. Symptomatic lesions will require surgical removal.

### 4. Conclusion

This report discusses a differential diagnosis of atypical odontogenic pain in the absence of obvious clinical dental pathology, alerting clinicians to consider rhinolith as a possible cause, and hence appropriate referral for the management of such rare cases.

### Conflict of interest

None.

### Funding

None.

**Ethical approval**

N/A.

**Consent**

This case report does not include any patient identifying features. We have obtained written consent from the patient and will be able to provide it if required.

**Author contributions**

Dr Sandra Girgis: Concept of case report, review of literature, critical revision and final approval.

Mr Leo Cheng: Critical revision and final approval.

Mr Darren Gillett: Final approval.

**Guarantor**

Dr Sandra Girgis.

**References**

- [1] I. Singh, G. Gathwala, S.P.S. Yadav, I. Singh, Rhinolith, *Indian J. Otolaryngol. Head Neck Surg.* 55 (4) (2003) 243–245.
- [2] L.A. Pinto, E.B. Campagnoli, R. de Souza Azevedo, M.A. Lopes, J. Jorge, Rhinoliths causing palatal perforation: case report and literature review, *Oral Surg. Oral Med. Oral Path. Oral Radiol. Endod.* 104 (6) (2007) e42–e46.
- [3] F.A. Shah, S. George, N. Reghunandan, A case presentation of a large rhinolith, *Oman Med. J.* 25 (3) (2010) 230–231.
- [4] M. Dogan, D.O. Dogan, C. Duger, S. Polat, S. Muderris, Recurrent rhinolithiasis: a case report with review of literature, *West Indian Med. J.* 61 (7) (2013) 760–763.
- [5] A. Chatziavramidis, A. Kondylidou-Sidira, A. Stefanidis, S. Soldatou, Longstanding rhinolith leading to anatomical alterations of the ipsilateral inferior nasal meatus and turbinate, *BMJ Case Rep.* (2010).
- [6] M.S. Kermanshahi, P. Jassar, A bolt from the blow: rhinolith in the nose for than 80 years, *BMJ Case Rep.* (2012).
- [7] K. Orhan, D. Kocyigit, R. Kisman, C.S. Paksoy, Rhinolithiasis an uncommon entity of the nasal cavity, *Oral Surg. Oral Med. Oral Path. Oral Radiol. Endod.* 101 (2) (2006) e28–32.
- [8] C.A. Barros, R.R. Martins, J.B. Silva, J.B. Souza, R.F. Ribeiro-Rotta, A.C. Batisht, E.F. Mendonca, Rhinolith a radiographic finding in a dental clinic, *Oral Surg. Oral Med. Oral Path. Oral Radiol. Endod.* 100 (4) (2005) 486–490.
- [9] G.A. Allen, S.L. Liston, Rhinolith unusual appearance on panoramic radiograph, *J. Oral. Surg.* 37 (1) (1979) 54–55.
- [10] A. I. Mastour, A.S. Ghnam, W.M. Zubaidi, Rhinolith: delayed presentation after head trauma – a case report, *Case Rep. Otolaryngol.* (2012).

**Open Access**

This article is published Open Access at [sciedirect.com](http://sciedirect.com). It is distributed under the [IJSCR Supplemental terms and conditions](#), which permits unrestricted non commercial use, distribution, and reproduction in any medium, provided the original authors and source are credited.