

[ CASE REPORT ]

## Resolution of Left Atrial Appendage Thrombus with Apixaban in a Patient with Heart Failure

Takenori Okada, Yuji Takaekou, Naomi Idei, Norihiko Ohashi and Shunichi Kaseda

### Abstract:

The effect of non-vitamin K antagonist oral anticoagulants on left atrial appendage (LAA) thrombus has not been fully elucidated. There are a few reports showing resolution of LAA thrombus with apixaban. An 84-year-old woman was admitted to our hospital due to acute exacerbation of chronic heart failure and marked tachycardia with atrial fibrillation. She had permanent atrial fibrillation and was treated with warfarin; however, transthoracic echocardiography revealed a non-mobile thrombus in the LAA. Therefore, we switched warfarin to apixaban at a dose of 5 mg/day. After two weeks on that therapy, the thrombus in the LAA was successfully resolved.

**Key words:** left atrial appendage thrombus, atrial fibrillation, heart failure, apixaban

(Intern Med 56: 2891-2894, 2017)

(DOI: 10.2169/internalmedicine.8893-17)

### Introduction

In patients with heart failure (HF) with a reduced left ventricular (LV) ejection fraction, the presence of atrial fibrillation (AF) carries a two-fold increased risk of ischemic stroke compared to normal sinus rhythm (1). AF predisposes patients to the development of atrial thrombi, most commonly in the left atrial appendage (LAA), which is the dominant source of embolism (>90%) in nonvalvular AF (2). Warfarin is used to prevent thrombotic complications with AF patients and the resolution of LAA thrombus (3). Apixaban is superior to warfarin in the prevention of thromboembolic complications in patients with AF (4), and a few case reports have described the resolution of LAA thrombus with apixaban (5, 6). However, whether or not apixaban is effective for the treatment of LAA thrombus remains unclear. We herein report a case of heart failure complicated by LAA thrombus that was successfully resolved with apixaban.

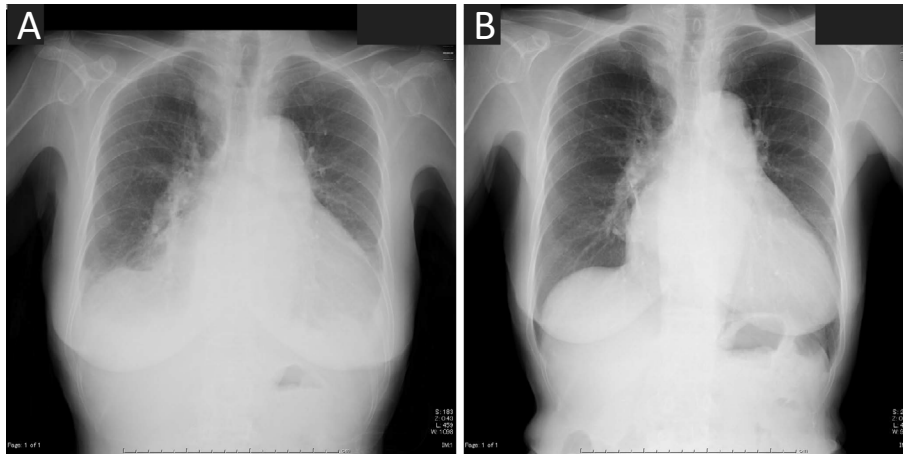
### Case Report

An 84-year-old woman was admitted to our hospital with acute exacerbation of chronic heart failure. On hospital ad-

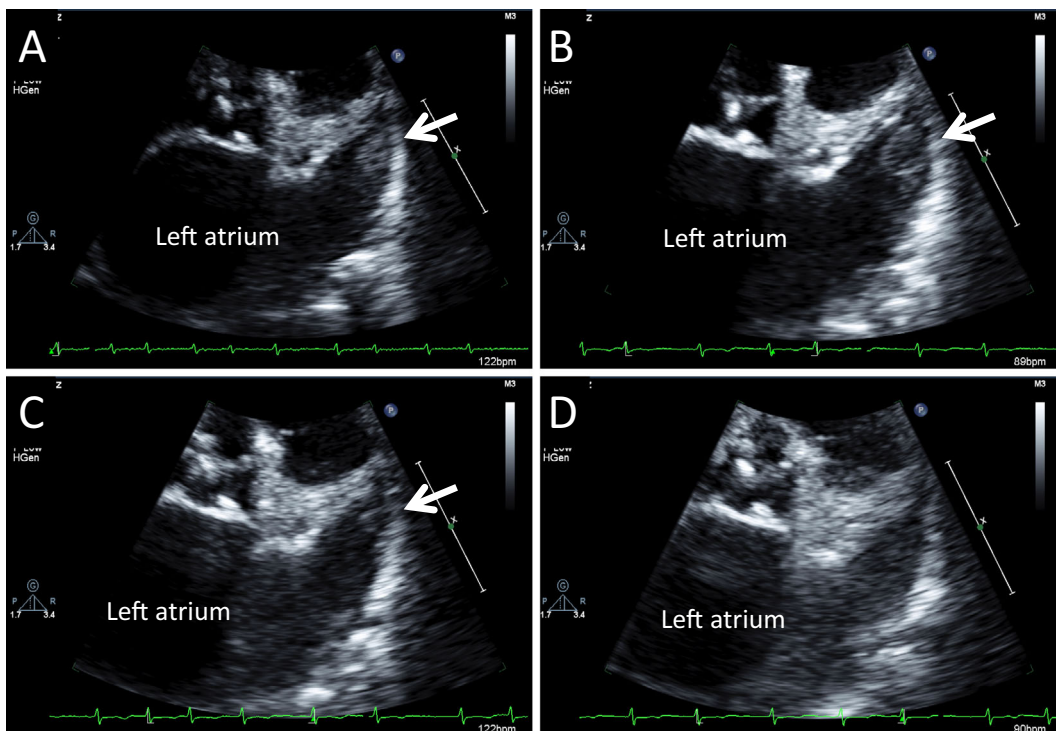
mission, she presented with functional New York Heart Association class IV. Her medical history included hypertension, chronic heart failure, permanent atrial fibrillation, and hyperthyroidism. Given her high thromboembolic risk (CHA<sub>2</sub>DS<sub>2</sub>-VASc score = 5), she had been pretreated with warfarin at a dose of 1 mg/day by her practitioner. In the 3 months prior to hospitalization, her prothrombin time international normalized ratio (PT-INR) values had ranged from 1.11 to 1.15, and her warfarin treatment time in the therapeutic range was 0%.

A physical examination showed coarse crackles over both lungs, an irregular heartbeat, and a grade II/VI systolic murmur at the apex. Chest X-ray revealed cardiomegaly and pulmonary congestion (Fig. 1A). Electrocardiogram showed atrial fibrillation with a ventricular heart rate of 127. Blood tests revealed plasma B-type natriuretic peptide (BNP), 2,000 pg/mL; D-dimer, 3.3 µg/mL; and PT-INR, 1.20. Since the PT-INR was not well controlled at the time of hospital admission, we switched the patient's warfarin to apixaban at 5 mg/day.

Due to her rapid heart rate and congestive heart failure, diuretics and β-blockers were administered, and pimobendan was added. Transthoracic echocardiography (TTE) revealed left ventricular dysfunction with an LV ejection fraction of 31% and left atrial enlargement with an LA diameter of



**Figure 1.** X-ray of the chest. X-ray images of the chest obtained on admission (A) and on day 19 (B).



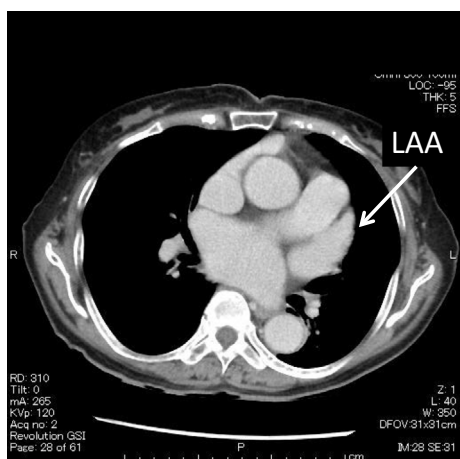
**Figure 2.** The clinical course of the left atrial appendage (LAA) thrombus demonstrated by trans-thoracic echocardiography (TTE). TTE obtained on the day after admission showing a non-mobile thrombus (13.9×11.8 mm) in the LAA (A). Subsequent TTE showed no remarkable change in the thrombus on day 3 after admission (B) but a decrease to 6.2×4.3 mm on day 9 after admission (C) and disappearance after 2 weeks of anticoagulant therapy with apixaban (D). The arrows show the thrombus in the LAA.

60.7 mm. Color flow Doppler echocardiography showed moderate mitral regurgitation (MR) without any findings of rheumatic heart disease, prolapse, or endocarditis. The MR was likely due to LV dilatation (functional MR). TTE also showed a small thrombus (13.9×11.8 mm) in the LAA (Fig. 2A). Myocardial perfusion scintigraphy showed no evidence of ischemia or old myocardial infarction.

TTE three days later showed no remarkable changes in the thrombus in the LAA (Fig. 2B). After 9 days of apix-

aban treatment, TTE showed a decrease in the thrombus size (6.2×4.3 mm) (Fig. 2C). After 2 weeks, we could not detect the thrombus in the LAA by TTE. (Fig. 2D). After 4 days of apixaban treatment, her D-dimer level decreased (1.5 µg/mL) with neither prolongation of PT-INR nor activated partial thromboplastin time.

Her symptoms were ultimately relieved, and the plasma BNP level improved to 744.8 pg/mL on day 14. Chest X-ray on day 19 revealed improvement of the pleural effusion and



**Figure 3.** Axial image obtained on multidetector computed tomography demonstrating complete opacification of the left atrial appendage (LAA) (arrow), which was considered normal without thrombus.

cardiomegaly (Fig. 1B). TTE showed improvement in the LV ejection fraction (44%) on treating her tachycardia and HF with drugs after hospitalization. Despite our explanations about transesophageal echocardiography for the detection of the LAA thrombus, she did not understand the procedure and did not consent to the examination. Accordingly, multidetector computed tomography (MDCT) was performed and demonstrated the complete opacification of the LAA, which was considered normal without thrombus (Fig. 3). In addition, no thromboembolism was detected in the range of the chest to the abdomen by MDCT. During anticoagulant treatment with apixaban, she experienced no serious bleeding complications, systemic embolisms, or strokes.

## Discussion

A reduced LV ejection fraction is independently associated with stroke (7), and the combination of HF with a reduced ejection fraction with AF doubles the risk of stroke compared to AF alone (8). The efficacy of long-term warfarin therapy for the prevention of stroke in patients with AF is well-established (9). However, non-vitamin K antagonist oral anticoagulants (NOACs) have been established as safe and effective first-line medications for the prophylaxis of thromboembolism in patients with AF (10). Approximately 35% of Apixaban for Reduction in Stroke and Other Thromboembolic Events in Atrial Fibrillation (ARISTOTLE) patients had heart failure, defined as an LV ejection fraction  $\leq$  40% or symptomatic heart failure within the previous 3 months (11). That study showed that apixaban at 5 mg twice daily was superior to warfarin in preventing stroke and systemic embolism and was associated with significantly lower rates of major bleeding (11). HF is a recognized risk factor for a reduced time in the therapeutic range, and patients receiving warfarin may be predisposed to a reduced efficacy and increased bleeding risk (12). In the present case, we se-

lected apixaban due to the patient's old age and low body weight.

TTE showed a thrombus in the LAA during warfarin administration. Watanabe et al. reported that LA blood stasis resulting from heart failure led to thrombus formation even under anticoagulant therapy with warfarin (13). In addition, a previous study reported that HF was an independent negative predictor of LA thrombus resolution in patients with AF receiving oral anticoagulation (14).

In our patient, successful thrombus resolution was obtained after 2 weeks on a reduced dose of apixaban at 2.5 mg twice daily. Warfarin therapy in patients with intracardiac thrombus is effective in reducing the size of a thrombus by inducing a relative predominance of plasma fibrinolytic activity over anticoagulation-inhibited thrombin activity (15). However, the effect of NOACs on intracardiac thrombus has not been fully elucidated, and whether or not apixaban therapy is effective in decreasing the size of an intracardiac thrombus is unclear. There have been a few case reports showing the resolution of LAA thrombus after apixaban administration (5, 6), which is likely an effect of apixaban shifting the coagulation/fibrinolysis balance to a relative predominance of fibrinolytic activity. In the present case, the D-dimer levels decreased with the resolution of the LAA thrombus, with neither prolongation of the PT-INR nor the activated partial thromboplastin time.

However, another case report described the occurrence of embolic stroke during apixaban therapy for LAA thrombus (16). It is therefore necessary to monitor patients for thromboembolic complications after the initiation of apixaban for treating pre-existing LAA thrombus. Future studies in a large population should investigate the utility of apixaban and other NOACs in resolving LAA thrombus.

The authors state that they have no Conflict of Interest (COI).

## References

1. Risk factors for stroke and efficacy of antithrombotic therapy in atrial fibrillation. Analysis of pooled data from five randomized controlled trials. *Arch Intern Med* **154**: 1449-1457, 1994.
2. Al Saady NM, Obel OA, Camm AJ. Left atrial appendage: structure, function, and role in thromboembolism. *Heart* **82**: 547-554, 1999.
3. The European Atrial Fibrillation trial Study group. Optimal oral anticoagulant therapy in patients with nonrheumatic atrial fibrillation and recent cerebral ischemia. *N Engl J Med* **333**: 5-10, 1995.
4. Ruff CT, Giugliano RP, Braunwald E, et al. Comparison of the efficacy and safety of new oral anticoagulants with warfarin in patients with atrial fibrillation: a meta-analysis of randomized trials. *Lancet* **383**: 955-962, 2014.
5. Kawakami T, Kobayakawa H, Ohno H, Tanaka N, Ishihara H. Resolution of left atrial appendage thrombus with apixaban. *Thromb J* **11**: 26, 2013.
6. Dobashi S, Fujino T, Ikeda T. Use of apixaban for an elderly patient with left atrial thrombus. *BMJ Case Rep* (in press).
7. Hays AG, Sacco RL, Rundek T, et al. Left ventricular systolic dysfunction and the risk of ischemic stroke in a multiethnic population. *Stroke* **37**: 1715-1719, 2006.

8. Agarwal M, Apostolakis S, Lane DA, Lip GY. The impact of heart failure and left ventricular dysfunction in predicting stroke, thromboembolism, and mortality in atrial fibrillation patients: a systemic review. *Clin Ther* **36**: 1135-1144, 2014.
9. Hart RG, Pearce LA, Aguilar MI. Meta-analysis: antithrombotic therapy to prevent stroke in patients who have nonvalvular atrial fibrillation. *Ann Intern Med* **146**: 857-867, 2007.
10. January CT, Wann LS, Alpert JS, et al. 2014 AHA/ACC/HRS guideline for the management of patients with atrial fibrillation: executive summary: a report of the American College of Cardiology/American Heart Association Task Force on practice guidelines and the Heart Rhythm Society. *Circulation* **130**: 2071-2104, 2014.
11. Granger CB, Alexander JH, McMurray JJ, et al. Apixaban versus warfarin in patients with atrial fibrillation. *New Engl J Med* **365**: 806-817, 2011.
12. Witt DM, Celate T, Clark NP, et al. Warfarin Associated Research Projects and other Endeavors (WARPED) Consortium. Outcomes and predictors of very stable INR control in prevalent warfarin users. *Blood* **114**: 952-956, 2009.
13. Watanabe A, Yamashita N, Yamashita T. Blood stasis secondary to heart failure forms warfarin-resistant left atrial thrombus. *Int Heart J* **55**: 506-511, 2014.
14. Kowalczyk E, Kasprzak JD, Lipiec P. Heart failure as an independent predictor of thrombus persistence in nonvalvular atrial fibrillation: a transesophageal echocardiography-based study. *Pol Arch Med Wewn* **125**: 358-362, 2015.
15. Yasaka M, Yamaguchi T, Misashita T, Tsuchiya T. Regression of intracardiac thrombus after embolic stroke. *Stroke* **221**: 1540-1544, 1990.
16. Ohyagi M, Nakamura K, Watanabe M, Fujigasaki H. Embolic stroke during apixaban therapy for left atrial appendage thrombus. *J Stroke Cerebrovasc Dis* **24**: e101-e102, 2015.

The Internal Medicine is an Open Access article distributed under the Creative Commons Attribution-NonCommercial-NoDerivatives 4.0 International License. To view the details of this license, please visit (<https://creativecommons.org/licenses/by-nc-nd/4.0/>).