


# Routine Bilateral Neck Exploration and Four-Gland Dissection Remains Unnecessary in Modern Parathyroid Surgery

Nathaniel J. Walsh, MD ; Brian T. Sullivan, BS; William S. Duke, MD; David J. Terris, MD

**Objective:** Recent advances in preoperative imaging techniques and intraoperative parathyroid hormone (ioPTH) assays have made single-gland, minimally invasive parathyroidectomy (MIP) the preferred treatment option for most patients with primary hyperparathyroidism (pHPT). Despite this evolution, a recommendation for bilateral neck exploration (BNE) with four-gland dissection in all patients has recently been advocated by a parathyroid surgical group. The current study compares the long-term outcomes of MIP with those of conventional BNE with four-gland dissection in patients with pHPT.

**Methods:** In order to objectively assess a recommendation in the literature that universal BNE with four-gland dissection is advisable, all patients undergoing an initial MIP with ioPTH assessment for pHPT in a tertiary endocrine practice during a 10-year period were reviewed. The cure rates from this procedure were compared with published results of conventional BNE with four-gland dissection.

**Results:** Of the 561 patients undergoing parathyroidectomy during the study period, 337 had initial surgery for pHPT; 282 of these patients met inclusion criteria and 212 had sufficient follow-up data available. A single adenoma was identified in 87.3% of cases. Preoperative imaging studies were co-localizing in 148 (69.8%), and 127 (85.8%) of these patients with co-localizing imaging required only single-gland surgery. Imaging studies did not co-localize in 49 patients, yet 32 (65.3%) of these patients were still cured with unilateral surgery. The cure rate for patients undergoing MIP was 98.6%, with a long-term recurrence rate of <2%.

**Conclusion:** When coupled with the ioPTH assay, patients with at least one preoperative localizing study can undergo MIP and anticipate a cure rate of 99%, which is as good as or better than the published rates for conventional BNE with four-gland dissection. With unilateral surgery, the risks of permanent hypoparathyroidism and airway obstruction from bilateral vocal fold paralysis are completely eliminated. Therefore, despite recommendations to the contrary, most patients with pHPT should not have a planned four-gland exploration.

**Level of Evidence:** III or IV

**Key Words:** Parathyroidectomy, parathyroid surgery, minimally invasive parathyroidectomy, bilateral neck exploration, minimally invasive parathyroid surgery, primary hyperparathyroidism.

## INTRODUCTION

Primary hyperparathyroidism (pHPT), which accounts for 90% of hypercalcemia seen in the outpatient setting, results from a single hyperfunctioning adenoma in approximately 85% of patients.<sup>1,2</sup> pHPT can only be cured by surgical removal of all hyperfunctional tissue. Although the majority of patients have only one abnormal parathyroid gland, patients with pHPT historically underwent a bilateral neck exploration (BNE) with identification of all four parathyroid glands. This approach was required to identify which of the parathyroid glands was clinically abnormal and to ensure that additional abnormal glands were not overlooked. BNE with four-gland dissection, however, required a large cosmetically less favorable incision,

exposed both recurrent laryngeal nerves (RLNs) to potential iatrogenic injury, and subjected the patient to the risk of permanent hypoparathyroidism.<sup>3,4</sup>

More recently, parathyroid surgery has evolved to include minimally invasive approaches that focus the exploration on a single gland or side of the neck. These operations, which can be performed through small incisions on an outpatient basis with a very low complication profile, have been facilitated by a number of technological developments.<sup>5</sup> The two advancements that have been most critical to the implementation and success of minimally invasive parathyroid surgery are preoperative imaging techniques, such as <sup>99m</sup>Tc-sestamibi (sestamibi) and high-resolution ultrasound (US), and the emergence of rapid intraoperative parathyroid hormone (ioPTH) assays. Preoperative localization studies allow the surgeon to focus the operation on a specific gland or side of the neck, while the ioPTH assay provides biochemical assurance that all hyperfunctional tissue has been removed, obviating the need to examine the other glands.<sup>6-9</sup>

Multiple studies have shown that image-guided, ioPTH-assisted minimally invasive parathyroidectomy (MIP) results in cure rates equivalent to that of conventional BNE with four-gland dissection.<sup>10-12</sup> Despite this, a parathyroid surgical group based, which had previously been

This is an open access article under the terms of the Creative Commons Attribution-NonCommercial-NoDerivs License, which permits use and distribution in any medium, provided the original work is properly cited, the use is non-commercial and no modifications or adaptations are made.

From the Department of Otolaryngology–Head and Neck Surgery (N.J.W., B.T.S., W.S.D., D.J.T.), Augusta University, Augusta, Georgia

Send correspondence to David J. Terris, MD, FACS, FACE, Surgical Director, AU Thyroid and Parathyroid Center, Regents Professor of Otolaryngology and Endocrinology, Augusta University, 1120 Fifteenth Street, BP-4109, Augusta, Georgia 30912-4060. Email: dtorris@augusta.edu

DOI: 10.1002/liv.2.223

staunch proponents of minimally invasive parathyroid surgery (calling “bilateral neck exploration for all parathyroid patients an operation for the history books”), changed their approach in 2012 and now are dogmatic advocates for universal BNE with four-gland dissection.<sup>13,14</sup> This change was based on the unacceptably high long-term failure rate of 6% associated with their unusual MIP protocol, which does not incorporate the use of an intraoperative PTH assay and therefore predictably fails to identify multiglandular disease. Although the more typical MIP technique has yielded excellent short-term cure rates, several studies have cited the need for more extended follow-up to confirm the durability of the results.<sup>15,16</sup> We therefore analyzed 10 years of MIP data to assess the long-term outcomes of this procedure as compared to published long-term cure rates of BNE with four-gland dissection.<sup>2,8,12,17</sup>

## METHODS

A prospectively maintained database of all patients who had a parathyroidectomy by a single surgeon at our tertiary endocrine surgery practice was interrogated, and every patient with sporadic pHPT who underwent initial parathyroid surgery between 2003 and 2013 was identified. Patients were included in the study cohort if they had at least one preoperative localization study (US or sestamibi) and if they were scheduled for minimally invasive parathyroid surgery, defined as a unilateral or focused single gland exploration. Patients diagnosed with renal hyperparathyroidism, parathyroid carcinoma, lithium-induced HPT multiple endocrine neoplasia (MEN), and those undergoing re-operative parathyroidectomy or concurrent thyroid surgery were excluded from analysis.

All patients included in the study cohort underwent a parathyroidectomy with anticipation of utilizing a focused approach (MIP). A baseline ioPTH level was obtained using an 8-minute rapid assay (Future Diagnostics, Wijchen, the Netherlands) after anesthesia was induced but before the skin incision was made, and the abnormal gland predicted by preoperative imaging was then removed. ioPTH values were analyzed, with levels acquired at 5, 10, and occasionally 15 minutes after gland excision. If the ioPTH value

decreased by >50% of the baseline level and fell to within the normal range ( $\leq 65$  pg/mL) the operation was usually concluded. If these criteria were not met, the patient was suspected to have additional hyperfunctional parathyroid tissue, and a bilateral exploration was performed through the same incision. In circumstances where the ioPTH kinetics were equivocal, additional levels were often obtained prior to pursuing additional exploration as some patients manifest a slow PTH degradation profile. Patients undergoing either MIP or bilateral neck exploration were discharged on the day of surgery and without a drain.

Patients with normal calcium values at the time of their postoperative follow-up visit approximately one month after surgery were considered cured. Persistent hyperparathyroidism was defined as hypercalcemia observed at any point within six months of surgery, while recurrent hyperparathyroidism was defined as hypercalcemia occurring more than 6 months after surgery and after achieving postoperative eucalcemia. The cure rate in MIP patients was compared to the published cure rates for patients undergoing planned BNE with four-gland dissection. Postoperative complications including temporary and permanent recurrent laryngeal nerve (RLN) injury and transient and permanent hypoparathyroidism were evaluated. Hypoparathyroidism was defined as a low parathyroid hormone level and a corresponding serum calcium level  $\leq 8.5$  mg/dL with a requirement for calcium replacement with or without calcitriol. Hypoparathyroidism was classified as temporary if it resolved within 12 months after surgery or permanent if it persisted beyond this timeframe.

All statistical calculations were performed using JMP Pro 11 (SAS Institutes, Inc.). Nominal data were analyzed using frequency counts and percentages. Continuous data that were approximately normally distributed were evaluated using means and standard deviations (SDs), while those that were markedly skewed were analyzed using medians and interquartile ranges (IQRs). *P*-values of  $< .05$  were considered statistically significant, and the 95% confidence intervals (CI) and corresponding standard errors are also reported where appropriate. This study was approved by the Augusta University Institutional Review Board (Pro00000155).

## RESULTS

During the study period 561 patients underwent parathyroid surgery. Of these, 337 had initial surgery for pHPT and 282 met inclusion criteria. Due to the tertiary referral nature of our practice, follow-up data were available for 212 (75.2%) of these patients who therefore comprised the study population.

The majority of patients undergoing MIP were female (167, 78.8%) and Caucasian (144, 67.9%) (Table I). The mean age was  $58.7 \pm 14.0$  years. The mean follow-up time was  $34.4 \pm 25.8$  months (range 1–120 months), with 182 (85.8%) patients having postoperative follow-up for at least 12 months (Table II). The mean preoperative calcium was  $11.0 \pm 0.7$  mg/dL, and the mean postoperative calcium was  $9.6 \pm 0.4$  mg/dL ( $P < .001$ ) (Table I).

Sestamibi, which was performed in 209 (98.6%) patients, was localizing in 181 (86.6%). Ultrasound was

TABLE I.  
Patient Demographics.

Patient Demographics	
Age (mean $\pm$ SD, years)	58.7 $\pm$ 14.0 (range 22–91 years)
Female gender (n, %)	167, 78.8
Race	
Caucasian (n, %)	144, 67.9
African American (n, %)	62, 29.2
Other (n, %)	6, 2.8
Preoperative calcium (mean $\pm$ SD, mg/dL)	11.0 $\pm$ 0.7
Postoperative calcium (mean $\pm$ SD, mg/dL)	9.6 $\pm$ 0.4
Multi-gland disease (n, %)	27, 12.7

SD = standard deviation.

TABLE II.  
Minimally Invasive Parathyroidectomy Outcomes.

Minimally Invasive Parathyroidectomy Outcomes	
Mean follow-up length (n ± SD, months)	34.4 ± 25.8 (range 1–120 months)
Cure rate (n, %)	209, 98.6
Persistent hyperparathyroidism (n, %)	3, 1.4
Recurrent hyperparathyroidism (n, %)	4, 1.9

SD = standard deviation.

performed in 200 (94.3%) patients and was localizing in 174 (87.0%). Both studies were performed in 197 (93.0%) patients and were co-localizing in 148 (75.1%) patients. Single-gland disease was confirmed in 171 (80.7%) patients with at least one localizing study and in 127 (85.8%) of the 148 patients with co-localizing studies. Multi-gland disease was identified in 27 (12.7%) patients, including 21 (14.1%) of the patients with co-localizing imaging studies. Preoperative imaging accurately identified multi-gland disease in 8 (29.6%) of the 27 cases where more than one gland was abnormal.

The cure rate after MIP was 98.6% (209 of 212 patients) (Table II). Of the 127 patients with co-localizing studies who had single-gland surgery, 125 (98.4%) were cured. All 21 patients with co-localizing studies and multi-gland disease were cured. Importantly, although sestamibi and US did not co-localize in 49 (24.7%) of 198 patients who had both studies performed, 32 (65.3%) of these patients were still able to be cured with unilateral surgery. The rate of postoperative hypocalcemia at the time of follow-up was 0 of 212 patients (0%). No patients (0 of 212) had temporary or permanent recurrent laryngeal nerve injury. During the follow-up period, four patients (1.9%) developed

recurrent disease. The cure rates for a MIP that incorporated both preoperative imaging and intraoperative PTH assessment were as good as or better than the mean published rates for planned BNE with four-gland dissection (Table III; Fig. 1).<sup>14,18–27</sup>

The ioPTH was an important confirmatory adjunct in the successful operations (209 of 212). Additionally, in the three patients with persistent disease in which no adenoma was found the ioPTH assay accurately confirmed intraoperatively that the exploration was not successful.

## DISCUSSION

Bilateral neck exploration was required in the early surgical management of pHPT because there was no other method to determine if more than one gland was abnormal without physically exposing and visually inspecting all four parathyroid glands. However, this approach relied on a clinical assessment of the parathyroid glands, rather than biochemical analysis, and was associated with a high risk of complications such as hypocalcemia and RLN injury.<sup>4</sup>

Advancements in preoperative imaging modalities have made targeted MIP possible, while the development of the rapid ioPTH assay has allowed surgeons to biochemically confirm a cure intraoperatively before terminating the procedure. In a recent literature review, MIP was shown to be a cost-effective alternative to conventional parathyroid surgery performed as a BNE with four-gland dissection.<sup>28</sup> MIP is associated with a reduced hospital stay, increased patient satisfaction, and improved postoperative cosmesis due to a smaller incision.<sup>17,28</sup> There is substantially less scar tissue to contend with if further central compartment surgery is later required.<sup>17</sup> Most importantly, MIP obviates the need to explore all four parathyroid glands and expose both

TABLE III.  
Comparison of Cure Rates in Literature for Minimally Invasive Parathyroidectomy (MIP) and Bilateral Neck Exploration with Four-Gland Dissection (BNE).

Parathyroidectomy Cure Rates by Operative Approach						
Author	Year	Journal	Patients (n)	Surgery	Mean Follow-Up (months)	Cure rate (%)
Joliat et al. <sup>18</sup>	2015	Langenbecks Arch Surg	118	MIP	39.6	95
Reilly et al. <sup>19</sup>	2014	ANZ J Surg	189	MIP	6	97.4
Lee et al. <sup>20</sup>	2014	Ann Surg Onc	567	MIP	13	96.6
Karakas et al. <sup>21</sup>	2014	World J Surg	265	MIP	33.4	98.9
Leder et al. <sup>22</sup>	2013	Ann Surg	104	MIP	27	100
Venkat et al. <sup>23</sup>	2012	World J Surg	200	MIP	37	97
Norman et al. <sup>14</sup>	2012	Am Coll Surg	15000	MIP	120	94
Udelsman et al. <sup>24</sup>	2011	Ann Surg	1037	MIP	37	99.4
Bumpous et al. <sup>25</sup>	2009	Laryngoscope	240	MIP	12 <sup>1</sup>	97
Hughes et al. <sup>26</sup>	2013	Surg	156	BNE	25	97
Beyer et al. <sup>27</sup>	2007	Am J Surg	49	BNE	11.9	95.9
Karakas et al. <sup>21</sup>	2014	World J Surg	1035	BNE	33.4	98.3
Udelsman et al. <sup>24</sup>	2011	Ann Surg	613	BNE	37	97.1

SD = standard deviation.

<sup>1</sup> Inclusion criteria for this study required a postoperative calcium level be obtained more than 12 months postoperatively, but no mean follow-up duration data was provided.

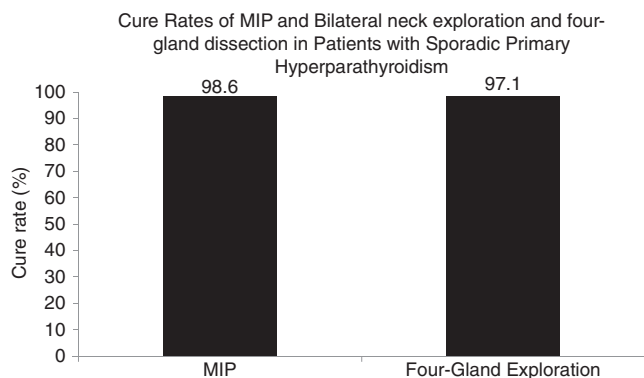


Fig. 1. Cure rate after minimally invasive parathyroidectomy (MIP) in the current study population compared to the mean published cure rate after bilateral neck exploration with four-gland dissection (from Table III).

RLNs, thereby eliminating the possibility of iatrogenic hypoparathyroidism and airway obstruction from bilateral RLN injury. Due to these advantages, MIP has become a favored surgical technique among most high-volume parathyroid surgeons for the treatment of pHPT. Despite the widespread adoption of MIP, a parathyroid surgical group that initially was a staunch proponent for MIP recently began to dogmatically advocate for universal four-gland surgery because they identified a high long-term failure rate with their unusual MIP approach.<sup>14</sup> Patients are therefore often puzzled by widespread marketing and internet advertising that promotes bilateral neck surgery in all patients. There are several factors that would explain why the long-term success rates (94%) that were reported were so much lower than those achieved by other experienced parathyroid surgeons. The principal concern of that group has been completing the operation as fast as possible (as is evident in their marketing materials on parathyroid.com, in their letters to referring physicians, and in their publications). They have therefore specifically spurned the use of intraoperative PTH monitoring (which adds a minimum of 13–18 minutes to a successful single-gland operation).<sup>14,29</sup> Instead they had embraced a poorly studied and irreproducible ratio of radioactivity of a putative parathyroid adenoma compared with randomly chosen background tissues in the neck of patients who underwent pre-operative injection with Tc-99m sestamibi. The study justifying this radioguided technique contained no controls and no systematic algorithm by which non-parathyroid tissue specimens were excised and tested for radioactivity.<sup>30</sup> Perhaps most troubling was the complete absence of double adenomas in their reported experience of 345 patients. Others have attempted to replicate their findings without success.<sup>31</sup> A naïve belief that the ratio associated with one single gland could rule out the presence of additional abnormal glands led the surgeons to prematurely abort the operation in nearly 1000 of their patients who were harboring additional hyperfunctional parathyroid tissue, which would have been readily apparent had they been willing to utilize intraoperative PTH testing. So fervent was their conviction of the robustness of this since disproven method that they announced in 2002 that “bilateral neck exploration for all parathyroid patients is an operation for the history books”.<sup>13</sup>

Furthermore, they reported that the high rate of single-gland disease mandates that “this technique is unnecessarily extensive for 90% or more of patients”.<sup>13</sup> Remarkably, when confronted with the reality that their unusual and flawed technique was resulting in hundreds of failed operations (6% failure rate), rather than acknowledging that failing to use the ioPTH results in missed double adenomas that would otherwise be identified, they instead chose to systematically subject all of their patients to the higher risks necessarily associated with BNE and four-gland dissection.<sup>14</sup> In keeping with the fixation on doing the operation quickly, they explained their decision was based on the ability to complete a bilateral exploration without adding more than an additional 6 minutes of operative time.<sup>14</sup>

As the results of our study show, minimally invasive surgery guided by preoperative imaging and paired with intraoperative PTH confirmation that all hyperfunctional tissue has been removed results in a cure rate equivalent to BNE with four-gland dissection (Fig. 1).

An important take-home message from our data, however, is that even in a group of highly selected, imaging-positive patients, double adenomas (and to a lesser extent, four-gland hyperplasia) were common (12.7%). This high prevalence of double adenomas, coupled with their poor understanding of the nature of this condition, doomed the approach to failure. Our data is completely consistent with the findings from large systematic reviews and meta-analyses evaluating MIP and bilateral neck exploration (BNE) including one completed by Ospina and colleagues in 2016. In their meta-analysis of 88 published studies, cure rates were reported to be 97% for MIP and 98% for BNE with four-gland dissection.<sup>12</sup> Of note, hypocalcemia occurred in 14% of BNE cases versus 2.3% in MIP cases, and there was also a statistically significant lower risk of laryngeal nerve injury with MIP compared to BNE (0.3% vs. 0.9%). Consequently, the so-called minimally invasive radioguided parathyroidectomy involving bilateral neck exploration and four-gland dissection (MIRP) is a bad operation for most patients because of the necessarily increased risk of laryngeal nerve injury and hypocalcemia. Conversely, radioguided surgery with focused exploration and without the use of ioPTH is similarly not advisable, as was concluded many years ago by Chen and his colleagues.<sup>32</sup>

Therefore, we recommend that patients with sporadic pHPT and at least one preoperative localizing study undergo a MIP with intraoperative assessment of PTH levels by an experienced parathyroid surgeon who is familiar with the use and the nuances of the rapid ioPTH assay and is prepared to extend the operation to a bilateral exploration in up to 15% of patients as needed based on the PTH findings. Despite the benefits of MIP over conventional bilateral neck exploration, four-gland surgery should still be employed in patients whose conditions are associated with multi-gland disease, such as multiple endocrine neoplasia, renal hyperparathyroidism, or lithium-induced hyperparathyroidism, and in most patients with non-localizing imaging studies.

The current study suffers from the usual limitations of a retrospective analysis including the potential for selection bias, evolution of the preferred imaging

modality, surgical learning curve and limited sample size with incomplete follow-up.

## CONCLUSION

Patients with sporadic pHPT and at least one localizing imaging study can undergo MIP with ioPTH assessment and expect a durable cure rate of nearly 99%. This rate is as good as or better than the published cure rates for bilateral neck exploration with four-gland dissection. This approach eliminates the need to expose both recurrent laryngeal nerves and all four parathyroid glands to potential injury, which is higher with BNE compared to MIP. The benefits of using intraoperative radioactive guidance, the so-called MIRP, have not been able to be reproduced, and it is not clear if there is any value to its use. We therefore conclude that most patients with pHPT can benefit from the advantages of minimally invasive parathyroidectomy and do not require a planned bilateral neck exploration and four-gland dissection.

## BIBLIOGRAPHY

1. Yeh MW, Ituarte PHG, Zhou HC, et al. Incidence and prevalence of primary hyperparathyroidism in a racially mixed population. *J Clin Endocrinol Metab* 2013;98(3):1122–1129.
2. Augustine MM, Bravo PE, Zeiger MA. Surgical treatment of primary hyperparathyroidism. *Endocr Pract* 2011;17(Suppl 1):75–82.
3. Brunaud L, Li Z, Van Den Heede K, et al. Endoscopic and robotic parathyroidectomy in patients with primary hyperparathyroidism. *Gland Surg* 2016;3(3):352–360.
4. Riss P, Kammer M, Selberherr A, Scheuba C, Niederle B. Morbidity associated with concomitant thyroid surgery in patients with primary hyperparathyroidism. *Ann Surg Oncol* 2015;22(8):2707–2713.
5. Flynn MB, Quayyum M, Goldstein RE, Bumpous JM. Outpatient parathyroid surgery: ten-year experience: is it safe? *Am Surg* 2015;81(5):472–477.
6. Opoku-Boateng A, Bolton JS, Corsetti R, Brown RE, Oxner C, Fuhrman GM. Use of a sestamibi-only approach to routine minimally invasive parathyroidectomy. *Am Surg* 2013;79(8):797–801.
7. van Ginhoven TM, Morks AN, Schepers T, de Graaf PW, Smit PC. Surgeon-performed ultrasound as preoperative localization study in patients with primary hyperparathyroidism. *Eur Surg Res* 2011;47(2):70–74.
8. Fraker DL, Harsono H, Lewis R. Minimally invasive parathyroidectomy: benefits and requirements of localization, diagnosis, and intraoperative PTH monitoring. long-term results. *World J Surg* 2009;33(11):2256–2265.
9. Chen H, Pruhs Z, Starling JR, Mack E. Intraoperative parathyroid hormone testing improves cure rates in patients undergoing minimally invasive parathyroidectomy. *Surgery* 2005;138(4):583–587.
10. Nagar S, Reid D, Czako P, Long G, Shanley C. Outcomes analysis of intraoperative adjuncts during minimally invasive parathyroidectomy for primary hyperparathyroidism. *Am J Surg* 2012;203(2):177–181.
11. Schneider DF, Mazeh H, Sippel RS, Chen H. Is minimally invasive parathyroidectomy associated with greater recurrence compared to bilateral exploration?. Analysis of more than 1,000 cases. *Surgery* 2012;152(6):1008–1015.
12. Singh Ospina NM, Rodriguez-Gutierrez R, Maraka S, et al. Outcomes of parathyroidectomy in patients with primary hyperparathyroidism: a systematic review and meta-analysis. *World J Surg* 2016;40(10):2359–2377.
13. Denham DW, Norman J. Bilateral neck exploration for all parathyroid patients is an operation for the history books. *Surgery* 2003;134(3):513.
14. Norman J, Lopez J, Politz D. Abandoning unilateral parathyroidectomy: why we reversed our position after 15,000 parathyroid operations. *J Am Coll Surg* 2012;214(3):260–269.
15. Hughes DT, Miller BS, Park PB, Cohen MS, Doherty GM, Gauger PG. Factors in conversion from minimally invasive parathyroidectomy to bilateral parathyroid exploration for primary hyperparathyroidism. *Surgery* 2013;154(6):1428–1434; discussion 1434–1435.
16. Bergenfelz AO, Jansson SK, Wallin GK, et al. Impact of modern techniques on short-term outcome after surgery for primary hyperparathyroidism: a multicenter study comprising 2,708 patients. *Langenbecks Arch Surg* 2009;394(5):851–860.
17. Kunstman JW, Udelsman R. Superiority of minimally invasive parathyroidectomy. *Adv Surg* 2012;46:171–189.
18. Joliat GR, Demartines N, Portmann L, Boubaker A, Matter M. Successful minimally invasive surgery for primary hyperparathyroidism: influence of preoperative imaging and intraoperative parathyroid hormone levels. *Langenbecks Arch Surg* 2015;400(8):937–944.
19. Reilly DJ, Chew GL, Eckhaus J, Smoll NR, Farrell SG. Outcomes for minimally invasive parathyroidectomy: widening inclusion criteria based on preoperative imaging results. *ANZ J Surg* 2016;86(9):701–705.
20. Lee S, et al. Operative failure in minimally invasive parathyroidectomy utilizing an intraoperative parathyroid hormone assay. *Ann Surg Oncol* 2014;21(6):1878–1883.
21. Karakas E, Schneider R, Rothmund M, Bartsch DK, Schlosser K. Initial surgery for benign primary hyperparathyroidism: an analysis of 1,300 patients in a teaching hospital. *World J Surg* 2014;38(8):2011–2018.
22. Leder SB, Donovan P, Acton LM, et al. Laryngeal physiology and voice acoustics are maintained after minimally invasive parathyroidectomy. *Ann Surg* 2013;257(5):968–970.
23. Venkat R, Kouniavsky G, Tufano RP, Schneider EB, Dackiw AP, Zeiger MA. Long-term outcome in patients with primary hyperparathyroidism who underwent minimally invasive parathyroidectomy. *World J Surg* 2012;36(1):55–60.
24. Udelsman R, Lin Z, Donovan P. The superiority of minimally invasive parathyroidectomy based on 1650 consecutive patients with primary hyperparathyroidism. *Ann Surg* 2011;253(3):585–591.
25. Bumpous JM, Goldstein RL, Flynn MB. Surgical and calcium outcomes in 427 patients treated prospectively in an image-guided and intraoperative PTH (IOPTH) supplemented protocol for primary hyperparathyroidism: Outcomes and opportunities. *Laryngoscope* 2009;119(2):300–306.
26. Hughes DT, Miller BS, Park PB, Cohen MS, Doherty GM, Gauger PG. Factors in conversion from minimally invasive parathyroidectomy to bilateral parathyroid exploration for primary hyperparathyroidism. *Surgery* 2013;154(6):1428–1435.
27. Beyer TD, Solorzano CC, Starr F, Nilubol N, Prinz RA. Parathyroidectomy outcomes according to operative approach. *Am J Surg* 2007;193(3):368–373.
28. Zanocco K, Heller M, Sturgeon C. Cost-effectiveness of parathyroidectomy for primary hyperparathyroidism. *Endocr Pract* 2011;17(Suppl 1):69–74.
29. Norman J, Politz D. 5,000 parathyroid operations without frozen section or PTH assays: measuring individual parathyroid gland hormone production in real time. *Ann Surg Oncol* 2009;16(3):656–666.
30. Murphy C, Norman J. The 20% rule: a simple, instantaneous radioactivity measurement defines cure and allows elimination of frozen sections and hormone assays during parathyroidectomy. *Surgery* 1999;126(6):1023–1029.
31. Hinson AM, Lawson BR, Franco AT, Stack BC. Association of parathyroid gland biopsy excision technique with ex-vivo radiation counts during radioguided parathyroid surgery. *JAMA Otolaryngol Head Neck Surg* 2017;143(6):595–600.
32. Chen H, Mack E, Starling JR. A comprehensive evaluation of perioperative adjuncts during minimally invasive parathyroidectomy: which is most reliable? *Ann Surg* 2005;242(3):375.