

Comparison of Minimal Skin Incision Technique in Living Kidney Transplantation and Conventional Kidney Transplantation

Sang-Dong Kim, Ji-Il Kim, In-Sung Moon, Sun-Cheol Park

Department of Surgery, Division of Vascular and Transplant Surgery, College of Medicine, The Catholic University of Korea, Seoul 137-040, Korea

Abstract

Background: Recently, the most common incision for kidney transplantation (KT) is an inverted J-shaped incision known as the “hockey-stick.” However, demands for minimally invasive surgery in KT are increasing as in other various fields of surgery. Hence, we evaluated whether there is difference between minimal skin incision technique in kidney transplantation (MIKT) and conventional KT (CKT).

Methods: Between June 2006 and March 2013, a total of 452 living kidney transplant patients were enrolled. The MIKT group included 17 young unmarried women whose body mass index was $<25 \text{ kg/m}^2$ and had no anatomic variation. The CKT group included 435 patients. The MIKT operation technique restricted to the 10 cm-sized skin incision in the lower right abdomen from laterally below the anterior superior iliac spine to the midline just above the pubis was performed. We compared the baseline clinical characteristics and postoperative results between two groups. For proper comparison, propensity score matching was implemented.

Results: There was no difference in graft function, survival, and postoperative complication rate between MIKT and CKT groups (all $P > 0.05$). The 5-year graft survival was 92.3% and 85.7% in MIKT and CKT groups, respectively ($P = 0.786$).

Conclusions: Our results indicated that MIKT showed more favorable cosmetic results, and there were no statistical differences in various postoperative factors including graft function, survival, and complications compared with CKT. Hence, we suggested that MIKT is an appropriate method for selected patients in living KT.

Key words: Kidney Transplantation; Minimal Skin Incision; Conventional Kidney Transplantation

INTRODUCTION

Nowadays, minimally invasive surgery (MIS) has replaced many open, conventional operations and is now important in almost every facet of abdominal surgery.^[1] Within the field of transplantation, laparoscopic fenestration of posttransplant lymphoceles was first described in 1991,^[2] and laparoscopic living donor nephrectomy has lately gained widespread acceptance since the first procedure was performed in 1995.^[3,4] More recent advances utilizing a “hand-assisted” laparoscopic approach may further improve results, providing an additional margin of safety for the procedure.^[5] However, there were only limited reports about a minimal skin incision technique in kidney transplantation (MIKT) in the literature.^[4,5] The shortage of MIKT publications in the literature was a bit surprising for several reasons.^[4] First, because

MIS procedures have been described for all kinds of sophisticated procedures.^[4] Second, because the potential advantages of reducing incision/tissue trauma are probably of greater benefit in immunosuppressed patients, with significantly impaired wound healing.^[4] Therefore, we evaluated whether there is difference between MIKT and conventional kidney transplantation (CKT) to identify the effectiveness of MIKT.

Address for correspondence: Prof. Sun-Cheol Park, Department of Surgery, Division of Vascular and Transplant Surgery, College of Medicine, The Catholic University of Korea, 65-1 Geumo-dong, Uijeongbu-si, Gyeonggi-do 480-717, Seoul 137-040, Korea
E-Mail: sun60278@catholic.ac.kr

This is an open access article distributed under the terms of the Creative Commons Attribution-NonCommercial-ShareAlike 3.0 License, which allows others to remix, tweak, and build upon the work non-commercially, as long as the author is credited and the new creations are licensed under the identical terms.

For reprints contact: reprints@medknow.com

© 2016 Chinese Medical Journal | Produced by Wolters Kluwer - Medknow

Received: 15-12-2015 **Edited by:** Xin Chen

How to cite this article: Kim SD, Kim JI, Moon IS, Park SC. Comparison of Minimal Skin Incision Technique in Living Kidney Transplantation and Conventional Kidney Transplantation. Chin Med J 2016;129:917-21.

Access this article online

Quick Response Code:



Website:
www.cmj.org

DOI:
10.4103/0366-6999.179800

METHODS

Subjects

This research was approved by the Institutional Review Board of College of Medicine, The Catholic University of Korea. From June 2006 to March 2013, a total of 452 kidney transplant patients were enrolled in this retrospective study. Seventeen patients were involved in MIKT group and 435 patients including 63 patients of ABO incompatible transplantation (iABO) were involved in CKT group. All operations of recipients included in both MIKT and CKT groups were performed by an expert surgeon. For immunosuppression and postoperative care, our standard protocols were equally applied to both groups. Unmarried women had a body mass index (BMI) <25 kg/m² with no anatomic variations underwent of minimal skin incisions in living kidney transplantation (KT). Authors have described in previous article for methods of MIKT with early experiences of five patients.^[6] The minimal skin incision was based on a careful and meticulous back-table preparation of the kidney before transplantation. All redundant fatty tissue outside the hilus plane was removed to achieve unencumbered access for the complete hemostatic control, also regarding minor vessels. The renal arteries and veins were dissected free, and all branches were thoroughly secured by ligatures. Furthermore, the lymphatic vessels, mostly located alongside the artery, were ligated. About a 10-cm transverse incision was placed 3–4 cm above the inguinal ligament, with the medial end 2–3 cm from the midline. Abdominal fascia and abdominal muscle dissection were similar to those with a conventional open hockey-stick incision. Extraperitoneally, the iliac vessels were dissected free while allowing lateral space for the transplanted kidney. A self-retracting system was introduced, giving medial, vascular exposure while allowing lateral space for kidney [Figure 1a]. The prepared kidney, which had been cooled by ice sludge, was placed in a retroperitoneal space. All three anastomoses were performed with the kidney in this final position. The renal

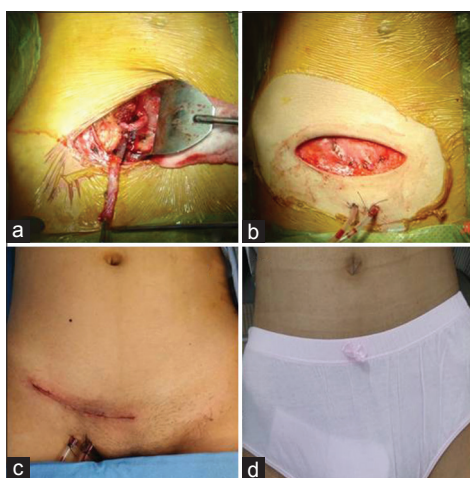


Figure 1: The minimal skin incision in living kidney transplantation. (a) Renal artery and vein anastomosis via an incision located at right lower abdomen. (b) Abdominal wall closure. (c) Skin closure. (d) Result of abdominal wound in 3 weeks posttransplantation.

vein was anastomosed to the external iliac vein (end-to-side) with continuous CV #7 (Gore-Tex® suture). The renal artery was anastomosed to the internal iliac artery (end-to-end) as in most living donor cases with continuous CV #7. Polar renal arteries were anastomized to the external iliac artery (end-to-side) [Figure 1a]. Re-implantation of the ureter was performed by the extravesical technique of Lich-Gregoir, with minimal bladder dissection and without a stent. The operative wound closure was similar to the conventional open transplant operation [Figure 1b-1d]. There was no case in which minimal incision procedures were interrupted or changed to conventional procedures. We have followed up both groups more than 1 year retrospectively.

Statistical analysis

Statistical analysis was done by Student's *t*-test, Chi-square test, propensity score matching (PSM), or log-rank test using the SPSS 18.0 (SPSS Inc., Chicago, IL, USA). A $P < 0.05$ was considered statistically significant. Data were presented as mean \pm standard deviation (SD).

RESULTS

The mean ages were 26.5 ± 9.3 years in MIKT group and 43.6 ± 11.0 years in CKT group. Patients in MIKT group were significantly younger than those in CKT group ($P < 0.001$) [Table 1]. The ratios of male to female were 0:17 in MIKT group and 271:164 in CKT group. Female patients were significantly predominant in MIKT group ($P < 0.001$) [Table 1]. The BMIs were 18.72 ± 2.47 kg/m² in MIKT group and 22.98 ± 3.76 kg/m² in CKT group. BMI in MIKT group was significantly less than that in CKT ($P < 0.001$) [Table 1]. Between MIKT and CKT groups, other clinical characteristics including kidney weight, renal artery number, total ischemic time (TIT), donor age, and related donor were statistically insignificant ($P > 0.05$) [Table 1]. After implementing the PSM for proper comparison, clinical characteristics including age, gender, BMI, kidney weight, renal artery number, TIT, donor age, and related donor were statistically insignificant between MIKT and CKT groups ($P > 0.05$) [Table 1]. With respect to surgical procedures, the average length of the skin incision was 9.5 ± 1.3 cm, and there were no significant differences in operative time, surgical complications requiring re-procedure, and postoperative hospital stay between MIKT and CKT groups. Between MIKT and CKT groups, postoperative clinical characteristics including hospital day, acute rejection (AR), delayed graft function (DGF), serum creatinine (sCr), creatinine clearance (Ccr), and graft function loss were statistically insignificant during follow-up period ($P > 0.05$) [Table 2]. During 1 month, 6 months, and 12 months postoperatively, sCr and Ccr were consecutively insignificant with similar functions between two groups ($P > 0.05$) [Table 2]. Moreover, graft function loss during follow-up period was statistically insignificant between two groups ($P > 0.05$) [Table 2]. The 5-year survival rates were 92.3% in MIKT and 85.7% in CKT groups ($P = 0.786$) [Figure 2].

Table 1: Baseline clinical characteristics in all study subjects

Characteristics	Total population				Propensity-matched population			
	MIKT group (n = 17)	CKT group (n = 435)	Statistical values	P	MIKT group (n = 17)	CKT group (n = 17)	Statistical values	P
Age (years), mean ± SD	26.5 ± 9.3	43.6 ± 11.0	-7.364*	<0.001	26.5 ± 9.3	28.8 ± 11.0	-0.724*	0.460
Female, n (%)	17 (100)	164 (37.7)	30.589†	<0.001	17 (100)	17 (100)	0.000†	1.000
BMI (kg/m ²), mean ± SD	18.72 ± 2.47	22.98 ± 3.76	-6.805*	<0.001	18.72 ± 2.47	19.47 ± 3.76	-0.691*	0.487
Kidney weight (g), mean ± SD	188.59 ± 34.36	186.62 ± 36.96	0.216*	0.829	188.59 ± 34.36	183.59 ± 36.96	0.396*	0.683
Single renal artery, n (%)	11 (64.7)	297 (68.3)	1.146†	0.757	11 (64.7)	13 (76.5)	2.027†	0.452
TIT (min), mean ± SD	48.00 ± 8.46	51.37 ± 16.97	-0.814*	0.416	48.00 ± 8.46	45.00 ± 16.97	0.910*	0.365
Donor age (years), mean ± SD	40.6 ± 11.6	40.8 ± 11.0	-0.069*	0.945	40.59 ± 11.57	40.38 ± 11.02	0.047*	0.965
Related donor, n (%)	14 (82.4)	297 (68.3)	1.511†	0.219	14 (82.4)	15 (88.2)	0.001†	1.000

*t values; †Chi-square values. MIKT: Minimal skin incision technique in kidney transplantation; CKT: Conventional kidney transplantation; SD: Standard deviation; BMI: Body mass index; TIT: Total ischemic time.

Table 2: Postoperative clinical characteristics of MIKT and CKT groups after implementing the propensity score matching

Characteristics	Propensity-matched population			
	MIKT group (n = 17)	CKT group (n = 17)	Statistical values	P
Hospital day (days), mean ± SD	17.88 ± 3.12	18.89 ± 5.31	-0.817*	0.436
Acute rejection, n (%)	2 (11.8)	3 (17.6)	2.927†	0.437
Delayed graft function, n (%)	0	1 (5.9)	1.822†	0.488
Serum creatinine (mg/L), mean ± SD				
1 month postoperatively	9.40 ± 0.12	13.10 ± 0.92	-2.477*	0.103
6 months postoperatively	11.70 ± 0.23	13.90 ± 1.02	-1.071*	0.382
12 months postoperatively	15.60 ± 1.67	13.60 ± 1.02	0.830*	0.432
Creatinine clearance (ml·min ⁻¹ ·1.73·m ⁻²), mean ± SD				
1 month postoperatively	77.12 ± 16.72	69.64 ± 20.82	3.215*	0.061
6 months postoperatively	67.92 ± 16.32	64.61 ± 17.12	0.820*	0.434
12 months postoperatively	64.33 ± 19.75	67.49 ± 16.63	-0.724*	0.446
Graft function loss, n (%)	1 (5.9)	1 (5.9)	0.000†	1.000

*t values; †Chi-square values. MIKT: Minimal skin incision technique in kidney transplantation; CKT: Conventional kidney transplantation; SD: Standard deviation.

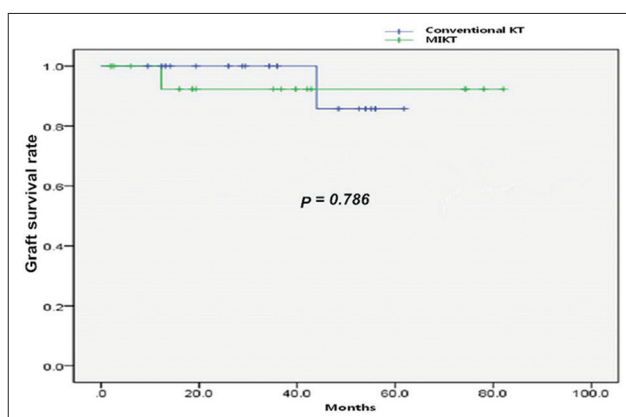


Figure 2: The 5-year graft survival rate between minimal skin incision technique in kidney transplantation and conventional kidney transplantation groups (92.3% vs. 85.7%). KT: kidney transplantation; MIKT: Minimal skin incision technique in kidney transplantation.

DISCUSSION

The MIKT, restricted to about a 10-cm incision of the abdominal transverse skin incision, is feasible and may be executed safely and relatively quickly because of its simplicity in experienced hands.^[6] By reducing the incision,

extent of dissection, and thereby tissue trauma, it seems reasonable that wound complications may be reduced accordingly.^[4] In addition, the minimal skin incision showed better cosmetic result and was more easily hidden.^[4] The MIKT seems particularly attractive in selected transplant recipients (low BMI, young woman, soft and expandable abdominal wall) with significantly delayed wound healing, which may be overcome with more careful wound care and delayed stitch out.^[4,6] This procedure may become even more important with the introduction of immunosuppressive drugs with pronounced antiproliferative actions.^[7] Potential wound problems due to immunosuppressive drugs prescribed to kidney transplant recipients are particularly associated with steroid and antiproliferative agents.^[8] A major point about the present minimally invasive approach is that reduction of tissue trauma seems particularly appropriate in this population, with significantly delayed wound healing and a high complication rate.^[4] Due to the immunosuppressive therapy, the incidence of wound dehiscence and incisional hernia is distinctly higher in transplant recipients, in particular with the introduction of sirolimus/everolimus,^[9] and it seems plausible that significant reduction of incision/tissue trauma would counteract such problems.^[4] The patient selection

criteria included unmarried woman, BMI <25 kg/m², no anatomic variation, and living KT.^[6] Patients who met all of above criteria have been performed MIKT. There were two key points of MIKT operation.^[6,8] The first was a careful and meticulous back-table preparation for reducing reperfusion bleeding in limited operation field: problems with even minor vessels affect the success of the procedure.^[6,8] We also removed all fatty tissues outside the hilar plane during the back-table preparation and ligating even the smallest blood vessel.^[6] The second was a self-retracting system to obtain an surgical field that was necessary, giving medial, vascular exposure while allowing lateral space for kidney.^[6,8] Considering the benefit of reducing trauma due to surgery and the effects of immunosuppressive drugs, one understands the importance of MIKT.^[8] However, it is rather unexpected that minimally invasive KT procedures have been just limitedly reported,^[6,8] and even more so when taking into consideration the wide range of sophisticated MIS procedures that have been introduced during recent years.^[1] The reasons may include the urge for safe handling of the kidney through sufficient access, for total control during revascularization, and the present unfeasibility of automating the vascular anastomoses.^[4] The access to the kidney during revascularization, particularly with regard to the back side of the hilus/parenchyma, is definitely reduced during the MIKT technique. Moreover, we would like to stress that a very careful back-table preparation of the kidney, taking cares of even minor vessels *a priori*, is an important prerequisite for the success of this procedure.^[4] Another criticism of MIKT could be that it does not sufficiently cool the kidney before revascularization.^[8] Furthermore, the technical difficulties encountered with a short renal vein is accentuated by the MIKT technique.^[4] Robot-assisted KT has been introduced in limited cases, but it showed long ischemic and operation time.^[10] Hence, it is not yet available and feasible. In the literature, MIS offers the advantages of cosmetic effect, less postoperative pain, fewer infections, early postoperative mobilization, a shorter recovery period, shorter hospitalization, reduced anesthetic risk and consequently a reduction in postoperative thromboembolic, respiratory, and metabolic complications.^[11,12] Of course, MIKT also showed beneficial effects on postoperative pain, analgesia, recovery, and complication.^[4,13] Øyen *et al.*^[4] reported that MIKT had benefits in surgical complications requiring re-interventions, postoperative analgesic requirements, hospitalization, and cosmetic effects. In our study, our patients also represented similar results. However, reports about benefits of MIKT were deficient. Hence, we need to do further intensive and large volume study for MIKT.

In our study, among baseline clinical characteristics, age, gender, and BMI were statistically significant, but kidney weight, renal artery number, TIT, donor age, and related donor were statistically insignificant between MIKT and CKT groups. After implementing the PSM for proper comparison, clinical characteristics including age, gender, BMI, kidney weight, renal artery number, TIT, donor age, and related

donor were statistically insignificant between MIKT and CKT groups. And then, we compared postoperative results between MIKT and CKT groups. Hence, we cannot confirm whether age, BMI, and ABO compatibility affect the results or not in this study. However, our additional primitive studies showed that age, BMI, and ABO compatibility did not affect the postoperative results. We plan to report about that in the future. Moreover, we compared kidney weight in respect to kidney size between two groups. In our result, TIT was insignificantly different between two groups. We mentioned about back-table procedure for reducing reperfusion bleeding in limited operation field, and it was thought to be a more careful preparation for complete hemostatic control. Hence, it would take a longer time for preparation that meant longer cold ischemic time was taken in MIKT. We thought that it was the reason why well-prepared MIKT group showed shorter anastomosis time and bleeding control time than CKT group despite of showing a longer preparing time. In a view of surgical procedures, there were no significant differences in operative time, surgical complications requiring re-procedure, and postoperative hospital stay between MIKT and CKT groups. During follow-up period, AR, DGF, sCr, Ccr, and graft function loss were statistically insignificant.

We thought that MIKT may cause vascular and urinary complications. Vascular complications involve bleeding, anastomotic stenosis, and thrombus.^[4,8] Moreover, urinary complications involve urinary leakage, anastomotic stenosis, and infection.^[4,8] Especially, because of the more limited views and exploration in MIKT, a higher complication rate was expected,^[8] but it was similar in MIKT and CKT groups in the literature.^[4,7,8] Øyen *et al.*^[4] reported that there were no statistically significant differences in bleeding, anastomotic stenosis, lymphocele, and wound dehiscence between MIKT and CKD groups. Kaçar *et al.*^[8] reported that there was no statistical significance in bleeding, urinary leakage, lymphocele, incisional hernia, and acute tubular necrosis between two groups.

Our results showed that MIKT had more favorable cosmetic effects and there was no difference in various postoperative factors including graft function, survival, and complications compared with CKT. This was similar with other reports.^[4,7,8] Hence, we thought that MIKT can be clinically useful and attractive in living transplantations for unmarried women with a BMI <25 kg/m², no anatomic variations, and significantly delayed wound healing, and may become even more important with the introduction of immunosuppressive drugs with pronounced antiproliferative actions such as sirolimus and everolimus.^[4,8,9,14,15]

Our study has several limitations. We compared factors such as hospital stay, graft function, rejection, postoperative complication, and survival between MIKT and CKT. However, we did not include further detailed factors such as intraoperative blood loss, postoperative pain scale, analgesics, and so on. This study was a retrospective study.

Although sample sizes of MIKT in the literature were small from 21 to 50,^[4,7,8] sample size ($n = 17$) in our study is very small. Hence, we thought that we need to do further qualified, prospective, and large sample size study for MIKT.

In conclusion, MIKT showed more favorable cosmetic results and there was no statistical difference in various postoperative factors including renal function and other complications compared with CKT. Hence, MIKT can be performed safely and may be an attractive surgical method in the immunosuppressed patients. Moreover, we suggest MIKT is an appropriate method for selected patients in living KT.

Financial support and sponsorship

Nil.

Conflicts of interest

There are no conflicts of interest.

REFERENCES

1. Harrell AG, Heniford BT. Minimally invasive abdominal surgery: Lux et veritas past, present, and future. *Am J Surg* 2005;190:239-43. doi: 10.1016/j.amjsurg.2005.05.019.
2. McCullough CS, Soper NJ, Clayman RV, So SS, Jendrisak MD, Hanto DW. Laparoscopic drainage of a posttransplant lymphocele. *Transplantation* 1991;51:725-7. doi: 10.1097/00007890-199103000-00034.
3. Ratner LE, Ciseck LJ, Moore RG, Cigarroa FG, Kaufman HS, Kavoussi LR. Laparoscopic live donor nephrectomy. *Transplantation* 1995;60:1047-9.
4. Øyen O, Scholz T, Hartmann A, Pfeffer P. Minimally invasive kidney transplantation: The first experience. *Transplant Proc* 2006;38:2798-802. doi: 10.1016/j.transproceed.2006.08.102.
5. Velidedeoglu E, Williams N, Brayman KL, Desai NM, Campos L, Palanjian M, *et al.* Comparison of open, laparoscopic, and hand-assisted approaches to live-donor nephrectomy. *Transplantation* 2002;74:169-72. doi: 10.1097/00007890-200207270-00005.
6. Park SC, Kim SD, Kim JI, Moon IS. Minimal skin incision in living kidney transplantation. *Transplant Proc* 2008;40:2347-8. doi: 10.1016/j.transproceed.2008.07.028.
7. Nanni G, Tondolo V, Citterio F, Romagnoli J, Borgetti M, Boldrini G, *et al.* Comparison of oblique versus hockey-stick surgical incision for kidney transplantation. *Transplant Proc* 2005;37:2479-81. doi: 10.1016/j.transproceed.2005.06.055.
8. Kaçar S, Eroglu A, Tilif S, Güven B. Minimally invasive kidney transplantation. *Transplant Proc* 2013;45:926-8. doi: 10.1016/j.transproceed.2013.02.079.
9. Dean PG, Lund WJ, Larson TS, Prieto M, Nyberg SL, Ishitani MB, *et al.* Wound-healing complications after kidney transplantation: A prospective, randomized comparison of sirolimus and tacrolimus. *Transplantation* 2004;77:1555-61. doi: 10.1097/01.TP.0000123082.31092.53.
10. Tsai MK, Lee CY, Yang CY, Yeh CC, Hu RH, Lai HS. Robot-assisted renal transplantation in the retroperitoneum. *Transpl Int* 2014;27:452-7. doi: 10.1111/tri.12279.
11. Brockschmidt C, Huber N, Paschke S, Hartmann B, Henne-Bruns D, Wittau M. Minimal access kidney transplant: A novel technique to reduce surgical tissue trauma. *Exp Clin Transplant* 2012;10:319-24. doi: 10.6002/ect.2012.0045.
12. Omar ME. Minimal-access kidney transplant. *Exp Clin Transplant* 2015;13 Suppl 1:284-5. doi: 10.6002/ect.mesot2014.P122.
13. Oyen O. Minimally invasive kidney transplantation (MIKT). *J Surg Res* 2008;145:4. doi: 10.1016/j.jss.2007.08.001.
14. Tzvetanov I, D'Amico G, Benedetti E. Robotic-assisted kidney transplantation: Our experience and literature review. *Curr Transplant Rep* 2015;2:122-6. doi: 10.1007/s40472-015-0051-z.
15. Sood A, Ghosh P, Jeong W, Khanna S, Das J, Bhandari M, *et al.* Minimally invasive kidney transplantation: Perioperative considerations and key 6-month outcomes. *Transplantation* 2015;99:316-23. doi: 10.1097/TP.0000000000000590.