

Case-Based Review of Literature

A rare case of lingual thyroid with hyperthyroidism: A case report and review of the literature

Mattakarottu Joseph Jacob, Mudalsha Ravina

Department of Nuclear Medicine, Army Hospital Research and Referral, Dhaula kuan, New Delhi, India

ABSTRACT

Lingual thyroid is a rare embryological anomaly resulting from failure of normal thyroid tissue to descend from the foramen cecum at base of tongue to its orthotopic location in front of the lower neck. It is a rare anomaly with a reported incidence of 1 in 3000 of the thyroid disorders. Lingual thyroid is often asymptomatic but may cause local symptoms such as dysphagia, dysphonia with stomatolalia, upper airway obstruction, and often with hypothyroidism. Hyperthyroidism is extremely rare finding and till now there are very few case reports published. We present here a case of lingual thyroid with hyperthyroidism, which was treated successfully with radioiodine.

Key words: Hyperthyroidism, lingual thyroid, radioiodine

INTRODUCTION

Thyroid gland begins to develop during the third week of intrauterine life as an endodermal thickening in the midline of the floor of the pharynx between first and second branchial arches. By the seventh week it reaches its final position anterior to the larynx trachea. The descent of thyroid may be arrested at any point between the base of tongue and the trachea. Lingual thyroid is the most common form of incomplete descent.^[1] The authors report a case of lingual thyroid with hyperthyroidism and the subsequent management of the case.

CASE REPORT

A 32-year-old female patient presented to our institution with the chief complaints of change in voice, difficulty in swallowing, foreign body sensation in the throat for 6 months duration. The patient also gave history of

palpitations, heat intolerance, increased sweating, easy fatigability, and irritability. There was history of weight loss in spite of increased appetite. All these symptoms were gradually progressive. On general physical examination, pulse was 104/min, regular. The patient had moist palms with fine digital tremors. There was a no neck swelling. There were no eye signs. Throat examination revealed a fleshy mass at the posterior aspect of the tongue, in midline. The mass moved with protrusion of the tongue. The surface of the mass was congested with numerous vessels [Figure 1]. On CNS examination brisk tendon reflexes were present. CVS examination revealed no abnormality other than tachycardia. On further investigations, the patients hemogram, ESR, chest radiograph were normal, ECG showed sinus tachycardia. The patient had a low TSH, with raised FT3 and FT4 (FT3 = 5.6 pg/ml, FT4 = 2.1 ng/ml, TSH = 0.01 μ IU/ml against normal range of 2.4--4.2 pg/ml, 0.8--1.7 ng/ml, and 0.5--6.5 μ IU/ml, respectively). Radioactive iodine uptake showed uptake of 18% at 04 hours and 42 % at 24 hours. A 99 mTc thyroid scan was done for the patient. The scan revealed presence of functioning thyroid tissue located at the base of the tongue [Figure 2]. No tracer accumulation was noted in the thyroid bed. Thus RAIU and Tc 99m thyroid scan were consistent with diagnosis of lingual thyroid with hyperthyroid status. T2-weighted MRI of the patient revealed well defined rounded, hyperintense midline mass at the base of tongue [Figure 3]. Thus final diagnosis of lingual thyroid with

Access this article online

Quick Response Code:



Website:
www.ijem.in

DOI:
10.4103/2230-8210.95708

Corresponding Author: Dr. Mudalsha Ravina, K. S. Nursing Home, Near Post Office, Badshapur, Gurgaon, Haryana – 122 101, India.
E-mail: mudalsharavina@gmail.com

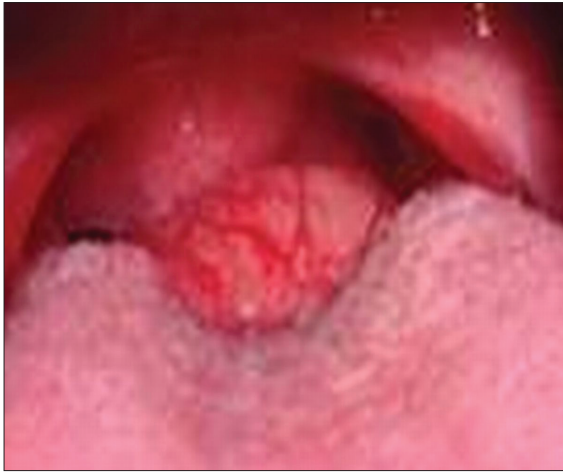

Figure 1: Midline mass in the posterior aspect of the tongue. The mass is congested with numerous vessels

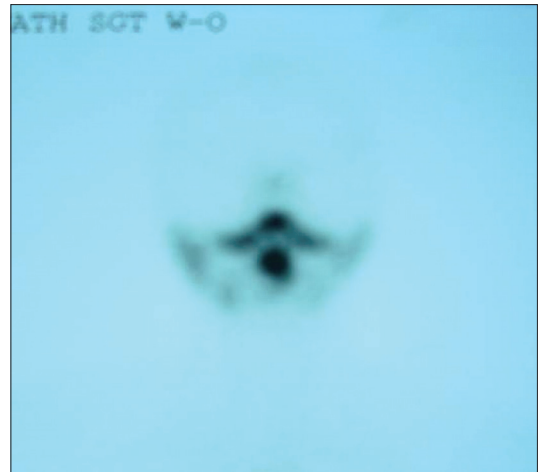


Figure 2: 99m Tc thyroid scan reveals functioning thyroid tissue in the base of tongue. No tracer upatake noted in the neck. Salivary gland and background activity is faintly visualised

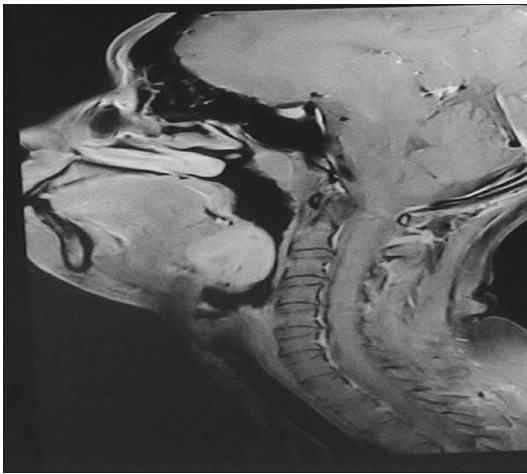


Figure 3: T2 weighted MR images of the face in sagittal section reveals hyperintense mass lesion in the posterior aspect of the tongue

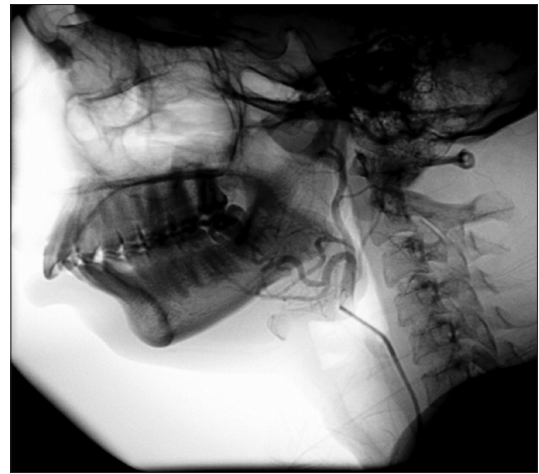

Figure 4: External carotid artery angiogram reveals supply of the hypervascular mass by lingual artery

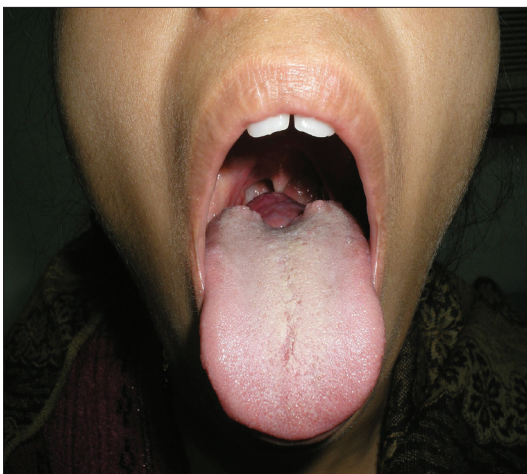

Figure 5: Regression in the size of the swelling post treatment

hyperthyroidism was made. Presurgical angiogram revealed high vascularity and supply of the lingual thyroid by the lingual artery [Figure 4]. Hypervascularity and the location of swelling made anesthesia and surgery in the base of tongue a high risk one and surgery was abandoned and the patient was referred for radioiodine treatment. The patient was put on a low iodine diet for 2 weeks and was administered 20 mCi of ^{131}I and was closely observed in the high dose therapy ward for 3 days. After 4 weeks the patient became clinically euthyroid. The swelling also regressed. At 3 monthly follow-up no obstructive symptoms were noticed. The swelling had markedly reduced [Figure 5]. The biochemical parameters were suggestive of hypothyroidism with FT3 = 2.0 pg/ml, FT4 = 0.7 ng/ml, and TSH=14.8 $\mu\text{IU/ml}$. The patient was started on tablet thyroxine 50 μg

OD. The patient is presently euthyroid on thyroid hormone replacement and is asymptomatic.

DISCUSSION

Lingual thyroid is the most common form of incomplete descent. It forms about 90% of the cases. Submandibular glands, lymph nodes of the neck and trachea or esophagus are uncommon sites of involvement. Ectopic-thyroid tissue in the mediastinum, pericardial sac, heart, breast, duodenum, mesentery of the small intestine, and adrenal gland has also been reported. Thyroid tissue in its normal location is seen in only one-fourth patients with lingual thyroid.^[1-5] It occurs more frequently in females, with a female to male ratio 4:1; ectopic thyroid is seen at any age but more commonly during childhood, adolescence, and around menopause. This probably occurs when demands for thyroid hormones increase, causing the increase in circulating TSH levels with growth of the ectopic thyroid tissue.^[6]

The majority of patients with ectopic thyroid are asymptomatic. Patients with lingual thyroid can present with obstructive symptoms as well as hypothyroidism. Hyperthyroidism is a rare presentation in cases of ectopic thyroid gland with few case reports being reported in the literature.^[7-9]

In the case report by Abdallah-Matta *et al.* the patient presented with a nodular lesion in the lingual thyroid with hyperthyroidism. The restoration of the euthyroid status was done with thionamide and then the ectopic gland was surgically removed. In another case report by Kamijo *et al.*, a 68-year-old female patient presented with perspiration, fatigue, and proptosis with periorbital edema. Examination revealed bilateral proptosis. On further investigations including thyroid function tests, neck ultrasound, color Doppler, computerized tomography, ^{99m}Tc thyroid scan and radioiodine uptake study, diagnosis of lingual thyroid with grave's disease and Grave's ophthalmopathy was established. The patient was treated with methimazole 15 mg/day. Regression in the symptoms was noticed. Steroid pulse therapy was given for reducing the periorbital edema.

Literature search showed only a few cases lingual thyroid with hyperthyroidism and all of them were treated with a combination of antithyroid drugs, steroids, and surgery. To our knowledge, this is the first case of lingual thyroid

with hyperthyroidism which has been successfully treated with radioiodine alone and followed by thyroid hormone replacement as the patient developed mild hypothyroidism after radioiodine treatment. Radioiodine treatment in this case could solve the hyperthyroid condition as well as the obstructive symptoms associated with a mass lesion at the base of the tongue in one go. Compared to surgery and antithyroid drugs, this treatment modality has shown that this is much simpler, very effective and gave the patient very satisfying result. Although radioiodine treatment even with a dose of 20 mCi warrants close monitoring and admission of the patient in high dose therapy ward for close monitoring.

So this is a rare case of lingual thyroid which presented with complaints of mass effect with hyperthyroidism. Surgery was difficult due to high vascularity and location of swelling making intubation and surgery technically difficult and risky. So the patient was treated with radioiodine with good result. The patient is presently asymptomatic.

REFERENCES

- Collins P. Embryology and development. In: Williams PL, Bannister LH, Berry MM, editors. *Gray's Anatomy - The Anatomical Basis of Medicine and Surgery*. 38th ed. New York: Churchill Livingstone; 1995. p. 174-99.
- Di Benedetto V. Ectopic thyroid gland in the submandibular region simulating a thyroglossal duct cyst: A case report. *J Pediatr Surg* 1997;32:1745-6.
- Pollice L, Caruso G. Struma cordis. Ectopic thyroid goiter in the right ventricle. *Arch Pathol Lab Med* 1986;110:452-3.
- Porqueddu M, Antona C, Polvani G, Cavoretto D, Pompilio G, Gianolli L, *et al.* Ectopic thyroid tissue in the ventricular outflow tract: Embryologic implications. *Cardiology* 1995;86:524-6.
- Ferlito A, Giarelli L, Silvestri F. Intratracheal thyroid. *J Laryngol Otol* 1988;102:95-6.
- Kumar R, Sharma S, Marwah A, Moorthy D, Dhanwal D, Malhotra A. Ectopic goiter masquerading as submandibular gland swelling: A case report and review of the literature. *Clin Nucl Med* 2001;26:306-9.
- Abdallah-Matta MP, Dubarry PH, Pessey JJ, Caron P. Lingual thyroid and hyperthyroidism: a new case and review of the literature. *J Endocrinol Invest* 2002;25:264-7.
- Kisakol G, Gonen S, Kaya A, Dikbas O, Sari O, Kiresi D, *et al.* Dual ectopic thyroid gland with Graves' disease and unilateral ophthalmopathy: A case report and review of the literature. *J Endocrinol Invest* 2004;27:874-7.
- Kamijo K. Lingual thyroid associated with Graves' disease and Graves' ophthalmopathy. *Thyroid* 2005;15:1407-8.

Cite this article as: Jacob MJ, Ravina M. A rare case of lingual thyroid with hyperthyroidism: A case report and review of the literature. *Indian J Endocr Metab* 2012;16:441-3.

Source of Support: Nil, **Conflict of Interest:** None declared.