

# High-Dose Tigecycline for the Treatment of Progressive Pneumonia Caused by *Chlamydia psittaci*: Case Series and Literature Review

Lu Wang<sup>1</sup>, Jingwei Liu<sup>2</sup>, Liping Peng<sup>1</sup>

<sup>1</sup>Department of Respiratory Medicine, The First Hospital of Jilin University, Changchun, Jilin Province, People's Republic of China; <sup>2</sup>Department of Pediatric Intensive Care Unit, The First Hospital of Jilin University, Changchun, Jilin Province, People's Republic of China

Correspondence: Liping Peng, Department of Respiratory Medicine, The First Hospital of Jilin University, Changchun, 130021, People's Republic of China, Email penglp@jlu.edu.cn

**Purpose:** To summarize the clinical characteristics of progressive pneumonia caused by *Chlamydia psittaci* (*C. psittaci*) and to explore the effect of high-dose tigecycline on severe *C. psittaci*.

**Patients and Methods:** We retrospectively analyzed the clinical characteristics, treatment, and outcomes of three progressive pneumonia patients caused by *C. psittaci* in our hospital in the past three years.

**Results:** All three patients showed high fever and progressive dyspnea, and all of them were finally diagnosed by bronchoalveolar lavage fluid (BALF) of metagenomic next-generation sequencing (mNGS). Case 1 rapidly developed into multilobar infiltration after raising a parrot with a normal appearance one week before. Respiratory failure occurred despite the use of moxifloxacin, requiring non-invasive ventilator-assisted ventilation. Case 2 developed discomfort one day after sightseeing in the forest park. Moxifloxacin was ineffective for her and she quickly developed respiratory failure, requiring invasive ventilator-assisted ventilation. Case 3 kept chickens and ducks at home. Respiratory failure and renal failure still occurred rapidly despite the use of doxycycline, requiring invasive ventilator-assisted ventilation and continuous renal replacement therapy (CRRT). After adjusting the antibiotic to high-dose tigecycline (100mg, I.V., q12h), all three patients were treated effectively and no side effects occurred.

**Conclusion:** *C. psittaci* pneumonia is one of the causes of progressive pneumonia. High-dose tigecycline is safe and effective for the treatment of severe *C. psittaci*.

**Keywords:** *Chlamydia psittaci*, progressive pneumonia, metagenomic next-generation sequencing, high-dose tigecycline

## Introduction

Progressive pneumonia is defined as clinical deterioration after 24 hours of treatment, with an increase of 50% in the extent of the pneumonic opacity on radiographic images or respiratory insufficiency requiring mechanical ventilation or septic shock after 72 hours of treatment.<sup>1</sup> Progressive pneumonia is a dangerous disease with high mortality. *Chlamydia psittaci* (*C. psittaci*) is an uncommon pathogen of community-acquired pneumonia (CAP). About 1–2% of annual CAP is caused by *C. psittaci*.<sup>2</sup> The severity of psittacosis pneumonia varies widely, from influenza-like mild respiratory infection to life-threatening severe pneumonia.<sup>3</sup> *C. psittaci* parasitizes in tissues, blood, and feces of pet birds (eg, peacocks, parrots, and pigeons) and poultry (eg, chickens, turkeys, and ducks), which can cause disease or present asymptomatic infection.<sup>4</sup> Tetracyclines are the first choice for the treatment of *C. psittaci* infection. Tigecycline is a new tetracycline drug with a broad antibacterial spectrum and is widely used in the clinical treatment of severe pneumonia. We presented a series of three rapid progressive *C. psittaci* pneumonia cases diagnosed by metagenomic next-generation sequencing (mNGS) of bronchoalveolar lavage fluid (BALF) in northeast China. Eventually, all three cases were effectively treated with high-dose tigecycline. To our best knowledge, this is the first case series report of severe *C. psittaci* pneumonia successfully treated with high-dose tigecycline.

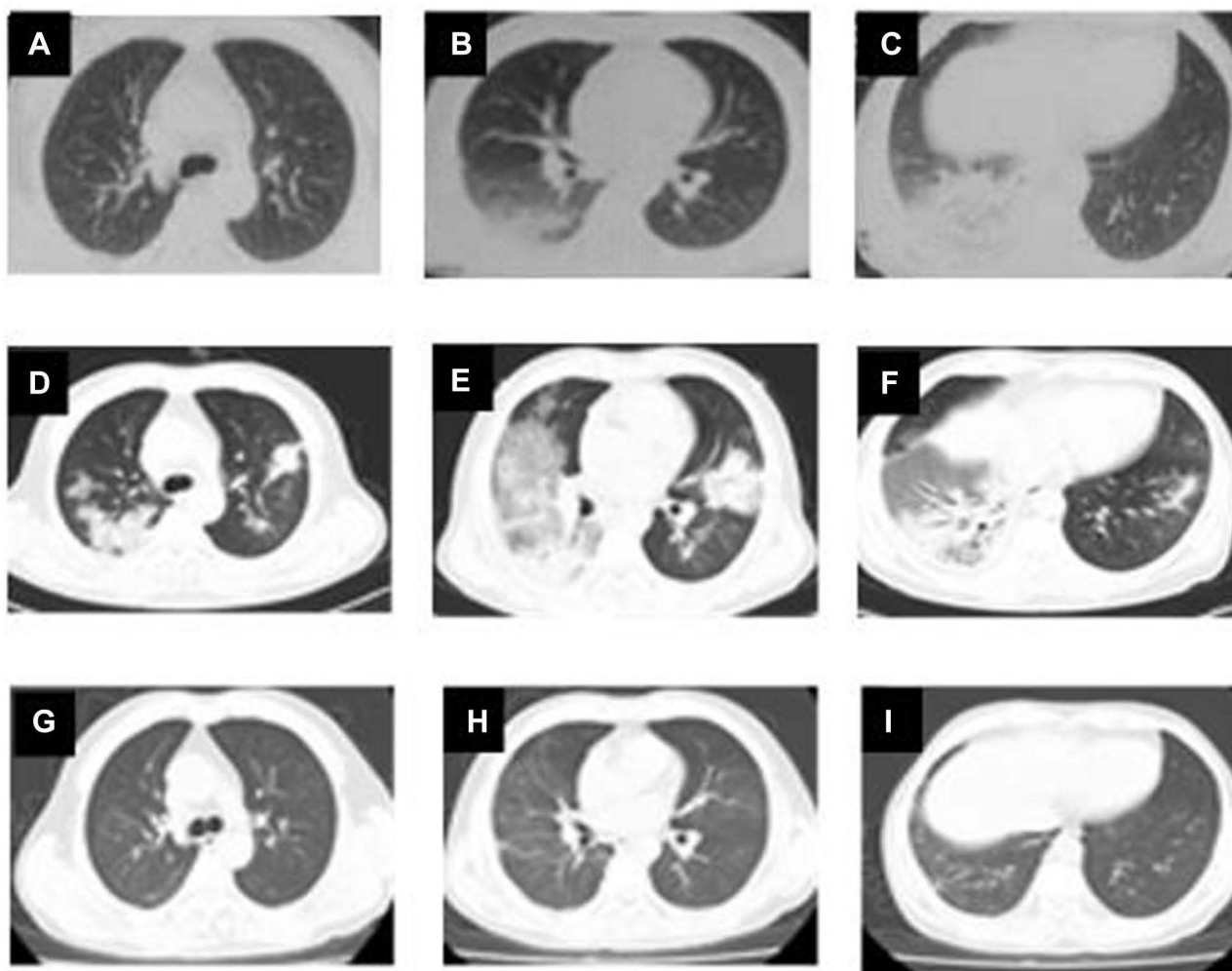
## Case Presentations

### Case I

A 50-year-old man with a high fever, non-productive cough, and progressive dyspnea for three days was admitted to our hospital. The body temperature was between 39.4°C and 40°C, accompanied by chills. He was a healthy man before the onset. He denied tuberculosis infection history or other infectious disease exposure history and no history of smoking or alcohol abuse. After moxifloxacin 0.4 g, I.V., qd in an external hospital for two days, his symptoms did not relieve. A chest CT scan was performed 24 hours before admission showing pulmonary infiltrate and consolidation in the lower lobe of the right lung (Figure 1A–C).

His vital signs of physical examinations at admission were as follows: temperature 39.5°C, pulse rate 118 beats/min, blood pressure 128 / 80mmHg, respiratory rate 34 breaths/min. He was tachypnea, and his lips were cyanotic. His saturation of peripheral oxygen was 88% with mask oxygen inspiration (5L/min). Wet rales could be heard in the lower lobe of the right lung. The rest of the physical examination was roughly normal.

Laboratory tests on admission showed white cell count  $10.7 \times 10^9/L$  (reference range:  $4-10 \times 10^9/L$ ), neutrophil ratio 95% (50–70%), hemoglobin 151 g/L (120–160 g/L), and platelet count  $221 \times 10^9/L$  ( $100-300 \times 10^9/L$ ). C reactive protein was 272mg/L (0–3mg/L). Erythrocyte sedimentation (ESR) was 38mm/1h (0–20 mm/1h). Procalcitonin (PCT) was 0.62ng/mL (<0.5ng/mL). His renal function was normal. He had severe liver function damage. His aspartate aminotransferase (AST) was 195 IU/L (8–40 IU/L), alanine aminotransferase (ALT) 112 IU (5–40 IU/L), albumin 23



**Figure 1** Chest CT of case I at the time of onset (A–C); 3 days after moxifloxacin treatment (D–F); 21 days after anti-pneumocystis treatment (G–I).

g/L (35–55 g/L). The laboratory tests revealed electrolyte disorders- hyponatremia and hypochloremia. Serum sodium concentration was 128mmol/l (130–150mmol/l), chloride concentration 95mmol/l (96–106mmol/l).

No etiological evidence was found. Sputum culture results, acid-fast bacilli stain, and GeneXpert MTB/RIF assay was negative. Nasal swabs for detection of Covid-19, influenza virus, adenovirus, and respiratory syncytial virus also found nothing.

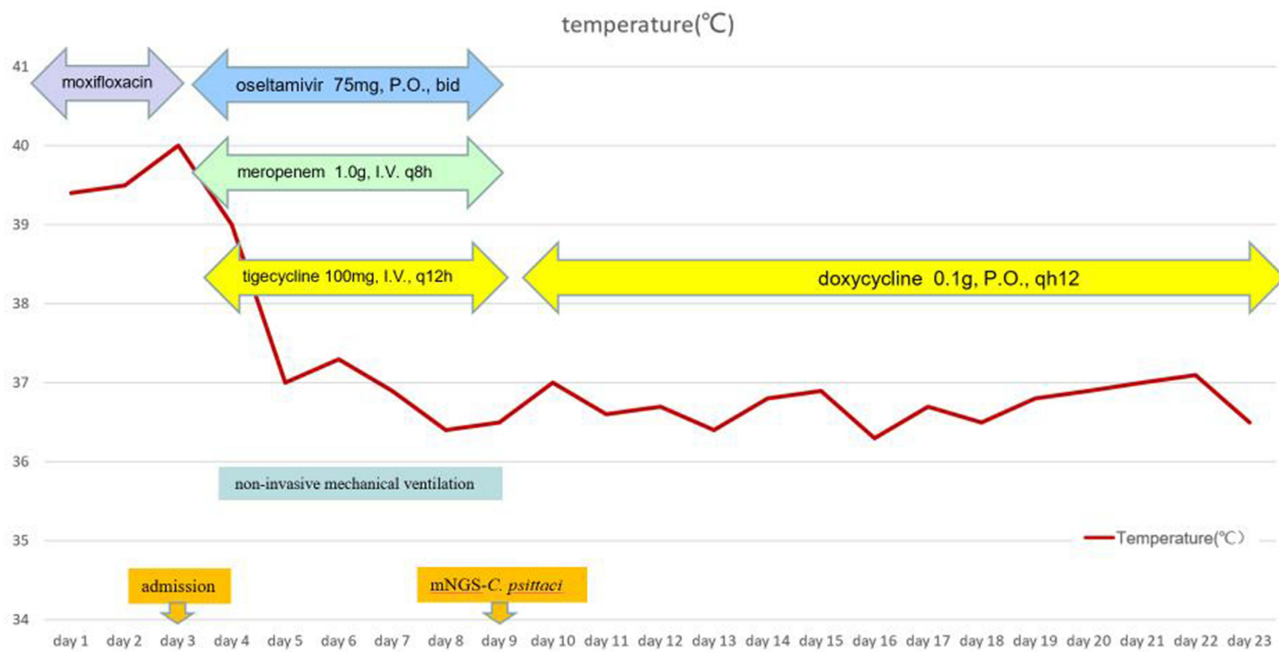
Intravenous infusion of moxifloxacin 0.4g was continued after admission. A chest CT scan was reexamined the next day after admission. The lung shadow progressed rapidly, showing multiple patchy ground-glass opacity and consolidation in both lungs (Figure 1D–F). The patient's condition deteriorated, with persistent high fever (39–40°C), and worsening dyspnea. With mask oxygen inhalation of 10L/min, arterial blood gas analysis revealed pH 7.52, PO<sub>2</sub> 40 mmHg (83–108mmHg), PCO<sub>2</sub> 25 mmHg (35–48mmHg), and HCO<sub>3</sub><sup>-</sup> 24.5 mmol/L (18–23mmol/L). He was treated with non-invasive mechanical ventilation in S/T mode with IPAP 15cmH<sub>2</sub>O, EPAP 6cmH<sub>2</sub>O, and FiO<sub>2</sub> 60%, which could achieve a tidal volume of about 450mL and minute ventilation of 9L/min and peripheral oxygen saturation of 94%. The patient progressed rapidly and was diagnosed with progressive pneumonia. We considered that the disease progressed rapidly, and the risk of death was high. We adjusted the anti-infection therapy regime according to common pathogens of progressive pneumonia. Moxifloxacin was discontinued and upgraded to tigecycline 100mg, I.V., q12h to cover for atypical pathogens, gram-positive cocci, and drug-resistant bacteria. At the same time, extended-spectrum antibiotic meropenem 1.0g, I.V. q8h was combined. In addition, oseltamivir 75mg, P.O., bid was administered to cover the influenza virus.

While adjusting the anti-infective regimen, we performed fiberoptic bronchoscopy alveolar lavage in the basal segment of the lower lobe of the right lung and sent the bronchoalveolar lavage fluid (BALF) for mNGS detection. We also conducted tests related to rheumatic connective tissue disease. Connective tissue assays including immunoglobulin levels (IgG, IgM, IgA, and IgE), anti-ARS antibodies (anti-Jo-1, anti-MDA-5, anti-PL-7, anti-PL-12, anti-EJ, anti-KS antibodies), antinuclear antibodies (ANA), rheumatoid factor, cyclic citrullinated peptide antibodies, cytoplasmic antineutrophil cytoplasmic antibodies (cANCA), and perinuclear antineutrophil cytoplasmic antibodies (p-ANCA) antibody titers were all within normal parameters, which provided no clue to rheumatic connective tissue disease.

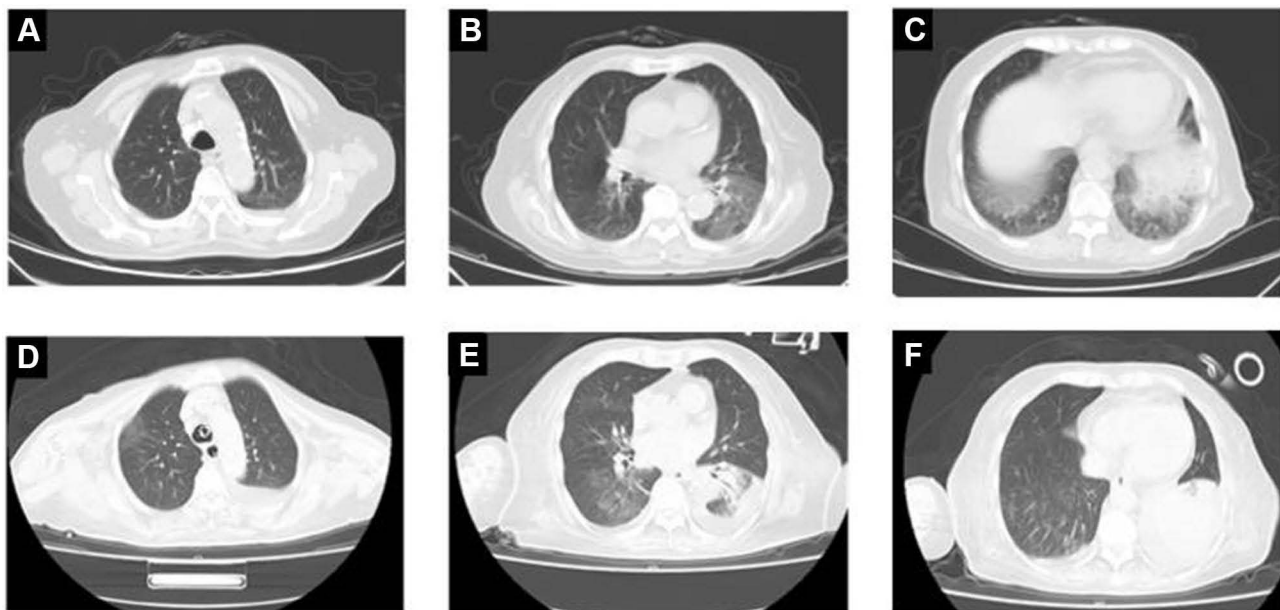
On the seventh day of admission, mNGS of BALF indicated *C. psittaci* (sequence reads: 205) and *Candida albicans* (sequence reads: 50). Upon close investigation, the patient had kept a pet bird a week before the onset of the disease. Until the patient was admitted to hospital, the bird did not appear abnormal. On the second day after tigecycline, the fever had gone down, and dyspnea was alleviated. After the mNGS results were reported, we adjusted the treatment regimen: we stopped meropenem and oseltamivir, and doxycycline 0.1g, P.O., q12h was successively administered for 14 days after 7 days of tigecycline administration. After 21 days of anti-psittacosis treatment, the patient's general condition was significantly improved, and there was no complaint of comfort. The patient's body temperature changes and treatment process were shown in Figure 2. A reexamination of chest CT revealed that the infiltrate was obviously absorbed (Figure 1G–I).

## Case 2

A 90-year-old female was admitted to our hospital with chills, fever, and dyspnea one day after sightseeing in the forest park. She had a history of hypertension for 20 years and her blood pressure was well controlled by amlodipine 1 tablet 1/ day. She denied a history of other diseases. At admission, her temperature was 39.5°C, pulse rate 98 beats/ min, blood pressure 160/64mmHg, and respiratory rate 28 breaths/min. Her saturation of peripheral oxygen was 88% with mask oxygen inspiration (5L/min). Wet rales could be heard in the lower lobe of the right lung. The rest of the physical examination was roughly normal. Laboratory tests on admission showed white cell count 19.8×10<sup>9</sup>/L, neutrophil ratio 92%, hemoglobin 150 g/L, and platelet count 224×10<sup>9</sup>/L. C reactive protein was 230mg/L. ESR was 40mm/1h. PCT was 0.62ng/mL (<0.5ng/mL). Her liver and renal function were normal. Her connective tissue assays were normal. Chest CT showed patches in the lower lobe of the left lung (Figure 3A–C). We gave her moxifloxacin 0.4 g, I.V., qd for anti-infection treatment. The patient continued to have fever and dyspnea. On the third day of admission, blood gas analysis showed pH 7.42, PO<sub>2</sub> 40 mmHg, PCO<sub>2</sub> 30 mmHg, and HCO<sub>3</sub><sup>-</sup> 19.9 mmol/L. A re-examination of chest CT showed large consolidation of the left lung (Figure 3D–F). We performed tracheal intubation and gave her invasive mechanical



**Figure 2** Body temperature changes and treatment process of case 1: in the first three days of onset, the patient showed persistent high fever. On the second day after the application of tigecycline, the patient's temperature returned to normal.



**Figure 3** Chest CT of case 2 showed patches in the lower lobe of the left lung at admission (A–C). Three days later chest CT showed large consolidation of the left lung (D–F).

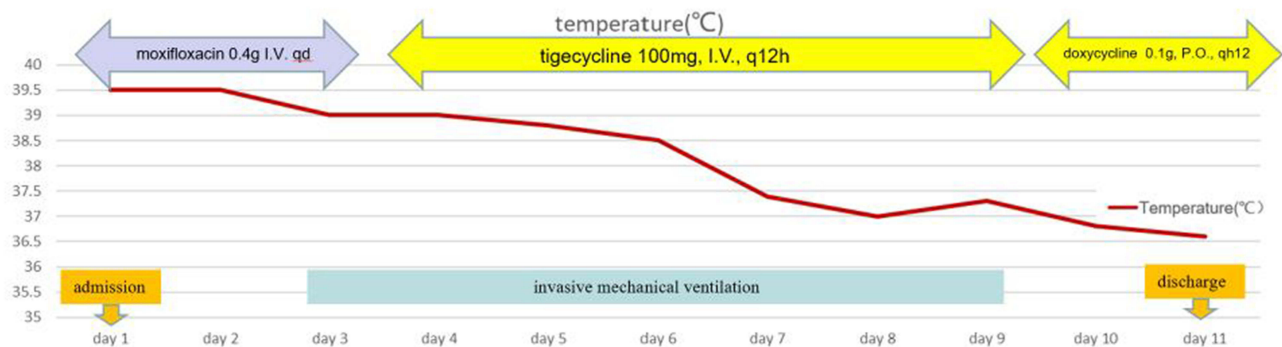
ventilation. PCV mode, PC 15 cmH<sub>2</sub>O, PEEP 8cmH<sub>2</sub>O, FiO<sub>2</sub> 60%, which could achieve a tidal volume of about 400mL, minute ventilation of 6 L/min, and peripheral oxygen saturation of 93%. At the same time, we underwent fiberoptic bronchoscopy alveolar lavage in the basal segment of the lower lobe of the left lung and sent the BALF to mNGS. And mNGS of BALF indicated *C. psittaci* (sequence reads: 88), *Acinetobacter baumannii* (sequence reads: 20) and *Candida albicans* (sequence reads: 55). We adjusted the antibiotics to tigecycline 100mg, I.V., q12h. And the patient's body temperature gradually decreased and returned to normal after 4 days. We gradually lowered the ventilator

support parameters, and the patient successfully weaned the ventilator two days later. Sequential doxycycline 0.1g, P.O., q12h for 13 days after discharge. The prognosis of the patient followed up by telephone was good, and there was no complaint of discomfort after discharge. The patient's body temperature changes and treatment process were shown in Figure 4.

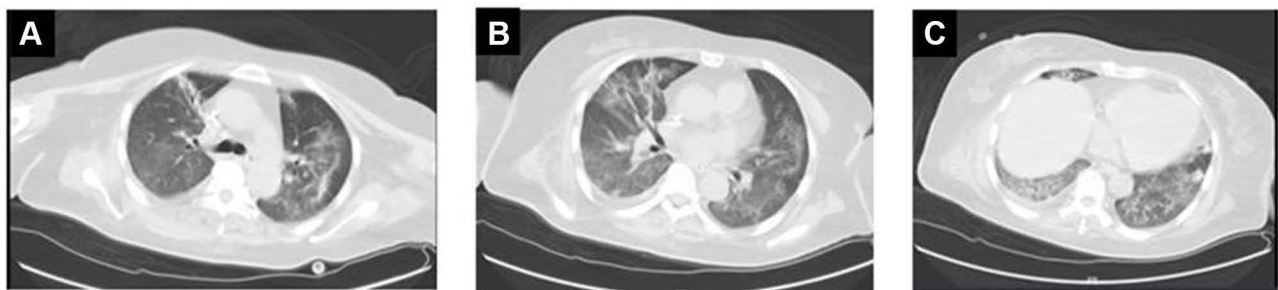### Case 3

A 69-year-old female was admitted to our hospital with fever, cough, and dyspnea for 2 days. She kept chickens and ducks at home. She was a healthy woman before the onset. At admission, her temperature was 40°C, pulse rate 119 beats/min, blood pressure 140/77mmHg, and respiratory rate 26 breaths/min. Her saturation of peripheral oxygen was 86% with mask oxygen inspiration (5L/min). Wet rales could be heard in both lungs. Laboratory tests on admission showed white cell count  $8.5 \times 10^9/L$ , neutrophil ratio 83%, hemoglobin 110 g/L, and platelet count  $207 \times 10^9/L$ . C reactive protein was 400mg/L. ESR was 44mm/1h. PCT was 12 ng/mL. Her liver and renal function were normal. Her connective tissue assays were normal. Chest CT showed diffuse ground-glass opacities in both lungs (Figure 5A–C). We selected meropenem 1.0g, I.V., q8h combined with doxycycline 0.1g, I.V., q12h for anti-infection treatment because of the patient's high PCT and history of poultry feeding. The patient's condition progressed rapidly. On the second day of admission, blood gas analysis showed pH 7.31,  $PO_2$  32 mmHg,  $PCO_2$  30 mmHg, and  $HCO_3^-$  22.1 mmol/L. We gave her invasive mechanical ventilation. PCV mode, PC 15 cmH<sub>2</sub>O, PEEP 10cmH<sub>2</sub>O,  $FiO_2$  80%, which could achieve a tidal volume of about 350mL, minute ventilation of 5 L/min, and peripheral oxygen saturation of 90%. At the same time, we sent the BALF to mNGS. BALF detected *C. psittaci* (sequence reads: 100) and *Acinetobacter baumannii* (sequence reads: 20).

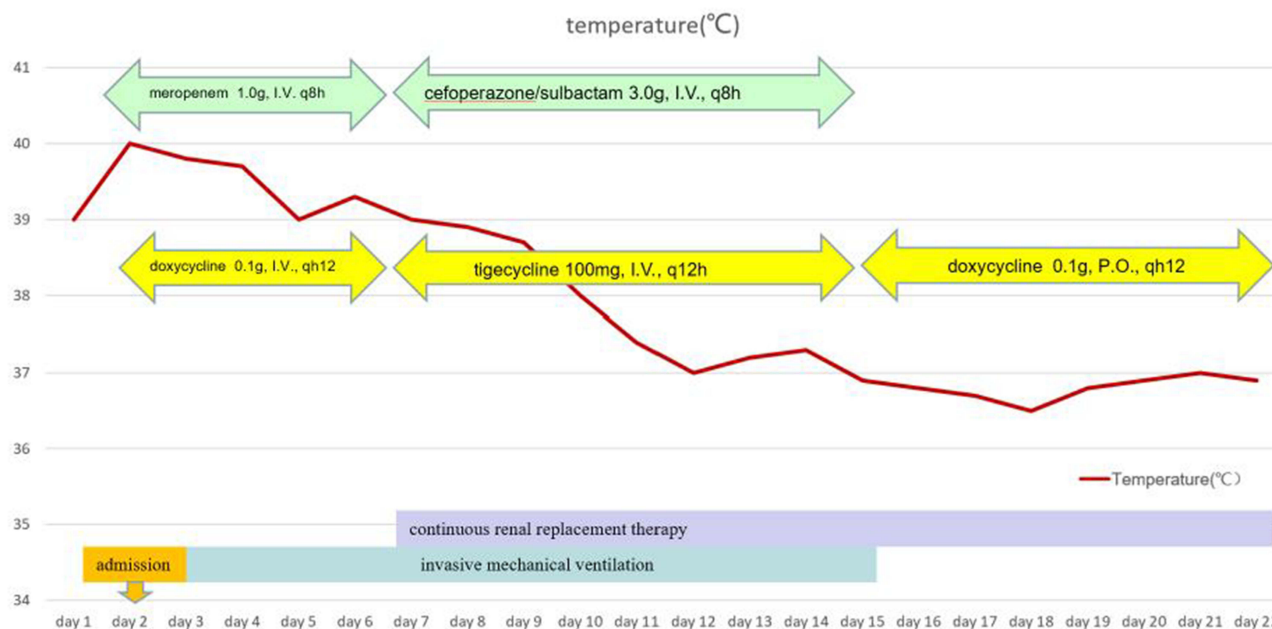
After 5 days of meropenem combined with doxycycline anti-infection treatment, the patient still sustained high fever and occurred oliguria. The urine volume was about 400mL/d, and the creatinine once increased to 405umol/l (normal:41–81umol/l). We adjusted the anti-infective treatment regimen to tigecycline 100mg, I.V., q12h plus cefoperazone/sulbactam 3.0g, I.V., q8h. At the same time, we performed continuous renal replacement therapy



**Figure 4** Body temperature changes and treatment process of case 2: the patient's temperature returned to normal after the application of high-dose tigecycline for 4 days.



**Figure 5** Chest CT of case 3 showed diffuse ground-glass opacities in both lungs (A–C).



**Figure 6** Body temperature changes and treatment process of case 3: the patient's temperature returned to normal after the application of high-dose tigecycline for 5 days.

(CRRT). The patient's temperature gradually returned to normal after 5 days and she weaned the ventilator 4 days later. We adjusted the antibiotic to doxycycline 0.1g, I.V., q12h after weaning. The patient's condition improved, and the urine volume gradually increased. After a total of half a month of CRRT treatment, her urine volume returned to normal, and the creatinine level decreased to 128 $\mu$ mol/l. She was discharged from our hospital after stopping CRRT treatment. The prognosis of the patient followed up by telephone was good, and the creatinine level returned to normal 3 months after discharge. The patient's body temperature changes and treatment process were shown in Figure 6.

## Discussion

Psittacosis is a zoonotic disease caused by *C. psittaci*, which is particularly common in tropical and subtropical regions while rarely occurring in northeastern China. In our first case, the bird looked healthy even after the patient developed severe pneumonia. Human beings could get sick by directly contacting the infected birds or inhaling contaminated aerosols from their feces, feathers, or nasal secretions. In comparison, person-to-person transmission of psittacosis is possible but rare.<sup>5</sup>

The incubation period is approximately 1–2 weeks. The contact history of birds or poultry before the onset of the disease has a suggestive effect on the diagnosis of psittacosis. After inhaling through the lung, pathogens first enter the blood to proliferate in the mononuclear macrophage system of the liver and spleen and then spread from the blood to systemic organs, involving the lung, liver, kidney, spleen, and central nervous system, resulting in pneumonia, hepatitis, renal impairment, spleen abscess, and nervous system symptoms. Among them, pneumonia is the most common manifestation, and the severity of pneumonia ranges from mild to severe.<sup>6</sup> Given its challenge for early diagnosis and rapid progression, misdiagnosis or improper antibacterial drugs may lead to multi-organ dysfunction with a mortality rate of 66–70%.<sup>7</sup> All our three cases presented with progressive pneumonia requiring mechanical ventilation-assisted support treatment and the third case developed renal failure and needed CRRT treatment.

Chest imaging findings of *C. psittaci* pneumonia lack specificity. Consolidation and ground glass opacity are the most common manifestations, while the presence of pulmonary nodules is rare.<sup>8</sup> The lesion is usually located in the subpleural of lower lobes of the lung. Pleural effusion or mediastinal lymphadenectasis is rare.<sup>9</sup> Our first case initially showed right lower lobe consolidation, and the lesion progressed in a short time, involving both lungs.

Conventional pathogen detection methods of *C. psittaci* are mainly pathogen culture and serological assay. However, due to the long testing time and low positive rate, traditional detection methods are often used in retrospective studies, which do not help guide clinical decisions. mNGS has recently been a new type of detection technology for microorganisms. It is a culture-independent method that directly performs high-throughput sequencing of nucleic acids in clinical samples. It can detect pathogenic microorganisms quickly and objectively (including viruses, bacteria, fungi, and parasites).<sup>10,11</sup> The detectable rate of mNGS for pathogens is nearly 89%, which is higher than that of traditional pathogens (25.73%).<sup>12</sup> In our case series, mNGS test of BALF accurately found the pathogen in only three days. Compared to traditional detection methods, mNGS has the advantages of shorter detection time, higher detection sensitivity, and broader pathogen coverage.

All three cases we reported showed progressive pneumonia. We searched Pubmed and Web of Science databases with “progressive pneumonia” as the subject word. We set the search deadline as July 2022. We found that both non-infectious and infectious lung diseases could cause clinical deterioration in a short time.<sup>1,13–19</sup> We summarize the common causes of progressive pneumonia in Table 1.

Non-infectious diseases that can cause rapidly progressive pneumonia are mainly connective tissue disease-interstitial lung diseases (CTD-ILDs). For example, pulmonary diseases related to dermatomyositis (especially MDA-5) antibody-positive dermatomyositis,<sup>20</sup> systemic lupus erythematosus, primary Sjogren syndrome, rheumatoid arthritis, and systemic vasculitis.<sup>21,22</sup> However, our series did not have a family history of autoimmune disease. They neither had myalgia and joint pain nor dry mouth and eye. As to physical examination, their limbs and joints were normal, and there was no rash all over their body. Autoimmune-related antibodies were also negative. Therefore, they were unlikely to suffer from CTD-ILD.

The primary infectious pathogens leading to rapidly progressive pneumonia in a healthy adult are viruses (influenza virus, adenovirus, coronavirus), atypical pathogens (*Mycoplasma*, *Chlamydia*, *Legionella*), and several bacteria.<sup>22</sup> Community-acquired methicillin-resistant *Staphylococcus aureus* (CA-MRSA) is the most common bacterium.<sup>13,23</sup> There are also cases of progressive pneumonia in immuno-competent hosts caused by invasive group A streptococcal,<sup>17</sup> *Pseudomonas aeruginosa*,<sup>24</sup> and hypervirulent types of *Klebsiella pneumoniae*.<sup>25</sup> Tigecycline can cover the above possible bacteria. All our three progressive pneumonia cases were immuno-competent hosts. Their condition improved after we changed the anti-infection treatment to high-dose tigecycline.

*C. psittaci* is an obligate intracellular parasitic bacterium. Tetracyclines are the first choice for treating psittacosis, followed by macrolides. There are cases of moxifloxacin in treating *C. psittaci* pneumonia,<sup>26</sup> but the result is not as good as the tetracyclines.<sup>27</sup> Moxifloxacin did not affect our case 1 and case 2. Case 3 improved after tigecycline treatment although initially insensitive to doxycycline. Tigecycline is a new generation of glycycl

**Table 1** Diseases That Can Lead to Progressive Pneumonia

Non-Infectious Diseases	Infectious Diseases	
	Immuno-Competent Host	Immuno-Compromised Host
Dermatomyositis	Influenza virus	Cytomegalovirus
Systemic lupus erythematosus	Adenovirus	Herpes simplex virus
Primary Sjogren syndrome	Coronavirus	Pneumocystis jirovecii
Rheumatoid arthritis	Mycoplasma	Aspergillosis
Systemic vasculitis	Chlamydia	Candida albicans
	Legionella	Escherichia coli
	CA-MRSA	Burkholderia cepacia
	Group A streptococcal	Tuberculous mycobacteria
		Klebsiella pneumoniae
		Pseudomonas aeruginosa
		Stenotrophomonas maltophilia
		NTM

**Abbreviations:** CA-MRSA, Community-acquired methicillin-resistant *Staphylococcus aureus*; NTM, non-tuberculous mycobacteria.

tetracycline belonging to broad-spectrum antibiotics and is less susceptible to generating drug resistance. Tigecycline offers good antibacterial performance towards gram-positive bacteria (*Staphylococcus*, *Streptococcus*, *Enterococcus*), gram-negative bacteria (*Acinetobacter*, *Klebsiella*, *Escherichia*) atypical pathogenic bacteria (*Mycoplasma*, *Chlamydia*, *Legionella*), and especially drug-resistant bacteria (*MRSA*, carbapenem-resistant *Klebsiella pneumoniae*, carbapenem-resistant *Acinetobacter baumannii*).<sup>28</sup> It is widely used in the treatment of severe infections. Combined use of tigecycline and meropenem regimen in case 1 could cover most of the pathogenic bacteria that may cause rapidly progressive pneumonia. Although at the time of admission, we failed to identify that the patient's infection pathogen was *C. psittaci*, the application of tigecycline just right covered the pathogenic bacteria of the patient.

The interplay between tigecycline metabolism and pathophysiological changes in severe patients (hypoxia, hypoproteinemia, and acid-base balance disorder) may impact the clinical effect during tigecycline therapy. A large number of studies have found that the conventional dose of tigecycline cannot play an influential role in the treatment of severe patients. Lei Zha<sup>29</sup> carried out a meta-analysis of 593 patients in 10 studies, comparing the safety and effectiveness of conventional-dose tigecycline with high-dose tigecycline. The study found that conventional-dose tigecycline (100mg loading dose, 50mg q12h) often could not achieve the ideal antibacterial treatment effect for severe patients. However, high-dose tigecycline (100mg loading dose, 100mg q12h) could effectively reduce mortality and improve the cure rate. The study also found that high-dose tigecycline did not increase the incidence of adverse drug reactions. The area under the concentration-time curve / minimum inhibitory concentration (AUC/MIC) is an effective indicator for evaluating the efficacy of antibiotics. The AUC of tigecycline has a linear relation to the dose. Increasing the dose of tigecycline is helpful to prompt AUC and improves effectiveness. In addition, tigecycline has a large apparent volume of distribution in vivo, and increasing the dose is beneficial to increasing the lung tissue drug concentration.<sup>30</sup> In our case series, high-dose tigecycline had a noticeable curative effect, and no adverse reactions such as liver function damage, nausea, or vomiting occurred. High-dose tigecycline was both effective and safe.

## Conclusion

In conclusion, *C. psittaci* pneumonia can progress in a short time, leading to respiratory failure. Avian or poultry exposure history is conducive to the diagnosis of *C. psittaci*. Even if the animal's appearance is not abnormal, it is also possible to infect human beings. mNGS plays an essential role in determining the pathogen of progressive pneumonia. High-dose tigecycline is safe and effective for the treatment of severe *C. psittaci*.

## Ethics Approval and Informed Consent

The Ethics Committees of the first hospital of Jilin University (2022-497) approved this study. Statement that signed consents were obtained from the patients for the publication of their case details.

## Author Contributions

All authors made a significant contribution to the work reported, whether that is in the conception, study design, execution, acquisition of data, analysis and interpretation, or in all these areas; took part in drafting, revising or critically reviewing the article; gave final approval of the version to be published; have agreed on the journal to which the article has been submitted; and agree to be accountable for all aspects of the work.

## Funding

There is no funding to report.

## Disclosure

The authors report no conflicts of interest in this work.



## References

1. Low DE, Mazzulli T, Marrie T. Progressive and nonresolving pneumonia. *Curr Opin Pulm Med*. 2005;11(3):247–252. doi:10.1097/01.mcp.0000158727.20783.70
2. Hogerwerf L, De Gier B, Baan B, Van Der Hoek W. Chlamydia psittaci (psittacosis) as a cause of community-acquired pneumonia: a systematic review and meta-analysis. *Epidemiol Infect*. 2017;145(15):3096–3105. doi:10.1017/S0950268817002060
3. Arenas-Valls N, Chacón S, Pérez A, Del Pozo R. Atypical chlamydia psittaci pneumonia. Four related cases. *Arch Bronconeumol*. 2017;53(5):277–279. doi:10.1016/j.arbr.2017.03.011
4. Hulin V, Bernard P, Vorimore F, et al. Assessment of Chlamydia psittaci shedding and environmental contamination as potential sources of worker exposure throughout the mule duck breeding process. *Appl Environ Microbiol*. 2015;82:1504–1518. doi:10.1128/AEM.03179-15
5. Lei JH, Xu Y, Jiang YF, Shi ZH, Guo T. Clustering cases of Chlamydia psittaci pneumonia in COVID-19 screening ward staff. *Clin Infect Dis*. 2020;9(36):11237.
6. Raeven VM, Spoorenberg SMC, Boersma WG, et al. Atypical aetiology in patients hospitalised with community-acquired pneumonia is associated with age, gender and season; a data-analysis on four Dutch cohorts. *BMC Infect Dis*. 2016;16(1):299. doi:10.1186/s12879-016-1641-9
7. Zuzek R, Green M, May S. Severe psittacosis progressing to suspected organizing pneumonia and the role of corticosteroids. *Respir Med Case Rep*. 2021;34:101486. doi:10.1016/j.rmcr.2021.101486
8. Wang Y, Lu H, Shao R, Wang W. Clinical characteristics analysis of patients with pneumonia infected by Chlamydia psittaci. *Zhonghua Wei Zhong Bing Ji Jiu Yi Xue*. 2020;32(11):1388–1390. doi:10.3760/cma.j.cn121430-20200408-00259
9. Wen W, Gu L, Zhao LW, et al. Diagnosis and treatment of Chlamydia psittaci pneumonia: experiences of 8 cases. *Zhonghua jie he he hu xi za zhi*. 2021;44(6):531–536. doi:10.3760/cma.j.cn112147-20210205-00097
10. Gu L, Liu W, Ru M, et al. The application of metagenomic next-generation sequencing in diagnosing Chlamydia psittaci pneumonia: a report of five cases. *BMC Pulm Med*. 2020;20(1):65. doi:10.1186/s12890-020-1098-x
11. Zhang H, Zhan D, Chen D, et al. Next-generation sequencing diagnosis of severe pneumonia from fulminant psittacosis with multiple organ failure: a case report and literature review. *Ann Translat Med*. 2020;8(6):401. doi:10.21037/atm.2020.03.17
12. Yuan YP, Zhang XB, Gui CM. Detection of Chlamydia psittaci in both blood and bronchoalveolar lavage fluid using metagenomic next-generation sequencing A case report. *Medicine*. 2021;100:27. doi:10.1097/MD.00000000000026514
13. Kashif M, Patel R, Bajantri B, Diaz-Fuentes G. Legionella pneumonia associated with severe acute respiratory distress syndrome and diffuse alveolar hemorrhage - A rare association. *Respir Med Case Rep*. 2017;21:7–11. doi:10.1016/j.rmcr.2017.03.008
14. Obasi J. An elusive case of acute interstitial pneumonia. *Cureus*. 2019;11(5):e4685.
15. Canton-Bulnes ML, Martinez AH, Lopez-Cerero L, Seisdedos AA, Merino-Bohorquez V, Garnacho-Montero J. A case of pan-resistant Burkholderia cepacia complex bacteremic pneumonia, after lung transplantation treated with a targeted combination therapy. *Transpl Infect Dis*. 2019;21(2):e13034. doi:10.1111/tid.13034
16. Cheng A, Vintch J. Necrotizing pneumonia and toxic shock caused by group a streptococcus: a case report. *Chest*. 2016;150(4):163A. doi:10.1016/j.chest.2016.08.172
17. Saha BK. Rapidly progressive necrotizing pneumonia: remember the Streptococcus anginosus group. *Pan Afr Med J*. 2020;36. doi:10.11604/pamj.2020.36.116.22218
18. Jellinge ME, Hansen F, Coia JE, Song Z. Herpes simplex virus type 1 pneumonia-A review. *J Intensive Care Med*. 2021;36(12):1398–1402. doi:10.1177/0885066620965941
19. Dermawan JKT, Ghosh S, Keating MK, Gopalakrishna KV, Mukhopadhyay S. Candida pneumonia with severe clinical course, recovery with antifungal therapy and unusual pathologic findings A case report. *Medicine*. 2018;97(2):e9650. doi:10.1097/MD.0000000000009650
20. Endo Y, Koga T, Suzuki T, et al. Successful treatment of plasma exchange for rapidly progressive interstitial lung disease with anti-MDA5 antibody-positive dermatomyositis A case report. *Medicine*. 2018;97(15):e0436. doi:10.1097/MD.00000000000010436
21. Aoyama J, Hayashi H, Yajima C, et al. Anti-MDA5 antibody-positive rapidly progressive interstitial pneumonia without cutaneous manifestations. *Respir Med Case Rep*. 2019;26:193–196. doi:10.1016/j.rmcr.2019.01.012
22. Kishaba T. Acute or subacute progressive interstitial pneumonia. *Respir Investig*. 2019;57(5):405–407. doi:10.1016/j.resinv.2019.05.003
23. Menendez R, Perpina M, Torres A. Evaluation of nonresolving and progressive pneumonia. *Semin Respir Infect*. 2003;18(2):103–111.
24. Okamoto M, Yamaoka J, Chikayama S, Ohishi T, Nakajima T, Nakashima T. Successful treatment of a previously healthy woman with Pseudomonas aeruginosa community-acquired pneumonia with plasmapheresis. *Intern Med*. 2012;51(19):2809–2812. doi:10.2169/internalmedicine.51.7921
25. Choby JE, Howard-Anderson J, Weiss DS. Hypervirulent Klebsiella pneumoniae - clinical and molecular perspectives. *J Intern Med*. 2020;287(3):283–300. doi:10.1111/joim.13007
26. Kong CY, Zhu J, Lu JJ, Xu ZH. Clinical characteristics of Chlamydia psittaci pneumonia. *Chin Med J*. 2021;134(3):353–355. doi:10.1097/CM9.0000000000001313
27. Fraeyman A, Boel A, Van Vaerenbergh K, De Beenhouwer H. Atypical pneumonia due to Chlamydia psittaci: 3 case reports and review of literature. *Acta Clin Belg*. 2010;65(3):192–196. doi:10.1179/acb.2010.040
28. Yaghoubi S, Zekiy AO, Krutova M, et al. Tigecycline antibacterial activity, clinical effectiveness, and mechanisms and epidemiology of resistance: narrative review. *Eur J Clin Microbiol Infect Dis*. 2022;41(7):1003–1022. doi:10.1007/s10096-020-04121-1
29. Zha L, Pan L, Guo J, French N, Villanueva EV, Tefsen B. Effectiveness and safety of high dose tigecycline for the treatment of severe infections: a systematic review and meta-analysis. *Adv Ther*. 2020;37(3):1049–1064. doi:10.1007/s12325-020-01235-y
30. Leng B, Yan G, Wang C, Shen C, Zhang W, Wang W. Dose optimisation based on pharmacokinetic/pharmacodynamic target of tigecycline. *J Glob Antimicrob Resist*. 2021;25:315–322. doi:10.1016/j.jgar.2021.04.006

Infection and Drug Resistance

Dovepress

## Publish your work in this journal

Infection and Drug Resistance is an international, peer-reviewed open-access journal that focuses on the optimal treatment of infection (bacterial, fungal and viral) and the development and institution of preventive strategies to minimize the development and spread of resistance. The journal is specifically concerned with the epidemiology of antibiotic resistance and the mechanisms of resistance development and diffusion in both hospitals and the community. The manuscript management system is completely online and includes a very quick and fair peer-review system, which is all easy to use. Visit <http://www.dovepress.com/testimonials.php> to read real quotes from published authors.

Submit your manuscript here: <https://www.dovepress.com/infection-and-drug-resistance-journal>