



Case Report

# Original technique of sealing cerebrospinal fluid leakage from dural sac causing spontaneous cerebral hypotension

Mateusz Miroslaw Zabek<sup>1</sup>, Grzegorz Turek<sup>2</sup>

<sup>1</sup>Medical Division, Cardinal Stefan Wyszyński University, <sup>2</sup>Department of Neurosurgery, Brodno Masovian Hospital, Warsaw, Poland.

E-mail: \*Mateusz Miroslaw Zabek - mateusz.m.zabek@gmail.com; Grzegorz Turek - turek.grz@gmail.com



**\*Corresponding author:**

Mateusz Miroslaw Zabek,  
Faculty of Medicine, Cardinal  
Stefan Wyszyński University,  
Warsaw, Poland.

mateusz.m.zabek@gmail.com

Received : 18 April 2022

Accepted : 30 April 2022

Published : 20 May 2022

**DOI**

10.25259/SNI\_360\_2022

**Quick Response Code:**



## ABSTRACT

**Background:** Spontaneous intracranial hypotension (SIH) is a rare disease characterized by a decrease in the volume and pressure of cerebrospinal fluid (CSF) resulting from its leakage through the dura mater. SIH is curable, but it can lead to serious clinical sequelae or even death if not treated properly.

**Case Description:** A 37-year-old female with headaches occurring in standing position and increasing especially during verticalization. Magnetic resonance imaging showed an image characteristic of SIH. Conservative treatment was applied in the form of bed rest. CT myelography scan located the site of CSF leakage. As the conservative treatment proved inefficient, it was decided to perform an epidural fistula sealing using the patient's venous blood, administered under computed tomography guidance. The performed procedure completely resolved the patient's complaints, allowing her to be discharged home.

**Conclusion:** Patients with suspected SIH should remain in the supine position until a definitive diagnosis is made. Sealing the meningeal fistula with venous blood under computed tomography guidance should be considered in case of conservative treatment failure.

**Keywords:** Computed tomography myelography, Dura mater fistula seal, Epidural blood patch under computed tomography guidance, Intracranial hypotension, Spontaneous intracranial hypotension

## INTRODUCTION

Spontaneous intracranial hypotension (SIH) is a disease characterized by a decrease in the amount and/or pressure of cerebrospinal fluid (CSF). The cause of the decrease in CSF is its leakage through the damaged dura. Typically, there are no trauma, surgery, or other causes explaining the history of existing dura mater injury in SIH.

Severe, debilitating headache that occurs or worsens during verticalization is the main symptom reported by the patients. The reclining position provides patients with relief. Associated complaints in this syndrome may include double vision, tinnitus, dizziness, neck stiffness, nausea, vomiting, auditory hypersensitivity, deafness, and vision loss.<sup>[3,12]</sup> The occurrence of these symptoms is explained by the Monro-Kellie hypothesis, according to which CSF leakage leads to a decrease in intracranial pressure and disrupts intracranial homeostasis. Decreased pressure leads to venodilation and increases meningeal tone, which is the likely cause of patient-reported pain. Meningeal tension can also lead to interruption of the bridging veins which can result in subdural bleeding.<sup>[11,13]</sup>

This is an open-access article distributed under the terms of the Creative Commons Attribution-Non Commercial-Share Alike 4.0 License, which allows others to remix, transform, and build upon the work non-commercially, as long as the author is credited and the new creations are licensed under the identical terms.

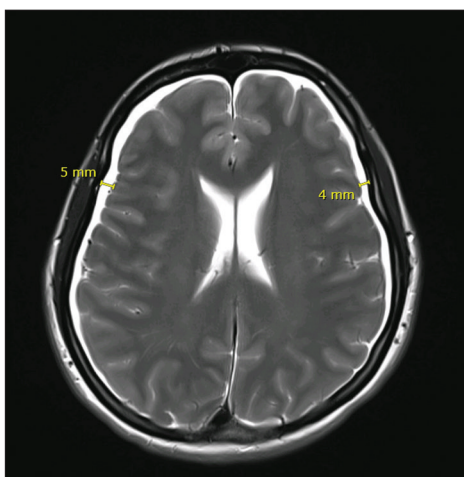
©2022 Published by Scientific Scholar on behalf of Surgical Neurology International

Magnetic resonance imaging (MRI) is a useful examination in the diagnostics of SIH, allowing to find changes such as cerebral hemispheres lowered below the tentorial notch, diffuse enhancement of the arachnoid mater, dilation of the dura mater sinuses, subdural exudates or hematomas, wedging of the cerebellar tonsils, enlargement and swelling of the pituitary gland, atrophy of the suprasellar and perimesencephalic cistern, thrombosis of the meningeal sinuses, and epidural congestion of the spinal canal.<sup>[1,8,10,12,18]</sup> Computed tomography (CT) myelography and radioisotope cisternography are other useful tests in the diagnostics of SIH, which may help in precise detection the site of CSF leakage.

Most patients recover with the conservative treatment which is limited to bed rest, hydration, and analgesics.<sup>[3,6,7,21,22]</sup> In patients unresponsive to conservative treatment, in whom imaging tests located the site of CSF leakage, sealing with the use of a blood patch or even an open surgery may be recommended. The epidural administration of venous blood to form a blood patch under the guidance of X-ray is a well-known option in the treatment of SIH.<sup>[2,5]</sup> However, in some patients, in whom spinal nerve root sheath rupture is the cause of SIH, we recommend a new method of treatment consisting in sealing the fluid fistula with the patient's venous blood administered epidurally through the intervertebral foramen under the guidance of CT.<sup>[2]</sup>

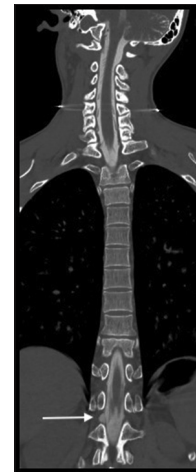
## CASE DESCRIPTION

A 37-year-old female patient, with typical symptoms of SIH and no history of trauma, was admitted to the hospital. Brain MRI showed peri hemispheric, subdural fluid collections, up to 4 mm thick [Figure 1]; reduced distance between the pons and the mammillary bodies to 4 mm, cerebellopontine angle reduced to 55°, and interpeduncular angle reduced to 51°. In addition, dilatation and rounding of the venous

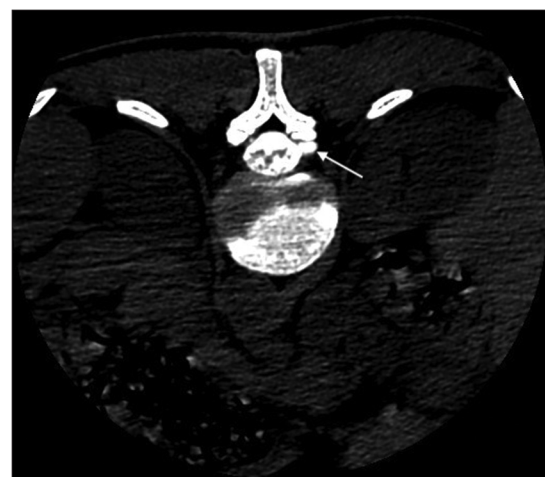


**Figure 1:** Subdural fluid collections in CT-T2 scanning, patient before EBP under CT guidance.

sinuses, rounding of the pituitary gland, absence of fluid in the optic nerve sheaths, and enhancement of the meninges were noted. MRI scan of the cervical, thoracic, and lumbar spine showed no abnormalities. Conservative treatment including bed rest and intravenous fluid infusions and corticosteroids were implemented. Isotope cisternography showed no evidence of a fluid fistula site. CT myelography with subdural administration of contrast mixed with saline in a ratio of 40/60 showed the fluid leakage site through the spinal nerve root sheath at the level of Th12/L1 intervertebral foramen on the right side [Figures 2 and 3]. Since CSF leakage was found on the level of intervertebral foramen, we decided to seal it with the patient's venous blood directly through the foramen instead of standard epidural puncture. For the procedure, the patient was placed on the CT table in the prone position. After confirmation of level Th12/L1 in the CT scout image, we, then, inserted 18G lumbar puncture needle



**Figure 2:** CT myelography showing the CSF leakage on the TH12/L1 level (arrow) on the right side, frontal plane.



**Figure 3:** CT myelography showing the CSF leakage on the TH12/L1 level (arrow) on the right side, transverse plane.

to the intervertebral foramen Th12/L1 under the guidance of CT [Figure 4]. Having previously taken 10 ml of the patient's venous blood, we, then, injected it at the root exit site of the intervertebral foramen under CT guidance [Figure 5]. It is worth noticing that we, then, positioned the patient laterally, but on the opposite side to fistula for better spreading of the injected blood around the damaged nerve root sheath. The patient remained in this position in her own bed for another 2 h. Patient's verticalization started after the next 2 days. After the verticalization the patients, no longer complained about the headache during hospitalization and was discharged from hospital. During the follow-up visit, 1 month after hospitalization, the patient was completely free of headache and we found normalization of MRI image [Figure 6].

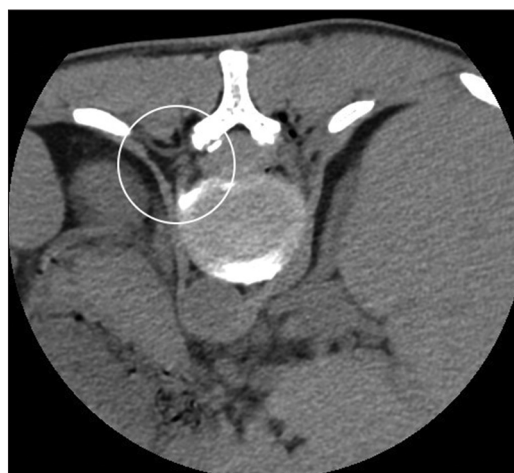## DISCUSSION

Headaches are a widespread and common cause of patients presenting to hospital emergency departments (0.5–4.5%).<sup>[4,17]</sup> One cause of headaches may include SIH, which often poses a real diagnostic challenge. In some patients, the location of a fluid fistula may be very challenging. There are several imaging tests used to diagnose cause of SIH; however, CT myelography turned to be the best choice, because it precisely showed the place of leakage. At the same time, both MRI and radioisotope cisternography were ineffective. Mokri presented in this study the same results – 67% versus 50% effectiveness for the diagnosis of SIH for the CT myelography and MRI, respectively.<sup>[16]</sup>

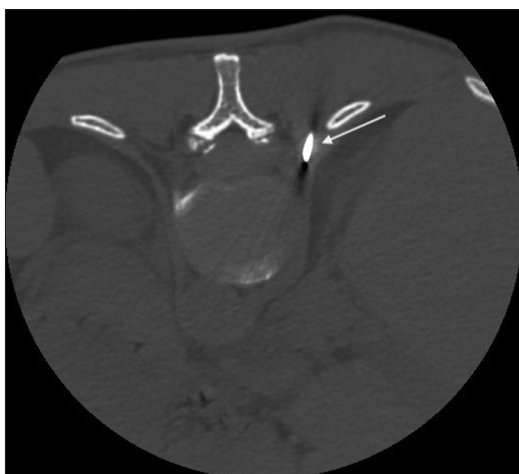
Bed rest is the first and primary recommendation for the treatment of SIH and it is usually effective. The same authors stated that a 2-week bed rest is sufficient time to control that disease, whereas other authors stated that conservative treatment alone could not be effective.<sup>[15,19,24]</sup> Such discrepancies are caused by the difficulty in fulfilling

the bed rest recommendation precisely. Patients in stable condition can experience deterioration very quickly or even go to critical due to cerebral wedging, caused by intracranial hypotension. Dr. Turek *et al.* are one of the first to point out a severe complication due to noncompliance with bed rest as a cause of brain wedging in patients with SIH.<sup>[20]</sup>

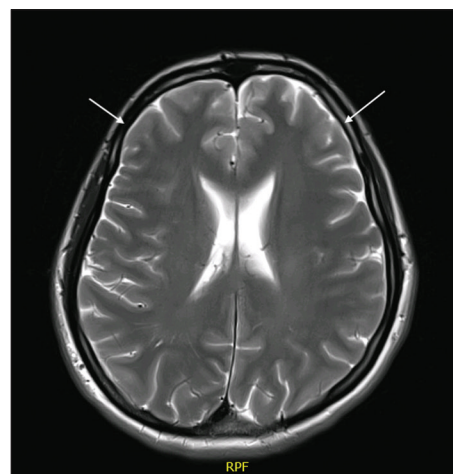
In this study, we presented a new approach in the treatment of SIH in cases when conservative treatment turned out to be ineffective. It consists in epidural sealing of the dural fistula with a blood patch formed from the patient's venous blood, injected directly to the intravertebral foramen under guidance of CT. This minimally invasive procedure is a modification of a standard epidural blood patch injection similar to epidural blockade, but under guidance of fluoroscopy. We think that in the cases of damage to the nerve root sheath on the level of intravertebral foramen, using our modification, we are



**Figure 5:** EBP under CT guidance, root sheath covered with patient's venous blood (area in the circle).



**Figure 4:** Controlling the needle positioning (arrow) during EBP under CT guidance, needle in the intervertebral canal on the right side Th12/L1.



**Figure 6:** CT scan performed 1 month after the EBP under CT guidance, complete disappearance of the fluid collections (arrowheads).

able to provide the blood patch more accurately for a more effective sealing of the damaged dura. With regard to other authors, we fully agree that using the contrast agent allows to visualize the administration site.<sup>[5,9,14,23]</sup> It is also our believe that the use of contrast is reasonable for sealing techniques with epidural administration into the spinal canal. However, in our opinion, the use of contrast agents is not essential in the technique of sealing throughout intravertebral foramen under the guidance of CT, because these techniques provide excellent efficacy of the correct needle location, for example, in the intervertebral foramen below the nerve root. Moreover, even without contrast enhancement, the blood patch is visible in the intervertebral foramen, which has been showed in [Figure 5]. In the literature, this type of procedure was performed in the prone position of the patients, which required administration of a large volume of blood.<sup>[5,9,14,23]</sup> The first step of the procedure is also performed in the prone position, but afterward, the patient is positioned on the side opposite to the leak which allows to use smaller volume of blood as well as to cover the damaged nerve root sheath more accurately and, consequently, may provide greater therapeutic efficacy. It is our believe that this procedure should be considered in all patients in whom conservative treatment was not effective, and the fistula site was visualized on the level of intervertebral foramen. We are convinced that the described method, involving sealing the fluid fistula under CT guidance, is much more likely to be effective than previously used standard epidural injections administered with the use of fluoroscopy. In our reported case, the patient's complaints subsided and the procedure was uneventful.

## CONCLUSION

Improperly treated SIH is a potentially fatal disease. Conservative treatment includes bed rest and, in most cases, is effective and may reduce the rate of serious complications. If conservative treatment is ineffective, a blood patch inserted to epidural space may be another treatment choice. We proposed modification of standard blood patch procedure for cases with damaged nerve root sheath on the level of intervertebral foramen by performing a blood patch through intervertebral foramen under guidance of CT. The procedure turned out to be easy, safe, and effective in the treatment of SIH.

## Declaration of patient consent

The authors certify that they have obtained all appropriate patient consent.

## Financial support and sponsorship

Nil.

## Conflicts of interest

There are no conflicts of interest.

## REFERENCES

- Allmendinger AM, Lee TC. Spontaneous intracranial hypotension from calcified thoracic disc protrusions causing CSF leak successfully treated with targeted epidural blood patch. *Clin Imaging* 2013;37:756-61.
- Berroir S, Loisel B, Ducros A, Boukobza M, Tzourio C, Valade D, *et al.* Early epidural blood patch in spontaneous intracranial hypotension. *Neurology* 2004;63:1950-1.
- Bezov D, Ashina S, Lipton R. Post-dural puncture headache: Part II prevention, management, and prognosis. *Headache* 2010;50:1482-98.
- Burch R, Rizzoli P, Loder E. The prevalence and impact of migraine and severe headache in the united states: figures and trends from government health studies. *Headache* 2018;58:496-505.
- Cho KI, Moon HS, Jeon HJ, Park K, Kong DS. Spontaneous intracranial hypotension: Efficacy of radiologic targeting vs blind blood patch. *Neurology* 2011;76:1139-44.
- Dillon WP, Fishman RA. Some lessons learned about the diagnosis and treatment of spontaneous intracranial hypotension. *AJNR Am J Neuroradiol* 1998;19:1001-2.
- Dripps RD, Vandam LD. Long-term follow-up of patients who received 10,098 spinal anesthetics: Failure to discover major neurological sequelae. *J Am Med Assoc* 1954;156:1486-91.
- Forghani R, Farb RI. Diagnosis and temporal evolution of signs of intracranial hypotension on MRI of the brain. *Neuroradiology* 2008;50:1025-34.
- Franzini A, Messina G, Nazzi V, Mea E, Leone M, Chiapparini L, *et al.* Spontaneous intracranial hypotension syndrome: A novel speculative physiopathological hypothesis and a novel patch method in a series of 28 consecutive patients. *J Neurosurg* 2010;112:300-6.
- Fullam L, Saidha S, Harrington H, MacEaney P. Spontaneous intracranial hypotension. *Ir J Med Sci* 2011;180:587-8.
- Garcia-Morales I, Porta-Etessam J, Galan L, Lagares A, Molina JA. Recurrent subdural haematomas in a patient with spontaneous intracranial hypotension. *Cephalalgia* 2001;21:703-5.
- Haritanti A, Karacostas D, Drevelengas A, Kanellopoulos V, Paraskevopoulou E, Lefkopoulos A, *et al.* Spontaneous intracranial hypotension: Clinical and neuroimaging findings in six cases with literature review. *Eur J Radiol* 2009;69:253-9.
- Hoffmann J, Goadsby P. Update on intracranial hypertension and hypotension. *Curr Opin Neurol* 2013;26:240-7.
- Lee JY, Lee MJ, Park HJ, Park JH, Jeong HJ, Oh MS, *et al.* Clinical effect of the proximity of epidural blood patch injection to the leakage site in spontaneous intracranial hypotension. *Br J Neurosurg* 2018;32:671-3.
- Liang H, Xu C, Liu T, Huang S, Hu S. Spontaneous intracranial hypotension in Hashimoto's thyroiditis. *Medicine* 2019;98:e15476.
- Mokri B. Spontaneous cerebrospinal fluid leaks: From intracranial hypotension to cerebrospinal fluid hypovolemia evolution of a concept. *Mayo Clin Proc* 1999;74:1113-23.

17. Munoz-Ceron J, Marin-Careaga V, Peña L, Mutis J, Ortiz G. Headache at the emergency room: Etiologies, diagnostic usefulness of the ICHD 3 criteria, red and green flags. *PLoS One* 2019;14:e0208728.
18. Schievink WI, Dodick DW, Mokri B, Silberstein S, Bousser MG, Goadsby PJ. Diagnostic criteria for headache due to spontaneous intracranial hypotension: A perspective. *Headache* 2011;51:1442-4.
19. Sugino T, Matsusaka Y, Mitsuhashi Y, Murata K, Sakaguchi M. Intracranial hypotension due to cerebrospinal fluid leakage detected by radioisotope cisternography. *Neurol Med Chir* 2000;40:404-7.
20. Turek G, Rogala A, Ząbek M, Ząbek M. Bed regime as a lifesaving factor in spontaneous intracranial hypotension. *Neurol Neurochir Pol* 2021;55:407-9.
21. Tyagi A. Management of spontaneous intracranial hypotension. *Pract Neurol* 2016;16:87-8.
22. Williams EC, Buchbinder BR, Ahmed S, Alston TA, Rathmell JP, Wang J. Spontaneous intracranial hypotension: Presentation, diagnosis, and treatment. *Anesthesiology* 2014;121:1327-33.
23. Wu JW, Hseu SS, Fuh JL, Lirng JF, Wang YF, Chen WT, *et al.* Factors predicting response to the first epidural blood patch in spontaneous intracranial hypotension. *Brain* 2017;140:344-52.
24. Zheng Y, Lian Y, Wu C, Chen C, Zhang H, Zhao P. Diagnosis and treatment of spontaneous intracranial hypotension due to cerebrospinal fluid leakage. *Springerplus* 2016;5:2108.

**How to cite this article:** Zabek MM, Turek G. Original technique of sealing cerebrospinal fluid leakage from dural sac causing spontaneous cerebral hypotension. *Surg Neurol Int* 2022;13:215.