

Received: 2020.11.16

Accepted: 2021.07.12

Available online: 2021.07.19

Published: 2021.08.30

May-Thurner Syndrome: A Rare Case of Unilateral Deep Vein Thrombosis in an Elderly Woman

Authors' Contribution:

Study Design A
Data Collection B
Statistical Analysis C
Data Interpretation D
Manuscript Preparation E
Literature Search F
Funds Collection G

ABCDEF 1 **Ayesha Siddiq**
ABCDEF 1 **Asim Haider**
ABCDEF 1 **Ked Fortuzi**
ABCDEF 1,2 **Muhammad Adrish**
ABCDEF 3 **Charbel Ishak**

1 Department of Internal Medicine, BronxCare Health System, Bronx, NY, USA
2 Department of Pulmonary Critical Care, BronxCare Health System, Bronx, NY, USA
3 Department of Interventional Radiology, BronxCare Health System, Bronx, NY, USA

Corresponding Author: Ayesha Siddiq, e-mail: ashsiddiq@gmail.com

Conflict of interest: None declared

Patient: Female, 78-year-old
Final Diagnosis: May-Thurner syndrome
Symptoms: Lower extremity edema • lower extremity pain
Medication: —
Clinical Procedure: —
Specialty: Critical Care Medicine • Hematology • General and Internal Medicine • Radiology

Objective: Rare disease





Background: Deep vein thrombosis (DVT) is a critical disorder with a high incidence and a high disease burden. Multiple acquired and genetic factors leading to hypercoagulation, venous injury, and venous stasis account for its basic pathophysiology. One of the rarely considered underlying etiologies of DVT is May-Thurner Syndrome (MTS), also known as iliac vein compression syndrome. MTS is an anatomical variant in which the left common iliac vein is extrinsically compressed by the right common iliac artery against the lumbar spine, leading to the development of iliofemoral DVT.

Case Report: We present the case of a 78-year-old woman who presented with chronic unilateral lower-extremity swelling and pain. Ultrasound was consistent with extensive DVT extending from the left common femoral vein to left popliteal vein. Further workup revealed left common iliac venous outflow obstruction due to the extrinsic compression by the overlying atherosclerotic calcified right common iliac artery crossing against the lumbosacral region.

Conclusions: MTS usually presents in the second to fourth decades of life, making it challenging to consider it as a differential diagnosis in older patients. The conventional treatment of DVT with anticoagulation alone is insufficient to address thrombotic MTS and can lead to recurrent DVT, post-thrombotic syndrome, and life-threatening complications. Our patient presented in the seventh decade of life, warranting a high index of clinical suspicion of MTS in patients presenting with unilateral leg DVT, regardless of patient age, for timely diagnosis and appropriate therapeutic management.

Keywords: May-Thurner Syndrome • Postthrombotic Syndrome • Venous Thrombosis

Full-text PDF: <https://www.amjcaserep.com/abstract/index/idArt/929897>

 1449   4  26



Background

May-Thurner syndrome (MTS) was first defined in 1957 when 22% of 430 cadavers on autopsy were found to have iliac vein compression against the lumbar vertebra by the overlying common iliac artery, leading to iliac venous outflow obstruction [1-4]. It is a pathological and anatomical variable, and its clinical manifestation correlates with an underlying venous obstruction, and may vary from being asymptomatic to thrombotic or non-thrombotic unilateral chronic venous hypertension. The actual clinical incidence and prevalence of MTS are unknown. Among patients who present with symptomatic lower-extremity venous disorder, MTS is estimated to be the etiology in only 2-5% of patients. However, multiple cadaveric and retrospective radiographic studies have suggested much higher incidence and overall prevalence [5-7].

Case Report

A 78-year-old woman with medical comorbidities of hyperlipidemia, hypertension, and chronic obstructive pulmonary disease (COPD) initially presented for gradually worsening left lower-leg pain, swelling, and edema over 1 month, along with the inability to ambulate for about 3 weeks. The patient denied any

associated trauma, fever, recent travel, hiking, or tick bites. The patient further denied any smoking, history of previous clots, or bleeding disorders. Home medications included nifedipine, lisinopril, simvastatin, Ventolin, and umeclidinium. On physical examination, the left calf had a mottled appearance with bluish discolorations representing impeding phlegmasia cerulea dolens. The left calf was tender to palpation, with a positive Homans sign (Figure 1). The left femoral, popliteal, posterior tibial, and dorsalis pedis pulses were present (2+), and sensation and motor reflexes were intact. Lab results were consistent with leukocytosis (WBC 20K/uL) and elevated D-dimer (10905 ng/mL). Creatinine kinase (CK), C reactive protein (CRP), pro-BNP, erythrocyte sedimentation rate (ESR), international normalized ratio (INR), and fibrinogen were within the normal reference ranges. Left lower-extremity Doppler ultrasound revealed acute deep vein thrombosis (DVT) extending from the non-compressible common femoral vein down to the popliteal vein level (Figure 2). A heparin drip was started, and an interventional radiologist (IR) was consulted for emergent endovascular percutaneous thrombolysis of extensive DVT. Computed tomography (CT) venography done before IR intervention, revealed an overlying atherosclerotic calcified right common iliac artery extrinsically compressing the left iliac vein's origin against the prominent lumbosacral promontory, leading to outflow obstruction of left common iliac vein (Figure 3). CT chest

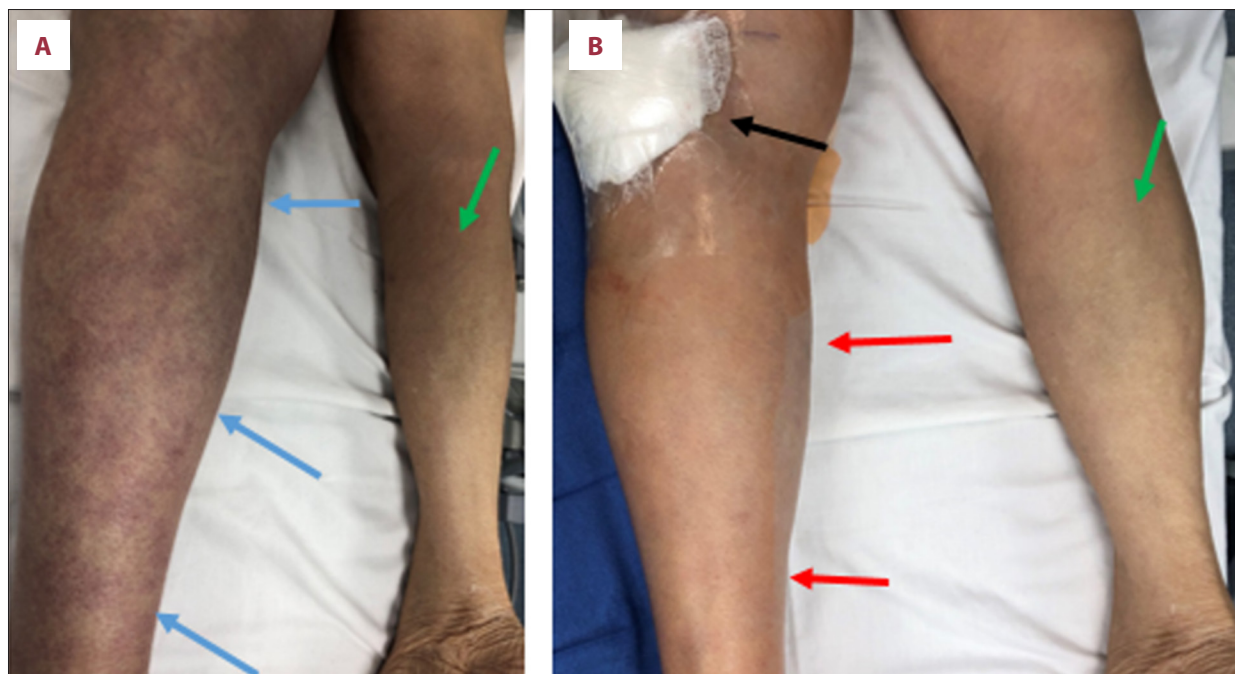


Figure 1. Photographs of patient's lower extremities in prone position before (A) and after thrombolysis, thrombectomy, and stenting of left iliac vein (B). Note the swelling and skin discolorations over the left calf (reddish alternating with bluish colored areas, blue arrows) due to obstructed venous return and resulting decreased in arterial inflow, representing impeding development of phlegmasia cerulea dolens, when compared to the right leg (green arrows). Complete resolution of the above physical examination findings (red arrows) after left iliac venous endovascular revascularization procedures via left popliteal venous access (black arrow). (Copyright and courtesy of author CI).

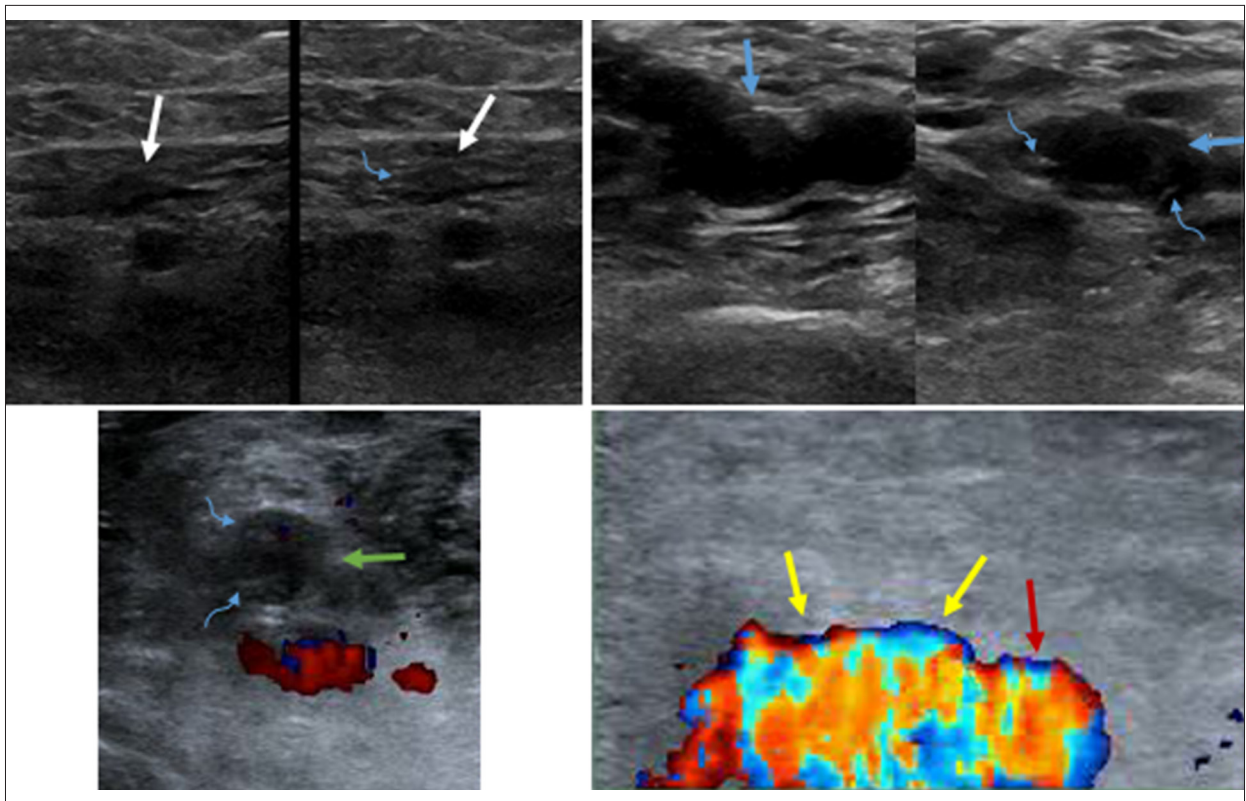


Figure 2. Sonography of the left lower extremity demonstrated echogenic intraluminal structures (curved blue arrows) compatible with deep venous thrombosis (DVT), non-compressible left common femoral (blue arrows), and superficial femoral (white arrows) and popliteal veins (green arrow) in a patient presenting with left leg swelling and discoloration. Note the left common femoral venous patency (yellow arrow) after thrombolysis, thrombectomy, and stenting of left common iliac vein. Patent left common femoral artery (red arrow).

with contrast was negative for any acute pulmonary embolism. A left popliteal venous approach was performed under sonography to place inferior vena cava (IVC) filter followed by clot lysis using endovascular percutaneous pharmacomechanical (PMT) and rheolytic power pulse thrombolysis and thrombectomy using an ANGIOJET device (Boston Scientific, MA) of left ilio-femoral-popliteal extensive venous thrombosis. Following the initial clot lysis, angioplasty and revascularization of left common iliac occlusion were performed using intravascular VENOVO stent (14 mm×8 cm) (Figure 4). Post-operatively, the patient was continued on a heparin drip directly through the left popliteal venous sheath for at least 48 h. Following sheath removal, oral apixaban was started. The patient was then discharged with outpatient hematology follow-up and anticoagulation duration to be determined depending on the resolution of clot and symptoms.

Discussion

The classic clinical presentation is a 20-40-year-old woman with chronic (≥ 4 to 6 weeks) left lower-extremity swelling [5,8]. Lower-limb swelling in MTS may or may not be associated with

DVT. Therefore, any chronic unilateral limb swelling without evidence of DVT must be evaluated for underlying MTS. Common clinical presentations of symptomatic MTS include acute extremity pain and swelling, venous claudication, chronic development of venous insufficiency (eg, edema, skin discoloration, or skin ulceration), or, rarely, pelvic congestion syndrome [9].

The left iliofemoral venous endothelium becomes irritated by the overriding common iliac artery chronic pulsatile stimulation, leading to local intimal injury, inflammation, and scarring, ultimately leading to a spectrum of venous occlusive lesions. However, due to the establishment of collateral circulation over time, most individuals with MTS anatomy remain asymptomatic unless the underlying venous obstruction is critical, if or short-lived risk factors, including pregnancy, surgery, or postpartum, precipitate a DVT [7]. In a prospective analysis done to determine the incidence and prevalence of MTS in asymptomatic patients, 9% of 500 patients were found to have more than 50% common iliac vein compression, with an incidence rate of 1.6% over 40-month follow-up [10]. Another study used a CT scan to screen 50 patients who presented with only abdominal complaints without any associated lower-extremity

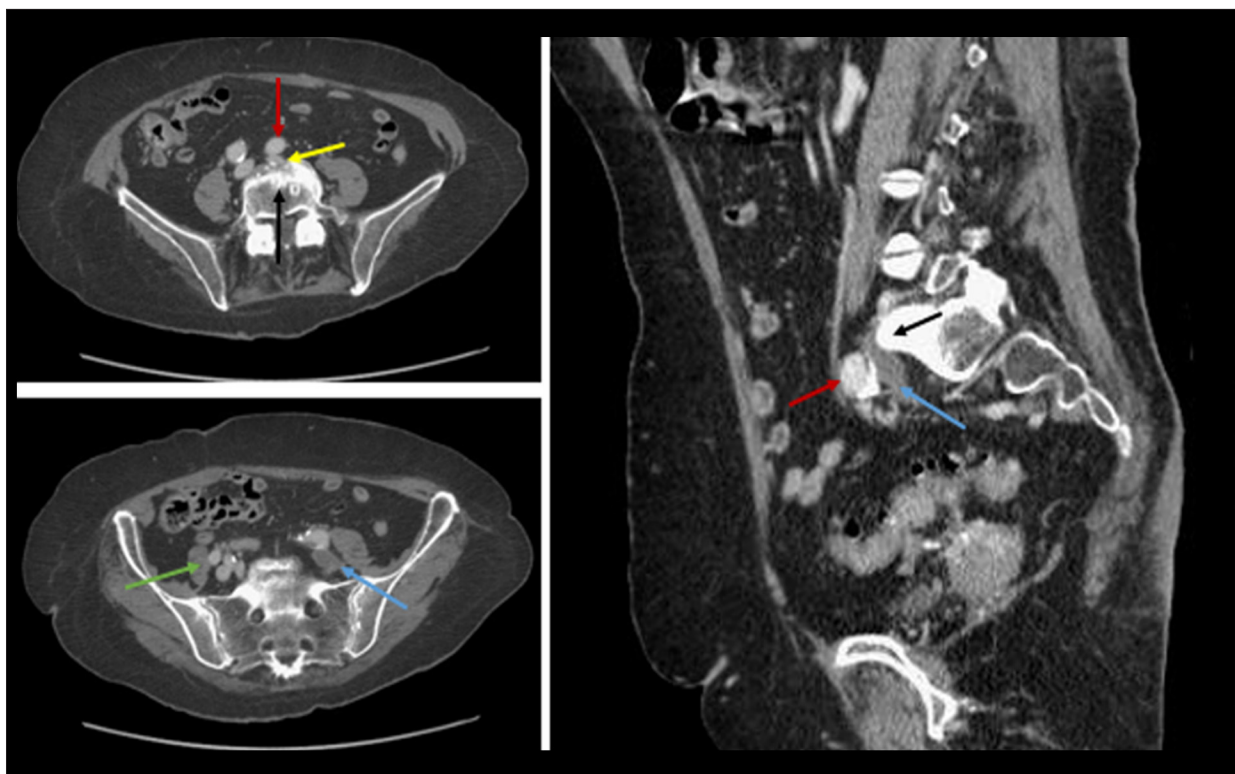


Figure 3. Axial and sagittal pelvic computed tomography venography (CTV) demonstrated left common iliac venous outflow obstruction caused by extrinsic compression of the origin of the left iliac vein (yellow arrow) by the overlying atherosclerotic calcified right common iliac artery (red arrows) crossing against the prominent lumbosacral promontory (black arrow), with resulting thrombosis along the distal left common iliac vein (blue arrows) when compared to patent right common iliac vein (green arrow).

symptoms. Results showed that 25% of the individuals had hemodynamically significant lesions causing at least 50% stenosis in the left common iliac vein. In contrast, 66% had at least 25% compression [4,7].

Despite the relatively high incidence of this pathological variant reported by multiple radiographic and cadaveric studies, clinically, only about 2-3% of all lower-extremity DVTs are attributed to MTS-related DVT [5]. One hypothesis of MTS underdiagnosis is the relatively high prevalence of other more easily recognized risk factors for DVT, including the history of oral contraceptive use, recent prolonged travel, or recent pregnancy, limiting the further diagnostic workup for DVT etiologies in patients with identifiable risk factors. However, conventional treatment of DVT with anticoagulation alone is not sufficient for addressing MTS. It is a progressive disease and warrants a high clinical suspicion for timely diagnosis and therapeutic management [5]. Failure to address the underlying anatomic-variant MTS can lead to DVT recurrence, post-thrombotic syndrome (PTS), and life-threatening complications, including iliac vein rupture and pulmonary embolism. PTS is the most common long-term adverse event of untreated or residual thrombus, with an incidence rate of 20-50%. Clinically, PTS manifests

as venous claudication, venous ulcers, or phlegmasia cerulea dolens, leading to poor quality of life [11-13].

A definitive diagnosis of MTS requires a demonstration of the stenotic venous lesion in an appropriate anatomic location. Doppler venous ultrasound has high specificity and sensitivity for the recognition of proximal DVT. However, its utility is limited due to underlying technical difficulties in evaluating the iliac vein and inferior vena cava. Moreover, MTS-associated anatomical defects occur high in the pelvis, an area that cannot be visualized by venous ultrasound [5,14]. Both CT and magnetic resonance (MR) venograms have more than 95% sensitivity and specificity for diagnosing MTS. They are useful in detecting venous collaterals, approximating the stenosis's location, and intensity in non-thrombosed veins, and ruling out other iliac vein compression causes, like, cellulitis, and hematoma. However, the use of CT or MR venography may be limited because of cost. Moreover, a frequent drawback associated with CT venography is the overestimation of the intensity of compression in a dehydrated patient, as it cannot account for the patient's volume status. Furthermore, due to the variability of left common iliac venous compression over time, a single MRV may not be adequate to diagnose MTS [15-17].

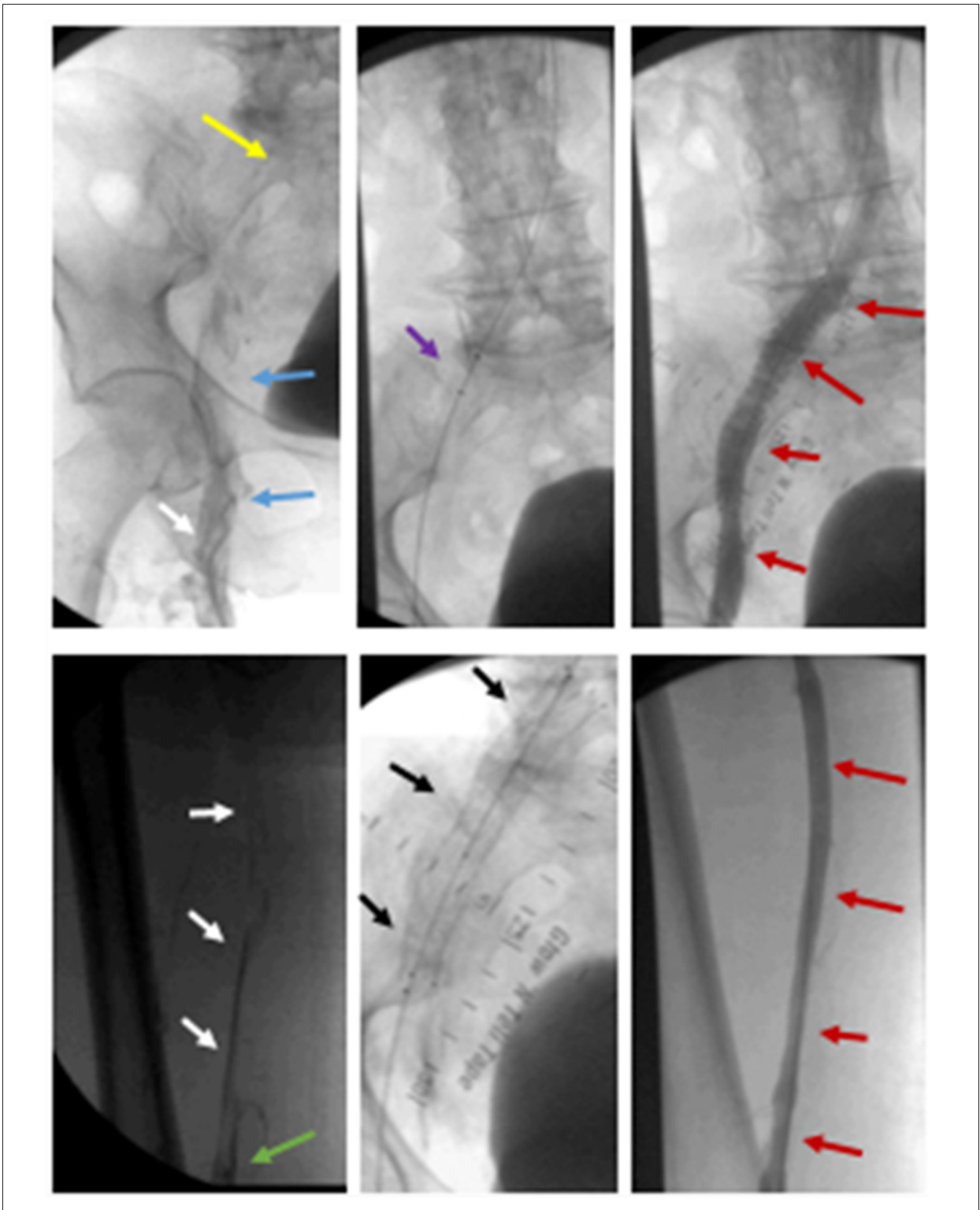


Figure 4. Pelvic venographic images in prone position demonstrating deep venous thrombosis (DVT) along the left common femoral (blue arrows), superficial femoral (white arrows) and popliteal veins (green arrow), with complete patency (red arrows) of left iliofemoral-popliteal venous axis after thrombolysis thrombectomy (Angiojet radiopaque markers, purple arrow), and deployment of venous stent (Venovo, black arrows) along the previously compressed left common iliac vein (yellow arrow) with stent extending toward the left external iliac vein in this patient with May-Thurner Syndrome.

The criterion standard diagnostic test for MTS is conventional venography with intravascular ultrasound (IVUS). The sensitivity and specificity of IVUS for evaluating venous stenosis exceeds 98%. IVUS can evaluate the spur's accurate and detailed morphology and estimate the distribution and severity of pathology. Moreover, it provides a real-time evaluation of the vessel diameter, aiding precise stent placement, guaranteeing full stent expansion, estimating the gain in cross-sectional area, and, with follow-up, identifying the severity of in-stent restenosis. Another significant advantage of IVUS is the lack of contrast usage to avoid contrast-related nephropathy and allergies [18-20].

The therapeutic management of MTS is determined by: (a) presence of symptoms, (b) their severity, and (c) presence or absence of DVT. Conservative management with compression stockings is recommended for asymptomatic and non-thrombotic patients. However, anticoagulation alone is insufficient to treat and prevent long-term sequelae in thrombotic MTS [21,22]. A more invasive therapeutic approach, like catheter-directed thrombolysis combined with percutaneous mechanical thrombectomy, is indicated for immediate symptom relief and reduces post-thrombotic syndrome incidence. Moreover, to preclude further embolization during lytic therapy, inferior vena cava filter insertion is highly recommended before any lower- extremity intervention, especially in individuals with large clot burdens. Following initial clot lysis, the recommended therapy includes continuous thrombolytic infusion for an

additional 24-48 h, followed by intravascular stent placement in iliac vein compression. After stent placement, at least 6 months of anticoagulation therapy is recommended [23-26].

Conclusions

MTS is a progressive disease with long-term disabling complications. Failure to address the underlying anatomic lesion in MTS can lead to recurrence and life-endangering complications, including iliac vein rupture, pulmonary emboli, and post-thrombotic syndrome. Therefore, physicians need to keep a high MTS suspicion index in patients presenting with chronic unilateral left-limb swelling, regardless of their age. Combined iliofemoral clot lysis with thrombolysis and thrombectomy, followed by common iliac vein stent placement and at least 6 months of anticoagulation, remains the mainstay therapy.

Conflict of Interests

None.

Declaration of Figures Authenticity

All figures submitted have been created by the authors who confirm that the images are original with no duplication and have not been previously published in whole or in part.

References:

1. England R. Towards a classification of left common iliac vein compression based on triplanar phlebography. *Surgical Science*. 2017;8:19-26
2. McMurrich, JP. The occurrence of congenital adhesions in the common iliac veins, and their relation to thrombosis of the femoral and iliac veins. *Am J Med Sci*. 1908;135:342-45
3. May R, Thurner J. The cause of the predominantly sinistral occurrence of thrombosis of the pelvic veins. *Angiology*. 1957;8:419-27
4. Padrnos LJ, Garcia D. May-Thurner syndrome and thrombosis: A systematic review of antithrombotic use after endovascular stent placement. *Res Pract Thromb Haemost*. 2018;3(1):70-78
5. Peters M, Syed RK, Katz M, et al. May-Thurner syndrome: A not so uncommon cause of a common condition. *Proc (Bayl Univ Med Cent)*. 2012;25(3):231-33
6. Cockett FB, Thomas ML, Negus D. Iliac vein compression: Its relation to iliofemoral thrombosis and the post-thrombotic syndrome. *Br Med J*. 1967;2:14-19
7. Kibbe MR, Ujiki M, Goodwin AL, et al. Iliac vein compression in an asymptomatic patient population. *J Vasc Surg*. 2004;39:937-43
8. Moudgill N, Hager E, Gonsalves C, et al. May-Thurner syndrome: Case report and review of the literature involving modern endovascular therapy. *Vascular*. 2009;17:330-35
9. Khan TA, Rudolph KP, Huber TS, Fatima J. May-Thurner syndrome presenting as pelvic congestion syndrome and vulvar varicosities in a nonpregnant adolescent. *J Vasc Surg Cases Innov Tech*. 2019;25:252-54
10. Cheng L, Zhao H, Zhang FX. Iliac vein compression syndrome in an asymptomatic patient population: A prospective study. *Chin Med J (Engl)*. 2017;130(11):1269-75
11. McLafferty RB. Evidence of prevention and treatment of postthrombotic syndrome. *J Vasc Surg*. 2010;52(5 Suppl.):69S-73S
12. Henke P, Vandy F, Comerota A, et al. Prevention and treatment of the post-thrombotic syndrome. *J Vasc Surg*. 2010;52:21-28
13. Kovač A, Janić M, Nuredini D, Kozak M. The influence of May-Thurner syndrome on post-thrombotic syndrome in young women. *Vasa*. 2019;48:393-98
14. Lensing AW, Prandoni P, Brandjes D, et al. Detection of deep-vein thrombosis by real-time B-mode ultrasonography. *N Engl J Med*. 1989;320(6):342-45
15. McDermott S, Oliveira G, Ergül E, et al. May-Thurner syndrome: Can it be diagnosed by a single MR venography study? *Diagn Interv Radiol*. 2013;19:44-48
16. Oguzkurt L, Tercan F, Pourbagher MA, et al. Computed tomography findings in 10 cases of iliac vein compression (May-Thurner) syndrome. *Eur J Radiol*. 2005;55:421-25
17. Chung JW, Yoon CJ, Jung SI, et al. Acute iliofemoral deep vein thrombosis: Evaluation of underlying anatomic abnormalities by spiral CT venography. *J Vasc Interv Radiol*. 2004;15(3):249-56
18. Forauer AR, Gemmete JJ, Dasika NL, et al. Intravascular ultrasound in the diagnosis and treatment of iliac vein compression (May-Thurner) syndrome. *J Vasc Interv Radiol*. 2002;13:523-27
19. Hager ES, Yuo T, Tahara R, et al. Outcomes of endovascular intervention for May-Thurner syndrome. *J Vasc Surg Venous Lymphat Disord*. 2013;1(3):270-75
20. Ahmed HK, Hagspiel KD. Intravascular ultrasonographic findings in May-Thurner syndrome (iliac vein compression syndrome). *J Ultrasound Med*. 2001;20:251-56
21. Comerota AJ. The ATTRACT trial: Rationale for early intervention for iliofemoral DVT. *Perspect Vasc Surg Endovasc Ther*. 2009;21:221-25
22. Du GC, Zhang MC, Zhao JC. Catheter-directed thrombolysis plus anticoagulation versus anticoagulation alone in the treatment of proximal deep vein thrombosis – a meta-analysis. *Vasa*. 2015;44:195-202

23. Zhang X, Shi X, Gao P, et al. Endovascular management of May-Thurner syndrome: A case report. *Medicine (Baltimore)*. 2016;95(4):e2541
24. Patel NH, Stookey KR, Ketcham DB, Cragg AH. Endovascular management of acute extensive iliofemoral deep venous thrombosis caused by May-Thurner syndrome. *J Vasc Interv Radiol*. 2000;11:1297-302
25. Heijmen RH, Bollen TL, Duyndam DA, et al. Endovascular venous stenting in May-Thurner syndrome. *J Cardiovasc Surg (Torino)*. 2001;42(1):83-87
26. O'Sullivan GJ, Semba CP, Bittner CA, et al. Endovascular management of iliac vein compression (May-Thurner) syndrome. *J Vasc Interv Radiol*. 2000;11(7):823-36