

Hirudotherapy Efficacy and Complications in the Management of Microsurgical Breast Reconstruction: A Systematic Review

#Jose Foppiani¹, #Angelica Hernandez Alvarez¹, Allan Weidman¹, Lauren Valentine¹, Stephen Stearns¹, Samuel J. Lin^{1*}

1. Division of Plastic and Reconstructive Surgery, Beth Israel Deaconess Medical Center, Harvard Medical School, Boston, MA, USA

Co-first Authors

***Corresponding Author:**

Samuel J. Lin, MD, MBA
110 Francis Street Suite 5A,
Boston, MA 02215

Email: sjlin@bidmc.harvard.edu

Received: 9/6/2024

Accepted: 14/10/2024

ABSTRACT

Background: We aimed to assess the effect of hirudotherapy on flap congestion and thrombosis in adult female patients who underwent microvascular breast reconstruction.

Methods: A systematic review of PubMed, Web of Science, and Cochrane was completed. A qualitative synthesis of all included studies was then performed.

Results: Twelve studies were included, pooling 34 female patients with ages ranging from 28 to 64 years old, having received medical leech therapy to breast flap following microsurgical breast reconstruction for a duration ranging from 1 to 10 days. The most common flap in our patient population was the Transverse Abdominis (TRAM) flap, followed by the Deep Inferior Epigastric (DIEP) flap and lastly, the Latissimus Dorsi flap. Nine patients experienced flap loss (26.5%), 9 experienced infections (26.5%), 19 had some degree of flap necrosis (55.9%), and 8 patients had to return to the operating room for revision surgeries (23.5%). Of the 9 reported cases of infection, 6 grew cultures specific to leech pathogens, confirming hirudotherapy as the cause (17.6%).

Conclusion: Presently, this systematic review provides an overview of the role that hirudotherapy has played in the management of congestion in breast microvascular reconstruction in the literature. Clinicians should be aware of the complications associated with this choice of therapy for their patients, especially infection. Despite their established use in flap congestion, the limited evidence available for hirudotherapy to treat flap complications in autologous breast reconstruction calls for more studies to be conducted on the matter.

KEYWORDS

Hirudotherapy; Microsurgical Breast Reconstruction; Flap Congestion; Flap Thrombosis; Therapeutic Outcomes

Please cite this paper as:

Foppiani J, Alvarez AH, Weidman A, Valentine L, Stearns S, Lin SJ. Hirudotherapy Efficacy and Complications in the Management of Microsurgical Breast Reconstruction: A Systematic Review. *World J Plast Surg.* 2024;13(3):3-13.

doi: 10.61186/wjps.13.3.3

INTRODUCTION

With goals of plastic surgery being to re-establish function and cosmesis to areas of the human body following trauma or surgery, breast reconstruction holds particular importance in shaping an individual's self-perception as well as society's view of that person^{1,2}. The loss of breast tissue following trauma or surgery as part of treatment or prophylaxis for breast cancer is often traumatic for patients^{1,2}. As of 2022, an estimated 287,850 new cases of invasive breast cancer are expected to be diagnosed in women in the U.S. alone, along with 51,400 new cases of non-invasive (in situ) breast cancer³. Following their treatment, the survivors of these disfiguring malignancies often turn to plastic surgery to help recover an aesthetic and functional breast contour.

Breast reconstruction has progressed significantly since its inception, with both implant-based reconstruction and autologous reconstruction as viable options to reconstruct almost any type of defect⁴. Autologous reconstruction in particular has been shown to result in long-term reconstructive longevity and patient satisfaction, with benefits that include a more natural appearance, shape and restoration of sensation⁵. Despite the advancement in microsurgical techniques and monitoring of flaps, tissue congestion, thrombosis, and failures remain possible complications of autologous breast reconstruction⁶⁻⁸.

Hirudotherapy is an FDA-approved therapeutic approach widely referenced in the literature for the treatment of flap congestion⁹⁻¹¹. This approach has been used therapeutically early in the history of mankind, with one of the first recorded use of leeches dating to the bronze age (1500BC)¹². Hirudin, a naturally occurring antithrombotic agent within leeches' saliva led to the development of direct-thrombin inhibitor, saw a resurgence of its use since it was first employed for treating congested flaps in 1960¹³. Their utilization in the field of plastic surgery for flap congestion has since been well-established, with an estimated improvement in flap survival between 70 and 80 percent¹³. Hirudotherapy works through multiple mechanisms to both prevent and alleviate existing venous congestion. Placement of leeches directly to the congested tissue bed allows for them to make small bites in the flap. The

salivary glands of leeches release various vasoactive substances that assist in local anticoagulation, anti-inflammation, and anesthesia. The active sucking and consumption of the blood by the leeches also result in a decrease in capillary pressure¹⁴.

Nonetheless, the outcome of hirudotherapy for breast microvascular reconstruction complication has not yet been thoroughly investigated⁹⁻¹¹. Thus, this paper aims to assess the effect of hirudotherapy on flap congestion and thrombosis in patients 18 years and older undergoing microvascular breast reconstruction.

METHODS

This study protocol was prospectively registered with PROSPERO (Study # ID: CRD42022360395)¹⁵. This systematic review followed the Preferred Reporting Items for Systematic Reviews and Meta-Analysis (PRISMA) statement guidelines^{16,17}.

Eligibility Criteria

Criteria for included studies were defined as adult female patients who underwent autologous breast reconstruction and received medical leech therapy. The full eligibility criteria are accessible at PROSPERO¹⁵ and are as follows:

Inclusion criteria:

- Adult female patients
- Patient who underwent autologous breast reconstruction (microvascular)
- Patient who underwent hirudotherapy for flap related complications (venous congestion)
- Observational studies and clinical trials
- Case series and case reports
- Studies in English, French, and Spanish

Exclusion criteria:

- Editorials
- Commentary reports
- Abstracts with no full text available
- Letters to the editors
- Animal studies
- Cadaveric studies
- Studies where breast flap related outcome could not be identified

Search Strategy

A comprehensive research review using subject headings, controlled vocabulary, and keywords was conducted on September 25, 2022, on MEDLINE (in Ovid), Web of Science, and the Cochrane Central Register for studies published until 2021. Our full-text search strategy is accessible at PROSPERO¹⁵.

Study Selection

The search results were uploaded into the online systematic review program Covidence to conduct study selection¹⁸. Five independent reviewers performed a two-screening process for study selection (S.A.S., L.V., A.H.A., and A.W.) First, titles and abstracts were screened. A fifth reviewer (J.A.F.) moderated and if discordances were present, resolved the conflict. Next, a full-text analysis was performed by two reviewers (J.A.F and A.H.A.). If conflicts arose between reviewers, a third reviewer moderated a discussion to come to a joint decision.

Data Extraction/ Synthesis

A predetermined checklist guided data extraction: first author last name, year of publication, total sample size, gender, type of flaps, number of medical leeches used, and length of hirudotherapy, antibiotic therapy, flap outcomes, flap complications, and flap take back/re A operations.

Outcomes

The primary outcome was flap complications, reoperation and loss following hirudotherapy for microvascular breast reconstruction. Secondary outcomes encompassed the type of flap used in each patient, hirudotherapy protocol (length of therapy, number of leeches, prophylactic antibiotics), and cost of therapy.

Quality Assessment

To assess the risk of bias, we utilized the National Institute of Health (NIH) quality assessment tool¹⁹. Each article was categorized as follows: “low risk,” “moderate risk,” or “high risk” of bias. (SDC 1 - Quality of Evidence.)

SDC 1: Study Quality Assessment

Author	Risk of Bias
Ardehali, 2005	Low
Bourdais, 2009	Low
Butt, 2016	Low
Camara, 2009	High
Dabb, 1992	High
de Chalain, 1996	Low
Flurry, 2011	Moderate
Hwang, 2017	Low
Kruer, 2015	Low
Maetz, 2012	Low
Nguyen, 2012	Low
Pannucci, 2014	Low

Statistical Analysis

As described in the literature, meta-analysis, similarly to medical procedures have their own set of indications and limitations^{20, 21}. These are powerful tools, where heterogeneity in data can be accounted for, enabling conclusions to be drawn from small sample sizes^{20, 21}. In light of the complexities and challenges associated with studying hirudotherapy in the context of breast reconstruction, our systematic review has identified a notable gap in the literature. The dearth of randomized trials and the limited number of patients that can be gleaned from our observational studies means the available data are somewhat restricted in their scope. This has resulted in an environment where the development of a comprehensive understanding of the potential benefits and risks of hirudotherapy in this context is challenging. However, far from being a detraction, we view this as an important observation that underscores the necessity of our work. It is clear that there is a need for additional robust, methodologically sound studies focusing on hirudotherapy. Rather than creating a meta-analysis simply for the sake of it, and potentially providing misleading conclusions based on the limited available data, we instead chose to highlight this need for further exploration.

RESULTS

A total of 149 studies were initially retrieved following the removal of duplicates. Of those, 12 articles were ultimately included for qualitative analysis²²⁻³³. (Figure 1) They included 5 observational studies, 2 case series, and 5 case reports. Of the

12 articles, 9 were found to be at low risk of bias, 1 at moderate risk, and 2 at high risk based on the NIH quality assessment tool. The included studies included a total of 34 female patients, with ages ranging from 28 to 64 years old, having received medical leech therapy following microsurgical breast reconstruction (Table 1).

Among the dozen studies incorporated in our review, it's noteworthy to highlight the most frequently used flaps in our patient cohort. The Transverse Rectus Abdominis Myocutaneous (TRAM) flap was the most prevalent, utilized in 35% of the cases. This was followed by the Deep Inferior Epigastric Perforator (DIEP) flap, which was used in 26% of the instances. The Latissimus Dorsi flap, meanwhile, was employed in 12% of the cases (Table 2).

Of all the 12 included studies, the length of hirudotherapy ranged from 1 day to 10 days^{22-24, 26, 27, 31, 33}. Some studies did not contain extractable information for the length of leech therapy in their patient's populations^{25, 28-30, 32}. The number of leeches used was only available in the studies by Dabb et Al²⁶, Hwang et Al²⁹, and Pannucci et Al³³, which ranged from 9 to 41 leeches. All studies apart from Camara et Al²⁵, and Dabb et Al²⁶, described the use of antibiotic prophylaxis before medical leech application as part of their treatment protocol. No information was available in Camara et Al²⁵ or in Dabb et Al²⁶ regarding antibiotic prophylaxis. Given the accepted nature of hirudotherapy generally for the treatment of flap congestion in a variety of clinical settings, the

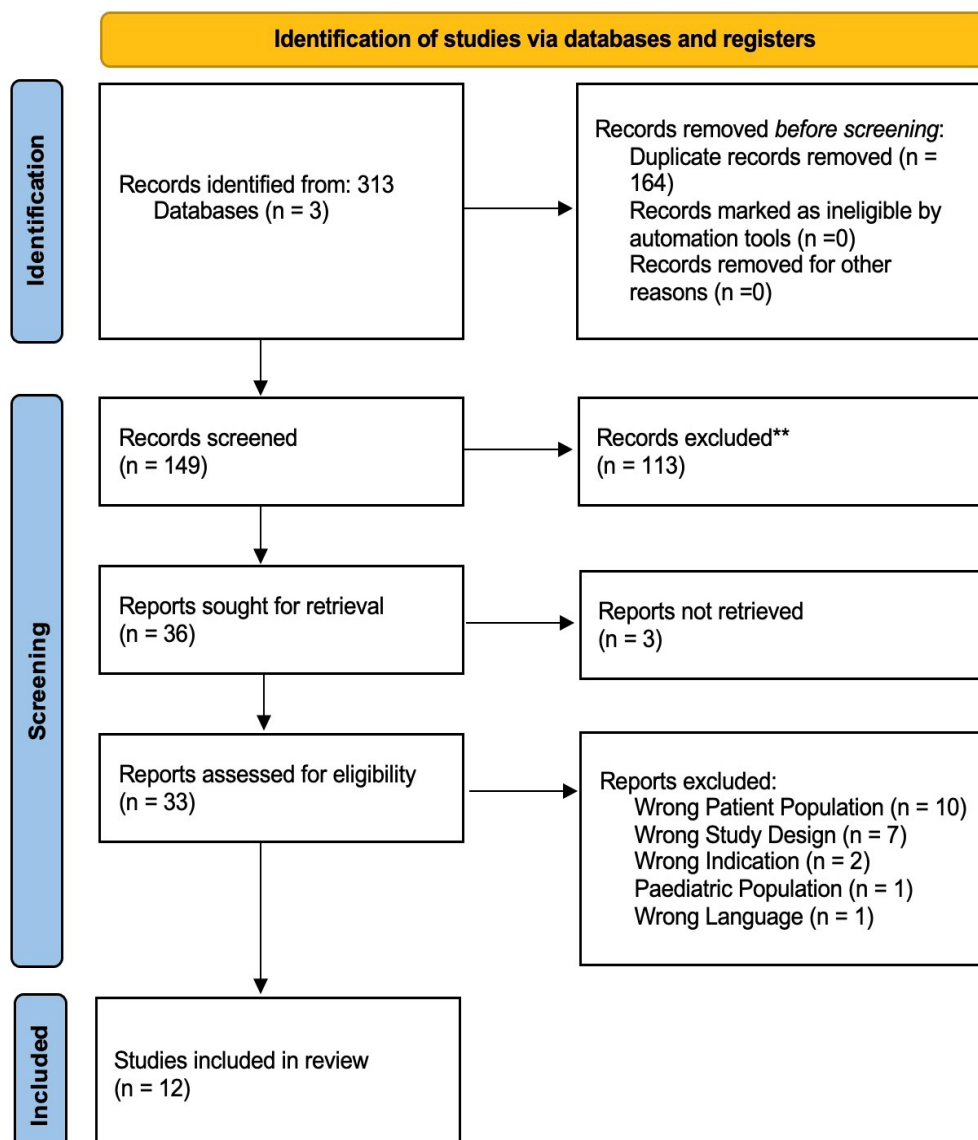


Figure 1: Prisma figure

number of leeches used likely varies greatly and underreported in the literature.

In our pooled population of 34 patients, 9 experienced flap loss (26.5%), 19 had some degree of flap necrosis (55.9%), 8 patients had to return to the operating room for revision surgeries (23.5%), and 9 experienced infections (26.5%) (**Table 3**). However, it is crucial to distinguish the nature of these infections. Specifically, only 6 out of these 9 infections, or 17.6% of the total patient population, were found to have cultures that were associated with leech-specific microbes, namely *Aeromonas hydrophilia* and *Aeromonas veronii biovar sobria*. This distinction is important because it suggests that not all reported infections can be directly attributed to the use of leech therapy. While the 17.6% of infections were definitively linked to microbes specific to leeches, the remaining 8.9% of infections are of uncertain origin. These infections could have potentially been caused by other factors unrelated to the use of leech therapy. Therefore, while leech therapy does carry a risk of infection, it is vital to note that not all infections observed in patients who underwent hirudotherapy are attributable to the leeches themselves.

DISCUSSION

This systematic review is the first to investigate the current state of literature regarding the use of hirudotherapy following microsurgical breast reconstruction. While the use of medical leeches has been described thoroughly, there has been little discussion of patient outcomes following their use for resolution of breast flap congestion. The results of this systematic review confirm that limited high-level evidence exists to support their use in this field in comparison to other therapy options. Further, while evidence is too sparse to directly compare outcomes between previous studies, rates of complications following hirudotherapy are noted, especially with regards to infection. Conversely, it is apparent from the reviewed studies that there may be distinct benefits to the use of leeches, such as cost benefits, prevention of invasive revision surgeries and potentially improved rates of flap salvage. However, the main conclusion to be drawn from the current literature is that the overall evidence is very uncertain regarding the benefits and risks of hirudotherapy following microsurgical breast reconstruction likely due to underreporting.

Table 1: Study characteristics

Author	Type of Studies	Patient	Age	Number of Patient	Type of Flaps
Ardehali, 2005	Case report	Patient 1	47	1	Latissimus Dorsi
Bourdais, 2009	Case report	Patient 1	56	1	TRAM
Butt, 2016	Case Series	Patient 1	37	1	SGAP
Camara, 2009	Observational	Patient 1	N/A	1	N/A
Dabb, 1992	Case Series	Patient 1	48	1	Latissimus Dorsi
		Patient 1	28		Free Gluteal Flap
		Patient 2	44		Latissimus Dorsi
		Patient 3	35		TRAM
		Patient 4	52		TRAM
		Patient 5	56		TRAM
de Chalain, 1996	Observational	Patient 6	41	6	TRAM
		Patient 4	52		TRAM
		Patient 5	56		TRAM
		Patient 6	41		TRAM
Flurry, 2011	Case Report	Patient 1	40	1	DIEP
Hwang, 2017	Case Report	Patient 1	45	1	Local Rotational Flap
Kruer, 2015	Observational	8 Patients	N/A	8	DIEP
		2 Patients	N/A	2	TRAM
Maetz, 2012	Case Report	Patient 1	55	2	TRAM
		Patient 2	56		TRAM
Nguyen, 2012	Observational	5 Patients	N/A	5	TRAM/DIEP
		Patient 1	45		TRAM
		Patient 2	64		DIEP
Pannucci, 2014	Observational	Patient 3	58	4	TRAM
		Patient 4	46		SIEA

Table 2: Hirudotherapy Characteristics

Author	Patient	Mean Number of Leeches	Mean Number of days	Antibiotics
Ardehali, 2005	Patient 1	N/A	5	Three doses of intravenous cefotaxime post-operative. Intravenous Augmentin (Co-amoxiclav) cover of 1.2 g tds started on the second day (the day the leech therapy was started) and switched to an oral variant on the third day. On the sixth post-operative day, leech therapy ceased, and the antibiotics stopped.
Bourdais, 2009	Patient 1	N/A	6	IV ciprofloxacin 200 mg 3 times daily, gentamycin 150mg per day and metronidazole 500 mg 3 times daily for 5 days. IV antibiotics switched to oral ciprofloxacin 500 mg 2 daily for 2 weeks
Butt, 2016	Patient 1	N/A	1	Ciprofloxacin for prophylaxis
Camara, 2009	Patient 1	N/A	N/A	N/A
Dabb, 1992	Patient 1	40	10	Oral Antibiotic started 1 week after discharge
	Patient 1	N/A	1,5	Cefazolin Prophylaxis
	Patient 2	N/A	3	Clindamycin + Ciprofloxacin Prophylaxis
de Chalain, 1996	Patient 3	N/A	2	Ceftriaxone Prophylaxis
	Patient 4	N/A	1	Cefazolin + Erythromycin Prophylaxis
	Patient 5	N/A	4	Cefazolin Prophylaxis
	Patient 6	N/A	3	Ciprofloxacin Prophylaxis
Flurry, 2011	Patient 1	N/A	N/A	Antibiotics Prophylaxis
Hwang, 2017	Patient 1	20	N/A	Amikacin prophylaxis, Vancomycin and piperacillin/tazobactam for MRSA
Kruer, 2015	9 Patients	N/A	N/A	Antimicrobial prophylaxis
	Patient 1	N/A	4	Vancomycin (1.5g/day) and cefotaxime (6g/day) for 10 days, and amikacin (350mg/day) for 2 days.
Maetz, 2012	Patient 2	N/A	3	IV prophylaxis amoxicillin/clavulanic acid (4g/day) and gentamicin (160mg/day) for 2 days. Amoxicillin/clavulanic acid stopped at day 10 and was replaced by cefotaxime (6g/day) for 10 days, followed by oral ofloxacin (400mg/day) for eight days.
Nguyen, 2012	5 Patients	N/A	N/A	Fluoroquinolone alone, a fluoroquinolone with a sulfonamide, penicillin, aminoglycoside, or alternative antibiotic regimen as prophylaxis. Many patients receiving combination antibiotic regimens were also being treated for infectious processes unrelated to the leech therapy. No patients had documented infection with <i>Aeromonas hydrophila</i>
Pannucci, 2014	Patient 1	15	3	Antibiotic therapy to specifically cover <i>Aeromonas</i> (most commonly levaquin) was prescribed
	Patient 2	41	6	
	Patient 3	9	3	
	Patient 4	11	4	

Table 3: Flap complications and outcomes

Author	Sepsis	Infection	Flap	Flap take back/reoperation	Patient	Infection	Shock	Culture	Necrosis	Expander / Explant	Outcome of flaps
Ardehali, 2005	Patient 1	1	0	Aeromonas hydrophilia	0		0		1	Yes	Good
Bourdais, 2009	Patient 1	1	1	Aeromonas hydrophilia	0		2		1	No	Good
Butt, 2016	Patient 1	N/A	N/A	N/A	1		2 (Failed S-GAP free flap was debrided, chest skin mobilized, defect closed and later breast implant planned.)		1	N/A	Flap Loss
Camara, 2009	Patient 1	N/A	N/A	N/A	0		N/A		N/A	N/A	Good
Dabb, 1992	Patient 1	1	N/A	Aeromonas hydrophilia	0		Return to OR for debridement of necrotic portion		1	Yes	Good
	Patient 1	0	N/A	N/A	0		Anastomosis revised		1	N/A	Poor (60% flap loss)
	Patient 2	1	N/A	Aeromonas hydrophilia	1		?		1	N/A	Flap Loss
de Chalin, 1996	Patient 3	0	0	N/A	0		0		1	N/A	Good (5% flap loss)
	Patient 4	0	0	N/A	1		Re-Anastomosis		1	N/A	Flap Loss
	Patient 5	0	0	N/A	0		Re-Anastomosis		1	N/A	Good (2% loss)
	Patient 6	0	0	N/A	0		Anastomosis		1	N/A	Moderate (10% loss)
Flurry, 2011	Patient 1	0	0	N/A	0		N/A		N/A	N/A	Good
Hwang, 2017	Patient 1	1	0	MRSA	0		Skin Graft		1	N/A	Good
Kruer, 2015	8 Patients	0	N/A	N/A	N/A		N/A		N/A	N/A	N/A
	1 Patient	1	N/A	N/A	N/A		N/A		N/A	N/A	N/A
	Patient 1	1	1	A. veronii biovar sobria	0		N/A		N/A	N/A	Good
Maetz, 2012				A. veronii biovar sobria							
	Patient 2	1	1	A. veronii biovar sobria	0		N/A		1	N/A	Good
Nguyen, 2012	5 Patients	N/A	N/A	N/A	3		N/A		3	N/A	2 Good, 3 Loss
	Patient 1										Partial Salvage
Pannucci, 2014	Patient 2	0	0	0	3		N/A		4	N/A	Loss
	Patient 3										Loss
	Patient 4										Loss

Free flap reconstruction can be complicated by many factors that may ultimately lead to flap failure. Selber et al. described their experience with 4,965 free flaps, reporting 10.3% required a return to the operating room for vascular complications and an overall flap salvage rate of 58%³⁴. Similarly, Mirzabeigi described 2,260 free flaps with a lower take-back rate of 2.1% and lower overall salvage rate of 49%³⁵. The discrepancy in percent of flaps requiring a return to the operating room is likely attributable to Mirzabeigi et al's decision to exclude surgical take-backs for hematomas and other common complications. A large percent of free flap failures occur due to venous congestion, with Chang et al. reporting that 34.1% of the flaps in their cohort failed because of venous congestion and 22.7% due to both arterial and venous thrombosis³⁶. In cases

where flaps are jeopardized not due to poor arterial supply, infection, tension or systemic hypotension, hirudotherapy is a viable option for treatment of venous congestion²⁶.

In the currently described patient population, the rate of flap loss following medical leech application for attempted flap salvage was 26.5%, and the salvage rate was 73.5%. This is in line with the literature on free flap loss following leech therapy and a higher rate of salvage than most documented rates for all cause flap compromise.^{11, 34, 35} A study by Nguyen et al³², with a cohort of 38 patients treated with leech therapy following local, regional, and free flaps, had a flap loss of 23.7%. Interestingly this study also showed worse outcomes for free flap/regional flap (salvage rate of 33.3%) following leech therapy compared to their local counterpart (salvage rate

90.9%).³² A possible explanation is that free flaps are often supplied either through a single artery or vein.³⁷ Therefore, if poor flow occurs due to vessel thrombosis, kinking, vasospasm, or inadequate perforator size, flap ischemia and/or congestion can ensue^{14,38}. Intriguingly, a study by Mousavian and Al³⁹ showed a flap loss of 16.8% in a 298-patient cohort that received free tissue transfer to the head and neck, trunks, and limbs following hirudotherapy for flap congestion. Moreover, 22.5% of their cohort had unknown outcomes of flap therapy, which could potentially raise the rate of flap loss of their cohort compared to ours.

Nguyen et Al³², demonstrated poorer outcome in free flaps compared to local flaps. The study by Pannucci et Al³³, provides insight into the possible reason for these poorer outcomes. In their study, Pannucci et Al³³, used hirudotherapy in patients that were either not candidates for surgical revision or following revision. Thus, the rate of free flap loss following hirudotherapy included patients in which leeches were used as a last resort. It would therefore not be reasonable to expect hirudotherapy alone to salvage those flaps, especially after an unsuccessful surgical intervention; certainly, the viability of flap perfusion is multifactorial and not only venous in origin.

Furthermore, leeches represent an infectious risk due to their intrinsic reliance on the *Aeromonas hydrophila* bacterium to digest blood²⁶. In the studies included in this review, the infection rate attributable to microbes specific to the leech microbiome was 17.6%. These infections often occurred despite antibiotic prophylaxis, thus clinicians should be aware of the significant risk present. The infection rate for this cohort corresponds to the upper limit reported in the literature¹⁴. A study by Whitaker et Al¹¹, reported a cohort of 277 patients receiving leech therapy and an infection rate of 14.4%. It is essential for clinicians to be aware of the significant rates of complications and infections that are associated with hirudotherapy. Cautious use of this therapy with rigorous selection of patients is necessary to prevent unnecessary harm while other treatments remain available. Patients at high risk for severe complications from infection or with suppressed immune functioning should not be offered this therapy option. Similarly, the prophylactic use of antibiotics that cover microbes common to leeches should also be recommended given the high rates

of infection seen with these bacteria throughout the included studies.

An essential component of medical practice is to consider the cost efficiency of available therapies. The studies included in this review did not contain cost-efficiency evaluations of leech therapy. However, prices for medical leeches range from \$10 to \$30 USD per leech in the USA⁴⁰. The studies of Dabb et Al²⁶, Hwang et Al²⁹, and Pannucci et Al³³, mentioned the use of 9 to 41 leeches per patient. If the upper margin for the cost of a leech is taken, it would take the cost of hirudotherapy to 270 USD - 1,230 USD per patient. This would be without considering antibiotic or hospital costs. Furthermore, a study by Fischer et Al⁴¹ showed that in 1303 flaps, the cost per patient was \$19,106 in those without surgical complications and \$28,261 in those with surgical complications. This demonstrates the potential cost benefit that leeches could have over surgical intervention if they were to resolve complications without the need for surgery.

Given the greater than \$9,000 difference between complicated cases and uncomplicated cases, there is significant value to preventing extensive complication and reoperation in patients who receive flap reconstruction. For example, an independent organization promoting pricing transparency (TURQUOISE) estimated the average price of hematoma evacuation to cost \$2,934 USD⁴². Other surgeries associated with flap salvage may cost more given increased length of operation, instruments used, and complexity. Therefore, more investigation into the true pricing of hirudotherapy to determine if hospital charging for leech use is similar to the \$270 - \$1230 estimate described above⁴². If so, hirudotherapy may be a cost efficient method of treatment for congested flaps following breast reconstruction.

Limitations

While this is a study to systematically review and compare the outcomes and complications of medical leech therapy in microvascular breast reconstruction, it does have limitations. Given the specific type of outcome investigated and the paucity of experimental designs in this domain, it was not feasible to restrict study designs to only randomized controlled trials or case-control cohorts. The final patient population was thus retrieved largely from

observational studies and case reports, which bring biases inherent to their design (e.g., underreporting or information bias, and publication bias) and frequently incomplete data. Another significant limitation was the lack of consensus on what defines some complications. Flap and skin necrosis were not reported in term of size potentially. Some study could have thus reported small defect as necrosis while other may have chosen to only count large area of necrosis as necrosis. Furthermore, the primary source of heterogeneity rested between cohorts, including patient characteristics, criteria followed to define which patients would receive hirudotherapy, and treatment protocols. Efforts must be made to arrive at a unified protocol for leech therapy, and a set of expert guidelines to indicate their ability to improve the quality of the available evidence. By openly acknowledging these limitations, we wish to emphasize the importance of our findings. This systematic review serves as a clarion call to the surgical and research communities, highlighting the necessity for increased scrutiny and investigation into the use of hirudotherapy in the realm of breast reconstruction microsurgery. Through this systematic review, we have laid the groundwork for future research efforts, mapping out the current landscape of knowledge and pointing out the areas where further investigation is needed. We believe that these insights can guide the development of future studies, potentially leading to more effective and safer use of hirudotherapy in the context of microvascular breast reconstruction complications and ultimately improving patient outcomes.

CONCLUSIONS

In its current form, this systematic review offers a comprehensive exploration of the function of hirudotherapy in managing postoperative congestion in breast microvascular reconstruction. It emphasizes the paucity of high-quality evidence supporting the use of hirudotherapy in this context. Practitioners must be cognizant of the potential complications, particularly infections that may arise with this therapeutic choice for their patients. Given these potential complications, the importance of patient selection cannot be overstated; the judicious selection of patients may contribute significantly to improved outcomes following hirudotherapy. Despite the long-standing use of leech therapy

in treating flap congestion, the scant evidence supporting the effectiveness of hirudotherapy in managing flap complications in autologous breast reconstruction underscores the need for further investigations. Therefore, this review calls for additional studies to delve deeper into this matter. By doing so, it aims to fill the gap in our knowledge and provide a clearer, more robust understanding of the benefits, risks, and potential applications of hirudotherapy in breast reconstruction microsurgery.

ACKNOWLEDGEMENTS

We sincerely thank Victor Joao, affiliated with the Universidad De La Republica Uruguay, for his help as the active Librarian for this project. He helped with creating search strategies and gathering the search results for this manuscripts.

AVAILABILITY OF DATA

All relevant information for this systematic review are either part of the manuscript, figures, tables and digital supplemental content. Any additional information can be found on the PROSPERO protocol for this paper. If any further information is required or unclear, the reader is more than welcome to contact the corresponding author for clarifications.

FINANCIAL SUPPORTS AND SPONSORSHIPS

This manuscript and the authors have not received any financial support of any form.

CONFLICTS OF INTERESTS

All authors declared that there are no conflicts of interest.

ETHICAL APPROVAL AND CONSENT TO PARTICIPATE

Not Applicable.

REFERENCES

1. Pećanac M. DEVELOPMENT OF PLASTIC SURGERY. *Med Pregl* 2015 May-Jun;68(5-6):199-204.

2. Spencer KW. Significance of the breast to the individual and society. *Plast Surg Nurs* 1996 Fall;**16**(3):131-2.
3. Siegel RL, Miller KD, Fuchs HE, Jemal A. Cancer statistics, 2022. *CA Cancer J Clin* 2022 Jan;**72**(1):7-33.
4. Homsey A, Rüegg E, Montandon D, Vlastos G, Modarressi A, Pittet B. Breast Reconstruction: A Century of Controversies and Progress. *Ann Plast Surg* 2018 Apr;**80**(4):457-63.
5. Garza R, 3rd, Ochoa O, Chrysopoulos M. Post-mastectomy Breast Reconstruction with Autologous Tissue: Current Methods and Techniques. *Plast Reconstr Surg Glob Open* 2021 Feb;**9**(2):e3433.
6. Griffiths M, Chae MP, Rozen WM. Indocyanine green-based fluorescent angiography in breast reconstruction. *Gland Surg* 2016 Apr;**5**(2):133-49.
7. Lin SJ, Nguyen MD, Chen C, et al. Tissue oximetry monitoring in microsurgical breast reconstruction decreases flap loss and improves rate of flap salvage. *Plast Reconstr Surg* 2011 Mar;**127**(3):1080-5.
8. Thiessen FEF, Tondu T, Cloostermans B, et al. Dynamic InfraRed Thermography (DIRT) in DIEP-flap breast reconstruction: A review of the literature. *Eur J Obstet Gynecol Reprod Biol* 2019 Nov;**242**:47-55.
9. El-Mrakby HH, Milner RH, McLean NR. Supercharged pedicled TRAM flap in breast reconstruction: is it a worthwhile procedure. *Ann Plast Surg* 2002 Sep;**49**(3):252-7.
10. Sbalchiero JC, de Albuquerque Leal PR, dos Santos CC. Breast reconstruction with a turbocharged transverse rectus abdominis myocutaneous flap on the contralateral perforator. *Ann Plast Surg* 2014 Nov;**73**(5):503-8.
11. Whitaker IS, Oboumarzouk O, Rozen WM, et al. The efficacy of medicinal leeches in plastic and reconstructive surgery: a systematic review of 277 reported clinical cases. *Microsurgery* 2012 Mar;**32**(3):240-50.
12. Munshi Y, Ara I, Rafique H, Ahmad Z. Leeching in the history--a review. *Pak J Biol Sci* 2008 Jul 1;**11**(13):1650-3.
13. Mumcuoglu KY. Recommendations for the use of leeches in reconstructive plastic surgery. *Evid Based Complement Alternat Med* 2014;**2014**:205929.
14. Hackenberger PN, Janis JE. A Comprehensive Review of Medicinal Leeches in Plastic and Reconstructive Surgery. *Plastic and Reconstructive Surgery – Global Open* 2019;**7**(12):e2555.
15. Indications and results of the use of facial fat grafting and fillers on complications of cosmetic facial augmentation. 2021 [cited; Available from: https://www.crd.york.ac.uk/prospero/display_record.php?RecordID=287675
16. Page MJ, McKenzie JE, Bossuyt PM, et al. The PRISMA 2020 statement: an updated guideline for reporting systematic reviews. *BMJ* 2021;**372**:n71.
17. Harrar H, Myers S, Ghanem AM. Art or Science? An Evidence-Based Approach to Human Facial Beauty a Quantitative Analysis Towards an Informed Clinical Aesthetic Practice. *Aesthetic Plast Surg* 2018 Feb;**42**(1):137-46.
18. Babineau J. Product Review: Covidence (Systematic Review Software). *Journal of the Canadian Health Libraries Association / Journal de l'Association des bibliothèques de la santé du Canada* 2014 08/01;**35**(2):68-71.
19. National Heart L, Institute B. Study Quality Assessment Tools [<https://www.nhlbi.nih.gov/health-topics/study-quality-assessment-tools>]. Accessed; 2019.
20. Greco T, Zangrillo A, Biondi-Zoccai G, Landoni G. Meta-analysis: pitfalls and hints. *Heart Lung Vessel* 2013;**5**(4):219-25.
21. Nordmann AJ, Kasenda B, Briel M. Meta-analyses: what they can and cannot do. *Swiss Med Wkly* 2012;**142**:w13518.
22. Ardehali B, Hand K, Nduka C, Holmes A, Wood S. Delayed leech-borne infection with *Aeromonas hydrophila* in escharotic flap wound. *J Plast Reconstr Aesthet Surg* 2006;**59**(1):94-5.
23. Bourdais L, Heusse JL, Aillet S, Schoentgen C, Watier E. [Leech-borne infection on a TRAM flap: a case report]. *Ann Chir Plast Esthet* 2010 Feb;**55**(1):71-3.
24. Butt AM, Ismail A, Lawson-Smith M, Shahid M, Webb J, Chester DL. Leech Therapy For The Treatment Of Venous Congestion In Flaps, Digital Re-Plants And Revascularizations - A Two-Year Review From A Regional Centre. *J Ayub Med Coll Abbottabad* 2016 Apr-Jun;**28**(2):219-23.
25. Camara O, Herrmann J, Egbe A, Koch I, Gajda M, Runnebaum IB. Venous coupler for free-flap anastomosis. *Anticancer Res* 2009 Jul;**29**(7):2827-30.
26. Dabb RW, Malone JM, Leverett LC. The use of medicinal leeches in the salvage of flaps with venous congestion. *Ann Plast Surg* 1992 Sep;**29**(3):250-6.
27. de Chalain TM. Exploring the use of the medicinal leech: a clinical risk-benefit analysis. *J Reconstr Microsurg* 1996 Apr;**12**(3):165-72.
28. Flurry M, Natoli NB, Mesa JM, Moyer KE. Tunneling of a leech into a free flap breast reconstruction. *J Plast Reconstr Aesthet Surg* 2011 Dec;**64**(12):1687-8.
29. Hwang K, Kim HM, Kim YS. Methicillin-Resistant *Staphylococcus Aureus* Following Leech Application at a Congested Flap after a Mastectomy. *Arch Aesthetic Plast Surg* 2017 10;**23**(3):143-5.
30. Kruer RM, Barton CA, Roberti G, Gilbert B, McMillian WD. Antimicrobial prophylaxis during

- Hirudo medicinalis therapy: a multicenter study. *J Reconstr Microsurg* 2015 Mar;**31**(3):205-9.
31. Maetz B, Abbou R, Andreoletti JB, Bruant-Rodier C. Infections following the application of leeches: two case reports and review of the literature. *J Med Case Rep* 2012 Oct 25;**6**:364.
 32. Nguyen MQ, Crosby MA, Skoracki RJ, Hanasono MM. Outcomes of flap salvage with medicinal leech therapy. *Microsurgery* 2012 Jul;**32**(5):351-7.
 33. Pannucci CJ, Nelson JA, Chung CU, et al. Medicinal leeches for surgically uncorrectable venous congestion after free flap breast reconstruction. *Microsurgery* 2014 Oct;**34**(7):522-6.
 34. Selber JC, Angel Soto-Miranda M, Liu J, Robb G. The survival curve: factors impacting the outcome of free flap take-backs. *Plast Reconstr Surg* 2012 Jul;**130**(1):105-13.
 35. Mirzabeigi MN, Wang T, Kovach SJ, Taylor JA, Serletti JM, Wu LC. Free flap take-back following postoperative microvascular compromise: predicting salvage versus failure. *Plast Reconstr Surg* 2012 Sep;**130**(3):579-89.
 36. Chang BL, Mondshine J, Attinger CE, Kleiber GM. Targeted Muscle Reinnervation Improves Pain and Ambulation Outcomes in Highly Comorbid Amputees. *Plastic and Reconstructive Surgery* 2021;**148**(2):376-86.
 37. Lucas JB. The Physiology and Biomechanics of Skin Flaps. *Facial Plast Surg Clin North Am* 2017 Aug;**25**(3):303-11.
 38. Rose J, Puckett Y. Breast Reconstruction Free Flaps. StatPearls. Treasure Island (FL): StatPearls Publishing Copyright © 2022, StatPearls Publishing LLC.; 2022.
 39. Mousavian A, Sabzevari S, Parsazad S, Moosavian H. Leech Therapy Protects Free Flaps against Venous Congestion, Thrombus Formation, and Ischemia/Reperfusion Injury: Benefits, Complications, and Contradictions. *Arch Bone Jt Surg* 2022 Mar;**10**(3):252-60.
 40. Orgill DP. Medicinal Leech Therapy. *Plastic and Reconstructive Surgery* 2007;**120**(3).
 41. Fischer JP, Sieber B, Nelson JA, et al. Comprehensive Outcome and Cost Analysis of Free Tissue Transfer for Breast Reconstruction: An Experience with 1303 Flaps. *Plastic and Reconstructive Surgery* 2013;**131**(2):195-203.
 42. Jiang JX, Polsky D, Littlejohn J, Wang Y, Zare H, Bai G. Factors Associated with Compliance to the Hospital Price Transparency Final Rule: a National Landscape Study. *J Gen Intern Med* 2022 Nov;**37**(14):3577-84.