



OPEN

# Treatment of Paraquat-Induced Lung Injury With an Anti-C5a Antibody: Potential Clinical Application\*

Shihui Sun, PhD<sup>1</sup>; Yuting Jiang, MSc<sup>1</sup>; Renxi Wang, PhD<sup>2</sup>; Chenfeng Liu, MSc<sup>1</sup>; Xiaoling Liu, MD, PhD<sup>2,3</sup>; Nianping Song, MSc<sup>1</sup>; Yan Guo, MSc<sup>1</sup>; Renfeng Guo, MD<sup>4</sup>; Lanying Du, PhD<sup>5</sup>; Shibo Jiang, PhD<sup>5</sup>; Yan Li, PhD<sup>2</sup>; Zewu Qiu, MD, PhD<sup>3</sup>; Guangyu Zhao, PhD<sup>1</sup>; Yusen Zhou, PhD<sup>1</sup>

**Objectives:** Complement activation product C5a plays a critical role in systemic inflammatory response syndrome induced by viruses, bacteria, and toxic agents including paraquat poisoning. This study is to explore the efficiency of anti-C5a–based intervention on systemic inflammatory responses induced by paraquat poisoning.

**Design:** Study of cynomolgus macaque model and plasma from paraquat-poisoning patients.

**Setting:** Laboratory investigation.

\*See also p. 834.

<sup>1</sup>State Key Laboratory of Pathogen and Biosecurity, Beijing Institute of Microbiology and Epidemiology, Beijing, China.

<sup>2</sup>Laboratory of Immunology, Beijing Institute of Basic Medical Sciences, Beijing, China.

<sup>3</sup>The 307th Hospital of Chinese People's Liberation Army, Beijing, China.

<sup>4</sup>InflaRx GmbH, Jena, Germany.

<sup>5</sup>Laboratory of Viral Immunology, Lindsley F. Kimball Research Institute, New York Blood Center, New York, NY.

Drs. Sun, Jiang, and Wang contributed equally to this work. Drs. Qiu, Zhao, and Zhou had full access to all of the data reported in this study and had final responsibility for the decision to submit this report for publication. Drs. Sun, Wang, Li, Zhao, and Zhou designed research study; Drs. Sun, Jiang, Wang, C. Liu, X. Liu, Song, and Guo performed research; Drs. Sun, Jiang, Wang, Li, and Zhao analyzed data; Drs. Sun, Zhao, and Zhou wrote the article; and Drs. Wang, Guo, Du, Jiang, and Li for revising the article.

Supplemental digital content is available for this article. Direct URL citations appear in the printed text and are provided in the HTML and PDF versions of this article on the journal's website (<http://journals.lww.com/ccmjjournal>).

Supported, in part, by grants from the National Nature Science Foundation of China (81571983 and 81371805), the Program of National Ministry of Science and Technology (2014ZX09J14105-04B) and funding of State Key Laboratory of Pathogen and Biosecurity (SKLPBS1509).

Dr. R. Guo disclosed that he is a cofounder for InflaRx, who provides IFX-1 used in this study. The remaining authors have disclosed that they do not have any potential conflicts of interest.

For information regarding this article, E-mail: [qjuzw828@163.com](mailto:qjuzw828@163.com); [guangyu0525@163.com](mailto:guangyu0525@163.com); [yszhou@bmi.ac.cn](mailto:yszhou@bmi.ac.cn)

Copyright © 2018 The Author(s). Published by Wolters Kluwer Health, Inc. on behalf of the Society of Critical Care Medicine and Wolters Kluwer Health, Inc. This is an open-access article distributed under the terms of the Creative Commons Attribution-Non Commercial-No Derivatives License 4.0 (CCBY-NC-ND), where it is permissible to download and share the work provided it is properly cited. The work cannot be changed in any way or used commercially without permission from the journal.

DOI: 10.1097/CCM.0000000000002950

**Subjects:** Cynomolgus macaque ( $n = 12$ ) and samples of plasma from patients ( $n = 16$ ).

**Interventions:** The neutralizing antihuman C5a antibody (IFX-1) was administered to investigate the new treatment strategy for paraquat-induced systemic inflammatory responses in cynomolgus macaque model. In addition, C5a activation in plasma of paraquat patients was blocked by IFX-1 to investigate the blockade role of anti-C5a antibody in activation of inflammatory cells.

**Measurements and Main Results:** Dysregulated complement activation and the subsequent cytokine storm were found in patients with acute lung injury and in a primate model of paraquat poisoning. Targeted inhibition of C5a by IFX-1 led to marked alleviation of systemic inflammatory responses and multiple organ damage in the primate model. In addition, blockade of C5a activity in plasma from patients completely inhibited activation of CD11b on blood granulocytes from normal donors, suggesting that IFX-1 may alleviate the excessive activation of inflammatory responses and have clinical utility for patients with acute lung injury.

**Conclusions:** Anti-C5a antibodies such as IFX-1 may be used as effective therapeutics for treatment of those suffering from systemic inflammatory responses induced by chemical poisoning like paraquat. (*Crit Care Med* 2018; 46:e419–e425)

**Key Words:** acute lung injury; complement; cynomolgus macaque; paraquat; treatment

The complement system is a pivotal component of innate immune system and bridge of the innate and adaptive immune responses. However, once dysregulated, it can turn against host cells and is involved in numerous diseases and pathologic conditions such as inflammatory diseases, autoimmune diseases, neurodegenerative diseases, and infectious diseases (1). Complement activation products such as C5a play an important role in mediating proinflammatory activity and regulating modulatory signals (2–4). Thus, regulation of complement activation is a promising treatment strategy (5, 6). Regulating C5a or C5aR has proven beneficial in animal models of transplantation, sepsis, arthritis, and cancer (7–9).

Our previous studies showed that aberrant complement activation plays an important role in H5N1-induced acute lung injury (ALI) in a mouse model (10) and that targeted blockade of C5a alleviates H7N9-induced ALI in an African Green Monkey model (11). We also demonstrated aberrant complement activation after paraquat poisoning in a mouse model, suggesting that it plays a major role in paraquat-induced ALI (12). ALI is characterized by severe lung damage accompanied by a protein-rich pulmonary edema (13). Lung injury is caused primarily by damage to endothelial and epithelial barriers and is closely associated with activation and infiltration by neutrophils (14). Clinically, the main cause of ALI is bacterial or viral pneumonia, along with sepsis, transfusions, drug reactions, or chemical reagents (15). Although lung-protective ventilator strategies have reduced mortality, no effective pharmacologic therapy is available (16, 17). Thus, an effective means of preventing, alleviating, or retarding systemic inflammatory responses is required.

Chemical poisoning is a major cause of morbidity and mortality worldwide. More than 2 million cases of chemical poisoning including paraquat are reported annually in China, resulting in over 150,000 deaths (18–21). Death in paraquat poisoning is either due to significant ALI or multiple organ failure (22). Oxygen-free radicals was reported to play a role in lung injury caused by paraquat poisoning (23). Interaction of C5a with C5aR could activate neutrophils and monocytes to generate oxidative burst with release of reactive oxygen species (ROS) (24, 25), whereas interception of C5a-C5aR signaling significantly inhibited oxidative burst in neutrophils induced with *Escherichia coli*. and in whole blood induced with *Neisseria meningitidis* (26, 27). Therefore, it is possible that blockade of C5a could effectively alleviate ALI induced by paraquat poisoning through the reduction of ROS release.

IFX-1 (NCT01319903; developed by InflaRx GmbH, Jena, Germany), a highly potent neutralizing antihuman C5a monoclonal antibody that leaves the formation of the membrane attack complex (MAC), is in various phase II clinical trials ([www.inflarx.de](http://www.inflarx.de)). In this study, we tested whether IFX-1 is an effective way to alleviate ALI by blocking systemic inflammatory responses in a monkey model of paraquat poisoning. The results showed that IFX-1 alleviated ALI and reduced levels of systemic inflammation. Importantly, *in vitro* data indicated that IFX-1 effectively blocks granulocytes activation by plasma from paraquat patients. Thus, targeting C5a might be a promising strategy for adjunctive treatment of ALI induced by toxic agents, such as paraquat.

## METHODS

### Patients

Patients were prospectively recruited from the 307th Hospital of Chinese People's Liberation Army, Beijing, China. CT scans of the lung were performed after admission. Serum and plasma samples from patients ( $n = 16$ ) were collected

prospectively within 2 hours after admission and stored at  $-70^{\circ}\text{C}$  until required. Samples from healthy control donors ( $n = 20$ ) were recruited using the same protocols. Written informed consent was obtained from all subjects, and the ethics committee approved this consent procedure. The study conformed to protocols approved by the Beijing Institute of Microbiology and Epidemiology and the local Ethics Committee.

### Cynomolgus Macaque Model

All animal experiments were approved by the Institutional Animal Care and Use Committee (IACUC) of the Beijing Institute of Microbiology and Epidemiology (IACUC Permit No. 2015-12). Cynomolgus monkeys were assigned to treatment and sham treatment groups. Both received an intraperitoneal injection of paraquat diluted in 5 mL of saline (40 mg/kg). One hour later, the sham treatment group ( $n = 5$ ) received an IV injection of phosphate buffered saline (PBS), whereas the treatment group ( $n = 5$ ) received IFX-1 (5 mg/kg in PBS). Another group of cynomolgus monkeys ( $n = 2$ ) received an intraperitoneal injection of saline (5 mL; normal group). Whole blood was collected at 0, 6, and 16 hours after paraquat administration, and serum and plasma samples were obtained and stored at  $-80^{\circ}\text{C}$ . All monkeys were anesthetized with pentobarbital sodium at 16 hours, and necropsies were performed. Lung and other tissues were collected for pathologic and immunologic assay.

### Assays

The blocking efficiency of IFX-1 was tested in a CD11b assay (11). Damage to the lung tissues was evaluated as previously described (28). The concentrations of C5a, C3a, and C5b-9 in plasma were measured using human enzyme-linked immunosorbent assay (ELISA) kits (BD Biosciences, San Jose, CA). Measurements of inflammatory cytokines in serum were performed using ELISA kits (U-CyTech Biosciences, Utrecht, The Netherlands; Uscn Life Sciences, Houston, TX; or eBioscience, Austria, respectively). The analysis of C3c deposition and expression of C3a receptor (C3aR), C5a receptor (C5aR), CD68, myeloperoxidase, surfactant protein A (SP-A), and vascular endothelial-cadherin were detected by immunohistochemistry staining. The relative expression of VE-cadherin was analyzed using the  $2^{-\Delta\Delta\text{CT}}$  method (29). For detailed information, see **Supplemental Material** (Supplemental Digital Content 1, <http://links.lww.com/CCM/D159>).

### Statistical Analysis

Data from semiquantitative histopathologic analyses and semiquantitative analysis of macrophage and neutrophil counts were analyzed using Student *t* test with Welch's correction. Differences in inflammatory cytokine and chemokine concentrations between the groups at the indicated time points were compared using two-way analysis of variance with Bonferroni's posttest. *p* values less than 0.05 were considered significant. Data are expressed as the mean  $\pm$  SEM. All analyses were performed using GraphPad Prism, version 5.0 (GraphPad Software, San Diego, CA).

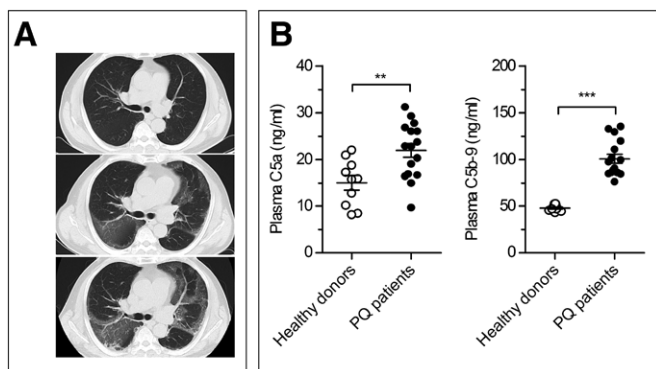
## RESULTS

### Aberrant Complement Activation and Systemic Inflammatory Responses in Patients With Paraquat Poisoning

Patients with paraquat ingestion from 20 to 60 years old. Some patients were sent to hospital 2 or 3 hours after poisoning, while some others were sent after a longer period of time. Nevertheless, the patients had similar clinical presentations and similar abnormal laboratory readings. Patients showed evidence of ALI, which included advanced changes to the air spaces in the lung lobes on chest CT (**Fig. 1A**). Elevated levels of inflammatory cytokines (**Supplemental Fig. 1**, Supplemental Digital Content 2, <http://links.lww.com/CCM/D160>; legend, Supplemental Digital Content 1, <http://links.lww.com/CCM/D159>) and abnormal laboratory readings (i.e., elevated alanine aminotransferase [ALT], aspartate aminotransferase [AST], creatinine [CRE], and blood urea nitrogen [BUN] levels) (**Supplemental Table 1**, Supplemental Digital Content 3, <http://links.lww.com/CCM/D161>) suggested systemic inflammatory responses and multiple -organ damage. The concentrations of C5a ( $p < 0.01$ ) and C5b-9 ( $p < 0.001$ ) in paraquat patients were significantly higher than those in healthy donors (**Fig. 1B**). Clinical data indicated that paraquat ingestion contributes to acute inflammatory responses, which is closely associated with aberrant complement activation.

### Aberrant Complement Activation and Systemic Inflammatory Responses in Cynomolgus Macaques Treated With Paraquat

Previously, we used a nonhuman primate model to show that C5a is an effective target for treatment of ALI induced by viral infection (11). However, little is known about the role of aberrant complement activation in paraquat-induced ALI. Here, we established a cynomolgus macaque model of paraquat-induced ALI to better understand the role of complement and to identify therapeutic targets. After paraquat administration, the monkeys showed typical ALI characteristics, including scattered hyperemia, thickened alveolar septa, and infiltration of inflammatory cells accompanied by cellular degeneration and/or necrosis



**Figure 1.** CT images and aberrant complement activation in patients with paraquat (PO) poisoning. **A**, CT images from one patient taken at different times post admission. **B**, Quantitative enzyme-linked immunosorbent assays were used to measure the concentrations of C5a and C5b-9 in plasma from patients ( $n = 10-16$ ). Data are expressed as the mean  $\pm$  SEM. \*\* $p < 0.01$ , and \*\*\* $p < 0.001$  (Student  $t$  test).

(**Supplemental Fig. 2A**, Supplemental Digital Content 4, <http://links.lww.com/CCM/D162>; legend, Supplemental Digital Content 1, <http://links.lww.com/CCM/D159>). At 6 hours, after paraquat administration, the serum concentrations of interleukin (IL)-1 $\beta$ , IL-6, tumor necrosis factor (TNF)- $\alpha$ , IP-10, and MCP-1 were marked higher than those in control animals (**Supplemental Fig. 2B**, Supplemental Digital Content 4, <http://links.lww.com/CCM/D162>; legend, Supplemental Digital Content 1, <http://links.lww.com/CCM/D159>). The concentration of C3a, C5a, and C5b-9, indicators of complement activation, was also significantly higher in paraquat-treated animals at the same time point (**Supplemental Fig. 3A**, Supplemental Digital Content 5, <http://links.lww.com/CCM/D163>; legend, Supplemental Digital Content 1, <http://links.lww.com/CCM/D159>). Paraquat up-regulated expression of C3aR and C5aR in lung tissues relative to that in normal lung tissues. Deposition of C3c was greater in lung tissues from paraquat-treated animals than in those from untreated animals (**Supplemental Fig. 3B**, Supplemental Digital Content 5, <http://links.lww.com/CCM/D163>; legend, Supplemental Digital Content 1, <http://links.lww.com/CCM/D159>). Taken together, these data further support aberrant activation of the complement system. One may argue that the route of administration of paraquat to macaques is different from that to the patients with paraquat poisoning as mentioned above. Because of the difficulty to control the amount of paraquat applied orally due to the severe vomit, we had to administer paraquat intraperitoneally according to the dynamic distribution and absorption of paraquat (30, 31) and obtained reproducible results which consistent with those from testing the blood samples of the patients with paraquat poisoning.

### IFX-1 Improves Paraquat-Induced Clinical Signs in Cynomolgus Macaques

Complement activation products C5a play an important role in proinflammatory responses. To determine whether IFX-1 could alleviate the clinical signs of paraquat poisoning, we compared hemograms, C-reactive protein (CRP), ALT, BUN, CRE concentrations, and the prothrombin time (PT) in IFX-1-treated (or not) cynomolgus macaques at 16 hours post paraquat administration. We found that the number of lymphocytes and eosinophils decreased significantly after paraquat administration, whereas the number of neutrophils and monocytes increased. Surprisingly, in contrast to the sham treatment group, the IFX-1 treatment group had fewer neutrophils ( $p < 0.001$ ) and monocytes ( $p < 0.05$ ) at 16 hours post paraquat administration. Compared with the sham treatment group, the IFX-1-treated group showed a sharp decrease in CRP, CRE, BUN, ALT, and AST levels, suggesting that IFX-1 reduced acute systemic inflammatory responses induced by paraquat. In addition, IFX-1 shortened the PT ( $p < 0.05$ ), indicating that the antibody also inhibited the coagulation cascade (**Supplemental Fig. 4**, Supplemental Digital Content 6, <http://links.lww.com/CCM/D164>; legend, Supplemental Digital Content 1, <http://links.lww.com/CCM/D159>). Coagulation abnormality has been suggested as one of the prognostic factors for ALI/acute respiratory distress syndrome (32, 33).



## Anti-C5a Treatment Reduces Inflammatory Responses in Cynomolgus Macaques Treated With Paraquat

To determine the effect of anti-C5a treatment on the local and systemic inflammatory responses initiated by paraquat, we measured inflammatory cytokines and chemokines in serum samples. Paraquat administration led to a significant increase in the serum concentration of all cytokines/chemokines tested. However, IFX-1 led to a significant reduction in serum IL-1 $\beta$ , IL-6, TNF- $\alpha$ , and MCP-1 (Fig. 2). IFX-1 also caused a significant reduction in plasma concentrations of C5a ( $p < 0.001$ ), but not C3a or C5b-9 (Supplemental Fig. 5A, Supplemental Digital Content 7, <http://links.lww.com/CCM/D165>; legend, Supplemental Digital Content 1, <http://links.lww.com/CCM/D159>). These data suggest that IFX-1 is highly specific for C5a.

Local infiltration by inflammatory cells plays an important role in tissue damage. Therefore, to determine the effects of IFX-1 on infiltration of lung tissue by neutrophils and macrophages, we stained tissue sections for myeloperoxidase and CD68. The results showed that paraquat administration led to a marked increase in the number of myeloperoxidase- and CD68-positive cells in the lung at 16 hours (Fig. 3, A and B; and Supplemental Fig. 5B, Supplemental Digital Content 7, <http://links.lww.com/CCM/D165>; legend, Supplemental Digital Content 1, <http://links.lww.com/CCM/D159>); these numbers were significantly lower in IFX-1-treated lungs. Thus, anti-C5a treatment might be a promising strategy for reducing both systemic and local inflammatory responses in ALI.

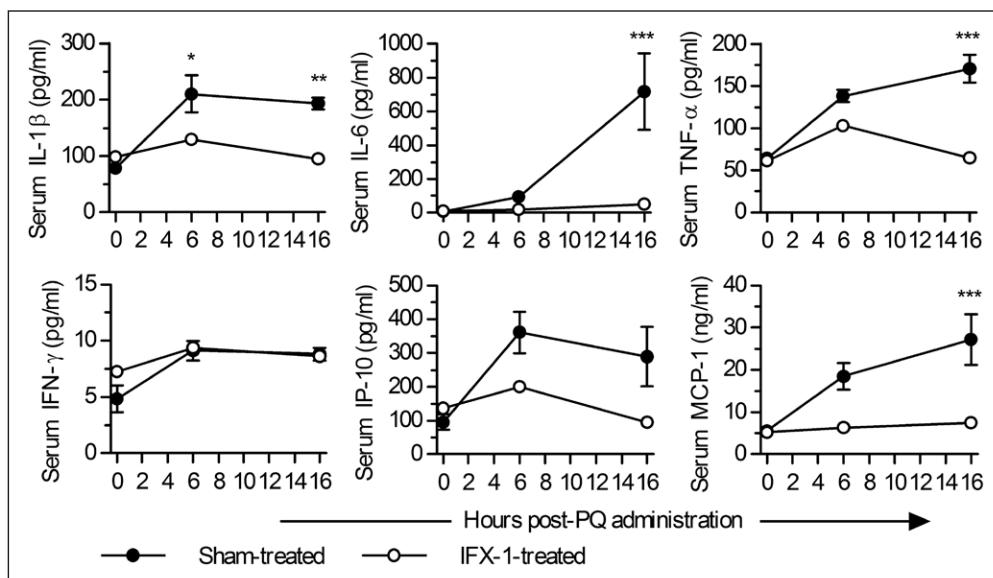
## Anti-C5a Treatment Ameliorates Paraquat-Induced Tissue Injury in Cynomolgus Macaques

Gross necropsy at 16 hours post paraquat administration revealed that the lungs of cynomolgus macaques in the sham

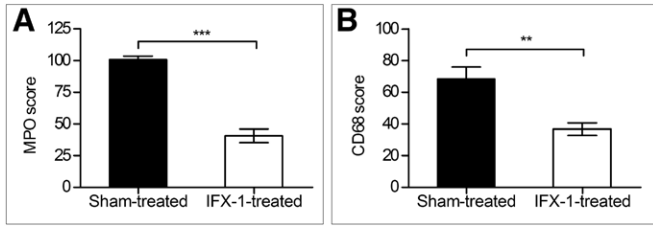
treatment group were cardinal red, whereas the lungs of cynomolgus macaques receiving IFX-1 were a lighter shade (Fig. 4A). Microscopic observation of lungs from sham-treated cynomolgus macaques at 16 hours post paraquat administration showed hemorrhagic alveolar damage characterized by scattered hyperemia, thickened alveolar septa, and infiltration by moderate numbers of neutrophils and macrophages, and degeneration or necrosis of the alveolar epithelium, with vacuolization of pneumocytes or with karyorrhexis and loss of cellular detail. Less exudation and some foamy alveolar macrophages and scattered neutrophils and erythrocytes were also observed in the alveolar lumen. However, the lungs of IFX-1-treated animals showed less severe damage, with some thickening of alveolar septa (Fig. 4B; and Supplemental Fig. 6, Supplemental Digital Content 8, <http://links.lww.com/CCM/D166>; legend, Supplemental Digital Content 1, <http://links.lww.com/CCM/D159>).

SP-A is a pulmonary surfactant primarily responsible for reducing surface tension at the air-liquid interface in the alveoli and plays an important role in the innate host defense and regulation of the inflammatory process in the lung (34). To further study the effect of IFX-1 on injury to the lung parenchyma, we examined expression of SP-A by immunohistochemistry. IFX-1 treatment increased expression of SP-A, suggesting that it may help protect alveolar epithelial cells (Fig. 4B). In addition, the expression and transcription level of VE-cadherin, a molecule important for maintaining endothelial barrier integrity in lung microvessels (35), increased significantly at 16 hours post IFX-1 treatment ( $p < 0.01$ ), further confirming that anti-C5a treatment protects lung integrity and function during paraquat-induced ALI (Supplemental Fig. 6, A and C, Supplemental Digital Content 8, <http://links.lww.com/CCM/D166>; legend, Supplemental Digital Content 1, <http://links.lww.com/CCM/D159>).

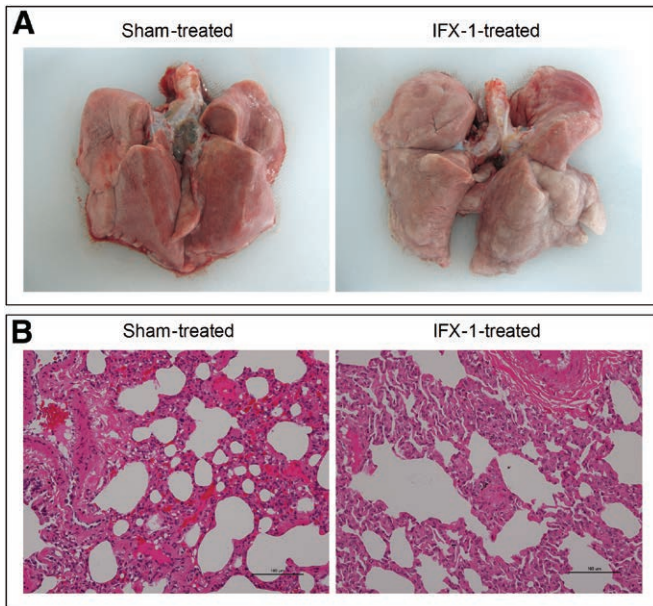
In addition, anti-C5a treatment also effectively ameliorated damage to organs including the spleen (Supplemental Fig. 7, Supplemental Digital Content 9, <http://links.lww.com/CCM/D167>; legend, Supplemental Digital Content 1, <http://links.lww.com/CCM/D159>), kidney, and intestine (Supplemental Fig. 8, Supplemental Digital Content 10, <http://links.lww.com/CCM/D168>; legend, Supplemental Digital Content 1, <http://links.lww.com/CCM/D159>) in paraquat-treated cynomolgus macaques. The results indicated that anti-C5a treatment not only alleviated tissue damage but also



**Figure 2.** IFX-1 reduces systemic inflammatory responses in cynomolgus macaques with paraquat (PQ)-induced acute lung injury. Quantitative enzyme-linked immunosorbent assays were used to measure the concentrations of interleukin (IL)-1 $\beta$ , IL-6, tumor necrosis factor (TNF)- $\alpha$ , interferon (IFN)- $\gamma$ , interferon-gamma-inducible protein (IP)-10, monocyte chemoattractant protein (MCP)-1 in serum from IFX-1-treated and Sham-treated monkeys at 16 hr post PQ administration. Data are expressed as the mean  $\pm$  SEM ( $n = 5$  in each group). \* $p < 0.05$ , \*\* $p < 0.01$ , and \*\*\* $p < 0.001$  (two-way analysis of variance with Bonferroni's posttest).



**Figure 3.** IFX-1 reduces inflammatory responses in lung tissue in cynomolgus macaques with paraquat (PQ)-induced acute lung injury. **A–B.** The semiquantitative analysis of neutrophils (**A**) and macrophages (**B**) infiltration in the lungs of IFX-1-treated and Sham-treated monkeys at 16 hr post PQ administration. Representative images are shown ( $n = 5$  in each group). \*\* $p < 0.01$  and \*\*\* $p < 0.001$  (Student  $t$  test with Welch's correction). MPO = myeloperoxidase.

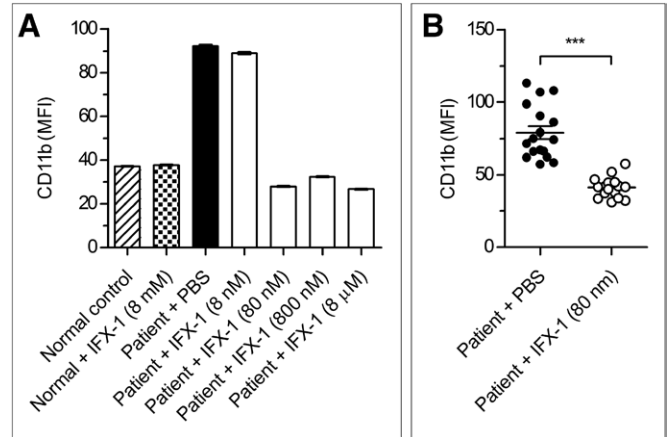


**Figure 4.** IFX-1 treatment ameliorates the pathology associated with paraquat (PQ)-induced acute lung injury in cynomolgus macaques. **A–B.** Gross necropsy (**A**) and hematoxylin and eosin-staining (**B**) of lung tissue obtained 16 hr after PQ administration. The lungs of cynomolgus macaques in the Sham treatment group were cardinal red with hemorrhagic alveolar damage in microscopic observation, whereas those in IFX-1-treated animals were a lighter shade with less severe damage.

mitigated an aberrant immune response induced by paraquat administration.

### IFX-1 Effectively Reduces Granulocyte Activation Induced by Plasma From Paraquat Patients

Normal human blood and plasma from paraquat patients were incubated in the presence/absence of IFX-1, and CD11b expression by granulocytes was analyzed. Paraquat-mediated up-regulation of CD11b expression by granulocytes was completely blocked by IFX-1 at 80 nM (**Fig. 5A**); the efficiency of blockade was consistent and significant when compared with that in the control group ( $p < 0.001$ ) (**Fig. 5B**). The results indicate that complement activation occurred in paraquat-poisoned patients and that complement inhibition by the anti-C5a antibody may be an effective strategy for limiting activation of inflammatory cells, thereby reducing associated tissue damage.



**Figure 5.** IFX-1 treatment inhibits paraquat (PQ)-induced activation of granulocytes in human blood. **A.** IFX-1 blocks C5a activity in patient plasma. The CD11b assay was performed by incubating normal human blood with plasma from PQ patients and a graded concentration of IFX-1. **B.** IFX-1 effectively inhibits up-regulation of CD11b expression. Normal human blood was incubated with plasma from PQ patients, with or without IFX-1, and CD11b expression on granulocytes was examined. Data are expressed as the mean  $\pm$  SEM ( $n = 17$  patients). \*\*\* $p < 0.001$  (one-way analysis of variance with Dunnett's posttest). MFI = mean of fluorescence intensity, PBS = phosphate buffered saline.

## DISCUSSION

ALI is an important cause of acute respiratory failure and is often associated with damage to multiple organs. Resolution of ALI requires repair of epithelial and endothelial barriers and the removal of inflammatory cells and exudate from the distal airspaces, all of which depend on the balance between inflammatory interactions and molecular signals (36, 37). Patients with paraquat poisoning develop ALI symptoms and typically die of multiple organ failure (38). A mouse model of paraquat-induced ALI showed strong activation of the complement system, resulting in tissue damage (12). Here, we observed aberrant complement activation in patients who had ingested paraquat and in a primate model of paraquat-induced ALI. This suggests that targeting complement activation might be a promising therapeutic approach to ALI induced by chemical agents.

The complement system is a key upstream sensor and effector system whose activation products are important regulators of immunologic and inflammatory processes; however, they also participate in many diseases and disorders (1). C5a is a major anaphylatoxin and exerts strong proinflammatory effects by targeting a broad spectrum of immune and nonimmune cells, affecting the migration of macrophages and neutrophils, and inducing synthesis of other chemotactic factors (2, 24). Furthermore, C5a triggers an oxidative burst in macrophages, neutrophils, and eosinophils and increases TNF- $\alpha$  and IL-1 $\beta$  gene expression and protein synthesis by macrophages (39). In a previous study, we showed that IFX-1 reduced serum levels of TNF- $\alpha$ , IL-1 $\beta$ , and IL-6 in African Green Monkeys infected with H7N9 virus (11). Here, we used a monkey model of paraquat-induced ALI to show that IFX-1 reduced the number of inflammatory cell infiltrating in lung, as well as levels of CRP, BUN, ALT and IL-1 $\beta$ , TNF- $\alpha$ , IL-6, thereby reducing injury to the lung, spleen, kidney, and intestine.

Altered permeability of the alveolar endothelial and epithelial barriers remains a central pathophysiological event in ALI. Indeed, the pulmonary endothelium plays a key role in the development of ALI (40, 41). Once activated, endothelial cells secrete cytokines and chemokines such as TNF- $\alpha$ , IL-1 $\beta$ , and MCP-1, which recruit neutrophils and macrophages and contribute to collateral cell damage and organ dysfunction. Zeng et al (42) demonstrated that H5N1-induced damage to pulmonary endothelial cells triggered host inflammatory responses and that C5a may participate in endothelial activation and affect expression of adhesion molecules. We found that IFX-1 increased VE-cadherin expression and alleviated lung lesions, suggesting that decreased activation of endothelial cells and an improved endothelial barrier in the lung contribute to an improved outcome. IFX-1 may also preserve lung function, as evidenced by the increased SP-A level in treated animals. SP-A is closely associated with lung structure and innate immune responses. It is unclear whether alveolar epithelial injury is primary to paraquat insult or secondary to lung endothelial injury. Nonetheless, it is evident that damage to epithelial and endothelial cells converges on a common pathway, resulting in diffuse alveolar damage. As such, reduced endothelial activation and protection of lung epithelial cells may be a potential mechanism underlying C5a blockade.

Evidence indicates that therapeutic modulation of C5a or C5 is a promising treatment for inflammatory disorders (43). Different from other complement blocking agents such as eculizumab, IFX-1 provides effective and specific blockade of C5a without disturbing the C5b assembly arm required for MAC formation (11); this may play an important role in host defense against secondary bacterial and fungal pneumonia that typically occurs in patients who suffer from ALI. Previously, we showed that IFX-1 effectively inhibits eC5a in humans and African Green Monkeys, thereby alleviating lung injury induced by H7N9 virus (11). Here, we found that C5a remained at basal levels after IFX-1 treatment, indicating that C5a can be effectively blocked without affecting the upstream pathways of complement activation.

Plasma obtained from paraquat patients activated blood granulocytes; this was completely abolished by IFX-1. In addition, targeting C5a with IFX-1 led to a marked weakening of the inflammatory responses and alleviated tissue damage, especially in the lung, kidney, and spleen. We also detected the complement activation in patients with ALI suffering from other chemical poisoning, including pesticides and herbicides (data not shown), the results showed that C5a was elevated significantly, indicating the possible role of C5a in lung injury induced by these types of chemical poisonings. These results suggest that blocking complement activation is an effective therapeutic approach to the treatment of ALI induced by toxic agents such as paraquat.

## CONCLUSIONS

We have demonstrated that aberrant complement activation plays an important role in paraquat poisoning-induced ALI.

Paraquat ingestion unleashes a C5a-induced cytokine storm in a primate model and in patients with paraquat-induced ALI. Blockade of C5a using a neutralizing anti-C5a antibody IFX-1 significantly alleviated the systemic inflammatory responses and associated ALI in the paraquat-ingested primate model. Blockade of C5a activity with IFX-1 in plasma from paraquat-poisoned patients completely inhibited activation of CD11b on blood granulocytes from normal donors. Treatment of paraquat-induced ALI with IFX-1 may be potential clinical application and may also have clinical utility for those suffering from ALI induced by other chemical poisoning.

## REFERENCES

1. Markiewski MM, Lambris JD: The role of complement in inflammatory diseases from behind the scenes into the spotlight. *Am J Pathol* 2007; 171:715–727
2. Guo RF, Riedemann NC, Ward PA: Role of C5a-C5aR interaction in sepsis. *Shock* 2004; 21:1–7
3. Hawlisch H, Belkaid Y, Baelder R, et al: C5a negatively regulates toll-like receptor 4-induced immune responses. *Immunity* 2005; 22:415–426
4. Kildsgaard J, Hollmann TJ, Matthews KW, et al: Cutting edge: Targeted disruption of the C3a receptor gene demonstrates a novel protective anti-inflammatory role for C3a in endotoxin-shock. *J Immunol* 2000; 165:5406–5409
5. Ricklin D, Lambris JD: Complement in immune and inflammatory disorders: Pathophysiological mechanisms. *J Immunol* 2013; 190:3831–3838
6. Woodruff TM, Nandakumar KS, Tedesco F: Inhibiting the C5-C5a receptor axis. *Mol Immunol* 2011; 48:1631–1642
7. Köhl J: Drug evaluation: The C5a receptor antagonist PMX-53. *Curr Opin Mol Ther* 2006; 8:529–538
8. Okada H, Imai M, Ono F, et al: Novel complementary peptides to target molecules. *Anticancer Res* 2011; 31:2511–2516
9. Tokodai K, Goto M, Inagaki A, et al: Attenuation of cross-talk between the complement and coagulation cascades by C5a blockade improves early outcomes after intraportal islet transplantation. *Transplantation* 2010; 90:1358–1365
10. Sun S, Zhao G, Liu C, et al: Inhibition of complement activation alleviates acute lung injury induced by highly pathogenic avian influenza H5N1 virus infection. *Am J Respir Cell Mol Biol* 2013; 49:221–230
11. Sun S, Zhao G, Liu C, et al: Treatment with anti-C5a antibody improves the outcome of H7N9 virus infection in African green monkeys. *Clin Infect Dis* 2015; 60:586–595
12. Sun S, Wang H, Zhao G, et al: Complement inhibition alleviates paraquat-induced acute lung injury. *Am J Respir Cell Mol Biol* 2011; 45:834–842
13. Matthay MA, Zimmerman GA: Acute lung injury and the acute respiratory distress syndrome: Four decades of inquiry into pathogenesis and rational management. *Am J Respir Cell Mol Biol* 2005; 33:319–327
14. Mantovani A, Cassatella MA, Costantini C, et al: Neutrophils in the activation and regulation of innate and adaptive immunity. *Nat Rev Immunol* 2011; 11:519–531
15. Ware LB, Matthay MA: The acute respiratory distress syndrome. *N Engl J Med* 2000; 342:1334–1349
16. Cepkova M, Matthay MA: Pharmacotherapy of acute lung injury and the acute respiratory distress syndrome. *J Intensive Care Med* 2006; 21:119–143
17. Wheeler AP, Bernard GR, Thompson BT, et al: Pulmonary-artery versus central venous catheter to guide treatment of acute lung injury. *N Engl J Med* 2006; 354:2213–2224
18. Hao R, Li P, Wang Y, et al: Chemical poisoning-related injury in China. *Lancet* 2013; 382:1327–1328



19. Onyeama HP, Oehme FW: A literature review of paraquat toxicity. *Vet Hum Toxicol* 1984; 26:494–502
20. Sabzghabae AM, Eizadi-Mood N, Montazeri K, et al: Fatality in paraquat poisoning. *Singapore Med J* 2010; 51:496–500
21. Gunnell D, Eddleston M, Phillips MR, et al: The global distribution of fatal pesticide self-poisoning: Systematic review. *BMC Public Health* 2007; 7:357
22. Sittipunt C: Paraquat poisoning. *Respir Care* 2005; 50:383–385
23. Blanco-Ayala T, Andérica-Romero AC, Pedraza-Chaverri J: New insights into antioxidant strategies against paraquat toxicity. *Free Radic Res* 2014; 48:623–640
24. Guo RF, Ward PA: Role of C5a in inflammatory responses. *Annu Rev Immunol* 2005; 23:821–852
25. Sacks T, Moldow CF, Craddock PR, et al: Oxygen radicals mediate endothelial cell damage by complement-stimulated granulocytes. An *in vitro* model of immune vascular damage. *J Clin Invest* 1978; 61:1161–1167
26. Molnes TE, Brekke OL, Fung M, et al: Essential role of the C5a receptor in E coli-induced oxidative burst and phagocytosis revealed by a novel lepirudin-based human whole blood model of inflammation. *Blood* 2002; 100:1869–1877
27. Sprong T, Brandtzaeg P, Fung M, et al: Inhibition of C5a-induced inflammation with preserved C5b-9-mediated bactericidal activity in a human whole blood model of meningococcal sepsis. *Blood* 2003; 102:3702–3710
28. Haagmans BL, Kuiken T, Martina BE, et al: Pegylated interferon-alpha protects type 1 pneumocytes against SARS coronavirus infection in macaques. *Nat Med* 2004; 10:290–293
29. Livak KJ, Schmittgen TD: Analysis of relative gene expression data using real-time quantitative PCR and the 2<sup>-</sup>(Delta Delta C(T)) Method. *Methods* 2001; 25:402–408
30. Pond SM, Rivory LP, Hampson EC, et al: Kinetics of toxic doses of paraquat and the effects of hemoperfusion in the dog. *J Toxicol Clin Toxicol* 1993; 31:229–246
31. Yoon SC: Clinical outcome of paraquat poisoning. *Korean J Intern Med* 2009; 24:93–94
32. Gropper MA, Wiener-Kronish J: The epithelium in acute lung injury/acute respiratory distress syndrome. *Curr Opin Crit Care* 2008; 14:11–15
33. Han YJ, Park JD, Choi JW, et al: Coagulopathy as a prognostic factor of acute lung injury in children. *J Korean Med Sci* 2012; 27:1541–1546
34. Murakami S, Iwaki D, Mitsuzawa H, et al: Surfactant protein A inhibits peptidoglycan-induced tumor necrosis factor-alpha secretion in U937 cells and alveolar macrophages by direct interaction with toll-like receptor 2. *J Biol Chem* 2002; 277:6830–6837
35. Vestweber D, Winderlich M, Cagna G, et al: Cell adhesion dynamics at endothelial junctions: VE-cadherin as a major player. *Trends Cell Biol* 2009; 19:8–15
36. Ware LB, Matthay MA: Alveolar fluid clearance is impaired in the majority of patients with acute lung injury and the acute respiratory distress syndrome. *Am J Respir Crit Care Med* 2001; 163:1376–1383
37. Wiener-Kronish JP, Albertine KH, Matthay MA: Differential responses of the endothelial and epithelial barriers of the lung in sheep to Escherichia coli endotoxin. *J Clin Invest* 1991; 88:864–875
38. Weng CH, Hu CC, Lin JL, et al: Predictors of acute respiratory distress syndrome in patients with paraquat intoxication. *PLoS One* 2013; 8:e82695
39. Schindler R, Gelfand JA, Dinarello CA: Recombinant C5a stimulates transcription rather than translation of interleukin-1 (IL-1) and tumor necrosis factor: Translational signal provided by lipopolysaccharide or IL-1 itself. *Blood* 1990; 76:1631–1638
40. Maniatis NA, Orfanos SE: The endothelium in acute lung injury/acute respiratory distress syndrome. *Curr Opin Crit Care* 2008; 14:22–30
41. Matthay MA, Zemans RL: The acute respiratory distress syndrome: Pathogenesis and treatment. *Annu Rev Pathol* 2011; 6:147–163
42. Zeng H, Pappas C, Belser JA, et al: Human pulmonary microvascular endothelial cells support productive replication of highly pathogenic avian influenza viruses: Possible involvement in the pathogenesis of human H5N1 virus infection. *J Virol* 2012; 86:667–678
43. Albrecht EA, Chinnaiyan AM, Varambally S, et al: C5a-induced gene expression in human umbilical vein endothelial cells. *Am J Pathol* 2004; 164:849–859