



# Is immediate internal fixation safe in induced membrane technique?

İhsan Akan, MD<sup>1</sup>, Tayfun Bacaksız, MD<sup>1</sup>, Naim Özpolat, MD<sup>2</sup>, Mahmut Tunçez, MD<sup>1</sup>, Cemal Kazımoğlu, MD<sup>1</sup>

<sup>1</sup>Department of Orthopedics and Traumatology, İzmir Katip Çelebi University Faculty of Medicine, İzmir, Türkiye

<sup>2</sup>Department of Orthopedics and Traumatology, Balıkgöl State Hospital, Şanlıurfa, Türkiye

Treatment of bone defects still remains challenging, despite the technical and clinical advances, and usually requires complex surgeries and multiple reoperations.<sup>[1-3]</sup> Masquelet et al.<sup>[4]</sup> proposed a two-staged induced membrane technique (IMT) which is based on the autologous cancellous bone grafting within the cement spacer-driven membrane. The IMT has been widely applied for the reconstruction of large bone defects after infection, tumor excision, and fractures.<sup>[4-7]</sup>

Since its first description by Masquelet<sup>[4]</sup> in 2000, the IMT continues to evolve. Recent studies have also demonstrated the favorable application of the procedure in the treatment of acute complex traumatic bone loss, despite the limited experience.<sup>[8,9]</sup> Masquelet<sup>[7]</sup> proposed skeletal stabilization by an external fixator (EF) in his original technique, despite all the known drawbacks of this type of fixation. Modification of

Received: August 21, 2022

Accepted: November 14, 2022

Published online: December 27, 2022

**Correspondence:** İhsan Akan, MD, İzmir Katip Çelebi Üniversitesi Tıp Fakültesi, Ortopedi ve Travmatoloji Anabilim Dalı, 35620 Çiğli İzmir, Türkiye.

E-mail: drihsanakan@gmail.com

Doi: 10.52312/jdrs.2023.829

**Citation:** Akan I, Bacaksız T, Özpolat N, Tunçez M, Kazımoğlu C. Is immediate internal fixation safe in induced membrane technique?. Jt Dis Relat Surg 2023;34(1):151-157. doi: 10.52312/jdrs.2023.829

©2023 All right reserved by the Turkish Joint Diseases Foundation

This is an open access article under the terms of the Creative Commons Attribution-NonCommercial License, which permits use, distribution and reproduction in any medium, provided the original work is properly cited and is not used for commercial purposes (<http://creativecommons.org/licenses/by-nc/4.0/>).

## ABSTRACT

**Objectives:** This study aimed to evaluate the treatment outcomes of patients treated with induced membrane technique (IMT) for the reconstruction of bone defects and to identify factors associated with the success and failure of the modified technique.

**Patients and methods:** Between January 2016 and April 2021, a total of 23 adult patients (20 males, 3 females; median age: 39.9 years; range, 20 to 69 years) who underwent bone reconstruction using the IMT for established pseudoarthrosis and acute bone loss were retrospectively analyzed. Fracture type, the size and location of bone defect, the nature of the index injury, the type of fixation, the interval between stages of the operation, and any diagnosis of infection or other complications of the patients were assessed.

**Results:** The median bone union was achieved in 6.6 (range, 4 to 11) months. The median index of reconstruction was 19 (range, 10 to 30%). The main complications were recurrent infection in two cases and nonunion in one case. Massive graft resorption occurred in two cases.

**Conclusion:** Immediate internal fixation is a reliable and effective method in the treatment of complex bone defects. A large volume of autograft is required for the reconstruction of long defects, which presents as a limiting factor, particularly in patients undergoing previous surgical interventions.

**Keywords:** Bone defects, immediate fixation, induced membrane technique

the original technique with internal fixation (IF) during the second stage after cement removal has been suggested by recent researches.<sup>[9-11]</sup> Moreover, few encouraging clinical results have been reported for immediate IF, despite the drawback of infection control in infected cases and open fractures associated with acute bone loss.

Immediate IF in the first stage allows early fracture stabilization and better limb alignment. Besides, it prevents the potential disadvantages of EF for patient

rehabilitation and comfort between the stages of IMT. In the present study, we aimed to evaluate the treatment outcomes of patients treated with this modified method and to identify factors associated with the success and failure of the modified technique.

## PATIENTS AND METHODS

This single-center, retrospective study was conducted at Izmir Katip Çelebi University Atatürk Training and Research Hospital, Department of Orthopedics and Traumatology between January 2016 and April 2021. In our center, over the past five years, IMT has become the preferred treatment method for critical bone defects due to acute bone loss or established nonunions with immediate IF. Medical records of the patients with long bone defects treated using the IMT were analyzed. Fracture type, the size and location of bone defect, the nature of the index injury, the type of fixation, the interval between stages of the operation, and any diagnosis of infection or other complications of the patients were assessed. Exclusion criteria were as follows: patients under 18 years of age, pathological fractures, and follow-up time less than 12 months after the second stage. Patients over 18 years old with a diagnosis of long bone defect, with a minimum one-year follow-up time, were included. Finally, a total of 23 patients (20 males, 3 females; median age: 39.9 years; range, 20 to 69 years) who met the inclusion criteria were enrolled.

The size of the bone defect was measured with anteroposterior (AP) and lateral X-rays. The bone reconstruction index (BRI) was expressed (bone defect length/total bone length) as previously described by Gouron et al.<sup>[10]</sup>

### Surgical technique

Bone reconstruction was deployed by the modification of the two-stage IMT as described by Masquelet et al.<sup>[6,11]</sup> and Giannoudis et al.<sup>[12]</sup> Radical bone resection to the level of viable bone was carried out initially. Thereafter, immediate IF was performed for skeletal stabilization in all patients instead of an EF described in the original technique. Depending on the location of the fracture skeletal stabilization was achieved with either an intramedullary nail (IMN) or a locking plate. After meticulous debridement and fracture stabilization, the bone defects were filled with a polymethylmethacrylate (PMMA) cement spacer that covers the bone ends. During the first stage, the sinus, dead bone, and necrotic tissue were completely removed and sampled for infected nonunions. Then, the bone defects were filled with antibiotic-loaded PMMA. We preferred using 2 g of vancomycin per 40 g of cement during spacer preparation.

The induced membrane was longitudinally cut open to expose the bone cement in the second stage. The spacer was, then, removed meticulously in order not to disrupt the induced membrane. When possible, the entire defect was filled with an autologous bone graft harvested from the iliac crests. In some cases, additional graft material was needed due to the large size of the bone defect. Morselized cancellous allografts combined with an autologous bone graft was used in these patients. Multiple tissue biopsy specimens were sent for regular culture during both stages of the procedure for infected cases. Flap surgery was performed for associated soft tissue defects during the first stage where necessary. The cement was removed from the contralateral side to the vascular anastomosis for patients who underwent flap surgery during the first stage.

Systemic antibiotic treatment adjusted according to the antibiogram was implemented at the time of wound coverage for infected cases. Postoperative clinical and laboratory confirmation of infection recurrence was carried out regularly at follow-ups. The second stage of the IMT was performed, when routine blood investigations of the patient revealed normal levels of C-reactive protein and erythrocyte sedimentation rate.

Clinical and radiological assessments of patients at follow-ups were reviewed to identify bone defect size, associated infection, spacer time, time to union, the necessity of reconstructive soft tissue procedures, and surgical complications. For cases involving the lower limb, partially assisted weight-bearing in the form of toe-touch walking was initiated after the healing of the soft tissues. Full weight-bearing as tolerated was allowed at 12 weeks of follow-up. The existence of a bridging callus, verticalization in three out of four cortices, and no pain upon weight-bearing were the criteria used for defining bone union.

### Statistical analysis

Statistical analysis was performed using the SPSS version 17.0 software (SPSS Inc., Chicago, IL, USA). Continuous variables were expressed in mean  $\pm$  standard deviation (SD) or median (25<sup>th</sup>-75<sup>th</sup> percentiles).

## RESULTS

Among 23 patients included in the study, 16 had chronic nonunions and/or infections and seven had traumatic segmental bone loss. Clinical and demographic details of the patients are presented in Tables I and II, respectively.

**TABLE I**  
Demographic and clinical details of patients

Variables	n	Median	Min-Max
Age (year)		39.9	20-69
Sex			
Male	20		
Female	3		
Anatomical location			
Tibia			
Femur			
Ulna			
Humerus			
Index fracture			
Closed			
Open			
Length of defects (cm)		5.76	3.1-9.9
BRI (length of defect/length of bone) (%)		19	10-30
Fixation			
IMH	15		
Plate	8		
The duration between Stage I and II (weeks)		6.4	5-10
The duration between Stage II to the final union (months)		6.6	4-11
Number of complications	3		
Re-fracture	0		
Deep infection	2		
Nonunion	3		
Implant failure	0		
Malunion	0		
Length discrepancy ( $\geq 2$ cm)	0		

BRI: Bone reconstruction index; IMN: Intramedullary nail.

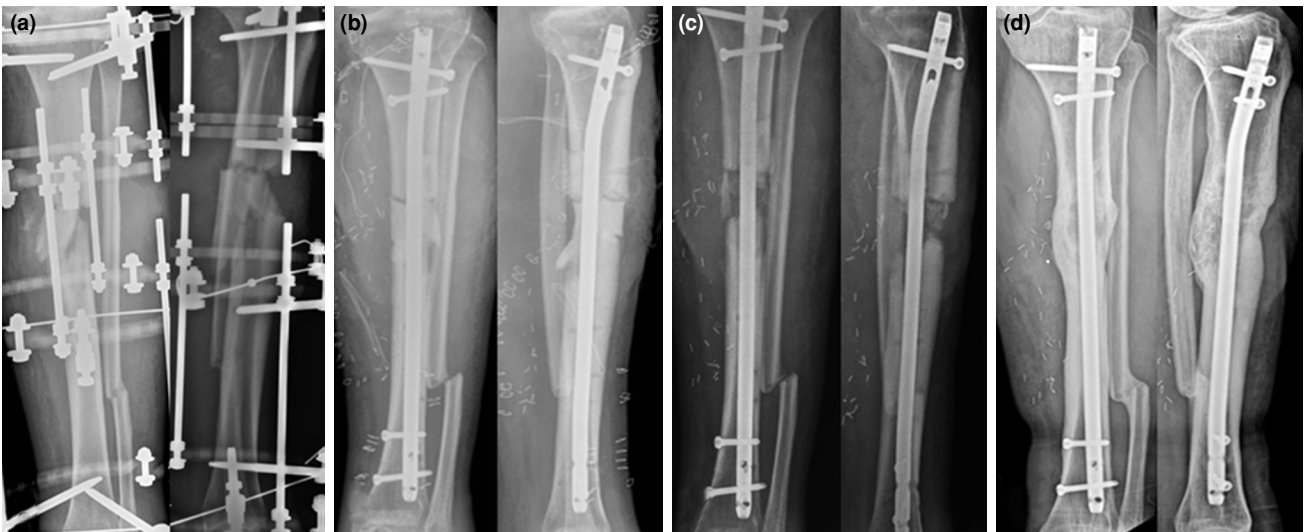
**TABLE II**  
Indications and fixation methods according to defect localization

	Infected NU (Plate/IMN)	Non-infected NU (Plate/IMN)	Acute bone defect (Plate/IMN)	Total
Tibia	10 (-/10)	1 (1/-)	3 (2/1)	14
Femur	-	2 (2/-)	2 (1/1)	4
Ulna	-	2 (1/1)	1 (-/1)	3
Humerus	-	1 (1/-)	1 (-/1)	2
Total	10	6	7	23

NU: Nonunion; IMN: Intramedullary nail.

Medical records revealed 19 open fractures out of 23 cases: type IIIA (n=2), type IIIB (n=16), and type IIIC (n=1). The most commonly treated bone was the tibia, followed by the femur. All tibia fractures, but

two, sustained a Grade 3 open fracture. The median length of the bone defect was 5.76 (range, 3.1 to 9.9) cm which accounted for 19% (range, 10 to 30%) of the total bone length. The median duration between the

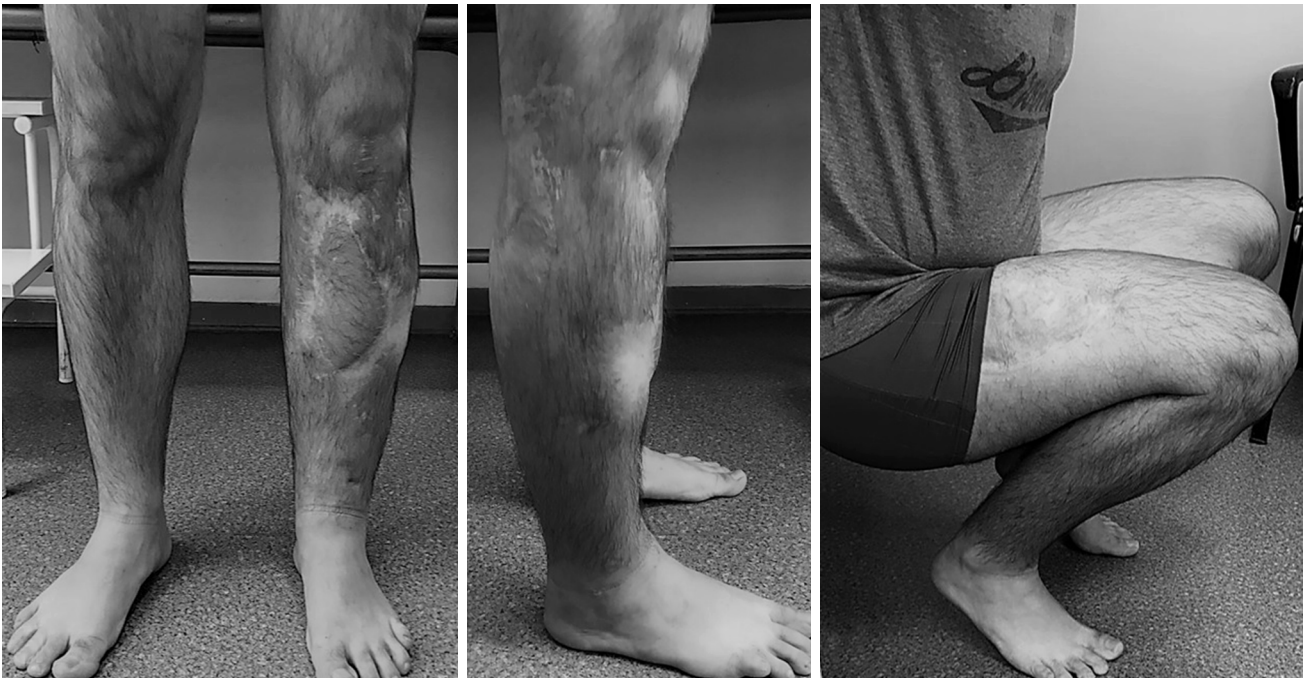

**FIGURE 1.** (a) Preoperative anteroposterior and lateral radiographs before the first-stage procedure in a patient with infected nonunion due to Grade 3B open tibia fracture. (b) Anteroposterior and lateral radiographs after the first stage of IMT. (c) Anteroposterior and lateral radiographs after the bone grafting procedure. (d) Sixty months after the second stage of the induced membrane procedure in the same patient revealing the establishment of both an intramedullary canal and a true cortex. IMT: Induced membrane technique.

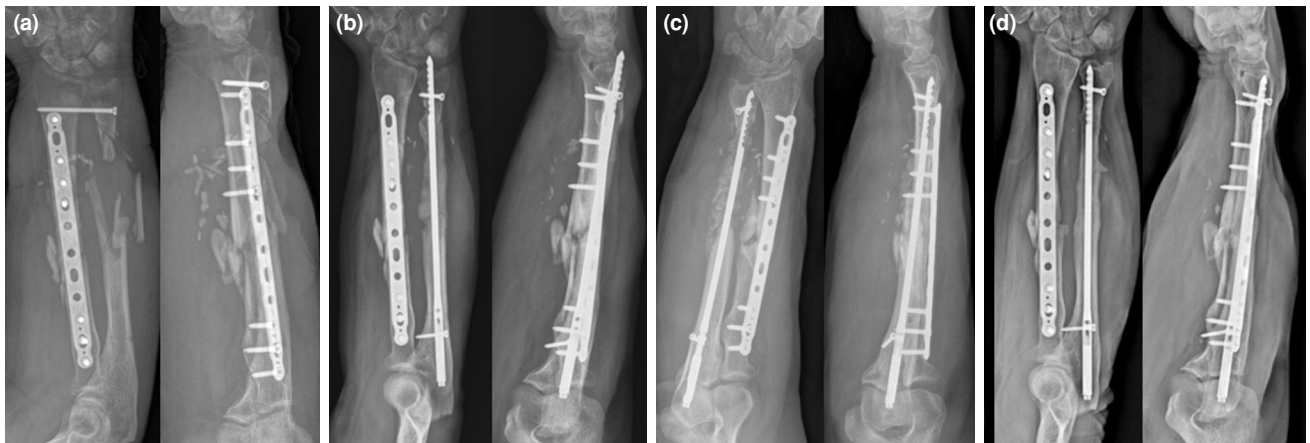stages of the procedure was 6.4 (range, 5 to 10) weeks. Bone consolidation was confirmed at a median of 6.6 (range, 4 to 11) months from the second stage. No significant differences were observed in the time to consolidation between patients who had open fractures and those with closed fractures, nor concerning the affected bone (tibia/femur). In this

series, the longest follow-up period was 60 months (Figures 1 and 2).

Ten patients had associated infection before the application of IMT. Among these, all of them affected the tibia due to open fracture with *Staphylococcus aureus* being the most prevalent



**FIGURE 2.** Good functional outcome after flap surgery and induced membrane technique.



**FIGURE 3.** (a) Preoperative anteroposterior and lateral radiographs before the first-stage procedure in a patient with the acute ulnar bone loss after Grade 3C both arm open fracture. (b) Anteroposterior and lateral radiographs after the first stage of IMT. (c) Anteroposterior and lateral radiographs after the bone grafting procedure. (d) Anteroposterior and lateral radiographs at 33 months after the second stage of the induced membrane procedure on an intramedullary nail in the same patient.

IMT: Induced membrane technique.

germ isolated. There was no need for additional debridement before the second stage due to the subsequent elevation of laboratory values in these series. However, infection recurrence was seen in two patients after the second stage.

Of 23 patients, three patients ended with failure. Overall, eight patients needed flap surgery for soft tissue coverage. Five patients with tibia fractures underwent flap surgery during the first stage and two of them after the IMT. One patient with type IIIC open forearm fracture also required flap surgery (Figure 3).

#### Failures

Absent bony union or recurrence of infection was defined as failure. Overall, we encountered technical failure in three cases. Out of 10, two patients had a failure due to persistent reinfection. Due to the persistent infection, one patient had three reoperations including repeated cementing and bone grafting procedures and ended with nonunion. Eventually, below-knee amputation was performed to control infection. One patient revealed a recurrent infection which was controlled with repeated debridement and cementing. Despite infection eradication, bone (graft) resorption occurred at the defect site at postoperative 18<sup>th</sup> months. This patient underwent a vascularized bone graft operation. One patient with established humerus pseudoarthrosis revealed graft resorption and nonunion at eight months of follow-up. Bone shortening, IMN, and autogenous bone grafting were performed for this patient recently. Overall, the success rate of

immediate IF in achieving bony union was 86.9% in this series.

#### DISCUSSION

In this patient series, out of 23 patients, 20 revealed bony union without complication and further surgery. Two patients with infected tibial nonunion failed to obtain bony union and infection control. One patient with established humerus pseudoarthrosis also ended with failure. The most common site of bone defect was the tibia, covering 60.8% of the present series. This is consistent with the recent meta-analysis of Mathieu et al.<sup>[11]</sup> showing that IMT is deployed for the reconstruction of the tibia in two-thirds of cases.

Fixation of the bone defect properly is critical in the eradication of infection and achieving union in IMT. Bone stabilization is obtained with a temporary EF in the original technique. However, EF can disturb plastic surgery, particularly in the tibia. Infectious complications at the pinholes may compromise the stability of the construct. The proximity of the pinholes to the joint prevents postoperative patient rehabilitation. Furthermore, the application in the upper extremity is challenging due to neurovascular damage risk. The objective of fixation modification over the last decade was to achieve bony union and improve functional results without creating adverse effects on infection control. Recently, Masquelet et al.<sup>[7]</sup> suggested high initial fixation rigidity, followed by more flexible fixation to promote bony union, which is usually not possible with EF. We also believe

that the preservation of the induced membrane and bone grafting can be carried out more safely after immediate IF, as it allows earlier weight-bearing and range of motion exercises and improves patient rehabilitation after the first stage of IMT. Besides, the second stage is considerably simplified and cost-effective, compared to the traditional method. The present study suggests that IMT with immediate IF can serve as a valuable treatment option for the management of complex bone loss with a low revision rate.<sup>[13]</sup>

The concept of applying IMT in acute cases gained popularity in recent years. Seven patients with acute bone loss in the present series healed without any complications. These results are consistent with the findings of Hatashita et al.<sup>[8]</sup> In the setting of open fractures associated with acute bone loss, the cement covers the dead space permitting the injured soft tissue to heal, while simultaneously delivering local antibiotics to prevent infection. Furthermore, limb alignment is restored and axial stability is improved. Overall, IMT with immediate IF presents a reliable and effective modality for the management of acute open fractures with severe bone defects in this cohort.

To the best of our knowledge, the largest single-center case series of 43 patients who were treated with IMT has been reported by Giannoudis et al.<sup>[12]</sup> in the literature. Initial stabilization of the affected extremity in open fractures and infected nonunion cases was achieved with an EF in this study, leaving a small number of patients fixed with immediate IF. The authors preferred immediate IF only in patients with acute bone loss. Aparad et al.<sup>[14]</sup> also published the use of immediate IF for post-traumatic segmental tibia bone loss in a small number of complicated cases.

The IMN allows promptly weight-bearing and has the advantage of accurately aligning the long bones from the mechanical point of view. Acting as a central core, it reduces graft material quantity and prevents central graft resorption.<sup>[13]</sup> Furthermore, Olesen et al.<sup>[15]</sup> described a better outcome with IMN compared to the plating. The authors reported that IMN decreased the amount of bone graft needed and the duration of treatment. In our experience, immediate IF with a plate or preferably with an IMN at the first stage even in infected cases yields favorable results.

Infection control is still the main concern for infected complex nonunions, particularly after multiple failed surgical interventions. Only two, among 10 infected nonunions treated with IMN at

the first stage revealed persistent infection in this series. In the original technique of Masquelet, the addition of antibiotics to PMMA was not proposed due to the risk of masking the signs of infection. However, many researchers have reported successful outcomes after the modification of the technique to improve the control of recurrent infection.<sup>[7,16]</sup> In this study, we preferred the insertion of a cement spacer loaded with antibiotics. Overall, the control of infection seems to be favorable with IMT in the present series. Our results are in agreement with the recent study reporting that antibiotic spacers may prevent repeated surgeries for bone grafting.<sup>[16]</sup>

In patients with osteomyelitis, infection recurrence can be associated with the isolated pathogen. Methicillin-resistant *Staphylococcus aureus* (MRSA), which is associated with higher rates of recurrence, was isolated in one of the failed patients in our study. Infection control should be obtained with clinical and laboratory confirmation before the second stage is performed to prevent relapse.

There is an ongoing debate about the optimal type of graft substitute for the reconstruction of the bone defect at the second stage. Autologous bone grafts provide cells with osteogenic potential, growth factors, and a scaffold covering all the essential components that are necessary for bone reconstruction. Thus, cancellous autologous bone graft remains the gold standard. However, additional graft material is usually required for the reconstruction of large bone defects. The ideal ratio of a bone autograft needs to be determined in order not to compromise union, when an allograft or a synthetic bone material is added. The absolute volume of autologous cancellous bone that can be harvested from iliac crests is limited in our experience. Furthermore, patients with open tibia fractures have usually multiple surgical operations before the application of IMT, which also compromises the iliac bone source.

Masquelet et al.<sup>[7]</sup> recommends at least 70% volume of autografts while using additional graft substitutes. The allograft portion exceeded 30% of graft volume in four cases in this study. Of the three failed cases in this series, two were treated with less than 70% of autogenous bone grafts. In this context, we agree with Hatashita et al.<sup>[8]</sup> that preoperative prediction of the amount of graft necessary is challenging, particularly in elderly patients. The insufficient iliac bone source after multiple previous interventions should be considered before the application of IMT, particularly in bone defects exceeding 6 cm.

Nonetheless, this study has some limitations. It is a single-center, retrospective study. The number of patients who needed complex bone reconstruction in a rational period is limited, even in referral centers. On the other hand, most of the recent researches evaluating the efficacy of IMT with an immediate IF includes only a single case or a small number of case series. This is an exceptionally valuable study, in which the IMT technique was applied with immediate IF in 23 consecutive patients. Induced membrane technique with immediate IF can be considered a valid method in the management of severe, complex, established nonunions and acute bone loss regarding successful outcomes.

In conclusion, our study results suggest that the immediate IF of bone defects is a reliable and effective method in the concept of IMT. However, future research including a large number of patients should be considered to confirm the promising results of immediate IF in IMT.

**Ethics Committee Approval:** The study protocol was approved by the Katip Çelebi University Local Ethics Committee (date: 21.04.2022, no: 214). The study was conducted in accordance with the principles of the Declaration of Helsinki.

**Patient Consent for Publication:** A written informed consent was obtained from each patient.

**Data Sharing Statement:** The data that support the findings of this study are available from the corresponding author upon reasonable request.

**Author Contributions:** Provided input into the concept and design of the study, and provided the materials, analyzed the data, carried out literature review: İ.A., T.B.; Collected and assembled the data: N.P., M.T.; Wrote the article: İ.A., C.K.; All authors have critically revised the article, read and approved the final version at the time of submission.

**Conflict of Interest:** The authors declared no conflicts of interest with respect to the authorship and/or publication of this article.

**Funding:** The authors received no financial support for the research and/or authorship of this article.

## REFERENCES

- Özcan Ö, Yeşil M, Yüzüğüldü U, Kaya F. Bone cement with screw augmentation technique for the management of moderate tibial bone defects in primary knee arthroplasty patients with high body mass index. *Jt Dis Relat Surg* 2021;32:28-34. doi: 10.5606/ehc.2021.76491.
- Kekeç AF, Güngör BŞ. Mid-term outcomes of hemipelvic allograft reconstruction after pelvic bone tumor resections. *Jt Dis Relat Surg* 2022;33:117-31. doi: 10.52312/jdrs.2022.344.
- Okaş B, Çırpar M, Şanlı E, Canbeyli İD, Bozdoğan Ö. The effect of the platelet-rich plasma on osteogenic potential of the periosteum in an animal bone defect model. *Jt Dis Relat Surg* 2021;32:668-75. doi: 10.52312/jdrs.2021.199.
- Masquelet AC, Fitoussi F, Begue T, Muller GP. Reconstruction of the long bones by the induced membrane and spongy autograft. *Ann Chir Plast Esthet* 2000;45:346-53.
- Wang X, Luo F, Huang K, Xie Z. Induced membrane technique for the treatment of bone defects due to post-traumatic osteomyelitis. *Bone Joint Res* 2016;5:101-5. doi: 10.1302/2046-3758.53.2000487.
- Masquelet AC. Induced membrane technique: Pearls and pitfalls. *J Orthop Trauma* 2017;31 Suppl 5:S36-S38. doi: 10.1097/BOT.0000000000000979. PMID: 28938390.
- Masquelet A, Kanakaris NK, Obert L, Stafford P, Giannoudis PV. Bone repair using the Masquelet technique. *J Bone Joint Surg Am* 2019;101:1024-36. doi: 10.2106/JBJS.18.00842.
- Hatashita S, Kawakami R, Ejiri S, Sasaki N, Toshiki N, Ito M, et al. 'Acute Masquelet technique' for reconstructing bone defects of an open lower limb fracture. *Eur J Trauma Emerg Surg* 2021;47:1153-62. doi: 10.1007/s00068-019-01291-2.
- Ronga M, Cherubino M, Corona K, Fagetti A, Bertani B, Valdatta L, et al. Induced membrane technique for the treatment of severe acute tibial bone loss: Preliminary experience at medium-term follow-up. *Int Orthop* 2019;43:209-15. doi: 10.1007/s00264-018-4164-8.
- Gouron R, Deroussen F, Plançq MC, Collet LM. Bone defect reconstruction in children using the induced membrane technique: A series of 14 cases. *Orthop Traumatol Surg Res* 2013;99:837-43. doi: 10.1016/j.otsr.2013.05.005.
- Mathieu L, Bilichtin E, Durand M, de l'Escalopier N, Murison JC, Collombet JM, et al. Masquelet technique for open tibia fractures in a military setting. *Eur J Trauma Emerg Surg* 2020;46:1099-105. doi: 10.1007/s00068-019-01217-y.
- Giannoudis PV, Harwood PJ, Tosounidis T, Kanakaris NK. Restoration of long bone defects treated with the induced membrane technique: Protocol and outcomes. *Injury* 2016;47 Suppl 6:S53-S61. doi: 10.1016/S0020-1383(16)30840-3.
- Morwood MP, Streufert BD, Bauer A, Olinger C, Tobey D, Beebe M, et al. Intramedullary nails yield superior results compared with plate fixation when using the Masquelet technique in the femur and tibia. *J Orthop Trauma* 2019;33:547-52. doi: 10.1097/BOT.0000000000001579.
- Apard T, Bigorre N, Cronier P, Duteille F, Bizot P, Massin P. Two-stage reconstruction of post-traumatic segmental tibia bone loss with nailing. *Orthop Traumatol Surg Res* 2010;96:549-53. doi: 10.1016/j.otsr.2010.02.010.
- Olesen UK, Eckardt H, Bosemark P, Paulsen AW, Dahl B, Hede A. The Masquelet technique of induced membrane for healing of bone defects. A review of 8 cases. *Injury* 2015;46 Suppl 8:S44-7. doi: 10.1016/S0020-1383(15)30054-1.
- Yu X, Wu H, Li J, Xie Z. Antibiotic cement-coated locking plate as a temporary internal fixator for femoral osteomyelitis defects. *Int Orthop* 2017;41:1851-7. doi: 10.1007/s00264-016-3258-4.