



Contents lists available at ScienceDirect

International Journal of Surgery Case Reports

journal homepage: www.casereports.com

Unknown primary nasopharyngeal melanoma presenting as severe recurrent epistaxis and hearing loss following treatment and remission of metastatic disease: A case report and literature review[☆]



Saïd C. Azoury^{a,b,*}, Joseph G. Crompton^a, David M. Straughan^a, Nicholas D. Klemen^a, Emily S. Reardon^a, Tatiana H. Beresnev^{a,c}, Marybeth S. Hughes^a

^a Surgery Branch, National Cancer Institute, National Institutes of Health, Bethesda, MD 20892, USA

^b Department of Surgery, The Johns Hopkins Hospital, Johns Hopkins University, School of Medicine, USA

^c Clinical Monitoring Research Program, Leidos Biomedical Research, Inc., USA

ARTICLE INFO

Article history:

Received 18 March 2015

Accepted 29 March 2015

Available online 1 April 2015

Keywords:

Nasopharyngeal

Head and neck

Mucosal

Melanoma

Metastasis

ABSTRACT

INTRODUCTION: Primary nasopharyngeal melanoma is an exceedingly rare pathology with unclear etiology and oftentimes obscure clinical presentation. Despite improved diagnostic capabilities, these lesions are often diagnosed at an advanced stage and associated prognosis is poor, partly due to high rates of recurrences and metastasis.

PRESENTATION OF CASE: A 74-year-old woman was diagnosed with metastatic melanoma to the liver, of unknown primary. Just prior to the time of diagnosis, she experienced several episodes of severe epistaxis which she managed conservatively. Her symptoms eventually subsided without further medical evaluation. The patient was initially treated with interleukin-2 (IL-2) for her advanced disease, but her cancer progressed. She was then enrolled in a protocol for percutaneous hepatic perfusion (PHP) with melphalan and had complete radiographic resolution of disease, yet her nosebleeds recurred and persisted despite conservative measures. Six years after her initial diagnosis, a nasopharyngoscopy demonstrated a pigmented lesion in the posterior nasopharynx. Surgical resection was performed (pathology consistent with mucosal melanoma) followed by radiation therapy. She has since had complete resolution of bleeding and shows no evidence of cancer.

DISCUSSION: To our knowledge, this is the first report of a diagnosis of primary nasopharyngeal melanoma 6-years following complete remission of metastatic disease. Surgery remains the primary treatment for disease and symptom control in this setting.

CONCLUSION: Timely diagnosis of nasopharyngeal melanomas remains challenging. Thorough clinical evaluations should be performed in such patients, and attention should be paid to recurrent and persistent symptoms, such as epistaxis and hearing loss. This may allow for earlier detection of primary disease.

Published by Elsevier Ltd. on behalf of Surgical Associates Ltd. This is an open access article under the CC BY-NC-ND license (<http://creativecommons.org/licenses/by-nc-nd/4.0/>).

1. Introduction

Whereas cutaneous melanoma is a familiar entity to many clinicians and patients alike, primary head and neck mucosal melanoma (HNMM) is a rare pathology with an unclear etiology and oftentimes obscure clinical presentation [1,2]. Similar to cutaneous

melanoma, there has been an increase in the incidence of HNMM in the United States since the late 1980s, most notably in white females ages 55–84 [3,4]. Despite advances in diagnostic capabilities and treatment approaches, prognosis remains poor and the 5-year overall survival rate is 10–30%, partly due to high rates of recurrences and metastasis [4].

Nasopharyngeal melanoma is an exceedingly rare type of HNMM and its incidence is usually reported with nasal cavity and sinonasal tract melanomas. Mucosal melanomas in these locations account for 4% of HNMMs and 4% of nasal tract/nasopharyngeal neoplasms [5]. Hearing loss, epistaxis, and nasal congestion are presenting symptoms, however the diagnosis is often delayed several months following symptom onset [6,7]. We present a report of a woman who had a complete response to systemic treatment of

[☆] This report has not been previously published or presented at a national/international meeting.

* Corresponding author at: National Cancer Institute, National Institutes of Health; Department of Surgery, Johns Hopkins University, School of Medicine, The Johns Hopkins Hospital, 600 N. Wolfe Street, Blalock 658, Baltimore, MD 21287, USA. Tel.: +1 4109556796/9846; fax: +1 4109559846.

E-mail address: sazoury1@jhmi.edu (S.C. Azoury).

metastatic melanoma of unknown origin. Six years later, a diagnosis of primary nasopharyngeal melanoma was made after an extensive work-up for recurrent symptoms of severe right-sided epistaxis and hearing loss. Herein, we describe the clinical decision-making and multidisciplinary management involved in the care of the patient.

2. Presentation of case

In February 2007, a 74-year-old woman presented with abdominal pain and generalized malaise. A CT showed multiple liver masses and subsequent biopsy was consistent with metastatic melanoma. Extensive work-up did not reveal a primary source of melanoma. Just prior to the time of diagnosis, she experienced severe epistaxis that she treated conservatively; these symptoms resolved and she did not pursue further medical work-up for her nosebleeds. She was initially treated with interleukin-2 (IL-2) for stage IV disease, but her cancer progressed. In November 2007, she enrolled in a National Institutes of Health (NIH) study investigating percutaneous hepatic perfusion (PHP) with melphalan for ocular or cutaneous melanoma metastatic to the liver. She tolerated two doses, but stopped therapy because of systemic toxicity. Despite no further treatment, her burden of disease decreased at subsequent visits and she was declared to have complete radiographic eradication of all tumor sites by April 2009.

In January 2013, the patient presented to an otolaryngology clinic for follow-up of chronic right-sided cerumen impaction and recurrent severe right-sided epistaxis. Following an unremarkable clinical exam, she was continued on a moisturization regimen with saline nasal spray, gel, and a humidifier. Symptoms persisted and the aforementioned regimen was modified to include other over-the-counter agents. She was later evaluated in April 2013 with similar complaints as well as diminished hearing. On exam, her physician noted right nasal turbinate swelling and

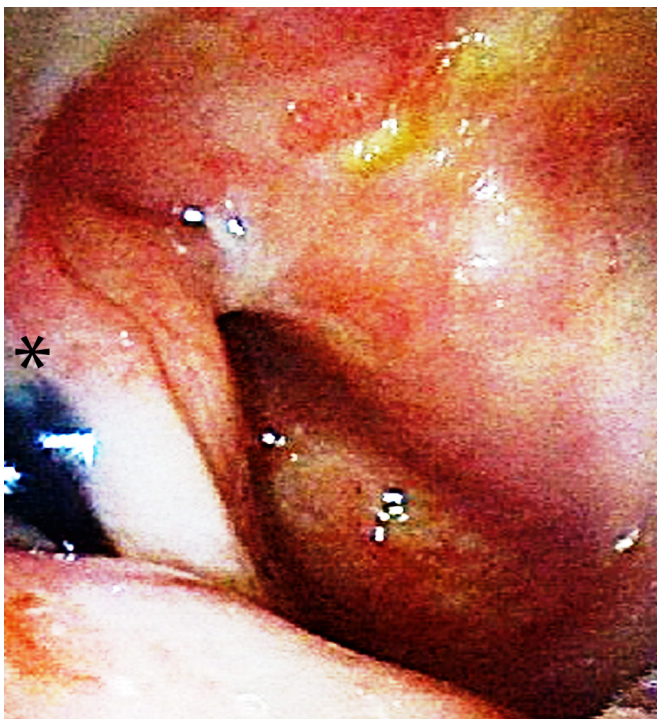


Fig. 1. Endoscopic evaluation revealed a dark melanotic lesion located in the right nasopharynx (bottom left).

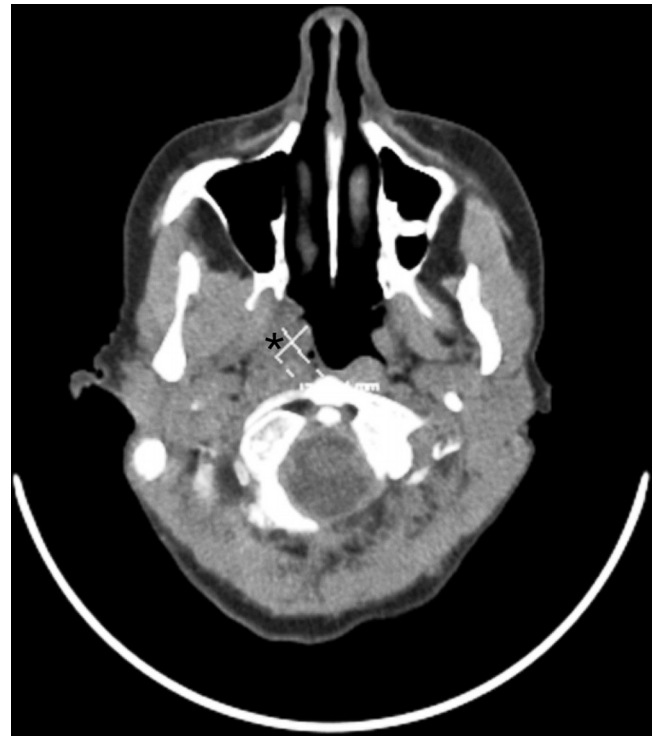


Fig. 2. Computed-tomography demonstrating a 1.3 × 1 cm lesion in the right fossa of Rosenmuller involving the eustachian orifice and tympanomastoid effusion.

septal ooze, as well as right ear cerumen impaction. Nasal packing was performed and the patient returned home, but bleeding persisted. The patient sought medical evaluation at a local hospital, and a limited nasal endoscopy was performed, revealing no bleeding source and a widely patent nasal cavity with no suspicious lesions. She subsequently returned to her original otolaryngology clinic and a more complete nasopharyngoscopy was performed, revealing a dark-nodular pigmented lesion in the right posterior nasopharynx with no evidence of satellite melanosis (Fig. 1). Imaging showed a 1.3 × 1 cm lesion in the right fossa of Rosenmuller obstructing the eustachian orifice and a right tympanomastoid effusion (Fig. 2). Staging PET scan demonstrated metabolic hyperactivity in this area extending into the ipsilateral torus tubarius and posteriorly into the eustachian tube orifice but without further evidence of local or metastatic disease. She underwent partial nasopharyngectomy, posterior septectomy, and resection of right torus in June 2013 via an endoscopic endonasal approach. Final pathology report demonstrated malignant mucosal melanoma (positive for S-100, HMB45, and Melan-A; BRAF and c-kit mutation-negative) and adjuvant radiation therapy (total of 70 Gy) was administered in September. She has since been doing remarkably well. In October 2013, several months following her surgery, examination of her right ear demonstrated a clear external auditory canal, with no evidence of effusion, retraction, or perforation. Surveillance imaging, clinical exams, and laboratory studies through November 2014 have been unremarkable for recurrent or metastatic disease, and she has had no further episodes of epistaxis.

3. Discussion

Primary mucosal melanoma accounts for approximately 0.03% of all cancer diagnoses, and head and neck cases account for 0.7–3.8% of melanomas [2,8]. Given its rarity, much of the management approach to nasopharyngeal melanoma is derived from

experience with sinonasal tract melanomas. One clinicopathologic review of nasopharyngeal/sinonasal tract melanomas performed at a single center over 25 years included 115 cases, of which, 9 (7.8%) were nasopharyngeal in origin [5]. The most common symptoms reported, in decreasing order, were epistaxis, mass/obstructive symptoms, difficulty breathing, pain, polyps, and nasal discharge [5]. Timely diagnosis of nasopharyngeal melanomas remains challenging, as such symptoms are often indistinguishable from benign processes and visual inspection is not possible without endoscopy (unlike cutaneous melanoma) [5]. Hence, it is not surprising that several studies have observed a 6–8 month delay in diagnosis from the reported onset of symptoms [5,6].

Surgical resection is the primary treatment modality for HNMMs and adjuvant radiation therapy improves local control, yet the overall survival is poor independent of treatment approach [2,4]. Complete surgical excision to negative margins is the goal but is not always possible, often a result of complex anatomy and proximity of the tumor to vital structures [5,9]. For sinonasal malignant melanomas, outcomes are similar when comparing endoscopic and open surgical approaches [10]. In addition to surgery, radiation and chemotherapy have been evaluated as adjuvant treatment for HNMM; however, it is uncertain if either of these systemic therapies improve survival outcomes [11,12]. Radiation therapy following surgery offers better local-regional control than radiation alone, and improves disease control even for small tumors [13].

The recurrence rate following definitive treatment for HNMM approaches 50%, with a mean time interval to recurrence of 13–14 months [6,14]. An analysis from the Surveillance, Epidemiology, and End Results (SEER) registry between 1973 and 2007 identified several independent predictors of poor overall and disease free survival [15]. Such factors include nasopharynx/paranasal sinus location, age greater than 70 years and distant metastasis, all of which are features pertinent to our case report [15]. At the molecular level, cell cycle and apoptotic regulators may serve as prognostic indicators in HNMMs, as expression of bcl-2 has been associated with improved survival and loss of p16 with tumor progression [16].

For certain pathologies, it is often difficult to distinguish a metastasis from a primary neoplasm, however, a de novo primary nasopharyngeal mucosal melanoma is much more likely than metastasis [17]. Up to 50% of patients with primary HNMM may develop distant metastasis to the brain, liver, and lungs [18]. Metastatic melanoma has a poor prognosis, with an associated median survival of approximately 3–6 months [7,19]. Female sex and prior immunotherapy have been associated with prolonged survival in patients with metastatic disease [19]. Cisplatin and accelerated hyperfractionated radiation has been studied in patients presenting with malignant melanoma of the nasal cavity and nasopharynx that are too advanced for surgery [11]. Of four such patients, three achieved complete local eradication of disease but later died of disseminated disease after 9–21 months, and one patient had no evidence of disease at a 34-month follow-up from treatment [11]. Our patient presented first with metastatic disease after progressing on IL-2 therapy and was enrolled on a PHP protocol for ocular/cutaneous melanoma based on assumption that this was likely of cutaneous origin. A study reviewing PHP for unresectable hepatic malignancies demonstrated a 50% overall response rate in patients with ocular melanoma, including two complete responses with durations of 10 and 12 months [20]. The patient presented in this report has survived more than seven years since her initial diagnosis, and to our knowledge, this is the first report of such a presentation and management of unknown primary melanoma following successful treatment of metastatic disease.

4. Conclusion

Nasopharyngeal mucosal melanoma is an exceedingly rare tumor and there is a paucity of data regarding clinical presentation and management of local and systemic disease. Surgery is the primary treatment and radiation therapy improves local control in the adjuvant setting. This report demonstrates that resection of a primary nasopharyngeal melanoma may be performed successfully after a delayed diagnosis following treatment and remission of metastatic disease. Thorough clinical evaluations should be performed in such patients, and attention should be paid to recurrent and persistent symptoms, as epistaxis and hearing loss. This may allow for earlier detection of primary disease.

Conflict of interest

The authors have no financial disclosures or multiplicity of interests.

Consent

Consent for publication was obtained from the patient presented in this report and is available for review.

References

- [1] S.C. Azoury, J.R. Lange, Epidemiology, risk factors, prevention, and early detection of melanoma, *Surg. Clin. North Am.* 94 (5) (2014) 945–962.
- [2] F. Lopez, J.P. Rodrigo, A. Cardesa, et al., Update on primary head and neck mucosal melanoma, *Head Neck* (2014), <http://dx.doi.org/10.1002/hed.23872>.
- [3] D.M. Marcus, R.P. Marcus, R.S. Prabhu, et al., Rising incidence of mucosal melanoma of the head and neck in the United States, *J. Skin Cancer* 2012 (2012) 231693.
- [4] S. Manolidis, P.J. Donald, Malignant mucosal melanoma of the head and neck: review of the literature and report of 14 patients, *Cancer* 80 (8) (1997) 1373–1386.
- [5] L.D. Thompson, J.A. Wieneke, M. Miettinen, Sinonasal tract and nasopharyngeal melanomas: a clinicopathologic study of 115 cases with a proposed staging system, *Am. J. Surg. Pathol.* 27 (5) (2003) 594–611.
- [6] N. McLean, M. Tighiout, S. Muller, Primary mucosal melanoma of the head and neck. Comparison of clinical presentation and histopathologic features of oral and sinonasal melanoma, *Oral Oncol.* 44 (11) (2008) 1039–1046.
- [7] E.H. Dauer, J.E. Lewis, A.L. Rohlinger, A.L. Weaver, K.D. Olsen, Sinonasal melanoma: a clinicopathologic review of 61 cases, *Otolaryngol. Head Neck Surg.* 138 (3) (2008) 347–352.
- [8] M.J. Hicks, C.M. Flaitz, Oral mucosal melanoma: epidemiology and pathobiology, *Oral Oncology.* 36 (2) (2000) 152–169.
- [9] R. Gonzalez-Garcia, L. Ruiz-Laza, L. Roman-Romero, Lateral rhinotomy combined with anterior transantral approach for the treatment of large malignant melanoma of the nasal cavity involving the nasopharynx, *J. Cranio-Maxillo-Facial Surg.* 40 (3) (2012) 266–270.
- [10] X.J. Meng, H.F. Ao, W.T. Huang, et al., Impact of different surgical and postoperative adjuvant treatment modalities on survival of sinonasal malignant melanoma, *BMC Cancer.* 14 (2014) 608.
- [11] M. Albertsson, J. Tennvall, T. Andersson, A. Biorlund, A. Elner, L. Johansson, Malignant melanoma of the nasal cavity and nasopharynx treated with cisplatin and accelerated hyperfractionated radiation, *Melanoma Res.* 2 (2) (1992) 101–104.
- [12] J.M. Owens, D.B. Roberts, J.N. Myers, The role of postoperative adjuvant radiation therapy in the treatment of mucosal melanomas of the head and neck region, *Arch. Otolaryngol. Head Neck Surg.* 129 (8) (2003) 864–868.
- [13] K. Christopherson, R.S. Malyapa, J.W. Werning, C.G. Morris, J. Kirwan, W.M. Mendenhall, Radiation therapy for mucosal melanoma of the head and neck, *Am. J. Clin. Oncol.* (2013).
- [14] M.S. Brandwein, A. Rothstein, W. Lawson, C. Bodian, M.L. Urken, Sinonasal melanoma: a clinicopathologic study of 25 cases and literature meta-analysis, *Arch. Otolaryngol. Head Neck Surg.* 123 (3) (1997) 290–296.
- [15] D. Jethanamest, P.M. Vila, A.G. Sikora, L.G. Morris, Predictors of survival in mucosal melanoma of the head and neck, *Ann. Surg. Oncol.* 18 (10) (2011) 2748–2756.
- [16] M.L. Prasad, S.G. Patel, J.P. Shah, S. Hoshaw-Woodard, K.J. Busam, Prognostic significance of regulators of cell cycle and apoptosis, p16(INK4a), p53, and bcl-2 in primary mucosal melanomas of the head and neck, *Head Neck Pathol.* 6 (2) (2012) 184–190.
- [17] J.G. Batsakis, J.A. Regezi, A.R. Solomon, D.H. Rice, The pathology of head and neck tumors: mucosal melanomas, Part XIII, *Head Neck Surg.* 4 (5) (1982) 404–418.

- [18] M. Meleti, C.R. Leemans, R. de Bree, P. Vescovi, E. Sesenna, I. van der Waal, Head and neck mucosal melanoma: experience with 42 patients, with emphasis on the role of postoperative radiotherapy, *Head Neck* 30 (12) (2008) 1543–1551.
- [19] J. Manola, M. Atkins, J. Ibrahim, J. Kirkwood, Prognostic factors in metastatic melanoma: a pooled analysis of Eastern Cooperative Oncology Group trials, *J. Clin. Oncol.* 18 (22) (2000) 3782–3793.
- [20] J.F. Pingpank, S.K. Libutti, R. Chang, I. et al. Phase, study of hepatic arterial melphalan infusion and hepatic venous hemofiltration using percutaneously placed catheters in patients with unresectable hepatic malignancies, *J. Clin. Oncol.* 23 (15) (2005) 3465–3474.

Open Access

This article is published Open Access at sciedirect.com. It is distributed under the [IJSCR Supplemental terms and conditions](#), which permits unrestricted non commercial use, distribution, and reproduction in any medium, provided the original authors and source are credited.