

CASE REPORT

INTERMEDIATE

CLINICAL CASE

Transcatheter Aortic Valve Replacement for Aortic Stenosis With Prosthetic Mitral Paravalvular Leak and Hemolytic Anemia



Hideaki Kanzaki, MD, PhD,^a Yusuke Shimahara, MD, PhD,^b Makoto Amaki, MD, PhD,^a Atsushi Okada, MD, PhD,^a Tomoyuki Fujita, MD, PhD,^b Chisato Izumi, MD, PhD,^a Satoshi Yasuda, MD, PhD,^a Junjiro Kobayashi, MD, PhD^b

ABSTRACT

This report describes a successful transcatheter aortic valve replacement in an older patient with severe aortic stenosis, mitral paravalvular leak, and associated hemolytic anemia. Transcatheter aortic valve replacement is worth considering as a first-line procedure in this high-risk patient because of its beneficial impact on reducing shear forces at the mitral valve. (**Level of Difficulty: Intermediate.**) (J Am Coll Cardiol Case Rep 2020;2:2146-50) © 2020 The Authors. Published by Elsevier on behalf of the American College of Cardiology Foundation. This is an open access article under the CC BY-NC-ND license (<http://creativecommons.org/licenses/by-nc-nd/4.0/>).

Paravalvular leak (PVL) is among the complications associated with prosthetic heart valve replacement. Mitral PVLs can occur in patients who have undergone surgical mitral valve replacement (MVR), with an incidence of 7% to 17% (1). Most PVLs are asymptomatic; however, clinically significant PVLs have been reported at a rate of approximately 1% to 5% (2). Clinical manifestations such as congestive heart failure, hemolytic anemia, or a mixed presentation may occur in association with PVL. In case the patient develops shortness of breath or requires multiple transfusions, closure of the PVL is recommended.

Surgical repair or valve re-replacement has been an established therapy for operable patients (2,3). Meanwhile, percutaneous repair using plugs has emerged as a therapeutic option for high-risk patients (3). Surgical treatment achieves a higher degree of PVL reduction but is associated with higher early morbidity and mortality than percutaneous repair (4).

Although several investigators have reported transcatheter aortic valve replacement (TAVR) in patients with a pre-existing prosthetic mitral valve (5-7), data on improvement in mitral PVL after TAVR is limited. Here, we describe a case of successful TAVR in an elderly patient with severe aortic stenosis (AS) and mitral PVL-related hemolytic anemia.

LEARNING OBJECTIVES

- To be able to diagnose cardiac prosthesis-related hemolytic anemia.
- To understand the treatment of PVL-related mechanical hemolysis.

HISTORY OF PRESENTATION

An 82-year-old woman was admitted to our institute with the chief complaint of increasing shortness of breath. Her blood pressure was 128/62 mm Hg, pulse 74 beats/min, an oxygen saturation 96% on room air.

From the ^aDepartment of Cardiovascular Medicine, National Cerebral and Cardiovascular Center, Osaka, Japan; and the ^bDepartment of Cardiac Surgery, National Cerebral and Cardiovascular Center, Osaka, Japan.

The authors attest they are in compliance with human studies committees and animal welfare regulations of the authors' institutions and Food and Drug Administration guidelines, including patient consent where appropriate. For more information, visit the *JACC: Case Reports* [author instructions page](#).

Manuscript received March 9, 2020; revised manuscript received July 7, 2020, accepted July 21, 2020.

The physical examination was notable for conjunctival pallor. She had a grade 3/6, high-pitched, ejection systolic murmur that was loudest at the second left intercostal space, radiating toward the neck.

PAST MEDICAL HISTORY

Her past medical history included long-standing atrial fibrillation, hypertension, hyperlipidemia, and chronic lung disease. Twelve years before the presentation, she was diagnosed with severe mitral stenosis and underwent MVR with a 27-mm ATS mechanical valve (ATS Medical, Minneapolis, Minnesota).

DIFFERENTIAL DIAGNOSIS

The differential diagnosis of her presenting symptoms included anemia and valvular heart disease, most likely AS.

INVESTIGATIONS

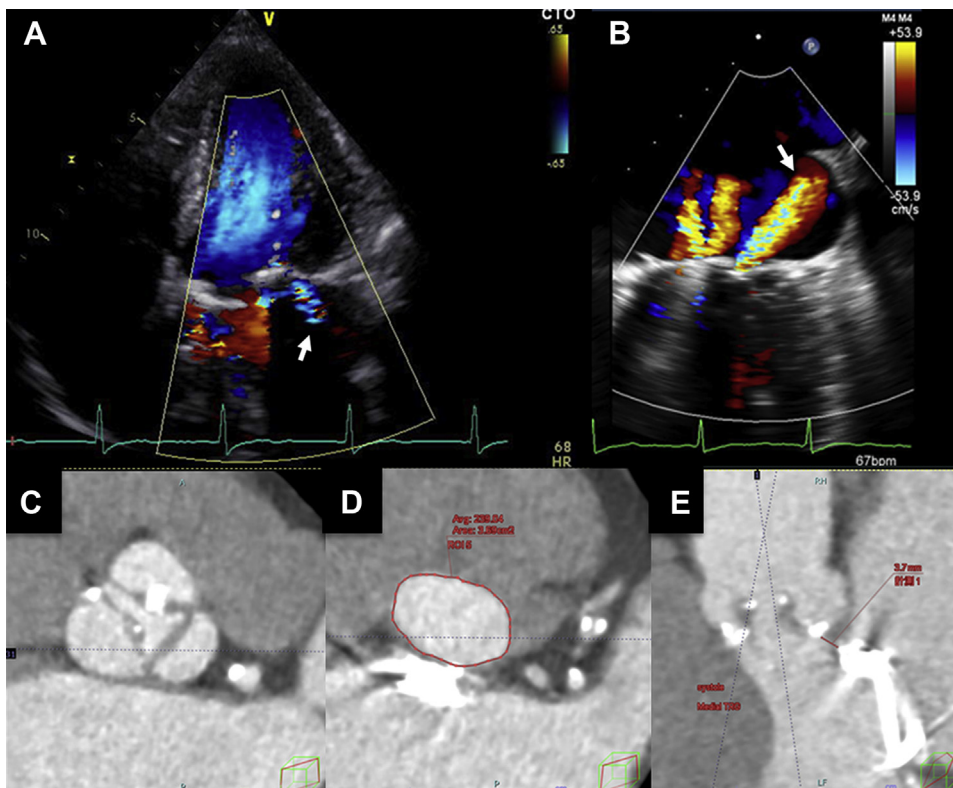
Laboratory tests revealed normochromic, normocytic anemia with hemoglobin of 9.5 g/dl and an elevated reticulocyte count (3.9%); other notable findings included elevated serum lactate dehydrogenase (1,880 IU/l), low haptoglobin (<10 mg/dl), and elevated total bilirubin level (1.6 mg/dl). Creatinine, C-reactive protein, platelet count, vitamin B12, and folic acid levels were within normal limits. Multiple fecal occult blood tests were all negative. Schistocytes were detected in a peripheral blood smear, and B-type natriuretic peptide was detected at an elevated 222.9 pg/ml.

Echocardiography revealed a normal left ventricular (LV) ejection fraction, but severe AS with an aortic valve area of 0.60 cm² was noted. The peak aortic velocity was high, measured at 5.3 m/s, with a

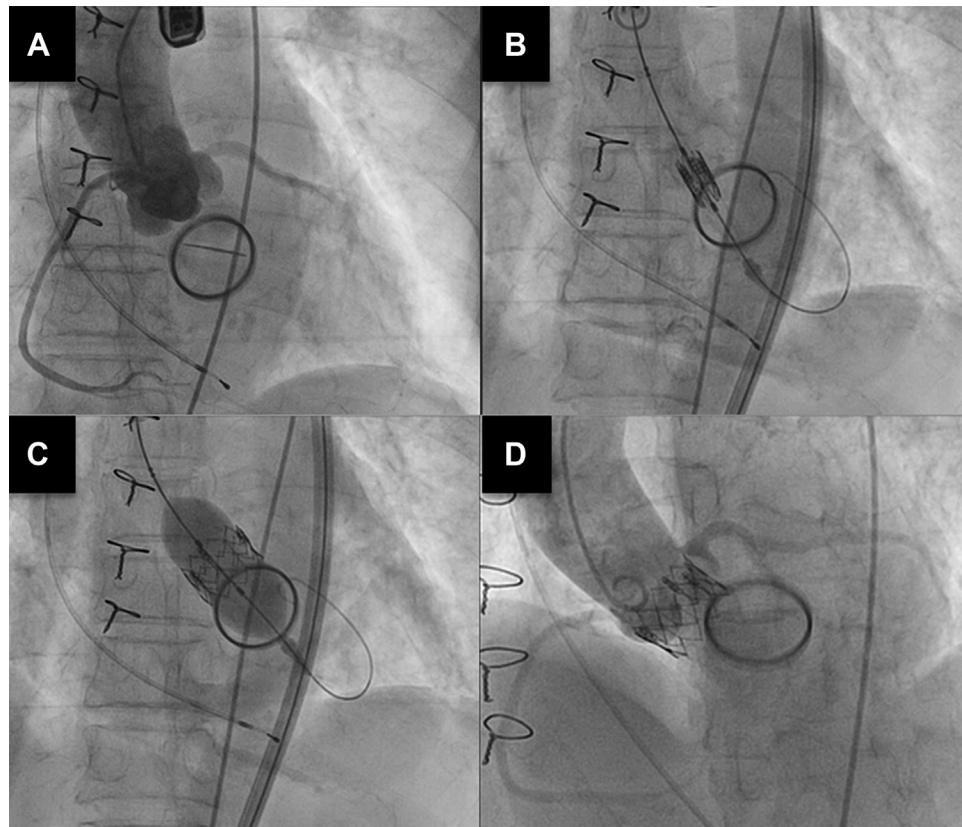
ABBREVIATIONS AND ACRONYMS

- AS** = aortic stenosis
- LV** = left ventricular/ventricle
- MVR** = mitral valve replacement
- PVL** = paravalvular leak
- TAVR** = transcatheter aortic valve replacement

FIGURE 1 Echocardiography and Multidetector Computed Tomography Imaging Prior to Transcatheter Aortic Valve Replacement



A single mitral paravalvular leak (arrow) was detected by (A) transthoracic echocardiography and (B) transesophageal echocardiography. (C) Calcification of aortic valve leaflet, (D) aortic annulus area, and the (E) distance between the aortic annulus and prosthetic mitral prosthesis determined by multidetector computed tomography.

FIGURE 2 Transcatheter Aortic Valve Replacement Procedure

(**A**) Aortography at the aortic root, (**B**) positioning of the prosthetic aortic valve, (**C**) deployment of the prosthetic aortic valve, and (**D**) aortography after the procedure.

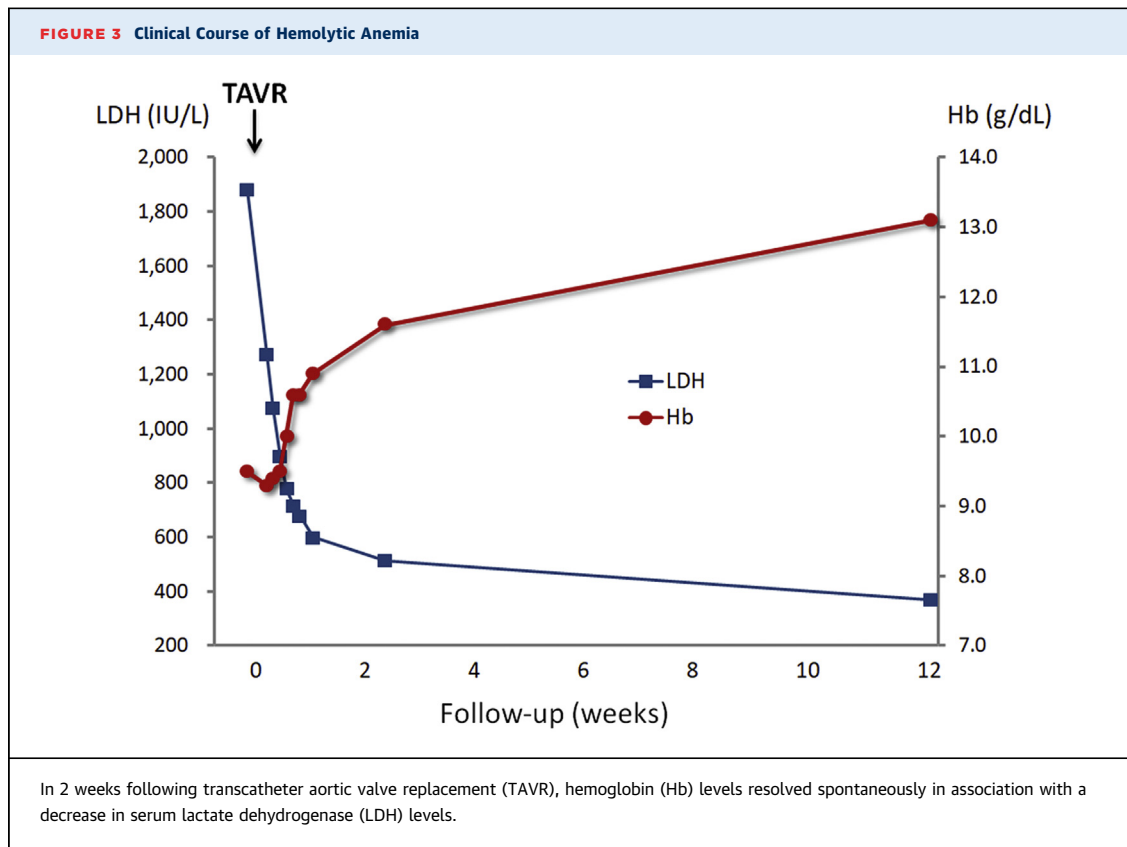
mean pressure gradient of 73 mm Hg. Grade 1 tricuspid regurgitation with a pressure gradient of 48 mm Hg also identified. A color flow Doppler study revealed a PVL at the prosthetic mitral valve (**Figure 1A**). The transprosthetic mitral mean pressure gradient was 3.0 mm Hg. Transesophageal echocardiography revealed a single grade 2 PVL (vena contracta width of 3 mm) near the left atrial appendage (**Figure 1B**, **Video 1**). Right heart catheterization performed for evaluation before surgery revealed a pulmonary artery wedge pressure of 25 mm Hg with a V-wave of 36 mm Hg; the pulmonary artery pressure was 50/20 mm Hg, with a mean pressure of 31 mm Hg.

Anemia persisted despite oral iron supplementation, and erythrocyte transfusion was required. Given her cardiac status, redo MVR, together with aortic valve replacement, was considered. However, the predicted operative mortality was high, determined at 14.7% and 16.1% by the Society of Thoracic Surgeons risk score and the EuroSCORE (European

System for Cardiac Operative Risk Evaluation) II, respectively. Given the high Society of Thoracic Surgeons and EuroSCORE II scores, the heart team at our hospital opted for the less invasive TAVR procedure. A multidetector computed tomography scan performed in preparation for the TAVR revealed that calcification of aortic valve leaflets (**Figure 1C**) and an aortic annulus area of 369 mm² (**Figure 1D**). The distance from the aortic annulus to the edge of the prosthetic mitral valve was 5.5 mm (**Figure 1E**).

MANAGEMENT

After aortography (**Figure 2A**), a straight wire was passed through the stenotic aortic valve under the guide of a 6-F AL-1 catheter; a 5-F pigtail catheter was then inserted into the LV. Before the procedure, LV and aortic pressures were 206/~20 mm Hg and 105/34 mm Hg, respectively, which are values consistent with severe AS. Through the pigtail



catheter, a round-shaped Amplatz stiff wire (Boston Scientific, Marlborough, Massachusetts) was placed in the LV, and a 23-mm SAPIEN XT prosthetic valve (Edwards Lifesciences, Irvine, California) was deployed to an optimal position (Figures 2B and 2C, Video 2). We verified no limitations by the newly implanted prosthesis in the motion of the mitral valve leaflets (Figure 2D, Video 3). After the procedure, LV and aortic pressures were 145/~20 mm Hg and 140/38 mm Hg, respectively, a 60-mm Hg decrease in LV systolic pressure. Transesophageal echocardiography with color flow Doppler imaging revealed a grade 1 aortic PVL and no mitral PVL.

At day 1 following TAVR, hemoglobin levels increased spontaneously, together with a decrease in serum lactate dehydrogenase (Figure 3). No additional blood transfusions were required, and her symptoms disappeared.

DISCUSSION

On initial evaluation, echocardiography revealed both severe AS and a moderate PVL at a prosthetic mitral valve. Significant mechanical hemolysis related to native stenotic aortic valves have also been

reported, but they are rare events (8); as such, we concluded that hemolytic anemia was most likely secondary to mechanical destruction of red blood cells at the PVL. To the best of our knowledge, this is the first report of the efficacy of TAVR on both severe AS and mitral valve prosthesis-related hemolysis in a high-risk surgical patient.

According to the guidelines for the management of valvular heart disease, transcatheter PVL closure is a Class IIa indication for patients at high risk for surgery (3). However, in our patient, the more immediate concern was formulating an appropriate treatment strategy for the severe AS. Hence, our heart team opted for the TAVR. We were intrigued to note that, after the procedure, her anemia improved more than expected despite no intervention at the mitral PVL. As such, we conclude that the treatment of AS was profoundly beneficial not only with respect to pressure gradients at the aortic valve, but also with respect to the resolution of mechanical hemolysis.

On reviewing the case, we found that the mitral PVL itself might have been responsible for the symptoms related to congestive heart failure. Even moderate mitral PVLs may result in marked increases in left atrial pressure in patients with noncompliant

left atrium. In the present case, prior long-standing mitral stenosis possibly already led to impaired compliance in the left atrium. Thus, TAVR might have improved her symptoms of shortness of breath due to congestive heart failure secondary to mitral PVL.

FOLLOW-UP

As shown in **Figure 3**, 3 months after TAVR, her hemoglobin had returned to the normal range, and her B-type natriuretic peptide level had decreased to 37.5 pg/ml. She remained well with no significant symptoms 3 years after the procedure.

CONCLUSIONS

The symptoms presented by this 82-year-old woman were most likely associated with a complex mix of factors, including severe AS, mitral PVL, and anemia. Interestingly, TAVR was quite effective not

only for severe AS, but also for resolving the PVL-related mechanical hemolytic anemia. Our conclusion is that the treatment of AS effectively reduced the mitral PVL and simultaneously eliminated the pathological high shear forces. The present case suggests that TAVR is worth considering first-line procedure in patients with severe AS and a mitral PVL after MVR who are at high risk for redo valve surgery.

AUTHOR DISCLOSURES

The authors have reported that they have no relationships relevant to the contents of this paper to disclose.

ADDRESS FOR CORRESPONDENCE: Dr. Hideaki Kanzaki, Department of Cardiovascular Medicine, Heart Failure Division, National Cerebral and Cardiovascular Center, 6-1, Kishibe-Shimmachi, Suita, Osaka 564-8565, Japan. E-mail: kanzakih@ncvc.go.jp.

REFERENCES

1. Hammermeister K, Sethi GK, Henderson WG, Grover FL, Oprian C, Rahimtoola SH. Outcomes 15 years after valve replacement with a mechanical versus a bioprosthetic valve: final report of the Veterans Affairs randomized trial. *J Am Coll Cardiol* 2000;36:1152-8.
2. Botta L, De Chiara B, Quattrocchi S, et al. Mitral periprosthetic leakage: contemporary results of surgical correction at a single centre. *Interact Cardiovasc Thorac Surg* 2017;25:185-90.
3. Nishimura RA, Otto CM, Bonow RO, et al. 2017 AHA/ACC focused update of the 2014 AHA/ACC guideline for the management of patients with valvular heart disease: a report of the American College of Cardiology/American Heart Association Task Force on Clinical Practice Guidelines. *J Am Coll Cardiol* 2017;70:252-89.
4. Alkhouli M, Rihal CS, Zack CJ, et al. Transcatheter and surgical management of mitral paravalvular leak: long-term outcomes. *J Am Coll Cardiol Intv* 2017;10:1946-56.
5. Asil S, Şahiner L, Özer N, et al. Transcatheter aortic valve implantation in patients with a mitral prosthesis; single center experience and review of literature. *Int J Cardiol* 2016;221:390-5.
6. Amat-Santos JJ, Cortés C, Nombela Franco L, et al. Prosthetic mitral surgical valve in transcatheter aortic valve replacement recipients: a multicenter analysis. *J Am Coll Cardiol Intv* 2017; 10:1973-81.
7. Scholtz S, Piper C, Horstkotte D, et al. Transcatheter aortic valve implantation in patients with pre-existing mechanical mitral valve prostheses. *J Invasive Cardiol* 2019;31:260-4.
8. Alkhouli M, Farooq A, Go RS, Balla S, Berzingi C. Cardiac prostheses-related hemolytic anemia. *Clin Cardiol* 2019;42:692-700.

KEY WORDS aortic stenosis, case report, hemolysis, paravalvular leak, transcatheter aortic valve replacement

APPENDIX For supplemental videos, please see the online version of this paper.