

Spinal intramedullary tuberculoma following pulmonary tuberculosis

A case report and literature review

Guan-Chyuan Wang, MD, Sheng-Wen Wu, MD*

Abstract

Rationale: Spinal intramedullary tuberculoma (IMTB) is a rare disease that accounts for 1 to 2/100,000 patients with tuberculosis. We presented a case with pulmonary tuberculosis and concurrent IMTB at C3 to C5 level and reviewed the recent case series and discussed the diagnosis, treatment, and outcome.

Patient concerns: A 33-year-old male had concurrent pulmonary TB and IMTB at the C3 to C5 level. He had quadriplegia (muscle power 0 at 4 limbs) and sensory loss below C5 level. He also had incontinence, anal tone loss, and paradoxical respiratory pattern.

Diagnosis: Spinal magnetic resonance imaging (MRI) showed a 25 × 11mm intramedullary lesion at C3/C4 level. Under the impression of IMTB, he underwent surgery.

Intervention: We performed C3 to C5 laminectomy and en bloc removal of the tumor. The patient kept receiving anti-TB medications after the surgery.

Outcome: His 4 limbs muscle power had improved but could not be liberated from the endotracheal tube, so tracheostomy was performed. Muscle power gradually increased to 3 points in his upper limbs and to 2 points in his lower limbs. Sensation in his 4 limbs gradually improved as well.

Lessons: IMTB is a rare disease that should be treated with a combination of medication and surgery. For patients with prominent spinal cord compression and neurological symptoms, early operation to remove the tumor is necessary.

Abbreviations: HIV = human immunodeficiency virus, IMTB = intramedullary tuberculoma, MRI = magnetic resonance imaging, TB = pulmonary tuberculosis.

Keywords: intramedullary lesion, spinal tuberculosis, surgery, treatment

1. Introduction

Pulmonary tuberculosis (TB) involving the spine is not uncommon. However, spinal intramedullary tuberculoma (IMTB) is a rare disease first reported in 1956.^[1] The prevalence of IMTB has

been reported as 1 to 2/100,000 patients with tuberculosis.^[2–6] We report the case of a patient who had pulmonary TB and developed IMTB during his treatment course. We present the images, intraoperative video, pathology, and treatment in this article. We will review the literature and focus on discussing the diagnosis, treatment, and outcomes.

Editor: N/A.

Informed consent was obtained from the patient. He could not write due to muscle weakness so he used fingerprint to sign the consent form. Additionally, there is no identifiable information about the patient in the article. This study has been approved by the Research Ethics Committee of Hualien Tzu Chi Hospital, Buddhist Tzu Chi Medical Foundation on September/13/2017.

No funding was received for this research.

The authors declare that they have no conflicts of interest.

Supplemental Digital Content is available for this article.

Department of Neurosurgery, Neuro-Medical Scientific Center, Buddhist Tzu Chi Hospital, Hualien, Taiwan.

* Correspondence: Sheng-Wen Wu, MD, Department of Neurosurgery, Neuro-Medical Scientific Center, Buddhist Tzu Chi General Hospital, 707, Section 3, Chung Yang Road, Hualien, 970, Taiwan (e-mail: B8801006@gmail.com/b9402097@gmail.com).

Copyright © 2017 the Author(s). Published by Wolters Kluwer Health, Inc. This is an open access article distributed under the terms of the Creative Commons Attribution-Non Commercial License 4.0 (CCBY-NC), where it is permissible to download, share, remix, transform, and buildup the work provided it is properly cited. The work cannot be used commercially without permission from the journal.

Medicine (2017) 96:49(e8673)

Received: 25 September 2017 / Received in final form: 24 October 2017 /

Accepted: 26 October 2017

<http://dx.doi.org/10.1097/MD.0000000000008673>

2. Case report

The patient was a 33-year-old man with alcoholic liver cirrhosis and pulmonary TB. He was under anti-TB medications. He suffered from progressive bilateral lower limb numbness and weakness for 3 months. He visited a nearby hospital, where spinal x-ray and computed tomography were conducted. However, due to the lack of positive findings, he was transferred to our hospital.

At our hospital, physical examinations showed quadriplegia (muscle power 0 in all 4 limbs) and sensory loss below the C5 level. He also had incontinence, anal tone loss, and a paradoxical respiratory pattern. Spinal magnetic resonance imaging (MRI) showed a 25 × 11 mm intramedullary lesion at the C3/C4 level (Fig. 1). The lesion exhibited T2WI hyperintensity, with T2WI hypointensity at the center. Contrast-enhanced T1WI showed a ring-enhanced target sign (Fig. 1). The lesion was also accompanied by syringomyelia (Fig. 1).

Under the impression of IMTB, laminectomy removal of the tuberculoma was performed. We performed C3 to C5 laminectomy and then opened the dura and pia to enucleate the tuberculoma (Supplemental Video 1, <http://links.lww.com/MD/>

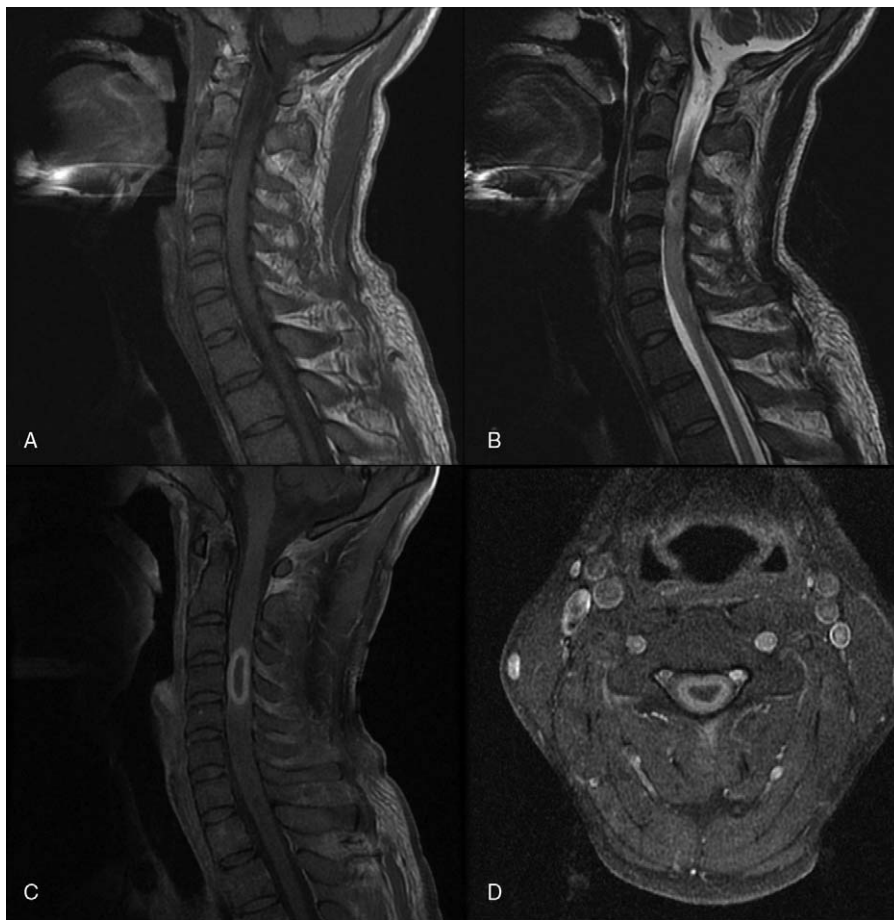

Figure 1. Magnetic resonance imaging (MRI) of the patient: (A) T1WI shows spinal cord swelling. (B) T2WI shows hyperintense lesion at C3 and C4 levels. (C) Contrast-enhanced T1WI shows typical target sign. (D) Axial view of the contrast-enhanced T1WI shows intramedullary lesion.

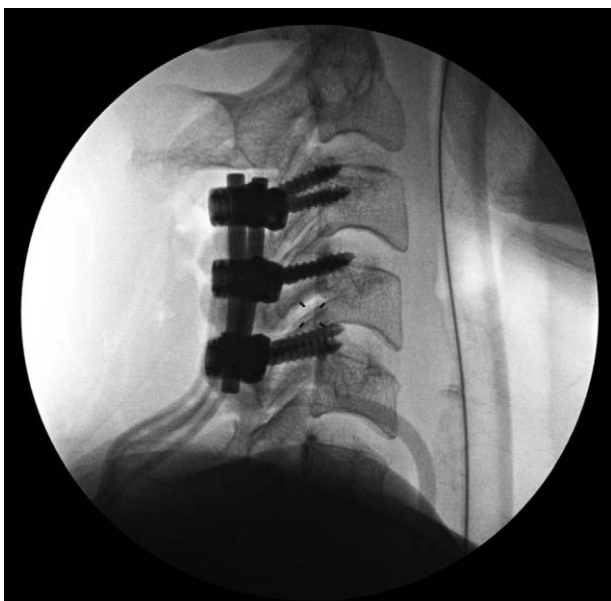

Figure 2. The postoperative image shows C3–C5 laminectomy and lateral mass screws.

C3). Placement of C3 to C5 lateral mass screws was performed for cervical spinal stability (Fig. 2). The patient gradually recovered and was admitted to the neurosurgical intensive care unit for postoperative care.

The patient had received steroid before and after the operation (betamethasone 4 mg Q8H for 14 days, then Q12H for 2 days, and Q1H for 2 days before discontinuation). Muscle power gradually increased to 3 points in his upper limbs and to 2 points in his lower limbs. Sensation in his 4 limbs gradually improved as well. However, he could not be removed from the ventilator due to pulmonary TB; therefore, tracheostomy was arranged 7 days after the operation. The final pathology showed granulomatous inflammation with caseous necrosis, compatible with tuberculosis (Fig. 3). He was scheduled for 18 months of anti-TB medication treatment.

3. Discussion

There are different opinions on whether IMTB is associated with pulmonary TB.^[5,7–9] Some studies have reported concurrent intracranial TB or Pott spine.^[2,5,10,11] The thoracic segment is the most common site of IMTB and hematogenous spread is believed to be the main cause of IMTB.^[6,11,12] Living in an endemic area or with immunosuppression (due to infection with human immunodeficiency virus [HIV]) have been associated with the disease.^[4,13] HIV tests were negative for our patient, but he had chronic liver cirrhosis, which may be a risk factor for the disease.

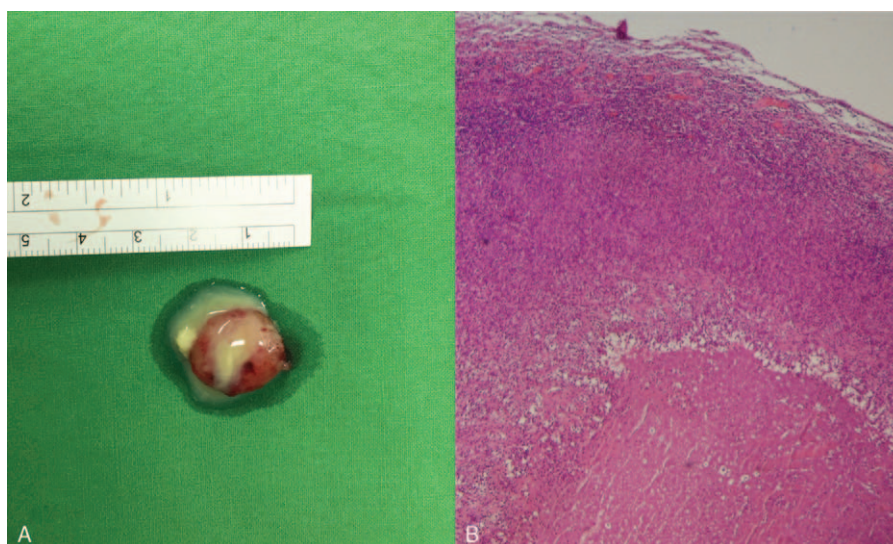


Figure 3. The specimen and the pathology: (A) A 2×2 nodule with central necrosis. (B) The postoperative pathologic results demonstrate centrozonal necrosis, epithelioid histiocytes, and lymphoid hyperplasia.

IMTB presents with symptoms of sensory loss, muscle weakness, and autonomic function loss depending on the spinal level involved. MRI is the optimal tool for evaluation and diagnosis. Because IMTB may be accompanied by intracranial TB, brain MRI should also be performed.^[11] On MRI, IMTB presents different characteristics in different phases.^[12,14] In the early phase, lesions appear homogenous and hyperintense to isointense in T1WI and T2WI images. However, in the late phase, due to caseous necrosis formation in the center of the tuberculoma, they become hypointense in the center in T2WI images. The different signal intensity in the late phase of T2WI is called the “target sign.”^[12,14] Contrast-enhanced MRI images show rim enhancement. Other differential diagnosis that should be taken into consideration include tumor, fungal infections, and lymphoma.^[15]

Anti-TB medication including isoniazid, rifampicin, ethambutol, and pyrazinamide for 18 months is necessary (isoniazid, rifampicin, ethambutol, and pyrazinamide for 6 months, followed by isoniazid and rifampicin for the next 12 months).^[5] A few patients have been reported to be cured by medication alone.^[5,8,11,16] However, most of the reported patients underwent surgery. The purpose of surgery is to decompress the spinal cord and to achieve neurological improvement.^[6,16,17] Hence, delayed surgery might be associated with worse outcomes.^[4]

There is no solid evidence on whether steroids should be administered and how many doses should be prescribed to treat IMTB. Many of the previous reports stated that short-term steroid treatment was prescribed for the patients.^[4,5,10,11,16,18] We used steroids for our patient (betamethasone 4mg Q8H) for 2 weeks and then gradually tapered the dosage. We believe the steroid was helpful for reducing spinal cord edema as well as traction damage during the surgery.

There are a few articles discussing the surgical procedure. The tuberculoma was enucleated in most of the previous cases, with the aim of preventing the bacteria from spreading if the abscess ruptures during the surgery. However, manipulation of the spinal canal when enucleating the tuberculoma is inevitable and may result in neurological damage, particularly because the spinal cord usually swells in IMTB. Ju et al suggested that anti-TB

medications should be prescribed for at least 3 weeks before surgery to prevent the TB bacteria from spreading during surgery.^[19] In our case, the patient had received 4 months of anti-TB medications and we enucleated the tumor without rupture. The pathological and abscess culture results showed that there were no TB bacteria. Therefore, in our opinion, if the tuberculoma is so large that aggressive manipulation of the spinal cord is inevitable during en bloc removal, it might be safer to drain the abscess first and remove the tuberculoma piece by piece if the patient had received anti-TB medications for a sufficient length of time.

4. Conclusion

IMTB is a rare disease that should be treated with a combination of medication and surgery. For patients with prominent spinal cord compression and neurological symptoms, early operation to remove the tumor is necessary.

Acknowledgment

The author wishes to acknowledge the help of Dr Ho-Mu Wu in collecting data and served as scientific advisors.

References

- [1] Cascino J, Dibble JB. Tuberculoma of spinal cord. *J Am Med Assoc* 1956;162:461–2.
- [2] Citow JS, Ammirati M. Intramedullary tuberculoma of the spinal cord: case report. *Neurosurgery* 1994;35:327–30.
- [3] Ratliff JK, Connolly ES. Intramedullary tuberculoma of the spinal cord. Case report and review of the literature. *J Neurosurg* 1999;90:125–8.
- [4] Li H, Liu W, You C. Central nervous system tuberculoma. *J Clin Neurosci* 2012;19:691–5.
- [5] Ramdurg SR, Gupta DK, Suri A, et al. Spinal intramedullary tuberculosis: a series of 15 cases. *Clin Neurol Neurosurg* 2009;111:115–8.
- [6] Liu J, Zhang H, He B, et al. Intramedullary tuberculoma combined with abscess: case report and literature review. *World Neurosurg* 2016;89:726.e1–4.
- [7] Dastur HM, Shah MD. Intramedullary tuberculoma of the spinal cord. *Indian Pediatr* 1968;5:468–71.

- [8] Sharma MC, Arora R, Deol PS, et al. Intramedullary tuberculoma of the spinal cord: A series of 10 cases. *Clin Neurol Neurosurg* 2002;104:279–84.
- [9] MacDonnell AH, Baird RW, Bronze MS. Intramedullary tuberculomas of the spinal cord: case report and review. *Rev Infect Dis* 1990;12:432–9.
- [10] Prasad S, Varma M, Vidyasagar S. Concurrent intracerebral and intramedullary spinal tuberculomas in an immunocompetent individual. *BMJ Case Rep* 2015;doi: 10.1136/bcr-2014-205496.
- [11] Jaiswal M, Gandhi A, Sharma A, et al. Experiences and conceptualisation of spinal intermedullary tuberculoma management. *Korean J Spine* 2015;12:5–11.
- [12] Lu M. Imaging diagnosis of spinal intramedullary tuberculoma: case reports and literature review. *J Spinal Cord Med* 2010;33:159–62.
- [13] Yusuf AS, Adeleke NA, Babalola OM, et al. Intramedullary tuberculoma of thoracic spinal cord in an apparently healthy Nigerian: a case report. *J West African Coll Surg* 2015;5:90–7.
- [14] Gupta VK, Sharma BS, Khosla VK, et al. Intramedullary tuberculoma: report of two MRI findings. *Surg Neurol* 1995;44:241–3.
- [15] Prakash ML, Sarwagi R, Ramkumar , et al. Spinal intramedullary tuberculoma: typical, atypical presentation on magnetic resonance imaging. *J Case Rep* 2013;3:404–9.
- [16] Rao GP. Spinal intramedullary tuberculous lesion: medical management. Report of four cases. *J Neurosurg* 2000;93:137–41.
- [17] Miyamoto J, Sasajima H, Owada K, et al. Spinal intramedullary tuberculoma requiring surgical treatment—case report. *Neurol Med Chir (Tokyo)* 2003;43:567–71.
- [18] Sonawane DV, Jagtap SA, Patil HG, et al. Intramedullary tuberculoma of dorsal spinal cord: a case report with review of literature. *J Orthop Case Rep* 2015;5:44–6.
- [19] Ju HB, Guo DM, Chen FF. Intramedullary cervical tuberculoma: a case report with note on surgical management. *Int Surg* 2015;100:133–6.