



## Case report

## Delayed presentation of massive haemoptysis from aortic aneurysm after aortic coarctation repair (a case report)

Yasser Farag Elghoneimy<sup>a,\*</sup>, Fahd Abdulrahman Makhdom<sup>a</sup>, Reem Shehab AlSulaiman<sup>b</sup>, Mohammed Ibrahim Alshaik<sup>b</sup>, Saud Abdulaziz AlShehri<sup>b</sup>

<sup>a</sup> Cardiac Surgery Unit, Surgery Department, College of Medicine, Imam Abdulrahman Bin Faisal, Saudi Arabia

<sup>b</sup> College of Medicine, Imam Abdulrahman Bin Faisal, Saudi Arabia

## ARTICLE INFO

## Keywords:

Thoracic aortic aneurysm  
Thoracic endovascular aortic repair  
Aortic coarctation  
Type B aortic dissection  
Carotid bypass

## ABSTRACT

**Introduction:** Massive haemoptysis refers to coughing and losing a huge amount of blood in a 24-hour period. It's a life-threatening condition with high mortality rate.

**Case presentation:** We report a rare case of massive haemoptysis in a 60-year-old female patient who had aortic coarctation repair 30 years ago. Her Computed tomography (CT) angiography showed huge aneurysmal dilatation and dissection of the descending thoracic aorta at the site of the repair. Thoracic endovascular aortic repair (TEVAR) was done, but the patient had recurrent massive haemoptysis due to extension of the aneurysm to the aortic arch. The patient then underwent one stage surgical right to left carotid artery shunt followed by TEVAR to the aortic arch covering the left common carotid artery. The procedure was successful, and haemoptysis was controlled without any complications.

**Discussion:** In this case the high index of suspicion for thoracic aortic aneurysm in patients presenting with haemoptysis and prior history of coarctation repair were demonstrated.

**Conclusion:** massive haemoptysis in patients who had aortic coarctation repair is an alarming sign, and surgical intervention is required. TEVAR has become one of the best approaches for managing aortic aneurysm and has replaced open repair.

### 1. Introduction

Aortic coarctation is a congenital cardiac disease in which the aorta narrows, most commonly in the left subclavian artery. It accounts for 5–8% of all congenital heart diseases [1]. Surgical repair of this condition can be done by several methods such as resection with end-to-end anastomosis, a bypass graft across the area of coarctation, and prosthetic patch aortoplasty. However, the problem with these techniques is having high incidence of aneurysm in a long run which can also result in massive haemoptysis [2,3].

Massive haemoptysis refers to coughing and losing a huge amount of blood in a 24-hour period, typically between 100 and 1000 ml. It's caused by high-pressure bronchial circulation in 95% of cases, and by ruptured aneurysms or Aortobronchial (AB) fistulae in the remaining 5% of cases. This condition usually arises as a complication of tuberculosis (TB), bronchiectasis and pulmonary carcinoma, while arises rarely as a

complication of ruptured Thoracic aortic aneurysm (TAA). The development of delayed haemoptysis in patients who have had an aortic coarctation repair raises the suspicion of an underlying TAA [4,5].

### 2. Case presentation

This patient is a 60-years-old Saudi smoker female who presented to the ER with massive haemoptysis (each attack up to 400 ml of fresh arterial blood) with severe anaemia due to blood loss that led to low haemoglobin reaching 5 g/dl.

The patient is a known case of type II diabetes (DM), hypertension (HTN) and dyslipidaemia on Metformin, Lisinopril, and statin. Furthermore, she had previous surgical repair of coarctation of the aorta by patch grafting 30 years ago in Riyadh which was successful. Computed tomography (CT) scan was ordered and showed a huge thoracic aneurysm at the site of previous surgical repair of the

**Abbreviations:** TTA, thoracic aortic aneurysm; TEVAR, thoracic endovascular aortic repair; ECG, electrocardiogram; CT, computed tomography; CHF, congestive heart failure; TB, tuberculosis; HTN, hypertension; DM, diabetes mellitus; AB fistula, aortobronchial fistula; CCU, Coronary Care Unit.

\* Corresponding author at: King Fahad University Hospital, Shura Street, Al Aqrabiyah, Al Khobar 34445, Saudi Arabia.

E-mail addresses: [yfarag@iau.edu.sa](mailto:yfarag@iau.edu.sa) (Y.F. Elghoneimy), [rsolaiman615@gmail.com](mailto:rsolaiman615@gmail.com) (R.S. AlSulaiman).

<https://doi.org/10.1016/j.ijscr.2021.106398>

Received 13 August 2021; Received in revised form 3 September 2021; Accepted 10 September 2021

Available online 13 September 2021

2210-2612/© 2021 The Authors. Published by Elsevier Ltd on behalf of IJS Publishing Group Ltd. This is an open access article under the CC BY-NC-ND license

(<http://creativecommons.org/licenses/by-nc-nd/4.0/>).

coarctation [Fig. 1]. The decision was to perform Thoracic endovascular aortic repair (TEVAR) percutaneously by the cardiac surgeon with insertion of 3 stents covering the left subclavian artery and sparing the left common carotid artery. The procedure was smooth, and the patient was transferred to the Coronary Care Unit (CCU) in a stable condition. CT angiography after the procedure and before discharge was done and showed no endoleak [Fig. 2].

The patient had no haemoptysis for 2 months after discharge and was doing well. However, after 2 months the patient was readmitted again with massive haemoptysis attack. On examination she was pale and sick, labs showed haemoglobin of 6.8 mg/dl and 2 units of blood were transfused to her. Fiberoptic bronchoscope was done and showed bleeding from left upper lobe. CT scan was repeated and showed expansion of the aortic arch aneurysm proximal to the stent and small area of dissection and type1 endoleak [Fig. 3]. Multidisciplinary team including interventional radiology, cardiothoracic surgery and internal medicine have decided to do another TEVAR for the aortic arch with coverage of the left common carotid artery. Utilizing cervical approach carotid- to-carotid bypass was done and then was followed by TEVAR. A stent was inserted in the aortic arch covering the left common carotid artery and the other one was inserted in the descending thoracic aorta. TEVAR was imported through the femoral cutdown [Fig. 4]. CXR after the procedure was done and showed successful Aortic arch repair [Fig. 5]. Two months later the patient was seen in the cardiac surgery clinic, and she was satisfied with the treatment plan. The overall outcome of the procedure showed high success rate.

**3. Discussion**

TAA occurs due to a weakness of the wall of the aorta. It's difficult to know the exact incidence and prevalence of this condition because it's

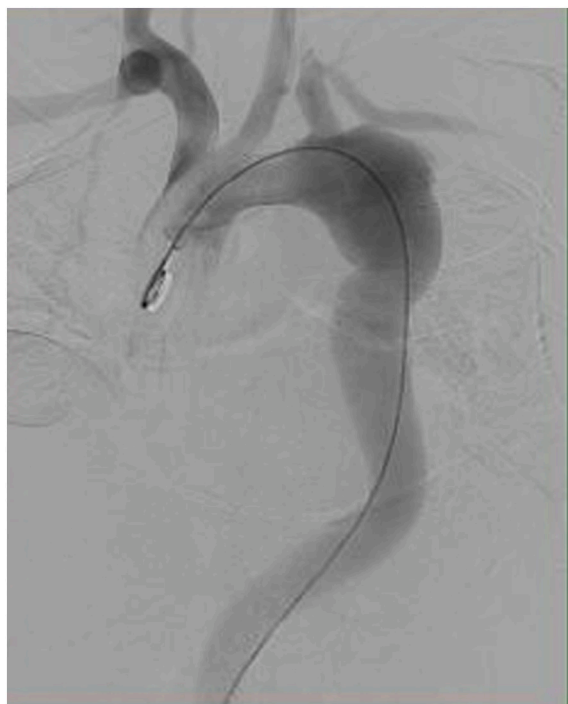

Fig. 2. Conventional aortography during TEVAR confirming the size and site of descending thoracic aortic aneurysm.

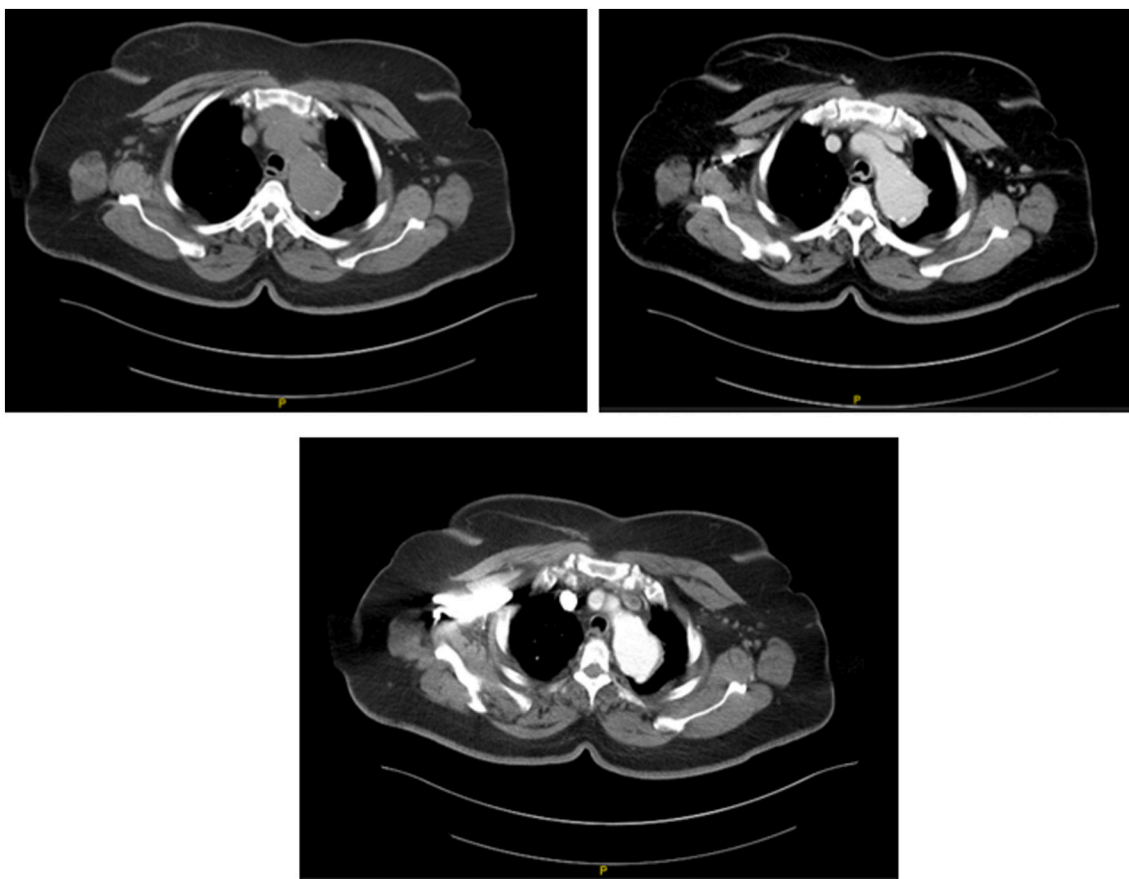
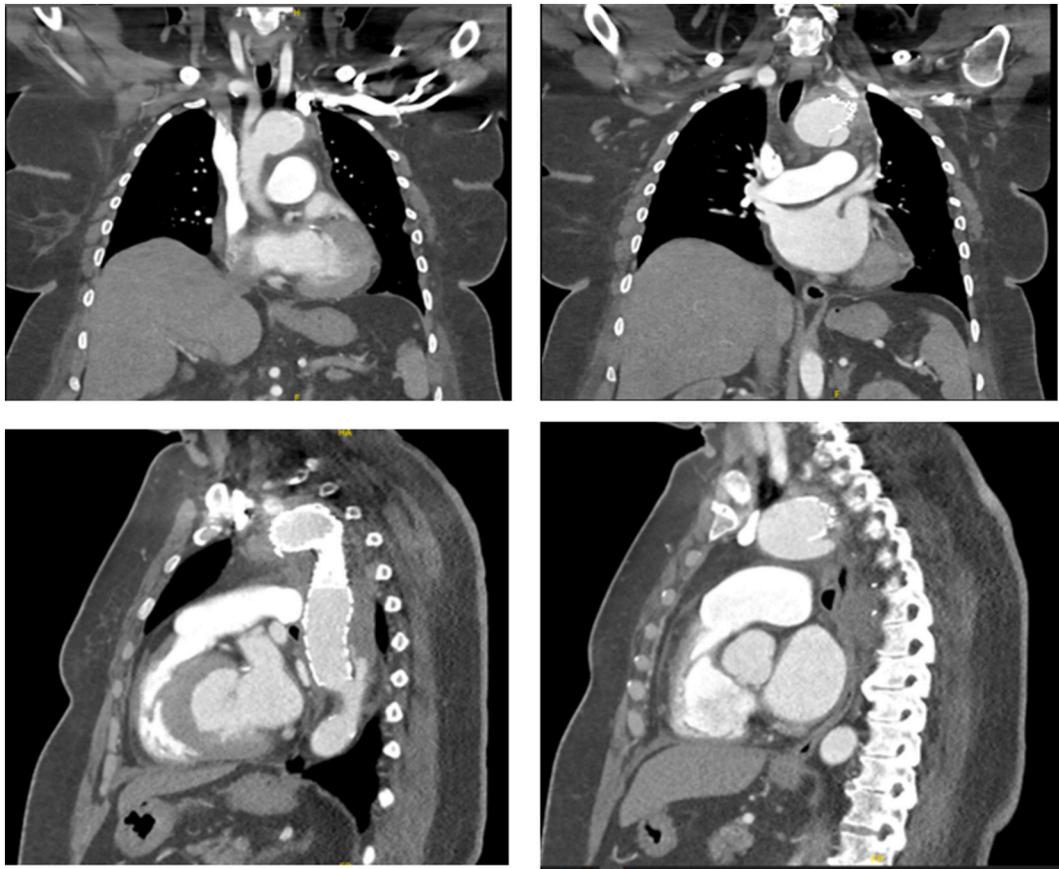
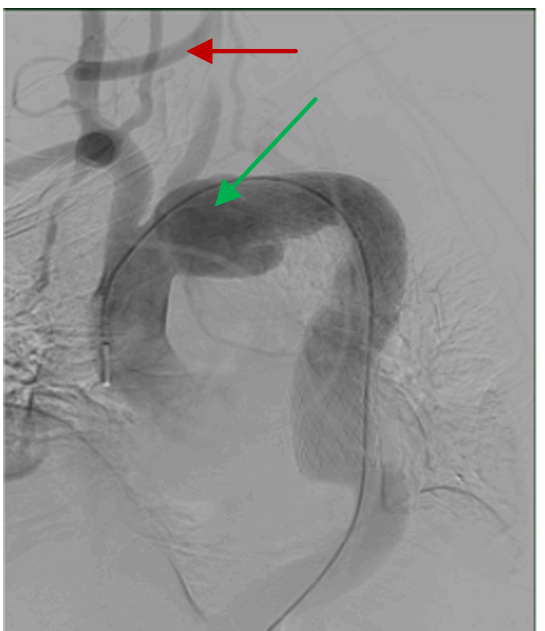
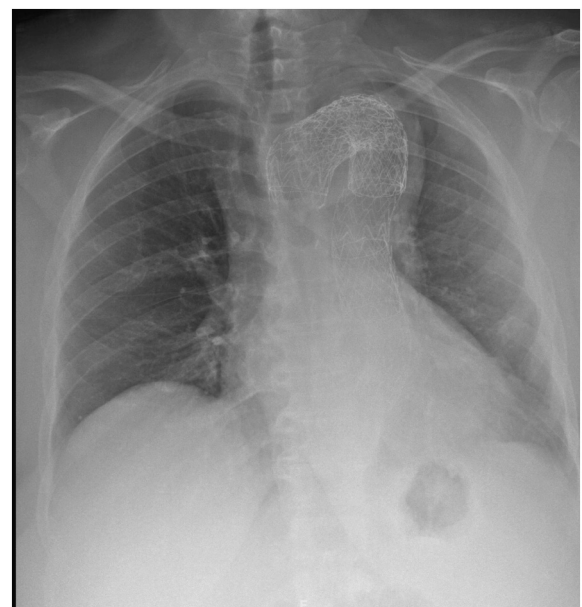
Fig. 1. Preoperative CT Angiography showing large descending thoracic aortic aneurysm after repair of aortic coarctation.



**Fig. 3.** Coronal and Sagittal views of CT angiography of the aorta showing expansion of aneurysm of the aortic arch 2 months after TEVAR.



**Fig. 4.** Intraoperative aortography showing patent right to left carotid shunt (Red arrow) and large aortic arch aneurysm and leak (green arrow). (For interpretation of the references to colour in this figure legend, the reader is referred to the web version of this article.)



**Fig. 5.** Chest X-ray PA, Post TEVAR showing successful stent deployment.

considered a silent disease. As this condition develops slowly many patients with TAA are asymptomatic. However, they can complain of chest pain, back pain, and difficulty breathing [6]. In our case the patient only had chest pain and on the second episode she had back pain post TEVAR.

Most cases of TAA are degenerative and occur in association with

atherosclerosis risk factors such as smoking, HTN which accounts for 60% of TAA and dyslipidaemia [6]. In our case the patient has HTN and dyslipidaemia as a risk factor.

These aneurysms can lead to major complications such as aortic dissection or rupture if not treated effectively. A contrast-enhanced CT angiography is the most used modality to diagnose TTA, however, in acute conditions CT scan is preferred. In these patients' surgery may be done to prevent dissection or rupture of the aneurysm [7].

Haemoptysis is a rare complication of TAA. It usually occurs after a formation of an AB fistula or ruptured aneurysm. Massive haemoptysis in these cases can be fatal if not treated surgically resulting in asphyxia from airway obstruction which accounts for a mortality rate of 30–70% [8]. In our case the patient developed haemoptysis first as a delayed complication of aortic coarctation repair, and the second time was 2 months Post TEVAR.

A limited number of studies have studied the presentation of massive haemoptysis in patients with prior coarctation of aorta repair. In 2015 a case report was written on a 46-year-old male who presented to the emergency with massive haemoptysis for several months. The patient had previously undergone aortic coarctation surgery at the age of 17. Endoscopy was done and it showed no evidence of bleeding, however, the CT scan demonstrated a large thoracic aortic pseudoaneurysm with a formation of an AB fistula. So, this case shows us that massive haemoptysis can raise a high suspicion of AB fistula especially in patient with prior coarctation of aorta repair [9].

In 2006, a 14-year cohort study at a Paris tertiary university hospital was done to evaluate the causes of significant haemoptysis in 1087 individuals. Bronchitis (20%), cryptogenic (18%), cancer (17%), active tuberculosis (12%), and tuberculosis sequelae (13%) were the most common causes of major haemoptysis in that patient population, according to the findings [10]. In our case the patient had massive haemoptysis due to TAA which is considered rare.

Diagnosis of massive haemoptysis must be done as soon as possible because it's a life-threatening condition. Chest radiography is the first modality done to see if there are any abnormalities. A flexible bronchoscopy and high-resolution CT are done to see the site of bleeding [10]. In our patient fiberoptic bronchoscope was done and showed bleeding from left upper lobe, and CT scan was repeated and showed expansion of the aortic arch proximal to the stent and small area of dissection and type 1 endoleak.

The first step in managing massive haemoptysis is to secure the airway and stabilize the patient condition then determine the cause of this condition. Angiography and fixing aortic aneurysm by TEVAR are other options after stabilization and they're both diagnostic and therapeutic [11].

Previously, open repair was the management approach for thoracic aortic diseases. However, it can be associated with high rate of mortality, paraplegia, and renal damage. TEVAR has become one of the best approaches for managing thoracic aortic pathology and in 2005 the FDA have approved the use of TEVAR for TAA. The use of stent grafts for thoracic aortic disease has increased dramatically especially high-risk patients [6], [7]. In our patient, TEVAR was done and insertion of 3 stents covering the left subclavian artery and sparing the left common carotid artery was done.

One of the commonest complications of TEVAR is endoleaks, which are defined as ongoing leakage of blood within the aneurysm sac, and can present in 20–40% of patients. Endoleaks are divided into five categories based on the site, cause, and pathophysiology (from I to V) [12]. In our case, the patient had type I endoleak, which is caused by an insufficient seal at the graft attachment site. This type doesn't resolve spontaneously and thus considered significant.

#### 4. Conclusion

In conclusion, massive haemoptysis in patients who underwent aortic coarctation repair is an alarming sign, and surgical intervention is

required. TEVAR has become one of the best approaches for managing aortic aneurysm and has replaced open repair.

#### Method

The work has been reported in line with the SCARE 2020 criteria [13].

#### Provenance and peer review

Not commissioned, externally peer-reviewed.

#### Funding

The authors deny any source of funding in this project.

#### Consent

Written informed consent was obtained from the patient for publication of this case report and accompanying images. A copy of the written consent is available for review by the Editor-in-Chief of this journal on request.

#### Ethical approval

No Ethical approval was needed because it's a case report and only informed consent was obtained from the patient.

#### Author contribution

Yasser Elghoneimy: Treating consultant, main author, writing the manuscript and preparing the images.

Fahd Makhdom: reviewing the literature and manuscript.

Reem Shehab AlSulaiman: writing the manuscript and data collection.

Mohammed Ibrahim Alshaiikh: writing the manuscript and data collection.

Saud Abdulaziz AlShehri: writing the manuscript and data collection.

#### Registration of research studies

Not applicable.

#### Guarantor

Dr. Yasser Elghoneimy.

#### Declaration of competing interest

The authors report no declaration of interest.

#### References

- [1] R. Torok, Coarctation of the aorta: management from infancy to adulthood, Available from: World J. Cardiol. 7 (11) (2015) 765 <https://www.ncbi.nlm.nih.gov/pmc/articles/PMC4660471/>.
- [2] S. Patnana, Coarctation of the Aorta: Background, Pathophysiology, Prognosis [cited 25 June 2021]. Available from: Emedicine.medscape.com, 2021 <https://emedicine.medscape.com/article/895502-overview>.
- [3] P. Agasthi, S. Pujari, A. Tseng, J. Graziano, F. Marcotte, D. Majdalany, Management of adults with coarctation of aorta, Available from: World J. Cardiol. 12 (5) (2020) 167–191 <https://www.ncbi.nlm.nih.gov/pmc/articles/PMC7284000/>.
- [4] C. Radchenko, A. Alraiyes, S. Shojae, A systematic approach to the management of massive hemoptysis, S1069-S1086. Available from: J. Thorac. Dis. 9 (S10) (2017) <https://www.ncbi.nlm.nih.gov/pmc/articles/PMC5696556/>.
- [5] E. Sueyoshi, H. Koike, I. Sakamoto, M. Uetani, Successful treatment of hemoptysis caused by a type 2 endoleak after thoracic endovascular aortic repair, Available from: CVIR Endovasc. (1) (2018) <https://www.ncbi.nlm.nih.gov/pmc/articles/PMC6319520/>.

- [6] J. Black, C. Burke, Epidemiology, risk factors, pathogenesis, and natural history of thoracic aortic aneurysm and dissection [cited 26 June 2021]. Available from: Uptodate.com, 2021 <https://www.uptodate.com/contents/epidemiology-risk-factors-pathogenesis-and-natural-history-of-thoracic-aortic-aneurysm-and-dissection>.
- [7] Z. Faiza, T. Sharman, Thoracic aorta aneurysm [cited 25 June 2021]. Available from: Ncbi.nlm.nih.gov, 2021 <https://www.ncbi.nlm.nih.gov/books/NBK554567/>.
- [8] L. Rodríguez-Hidalgo, L. Concepción-Urteaga, J. Santos Hilario-Vargas, D. Ruiz-Caballero, Hemoptysis as a warning sign of thoracic aorta pseudoaneurysm: a case report, Available from: Medwave 21 (01) (2021), e8112-e8112 <https://www.medwave.cl/link.cgi/English/Original/CaseReport/8113.act>.
- [9] V. Kansal, S. Nagpal, Delayed diagnosis of hemoptysis in the case of prior aortic coarctation repair: a case report of aortobronchial fistula, Available from: Respir. Med. Case. Rep. 16 (2015) 51–53 <https://www.ncbi.nlm.nih.gov/pmc/articles/PMC4681956/>.
- [10] R. Cordovilla, E. Bollo de Miguel, A. Nuñez Ares, F. Cosano Povedano, I. Herráez Ortega, R. Jiménez Merchán, Diagnosis and treatment of hemoptysis, Available from: Arch. Bronconeumol. 52 (7) (2016) 368–377 <https://www.sciencedirect.com/science/article/abs/pii/S1579212916300568?via%3Dihub>.
- [11] H. Kathuria, H. Hollingsworth, R. Vilvendhan, C. Reardon, Management of life-threatening hemoptysis, Available from: J. Intensive Care 8 (1) (2020) <https://jintensivecare.biomedcentral.com/articles/10.1186/s40560-020-00441-8>.
- [12] D. Souza, Endoleak | Radiology reference article [cited 31 July 2021]. Available from: Radiopaedia.org. Radiopaedia.org, 2021 <https://radiopaedia.org/articles/endoleak>.
- [13] for the SCARE Group, R.A. Agha, T. Franchi, C. Sohrabi, G. Mathew, The SCARE 2020 guideline: updating consensus Surgical CASE REport (SCARE) guidelines, Int. J. Surg. 84 (2020) 226–230.