



Original Article

Incidence and predictors of forearm hematoma during the transradial approach for percutaneous coronary interventions



Naveen Garg*, Koneru Lakshmi Umamaheswar, Aditya Kapoor, Satendra Tewari, Roopali Khanna, Sudeep Kumar, Pravin Kumar Goel

Department of Cardiology, Sanjay Gandhi Post Graduate Institute of Medical Sciences, Lucknow, India

ARTICLE INFO

Article history:

Received 9 November 2018

Accepted 29 April 2019

Available online 3 May 2019

Keywords:

Transradial angioplasty

Forearm hematoma

Percutaneous coronary intervention

Vascular access

ABSTRACT

Background: The transradial approach for percutaneous coronary intervention (TRA-PCI) reduces vascular complications compared with the transfemoral approach (TFA). Although hematoma formation is less frequent with the TRA than TFA, it is not uncommon, and its presentation ranges from mild hematoma to compartment syndrome. Incidence and predictors of hematoma have not been well studied.

Methods and results: The present study was conducted to prospectively evaluate the incidence and predictors of forearm hematoma after TRA-PCI. The study population consisted of consecutive patients undergoing TRA-PCI. Baseline and procedural characteristics and clinical outcomes were prospectively collected. All patients were observed for forearm/arm hematoma immediately after procedure, after band removal, before discharge, and whenever the patient complained of pain/swelling in the limb. Logistic regression analysis was performed to determine the predictors for hematoma formation. A total of 520 patients who had successfully completed TRA-PCI were included in the final analysis. The mean age was 55.2 ± 9.5 years, and 24% patients were women. Hematoma occurred in 53 (10.2%) patients. Hematomas were of grade I, II, III, and IV in 22 (4.2%), 9 (1.7%), 18 (3.5%), and 4 (0.8%) patients, respectively. On multivariate logistic regression analysis, age, body mass index, multiple puncture attempt, glycoprotein IIb/IIIa receptor blocker use, nonclopidogrel agent use for dual antiplatelet therapy, and multiple catheter exchanges emerged as independent predictors for hematoma formation.

Conclusions: Forearm hematoma following TRA-PCI occurs in about 10% patients. Most hematomas occur near the puncture area. The independent predictors for hematoma formation are age, body mass index, multiple puncture attempts, intensive antiplatelet therapy, and multiple catheter exchanges.

© 2019 Cardiological Society of India. Published by Elsevier B.V. This is an open access article under the CC BY-NC-ND license (<http://creativecommons.org/licenses/by-nc-nd/4.0/>).

What is known

- Forearm hematoma can occur after transradial coronary angioplasty, is the main reason of patient discomfort and sometimes can lead to the development of compartment syndrome.

What the study adds

- Forearm hematoma occurs in about 10% patients after transradial coronary angioplasty.

- Most hematomas occur at the access site and are associated with multiple puncture attempts.
- Non-access site hematomas are uncommon and are associated with intensive antiplatelet therapy and multiple catheter exchanges.
- The independent predictors for hematoma formation are age, body mass index, multiple puncture attempt, intensive antiplatelet therapy (nonclopidogrel agent use for dual antiplatelet therapy and/or glycoprotein IIb/IIIa receptor blocker use), and multiple catheter exchanges.

1. Introduction

The transradial approach for percutaneous coronary intervention (TRA-PCI) has fewer vascular complications, especially

* Corresponding author. Department of Cardiology, Sanjay Gandhi PGIMS, Raibareli Road, Lucknow, India. Fax: +91 0522 2668017.

E-mail addresses: navgarg@gmail.com, navgarg@sgpgi.ac.in (N. Garg).

bleeding complications, compared with the transfemoral approach (TFA).^{1–4} It has become increasingly popular as a better alternative access site in comparison with the TFA because of fewer access site–related complications, early patient mobilization, shorter hospital stay, reduced procedural cost, and near absence of clinically significant complications.^{5–7} Although hematoma is less frequent after the TRA than TFA, it is not uncommon, and its presentation ranges from mild hematoma to compartment syndrome.^{8–10} To the best of our knowledge, there is no large trial or multicenter registry evaluating the forearm hematoma per se, so it is difficult to ascertain their exact incidence and predictors. Some studies have reported an incidence varying from 0.04% to 14.4%.^{8,9} But most of these studies have included a mixed patient population of TRA-PCI and diagnostic transradial coronary angiography. Until now, none of the studies has studied forearm hematoma exclusively in patients undergoing TRA-PCI. Considering the limited data on forearm hematoma after TRA-PCI, this study was undertaken to prospectively evaluate the true incidence, predictors, and outcome of forearm hematoma after TRA-PCI.

2. Materials and methods

2.1. Study population

Consecutive patients who were taken up for ad hoc PCI at our tertiary care referral center over the last one year were prospectively recruited in the study. Only patients who underwent successful PCI through the TRA were included. Patients with negative Allen's test were excluded from the study. Patients with a prior history of transradial procedures complicated with hematoma formation were excluded. Patients not proceeding to PCI (patients with mild/no coronary artery disease and patients advised for coronary artery bypass surgery) were excluded. Patients who were switched over to transfemoral access were also excluded. Human subjects were given informed consent, and the authors have conformed to institutional guidelines and those of the American Physiological Society.

Data on demographics, medical history, and procedural characteristics were recorded for every patient. The routine hemogram and renal function test were carried out and blood sugar levels were measured in all patients. The left ventricular ejection fraction (LVEF) was measured by echocardiography in all patients. Clinical radial artery patency was assessed by radial pulse examination. All procedures were performed by operators experienced with radial interventions.

2.2. Transradial angioplasty

The access site was anesthetized with lidocaine, and then, radial arterial access was taken using a 6F radial sheath (Radifocus introducer II; Terumo, Japan). To prevent vasospasm and thromboembolic events, a preprepared mixture of nitroglycerine (100 µg), verapamil (5 mg), and xylocaine (100 µg) along with 100 units/kg heparin was injected into the radial artery sheath. Glycoprotein IIb/IIIa (Gp IIb/IIIa) receptor blockers were administered at the discretion of the operating physician.

Immediately after the procedure, the radial artery sheath was removed, and hemostasis was achieved by application of the TR band (Terumo, Japan) using patent hemostasis technique.¹¹ Patency of the radial artery was assessed using pulse oximetry by documenting the presence of pulsatile plethysmography signals from the index finger while manually compressing the ipsilateral ulnar artery. After about 15 min of the TR band placement, patency of the radial artery was again assessed. If not present; then TR band was slightly deflated until the plethysmography signal returned to restore radial patency. After 4 h of continuous compression, the

band was gradually deflated and then removed, and a light dressing was applied. Patent hemostasis was again confirmed. The light-pressure bandage was removed after about 8 h. All patients were encouraged to squeeze and release the hand and to keep the arm in an elevated position during the whole compression period.

Procedural details such as puncture attempts, number of catheter exchanges, angiographic severity of coronary artery disease, number of vessels stented, and total number of stents used in each patient were noted. The complexity of lesions demanding prolonged radial cannulation time or use of multiple hardware uses (e.g., bifurcation lesions, chronic total occlusions, aorto-ostial lesions, lesions involving left anterior descending artery (LAD), or left circumflex artery (LCX) ostia) was noted. PCI performed in any of such lesions was considered as complex PCI. Total fluoroscopy time and radiation dose were also noted for each patient.

2.3. Observations for hematoma

All patients were observed for forearm/arm hematoma immediately after procedure, after band removal, on the next day of the procedure, and whenever the patient complained of pain and swelling in the limb. Local hematoma was graded using the EASY (Early Discharge After Transradial Stenting of Coronary Arteries Study) hematoma scale: grade I, <5 cm in diameter (nonsignificant); grade II, 5–10-cm diameter (mild); grade III, >10 cm but distal to the elbow (moderate); grade IV, extending above the elbow (severe); and grade V, anywhere with ischemic threat to the hand (compartment syndrome).¹² Grade I and II hematomas were managed with analgesia, loose compression dressing, gentle elevation of the arm, and careful observation. Grade III and IV hematomas were managed by stopping any ongoing antithrombotic agents and external compression using an elastic bandage.

2.4. Statistical analysis

All data were prospectively collected and entered. Patients who developed forearm hematoma were compared with patients who did not develop hematoma. Dichotomous variables were reported as numbers and proportions. Continuous variables were presented as mean ± standard deviation. Student's *t* test was used to compare each continuous variable, whereas the chi-square test was applied to the categorical values. Potential risk factors for hematoma were investigated first by univariate logistic regression analysis. A multivariate logistic regression model with all significant variables was established to estimate odds ratio and inclusive 95% confidence bounds. All tests were performed as 2-sided at the significance level of a *p* value of <0.05. For further subanalysis, we divided all our patients who developed hematomas into two groups; access site–related forearm hematomas (forearm hematoma grade I and II) and non–access site–related forearm hematoma (forearm hematoma grade > II). We then compared the baseline and procedural characteristics in these two groups. To evaluate the predictors for the development of non–access site hematoma, the patients who developed hematomas of >grade II were compared with the rest of the study population. All statistical analyses were performed using SPSS version 20.0 (SPSS, Inc). The corresponding author has full access to all the data in the study and takes responsibility for the integrity of the data and the data analysis.

3. Results

3.1. Baseline characteristics

A total of 1200 consecutive patients undergoing PCI or ad hoc PCI were prospectively screened, and 520 patients who had

completed a successful TRA-PCI were included in the final analysis (Fig. 1). Baseline characteristics are presented in Table 1. The mean age of the patients was 55.2 ± 9.5 years; most patients (76.0%) were men, and the mean body mass index (BMI) was 25.7 ± 3.2 kg/m². About one-third of the patients were diabetic (33.3%), and about half of the patients were hypertensive (44.2%). Nearly, one-third of our patients had stable angina, while the rest had acute coronary syndrome. About one-fifth of our patients had double- or triple-vessel disease. Only 7.9% patients had an LVEF of <40%. All patients have received aspirin, clopidogrel/prasugrel/ticagrelor, and a statin. A history of prior radial artery cannulation was present in nearly one-fifth of the cases. Most patients with the history of prior radial artery cannulation underwent coronary angiography at other centers and were referred to our institute for further management. A total of 28 patients underwent transfemoral PCI during the study period (Fig. 1). Their mean age was 55.9 ± 8.9 years; 75.0% were men, and the mean BMI was 25.5 ± 2.2 kg/m².

3.2. Procedural characteristics

Procedural characteristics are presented in Table 1. A radial sheath of 6F size was used in all patients. Most patients underwent single-vessel angioplasty (79.6%), and one-fifth of the patients had double- or triple-vessel stenting. Complex PCI was carried out in about one-third of the patients. Gp IIb/IIIa antagonists were used in 38.7% of the patients. The mean fluoroscopy time was 15.4 ± 7.9 min. The mean radiation dose was 2.6 ± 1.4 Gy. Nearly, one-fifth of the patients had undergone more than 1 puncture attempt (22.6%), and catheter exchange of >3 times was noted in nearly one-third (34.2%) of the patients.

3.3. Forearm hematoma formation

The incidence of forearm hematoma formation in our study population was 10.2% (53 patients) with 22 (4.2%), 9 (1.7%), 18 (3.5%), and 4 (0.8%) patients having grade I, grade II, grade III, and

grade IV hematoma, respectively (Fig. 2). None of our patients developed compartment syndrome (grade V hematoma). In all the 4 patients with grade IV hematoma, hematoma was extended to the arm from the forearm. None of our patients developed hematoma restricted to the arm only. Hematomas were access site related (grade I and II) in 31 (5.9%) patients, whereas 22 (4.2%) patients developed non-access site-related hematomas (grade III and IV). All these hematomas were successfully managed with manual bandage compression without any untoward consequence and without the need for blood transfusion. The patients who developed hematoma were of significantly higher age, lower weight, lower height, and lower BMI than those patients who did not develop hematoma. Multiple puncture attempts, catheter exchange >3, nonclopidogrel agent use for dual antiplatelet therapy (DAPT), and Gp IIb/IIIa blocker use were significantly more in patients who developed forearm hematoma (Table 1).

3.4. Predictors of forearm hematoma formation

Univariate and multivariate logistic regression analysis for the predictors of forearm hematoma formation is presented in Table 2. On univariate analysis, the predictors for hematoma formation were older age, low body weight, lower height, lower BMI, non-clopidogrel agent use for DAPT, Gp IIb/IIIa blocker use, radial artery puncture attempts >1 time, and catheter exchange >3 times. On multivariate logistic regression analysis; older age, low BMI, >1 puncture attempt, catheter exchange >3 times, nonclopidogrel agent use for DAPT, and Gp IIb/IIIa blocker use have emerged as independent predictors for hematoma formation.

3.5. Access site vs. non-access site forearm hematoma

Comparison of access site-related vs. non-access site-related forearm hematoma is presented in Table 3. Radial artery puncture attempts of >1 time were significantly more common in patients with access site-related forearm hematoma, whereas catheter

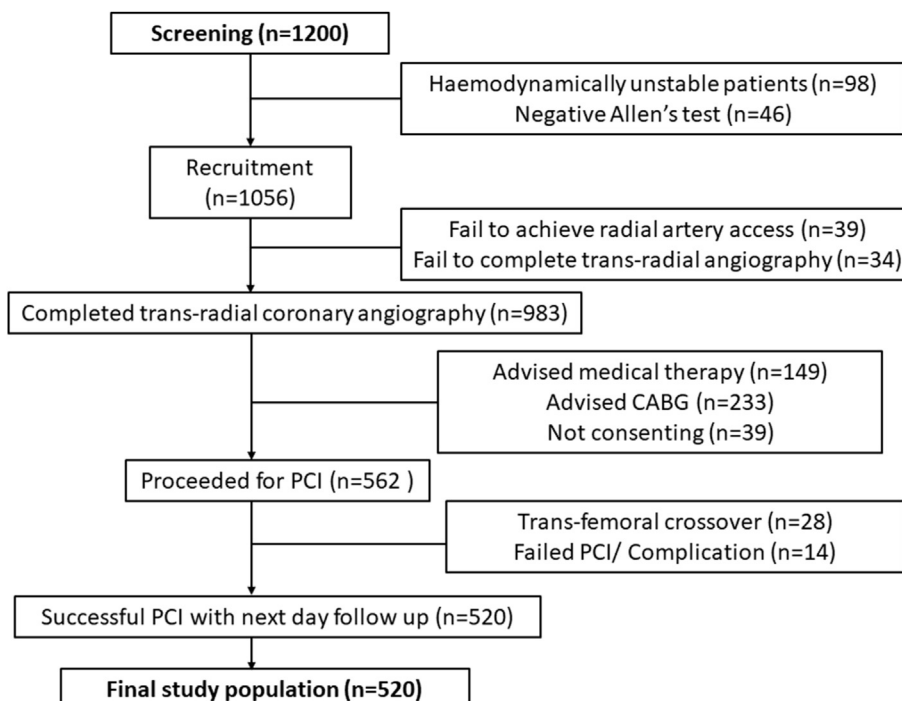


Fig. 1. Study flow chart. PCI, percutaneous coronary intervention. CABG, coronary artery bypass surgery.

Table 1
Baseline and procedural characteristics (n = 520).

Variables	All patients (n = 520)	No forearm hematoma (n = 467)	With forearm hematoma (n = 53)	p value
Age (years)	55.2 ± 9.5	54.9 ± 9.4	58.6 ± 9.5	<0.01
Female gender	125 (24.0%)	107 (22.9%)	18 (34.6%)	0.07
Weight (kg)	67.7 ± 10.9	68.5 ± 10.5	61.1 ± 12.9	0.01
Height (cm)	162.1 ± 8.4	162.4 ± 8.2	159.3 ± 9.7	0.01
BMI (kg/m ²)	25.7 ± 3.2	25.9 ± 3.0	23.9 ± 3.7	0.01
Diabetes	173 (33.3%)	161 (34.5%)	12 (22.6%)	0.08
Hypertension	230 (44.2%)	210 (45.0%)	20 (37.7%)	0.32
Smoking	339 (65.2%)	304 (65.1%)	35 (66.0%)	0.89
Dyslipidemia	133 (25.6%)	123 (26.3%)	10 (18.9%)	0.24
Presentation with ACS	365 (70.2%)	333 (71.3%)	32 (60.4%)	0.10
Ejection fraction <40%	41 (7.9%)	37 (7.9%)	4 (7.5%)	0.92
Peripheral artery disease	42 (8.1%)	40 (8.6%)	2 (3.8%)	0.24
Prior radial artery cannulation	98 (18.8%)	86 (18.4%)	12 (22.6%)	0.50
Radial artery puncture attempts >1	116 (22.6%)	87 (18.6%)	29 (54.7%)	0.01
Catheter exchange >3	178 (34.2%)	141 (30.2%)	37 (69.8%)	0.01
Multivessel stenting	106 (20.6%)	91 (19.5%)	15 (28.3%)	0.13
Complex angioplasty	167 (32.1%)	144 (30.8%)	23 (43.6%)	0.06
Number of stents/patient	1.4 ± 0.6	1.4 ± 0.7	1.55 ± 0.7	0.20
Nonclopidogrel DAPT	111 (22.3%)	87 (18.6%)	24 (45.3%)	0.01
Glycoprotein inhibitor use	201 (38.7%)	171 (36.6%)	30 (56.6%)	<0.01
Fluoroscopy time (min)	15.4 ± 7.9	15.2 ± 7.4	16.9 ± 11.9	0.15
Radiation dose (Gy)	2.6 ± 1.4	2.5 ± 1.4	2.7 ± 1.3	0.42

BMI, body mass index; ACS, acute coronary syndrome; DAPT, dual antiplatelet therapy.

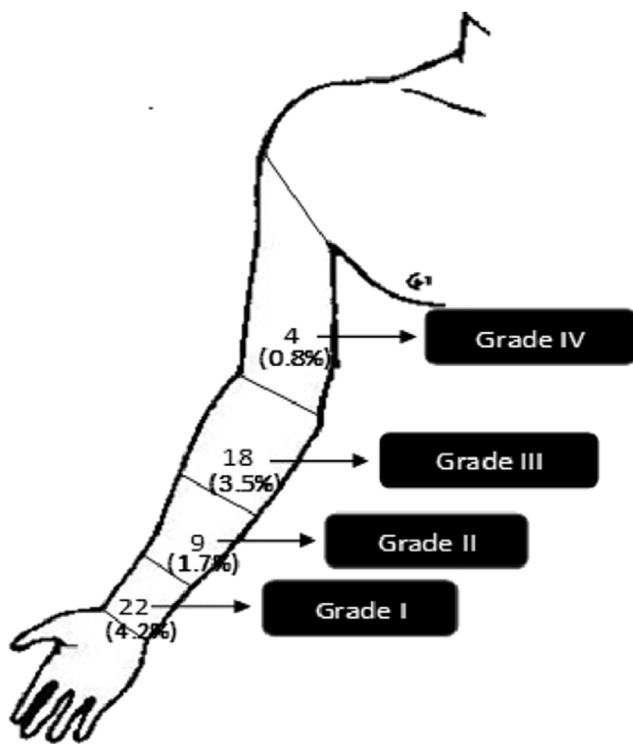


Fig. 2. EASY (Early Discharge After Transradial Stenting of Coronary Arteries Study) hematoma grading.

exchange of >3 times, complex angioplasty procedures, Gp IIb/IIIa blocker use, and nonclopidogrel agent use for DAPT were significantly more common in patients who developed non-access site-related forearm hematoma.

3.6. Predictors for the development of non-access site hematoma

Univariate and multivariate logistic regression analysis for the predictors of development of non-access site forearm hematoma

formation is presented in Table 4. On univariate analysis, low body weight, low BMI, nonclopidogrel agent use for DAPT, Gp IIb/IIIa blocker use, catheter exchange >3 times, and complex angioplasty procedures were the predictors for development of non-access site hematoma. On multivariate logistic regression analysis, Gp IIb/IIIa blocker use, nonclopidogrel agent use for DAPT, catheter exchange >3 times, and complex angioplasty procedures have emerged as the independent predictors (Table 4).

4. Discussion

The present study has shown that forearm hematomas occur in about 10% of patients undergoing TRA-PCI. Most hematomas occur near the puncture area (grade I and II) and are related to access site-related issues. Only about 4% patients develop hematoma in the proximal forearm and arm (grade III and IV), and the hematomas are related to low BMI, more intensive antiplatelet therapy, and multiple catheter exchanges. All these hematomas can be successfully managed with manual bandage compression without any untoward consequence or need for blood transfusion. To the best of our knowledge, this is probably the first study of its kind that has systematically studied the incidence and predictors of hematoma after TRA-PCI. Ours is the only study conducted exclusively in patients who underwent successful TRA-PCI, thus depicting the true incidence of forearm hematoma after TRA-PCI.

In our study, the overall incidence of hematoma was 10.2%, which is in accordance with the study by Bertrand¹³ who have reported an incidence of 9.5% using the similar bleeding and hematoma scale as used in our study. In previous studies, forearm hematomas have been reported in 0.04–14.4% patients.^{8,9} This wide variation is probably due to hematoma definition used, reporting of only a particular grade of hematoma, experience of the operator, radial volume of the center, frequency of use of non-clopidogrel drugs for DAPT, and Gp IIb/IIIa blocker usage.

Access site hematomas are generally noticed only after the removal of the arterial introducer sheath and occur because of proximal extension of bleeding from the access site. It is usually related to multiple puncture attempts and/or inadequate hemostasis because of improper TR band application or excessive anticoagulation. In the present study, multiple radial artery puncture

Table 2
Predictors of hematoma formation (n = 520).

Variables	OR (95% CI)	p value (univariate)	p value (multivariate)
Age	1.0 (1.0–1.1)	<0.01	0.04
Female gender	1.7 (0.9–3.2)	0.07	0.40
Weight	0.9 (0.9–1.0)	<0.01	0.72
Height	1.0 (0.9–1.0)	0.01	0.52
BMI	0.8 (0.7–0.9)	<0.01	<0.01
Diabetes	1.8 (0.9–3.5)	0.08	0.11
Hypertension	1.3 (0.7–2.4)	0.316	–
Smoking	1.0 (0.6–1.9)	0.89	–
Dyslipidemia	1.5 (0.7–3.1)	0.24	–
Peripheral artery disease	2.4 (0.6–10.2)	0.24	–
Presentation with ACS	1.6 (0.9–2.9)	0.10	–
LVEF <40%	1.0 (0.4–3.0)	0.90	–
Prior radial artery cannulation	1.3 (0.6–2.5)	0.50	–
Radial artery puncture attempts >1	5.2 (3.0–9.5)	<0.01	<0.01
Catheter exchange >3	5.3 (2.8–9.9)	<0.01	<0.01
Multivessel stenting	1.6 (0.9–3.1)	0.13	–
Complex angioplasty procedure	1.7 (0.9–3.1)	0.06	0.27
Nonclopidogrel DAPT	3.6 (2.0–6.5)	<0.01	<0.01
Glycoprotein inhibitor use	2.2 (1.4–4.0)	<0.01	<0.01
Fluoroscopy time	1.0 (0.9–1.1)	0.15	–
Radiation dose	1.1 (0.9–1.3)	0.42	–

CI, confidence interval; OR, odds ratio; BMI, body mass index; ACS, acute coronary syndrome; LVEF, left ventricular ejection fraction; DAPT, dual antiplatelet therapy.

Table 3
Comparison of patients with access site vs. non-access site hematoma (n = 53).

Variables	Access site hematoma (n = 31)	Non-access site hematoma (n = 22)	p value
Age (years)	58.8 ± 10.9	58.4 ± 7.4	0.90
Female gender	13 (61.3%)	5 (72.7%)	0.15
Weight (kg)	61.3 ± 14.3	60.8 ± 10.8	0.90
Height (cm)	159.5 ± 10.5	159.0 ± 8.6	0.80
BMI (kg/m ²)	23.9 ± 4.0	24.0 ± 3.4	0.90
Diabetes	5 (16.1%)	7 (31.8%)	0.18
Hypertension	12 (37.7%)	8 (36.4%)	0.90
Smoking	19 (61.3%)	16 (72.7%)	0.40
Dyslipidemia	5 (16.1%)	5 (22.7%)	0.55
Peripheral artery disease	1 (3.2%)	1 (4.5%)	0.80
Presentation with ACS	18 (58.1%)	14 (63.6%)	0.70
Ejection fraction <40%	3 (9.7%)	1 (4.5%)	0.50
Prior radial artery cannulation	6 (19.4%)	6 (27.3%)	0.50
Radial artery puncture attempts >1	22 (71.0%)	7 (31.8%)	<0.01
Catheter exchange >3	18 (58.1%)	19 (86.4%)	0.03
Multivessel stenting	8 (25.8%)	7 (31.8%)	0.63
Complex angioplasty procedure	10 (32.3%)	13 (59.1%)	0.05
Average number of stents/patient	1.5 ± 0.6	1.6 ± 0.8	0.70
Nonclopidogrel DAPT	9 (29.0%)	15 (68.2%)	<0.01
Glycoprotein inhibitor use	17 (41.9%)	13 (77.3%)	0.01
Fluoroscopy time	15.9 ± 10.9	18.3 ± 14.3	0.84
Radiation dose	2.7 ± 1.4	2.7 ± 1.3	0.42

BMI, body mass index; ACS, acute coronary syndrome; DAPT, dual antiplatelet therapy.

attempts were significantly associated with the development of access site hematomas. Indeed, about two-third of the patients who have >1 puncture attempt actually developed hematoma near the radial artery puncture site.

Non-access site forearm hematoma occurs because of the perforation of either the radial artery or its small branches. Perforation of the radial artery during TRA-PCI usually occurs because of vessel wall injury induced by either the introducer sheath or guide catheter due to the “razor blade effect.”¹⁴ It is usually related to impedance to sheath/catheter entry into the radial artery and may occur because of either radial artery spasm, excessive tortuosity of the radial artery, radial artery loop, or atherosclerotic disease in the radial artery or small-caliber radial artery (sheath/artery size ratios >1). Radial artery perforation usually produces progressive hematomas, if not treated urgently. Another possible mechanism for the development of forearm hematoma is the perforation of a radial

artery side branch. Unlike the femoral artery, the radial artery has multiple small side branches, and if the wire (especially, hydrophilic wire) is aggressively advanced into a side branch, it can result in its perforation. It usually produces self-limiting small forearm hematomas, but the clinical consequences may be more significant if the side branch is large or the antiplatelet or anticoagulation therapy is aggressive.

Our findings suggested that low BMI, nonclopidogrel agent use for DAPT, Gp IIb/IIIa blocker use, and multiple catheter exchanges are the independent predictors for non-access site forearm hematoma formation. Patients with low BMI usually have small-caliber radial arteries, and this may result in difficult manipulation of hardware that may result in radial artery perforation, leading to forearm hematoma formation. Similarly, multiple catheter exchanges can lead to vessel wall injury because of the “razor blade effect,” leading to non-access site hematoma formation. More

Table 4

Predictors of non-access site hematoma formation (n = 520).

Variable	Odds ratio (95% CI)	p value (univariate)	p value (multivariate)
Age	1.0 (1.0–1.1)	0.10	–
Female gender	1.1 (0.4–3.0)	0.88	–
Weight	0.9 (0.9–1.0)	<0.01	0.61
Height	1.0 (0.9–1.0)	0.72	–
BMI	0.8 (0.7–1.0)	0.01	0.57
Diabetes	1.1 (0.4–2.7)	0.88	–
Hypertension	1.4 (0.6–3.4)	0.45	–
Smoking	1.4 (0.5–3.8)	0.45	–
Dyslipidemia	1.2 (0.4–3.2)	0.75	–
Peripheral artery disease	1.9 (0.2–14.4)	0.54	–
Presentation with ACS	1.4 (0.6–3.3)	0.50	–
Ejection fraction <40%	1.8 (0.2–14.0)	0.56	–
Prior radial artery cannulation	1.6 (0.6–4.3)	0.30	–
Radial artery puncture attempts >1	1.7 (0.7–4.2)	0.28	–
Catheter exchange >3	13.5 (3.9–46.3)	0.01	<0.01
Multivessel stenting	1.9 (0.7–4.7)	0.18	–
Complex angioplasty procedure	3.2 (1.3–7.7)	<0.01	0.01
Nonclopidogrel DAPT use	9.0 (3.6–22.6)	<0.01	<0.01
Glycoprotein inhibitor use	5.8 (2.1–16.0)	<0.01	<0.01
Fluoroscopy time	1.0 (1.0–1.1)	0.08	0.07
Radiation dose	1.1 (0.8–1.4)	0.73	–

CI, confidence interval; BMI, body mass index; ACS, acute coronary syndrome; DAPT, dual antiplatelet therapy.

intensive antiplatelet therapy (nonclopidogrel agent use for DAPT and/or Gp IIb/IIIa blocker use) was also the independent predictor for forearm hematoma formation. Often, perforation of the radial artery small branch (and maybe even the radial artery) seals by the tamponade effect of the guide catheter. But in cases of intensive antiplatelet therapy, bleeding may continue from these perforations and can lead to hematoma formation. This may be the reason that intensive antiplatelet therapy was significantly associated with and was the independent predictor for the forearm hematoma formation in the present study.

As per the previous hematoma classification scheme (Bertrand et al¹²), grade I and II hematomas are associated with puncture site issues, and grade II and IV are related to intramuscular bleeding secondary to vascular injury. Therefore, we separately analyzed the predictors for the development of hematomas of more than grade II (non-access site hematomas). In our study, access site hematomas were noticed in 6.9% cases, which is similar as noticed by Bertrand¹³ (7.8%). However, in our study, non-access site hematomas were noted in overall 4.3% patients, which is higher than that reported by Bertrand et al and can be explained by the more frequent usage of nonclopidogrel drugs for DAPT (22.3% in our study) and Gp IIb/IIIa inhibitors in our study. The bigger size sheath and catheter (6F) used in all our patients (only patients after TRA-PCI) than that used in previous studies including a mixed population of both coronary angiography and angioplasty could be another reason for relatively higher incidence of hematoma formation in our study.

Small nongrowing hematoma in the forearm can generally be managed conservatively. A loose compression dressing, gentle elevation of the arm, and careful observation may suffice in most of the cases. Larger or growing hematomas require immediate attention. A pressure dressing wrapped around the forearm can be applied and is usually very effective. Additional application of pressure by an inflated blood pressure cuff on to the arm or forearm can also be beneficial. If compartment syndrome is a concern, the vascular surgeon should be consulted for surgical decompression. In our study, none of the forearm hematomas progressed to compartment syndrome. It denotes that early recognition and prompt treatment of forearm hematoma prevents the development of this complication.

Forearm hematoma formation is easily preventable. In our opinion, in instances of nonprogression of a diagnostic catheter or

guide catheter at any level during the TRA, the operator should inject the contrast agent through the side port of the introducer sheath to define the anatomical issues of that region. Once that is identified, one should use a 0.032" or 0.035" hydrophilic J-tip guidewire to cross the affected segment. Treatment of spasm or atherosclerotic disease, selection of alternative equipment, or reevaluation of the access approach can then be appropriately implemented. Interestingly, in the case of the radial artery or its side branch perforation, the best treatment may be to continue the procedure. We have found that if a catheter can traverse and then tamponade the area of concern, the perforation often seals by the end of the procedure.

4.1. Limitations

First, the preprocedural radial artery diameter was not measured, and all our patients were cannulated using the 6F sheath. It has been reported that the use of a larger sheath in the small-diameter radial artery provokes greater vascular injury, and this could be the reason of relatively higher incidence of forearm hematoma formation in our study. Second, angiographic evaluation of the radial artery was not performed in our study. Radial artery anomalies and variation in the anatomy (loops, tortuosity, and accessory branches) were not noted in our study. These may provide the resistance while advancing the wire or catheter and may end up in causing perforation and hematoma. Third, the study population was relatively younger than that of the previous landmark trial conducted for TRA-PCI, and this potentially will be masking the true hemorrhagic risks. Finally, heparin was used uniformly in doses of 100 units/kg, and the total volume of heparin used during the procedure was not correlated with hematoma formation because of nonavailability of data regarding additional boluses of heparin given during the prolonged procedures.

5. Conclusions

Forearm hematoma formation following TRA-PCI occurs in about 10% patients. Most hematomas occur near the puncture area. The independent predictors for hematoma formation are age, BMI, multiple puncture attempts, intensive antiplatelet therapy, and multiple catheter exchanges. All these hematomas can be

successfully managed with manual bandage compression without any untoward consequences and without the need for blood transfusion.

Sources of funding

None.

Conflict of interest

None.

Disclosure

This work was presented in TCT 2017 held at Denver, USA.

References

- Rao SV, Cohen MG, Kandzari DE, Bertrand OF, Gilchrist IC. The transradial approach to percutaneous coronary intervention: historical perspective, current concepts, and future directions. *J Am Coll Cardiol*. 2010;55(20):2187–2195.
- Agostoni P, Biondi-Zoccai GG, de Benedictis ML, et al. Radial versus femoral approach for percutaneous coronary diagnostic and interventional procedures; systematic overview and meta-analysis of randomized trials. *J Am Coll Cardiol*. 2004;44(2):349–356.
- Cantor WJ, Mahaffey KW, Huang Z, et al. Bleeding complications in patients with acute coronary syndrome undergoing early invasive management can be reduced with radial access, smaller sheath sizes, and timely sheath removal. *Catheter Cardiovasc Interv*. 2007;69(1):73–83.
- Valgimigli M, Frigoli E, Leonardi S, et al, MATRIX Investigators. Radial versus femoral access and bivalirudin versus unfractionated heparin in invasively managed patients with acute coronary syndrome (MATRIX): final 1-year results of a multicenter, randomized controlled trial. *Lancet*. 2018;392(10150):835–848.
- Mann T, Cubeddu G, Bowen J, et al. Stenting in acute coronary syndromes: a comparison of radial versus femoral access sites. *J Am Coll Cardiol*. 1998;32:572–576.
- Cooper CJ, El-Sheikh RA, Cohen DJ, et al. Effect of transradial access on quality of life and cost of cardiac catheterization: a randomized comparison. *Am Heart J*. 1999;138:430–436.
- Kiemeneij F, Laarman GJ, Odekerken D, Slagboom T, van der Wieken R. A randomized comparison of percutaneous transluminal coronary angioplasty by the radial, brachial and femoral approaches: the access study. *J Am Coll Cardiol*. 1997;29:1269–1275.
- Patel T, Shah S, Sanghavi K, Pancholy S. Management of radial and brachial artery perforations during transradial procedures: a practical approach. *J Invas Cardiol*. 2009;21:544–547.
- Tizón-Marcos H, Bertrand OF, Rodés-Cabau J, et al. Impact of female gender and transradial coronary stenting with maximal antiplatelet therapy on bleeding and ischemic outcomes. *Am Heart J*. 2009;157(4):740–745.
- Jue J, Karam JA, Mejia A, Shroff A. Compartment syndrome of the hand: a rare sequela of transradial cardiac catheterization. *Tex Heart Inst J*. 2017;44(1):73–76.
- Pancholy S, Coppola J, Patel T, Roke-Thomas M. Prevention of radial artery occlusion-patent hemostasis evaluation trial (PROPHET study): a randomized comparison of traditional versus patency documented hemostasis after transradial catheterization. *Catheter Cardiovasc Interv*. 2008 Sep 1;72(3):335–340.
- Bertrand OF, Larose E, Rodes-Cabau J, et al. Incidence, predictors, and clinical impact of bleeding after transradial coronary stenting and maximal antiplatelet therapy. *Am Heart J*. 2009;157(1):164–169.
- Bertrand OF. Acute forearm muscle swelling post transradial catheterization and compartment syndrome: prevention is better than treatment. *Catheter Cardiovasc Interv*. 2010;75:366–368.
- Garg N, Sahoo D, Goel PK. Pigtail assisted tracking of guide catheter for navigating the difficult radial: overcoming the "razor effect". *Indian Heart J*. 2016;68(3):355–360.