

Clinical and biochemical profile of scrub typhus patients at a tertiary care hospital in Northern India

Sudhir K. Verma¹, Kamlesh K. Gupta¹, Rajesh K. Arya², Vivek Kumar¹,
D. Himanshu Reddy¹, Shyam C. Chaudhary¹, Satyendra K. Sonkar¹,
Satish Kumar³, Neeraj Verma¹, Deepak Sharma¹

¹Departments of Medicine and ³Endocrinology, King George's Medical University, Lucknow, Uttar Pradesh, ²Department of Medicine, Government Medical College, Orai, Jalaun, Uttar Pradesh, India

ABSTRACT

Background: Scrub typhus is a neglected rickettsial disease in India. Every year, we are facing outbreaks of Scrub typhus after Monsoon season. Patients present with a wide clinical spectrum ranging from pyrexia of unknown origin to multiple organ dysfunction. Some of these clinical features overlap with presentation of other tropical infections prevalent in Indian subcontinent, which leads to diagnostic dilemma and delay in diagnosis. Hence, we planned this study to know the demographic, clinical and biochemical profile of scrub typhus patients. **Methods:** This was an observational study conducted in department of Medicine, King George's Medical University Lucknow, India a leading tertiary care hospital of Northern India. All scrub typhus patients were evaluated by detailed history, examination and laboratory tests. **Results:** We enrolled 52 patients in our study. The mean age of the patients was 35.17 ± 16.90 years with majority (82.7%) of patients from rural background. All the patients had fever with an average duration of 9.6 ± 2 days. Most of the patients developed hepatitis (69.2%) followed by acute encephalitis syndrome (47%), acute kidney injury (23.1%) and acute respiratory failure (19.2%). Eschar was found in 11 patients (21.2%). **Conclusion:** Scrub typhus is often misdiagnosed or diagnosed late due to its wide clinical spectrum overlapping with clinical presentation of other commonly prevalent tropical diseases. One should always consider the differential diagnosis of scrub typhus while evaluating a young febrile patient of rural background, with features of single or multiple organ dysfunction and laboratory findings of leucocytosis, thrombocytopenia and elevation of transaminases.

Keywords: Indian subcontinent, organ dysfunction, pyrexia, rickettsial disease, scrub typhus

Introduction

Scrub typhus is the most common rickettsial disease prevalent in India.^[1] It is caused by *Orientia tsutsugamushi*, an obligate intracellular gram negative bacteria and transmitted to humans through the bite of larval forms of trombiculide mites.^[1]

In India, every year during and after monsoon season, there is sudden rise in cases of acute febrile illness. Viral infections, malaria, dengue, typhoid, leptospirosis and scrub typhus have been classically responsible for such outbreaks.^[1] These diseases may presents with overlapping clinical features.^[2] This often leads to either misdiagnosis or delay in diagnosis. This study will provide diagnostic clues to the primary care physicians, so that they can diagnose cases scrub typhus earlier for better outcome of patients.

According to the WHO, Scrub typhus is probably one of the most underdiagnosed and under-reported febrile illnesses

Address for correspondence: Dr. Sudhir K. Verma,
Department of Internal Medicine, King George's Medical
University, Shahmina Road, Chowk, Lucknow - 226 003,
Uttar Pradesh, India.
E-mail: sudhirkgmu@gmail.com

Received: 12-06-2020

Revised: 08-09-2020

Accepted: 20-10-2020

Published: 08-04-2021

Access this article online

Quick Response Code:



Website:
www.jfmpc.com

DOI:
10.4103/jfmpc.jfmpc_1162_20

This is an open access journal, and articles are distributed under the terms of the Creative Commons Attribution-NonCommercial-ShareAlike 4.0 License, which allows others to remix, tweak, and build upon the work non-commercially, as long as appropriate credit is given and the new creations are licensed under the identical terms.

For reprints contact: WKHLRPMedknow_reprints@wolterskluwer.com

How to cite this article: Verma SK, Gupta KK, Arya RK, Kumar V, Reddy DH, Chaudhary SC, et al. Clinical and biochemical profile of scrub typhus patients at a tertiary care hospital in Northern India. J Family Med Prim Care 2021;10:1459-65.

requiring hospitalization^[1,3,4] In India also, it is a neglected disease. The mortality of the disease varies from 7% to 30%.^[5]

In recent years, we have noticed an increase in the incidence of Scrub Typhus at our institute. So, we planned this study with an aim to study the demographic, clinical and biochemical profile in patients of Scrub Typhus.

Materials and Methods

This was a prospective observational study conducted from September 2019 to January 2020 in the Department of Internal Medicine, King George Medical University, Lucknow, a tertiary care institution located in Northern India. We enrolled 52 patients for the study, who fulfilled the inclusion and exclusion criteria.

Inclusion criteria

1. Pyrexia for more than 5 days
2. Age more than 18 years
3. Patients tested positive for IgM antibodies against *O.tutsugamushi*

Exclusion criteria

1. Patients who had other causes of fever like Malaria, Dengue, viral diseases, Leptospirosis, Typhoid fever, pneumonia, pleural effusion, urinary tract infections
2. Patients tested negative for IgM antibodies against *O.tutsugamushi*
3. Patients who didn't gave their consent for the study.

All demographic data, detailed clinical history including age, gender, occupation and presenting complaints in chronological order were carefully recorded. All the patients were subjected to detailed physical examination with special attention to temperature, presence of skin eschar, icterus, respiratory rate, altered sensorium and hepatosplenomegaly. Ethical approval was taken before initiation of the study from institutional ethical committee on 13-08-2019.

A standard set of investigations were sent to establish the cause of fever. This included complete blood count (CBC) including peripheral blood smear for malaria parasites, liver function tests, kidney function tests, urine examination and serology for dengue, chikungunya, scrub typhus, leptospirosis and enteric fever. Chest X-ray and ultrasound of the abdomen was also carried out. Scrub typhus serology was tested for IgM antibodies against the causative agent *O.tutsugamushi* using ELISA kits. A CT/MRI imaging of brain and Cerebrospinal fluid analysis of the patients was done in patients who presented with features of Acute encephalitic syndrome.

We used following definitions to describe complications in our the study.

1. Acute kidney injury (AKI): It was defined as per the latest Acute Kidney Injury Network (AKIN) classification

guidelines.^[6]

2. Acute hepatitis: elevation of serum transaminases [aspartate aminotransferase (AST)/alanine aminotransferase (ALT)] more than two times of the upper limit of normal
3. Acute respiratory distress syndrome (ARDS): Acute-onset (<7 days) noncardiogenic pulmonary edema which manifests as bilateral alveolar or interstitial infiltrates on a chest radiograph, with a $\text{PaO}_2/\text{FiO}_2 \leq 300$ mmHg on arterial blood gas analysis
4. Pneumonia: Patients with acute-onset fever and cough/breathlessness, with or without crackles/rhonchi, with radiographic evidence of consolidation or interstitial infiltrates
5. Meningitis: Patients with fever and altered mental status, with or without nausea/vomiting, with or without signs of meningeal irritation and an abnormal cerebrospinal fluid (CSF) analysis

On admission, all the patients admitted as case of acute febrile illness with single or multiorgan dysfunction were given empirical antibiotics (Ceftriaxone and Azithromycin intravenously) along with symptomatic and supportive treatment. After ruling out other causes of fever and confirmation of the diagnosis of Scrub typhus, Ceftriaxone was replaced with oral doxycycline 100 mg twice daily in patients with normal liver functions.

Results

Based on inclusion and exclusion criteria, we enrolled 52 patients. The demographic and clinical profile of all enrolled patients is depicted in Table 1. The mean age of the patients was 35.17 ± 16.90 years with majority of patients between 21-50 years of age (51.9%) [Figure 1]. Females were slightly more affected with female to male ratio of 1.16:1 [Figure 2]. Majority of the patients (82.7%) belonged to rural area were involved in farming [Figure 3].

All the patients had fever with an average duration of 9.6 ± 2 days. All the patients had fever with an average duration of 9.6 ± 2 days. Fever was high grade, continuous in majority of patients. Twenty one (40.3%) and sixteen (30.7%) patients presented as fever with chills and pyrexia of unknown origin respectively. Sixteen (30.7%) patients presented as pyrexia of unknown origin. Other associated symptoms were

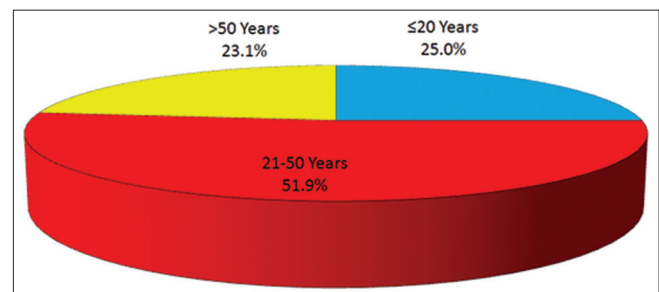


Figure 1: Age wise distribution of patients with scrub typhus

headache (69.2%), followed by nausea and vomiting (59.6%). On examination, icterus was present in fifteen (28.8%) patients. Eschar, a characteristic skin lesion seen in patients of Scrub typhus, was found in eleven patients (21.2%) on abdomen, thighs and arms [Figure 4]. Erythematous maculopapular rash was seen in 4 (7.7%) patients. On abdominal examination, hepatomegaly was present in 11 (21.2%) and splenomegaly in 15 (28.8%) patients. Among patients presented as AES, signs of meningeal irritation (neck rigidity and/or Kernig's sign) were present only in nine patients (17.3%).

Table 1: Demographics and Clinical profile of enrolled Scrub typhus patients (n=52)

Characteristic	No. of cases	Percentage
Age		
≤20 Years	13	25.0
21-50 Years	27	51.9
>50 Years	12	23.1
Mean Age±SD (years)	35.17±16.90	
Sex		
Male	24	46.2
Female	28	53.8
Duration of illness (days)		
≤7 days	8	15.4
8-14 days	42	80.8
>14 days	2	3.8
Mean duration of illness±SD (days)	9.6±2	
Residence		
Rural	43	82.7
Urban	9	17.3
Symptoms		
Fever	52	100.0
Breathlessness	10	19.2
Nausea/Vomiting	31	59.6
Headache	36	69.2
Jaundice	15	28.8
Altered sensorium (A/S)	27	48.1
Rash	4	7.7
Decreased urine output	12	23.1
Signs		
Pallor	10	19.2
Icterus	15	28.8
Hypotension/Shock (BP <90 mmHg)	8	15.4
Hepatomegaly	11	21.2
Splenomegaly	15	28.8
Eschar	11	21.2
Meningeal sign (Neck rigidity/ Kernig's sign)	9	17.3

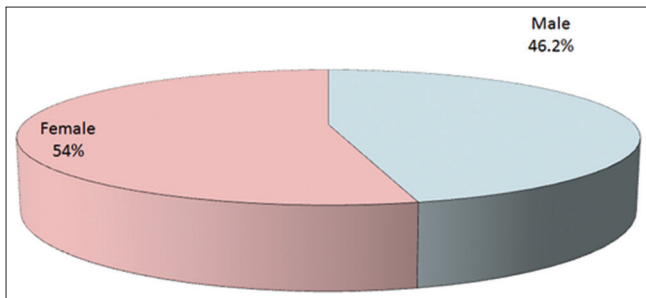


Figure 2: Sex wise distribution of patients with scrub typhus

The biochemical profile of patients enrolled in our study is shown in Table 2. Complete blood count revealed anemia in 31 (59.6%), leucocytosis in 26 (50%) and thrombocytopenia in 40 (76.9%) patients. Liver function test showed elevated transaminases with rise in SGOT and SGPT in thirty six (69.2%) and thirty (57.7%) patients, respectively and hyperbilirubinemia (bilirubin > 2mg/dL) in eighteen (34.6%) patients. Rise in SGOT was more than SGPT (SGOT/SGPT > 1). Acute kidney injury characterized by recent elevation of blood urea and serum creatinine was seen in 31 (59.6%) patients.

Lumbar puncture was performed in 16 cases. The findings of CSF analysis are depicted in Table 3. Cerebrospinal fluid analysis (CSF) revealed elevated protein (mean- 103.38 mg/dL) with lymphocytic predominance (mean cells-69) and mean ADA of 8.1IU/L. All CSF samples were negative for acid-fast bacilli (AFB), Gram and Indian ink stain. MRI Brain showed findings of either meningitis or meningoencephalitis except one patient which showed finding of left-sided intracerebral hemorrhage. In patients presenting with respiratory distress, Chest radiographs PA view revealed findings of pneumonitis in 6 (11.5%), ARDS in 4 (7.7%) and pleural effusion in 3 (5.8%) patients.

The complications of scrub typhus in our patients are depicted in Table 4. Multi organ dysfunction syndrome (MODS) was found in 23 (44.2%) patients. Among other complications, hepatitis was the most common, presenting either as elevation of AST and ALT in 36 (69.2%) and 30 (57.7%) patients respectively and/or hyperbilirubinemia in 18 (34.6%) patients. Features of acute febrile encephalopathy was found in 27 (48.1%) patients. Acute kidney injury was observed in 12 (23.1%) patients who presented with history of decreased urine output. Similarly, 10 (19.2%) patients presented with acute respiratory failure presenting as breathlessness, of which 4 (7.7%) patients required ventilatory support.

In our study, we also encountered two unusual presentations of scrub typhus. One of our patients presented with gangrenous changes of digits of bilateral upper limb [Figure 3] which was probably due to disseminated intravascular coagulation (DIC). Another patient developed hemorrhagic stroke during hospital stay which might be due to severe thrombocytopenia or hemorrhagic transformation of encephalitis.

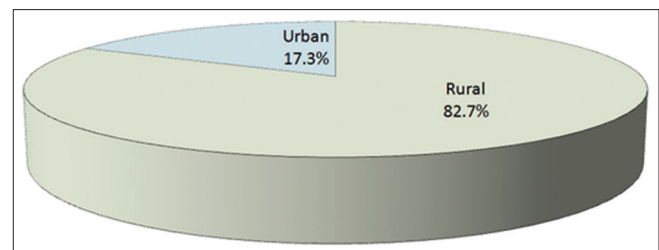


Figure 3: Residential address of enrolled scrub typhus patients

Table 2: Laboratory investigations of enrolled patients

Characteristic	No. of cases	Percentage
Hemoglobin (<10 gm/dl)	31	59.6
Mean Hb±SD (gm/dl)	9.30±1.77	
Total leucocyte count		
<4000	4	7.7
4000-11000	22	42.3
>11000	26	50.0
Mean±SD (thousands/mm ³)	11.29±5.08	
Platelet count <1.5×10 ⁶ /cumm	40	76.9
Mean±SD	1.06±0.63	
SGOT>80 IU/ml (Mean±SD)	36	69.2
	180.12±151.45	
SGPT>80 IU/ml (Mean±SD)	30	57.7
	115.08±95.52	
Positive Weil Felix test	7	13.5
Elevated total bilirubin (>2 mg/dl)	18	34.6
Increased serum urea/creatinine	31	59.6

Table 3: CSF Findings of scrub typhus patients with Acute encephalitis syndrome (n=16)

Parameters	Mean value	SD
Total cells (per mm ³)	69.94	48.36
Protein (mg/dl)	103.38	36.27
Sugar (mg/dl)	57.27	14.70
ADA (IU/L)	8.1	2.60

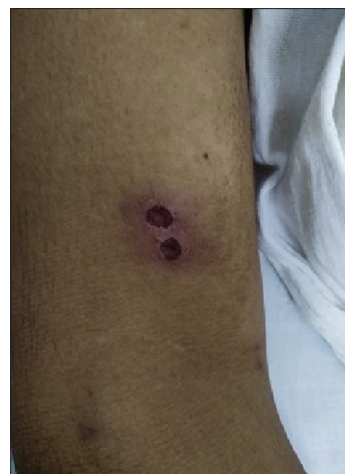Table 4: Complications of Scrub typhus in our study

Characteristic	No. of cases	Percentage
Hepatic dysfunction	40	76.9
Renal dysfunction	30	57.7
Meningoencephalitis	11	21.2
Shock	8	15.4
Pneumonitis	6	11.5
Pleural effusion	3	5.8
Intracerebral hemorrhage	1	1.9
ARDS	4	7.7
Gangrenous changes in digits	1	1.92

Discussion

Scrub typhus is a neglected rickettsial disease prevalent in India. This prompted us to conduct the present study with an aim to study the clinical and biochemical profile of scrub typhus patients. This study will guide upcoming physicians to diagnose and manage these patients in a better way.

Most of the patients enrolled in our study were young with mean age of 35 years and belonged to rural areas, which might be due to more involvement of younger population in outdoor farming activities. Females were slightly more affected than males (1.16:1), which shows significant contribution of females in farming activities in northern India. These findings are supported by many previous studies. Lakshmi RMMV *et al.* found that most of the patients were between 20 and 50 years.^[7] Similarly, Pathania M *et al.* found that young adults between 20 and 40 years are the most

**Figure 4: Eschar at dorsal aspect of arm of scrub typhus patient**

affected group with female-to-male ratio was 2.8:1.^[8] However, Zhang M *et al.* found that scrub typhus was more prevalent in higher age group with mean age of 54 years and female to male ratio of 1.08:1.^[9] Study done by Jayprakash V *et al.* also observed that mean age of affected population was 45.7 ± 15 years with female to male ratio of 1.68:1.^[10] So, studies suggest that any febrile young patient from rural background should always be evaluated for Scrub typhus.

In our study, the mean duration of fever at presentation was 9.6 days. In most cases, fever was high grade, continuous and responded to antipyretics. Fever was associated with chills in 20 (38.5%) of patients. Lakshmi RMMV *et al.* also found that majority of the patients (58.6%) presented with 7–14 days of fever and 10.3% of them had prolonged pyrexia beyond 2 weeks.^[7] Similarly, Pathania M *et al.* reported mean duration of illness 9.8 ± 4 days, which is almost same as found in our study.^[8] In the study of Zhang M *et al.*, mean duration of fever was 6.6 days with 35.3% had continued fever, 23.5% had remittent fever, 34.3% had irregular fever, and 6.9% were unspecified fever type.^[9]

In current study, other complaints were headache (69.2%) followed by nausea and vomiting (59.6%). Eschar, a characteristic blackish necrotic skin lesion of scrub typhus, was seen only in 11 patients (21.2%). The most common site of eschar was thigh. Previous Indian studies have also reported similar frequencies of occurrence of eschar (1.8-24%). Lakshmi RMMV *et al.*, Pathania M *et al.*, Takhar *et al.*, Sivarajan *et al.* and Subbalaxmi *et al.* reported eschar in 13.7%, 1.8%, 12.1%^[5], 11.1% and 13.1%, respectively.^[5,7,8,11,12] The lower detection rate of eschar in Indian studies study might be due to darker skin color of patients.

Similarly, Jayprakash V *et al.* observed anorexia, nausea, and vomiting in 21.24% of patients, jaundice in 6.22% of patients and eschar in 28.49% of patients. Thigh was commonest location of the eschar, followed by neck and chest, abdomen, perineum, axillae, and the back.^[9] Zhang M *et al.* also reported manifestations like eschar or skin

ulcer (86.3%), anorexia (71.6%), fatigue (71.6%), rash (68.6%), headache (62.7%) and generalized myalgia (47.1%).^[9]

Acute hepatitis was the most common complication observed in our study. Most of such patients complaint of fatigue and loss of appetite. Patients presented as elevation of AST and ALT in thirty six (69.2%) and thirty (57.7%) patients respectively with SGOT/SGPT ratio >1. Hyperbilirubinemia was found in 15 (28.8%) patients presenting as icterus. On abdominal examination, hepatomegaly was present in 11 (21.2%) and splenomegaly in 15 (28.8%) patients. Previous studies by Pathania M *et al.* and Elsom KA *et al.* reported 7.40% with acute hepatitis, hepatomegaly in eight 14.8% and, splenomegaly in one case 1.85%.^[8,13] Narvencar KP *et al.* also found similar results in their study with hepatomegaly in 6.9% and splenomegaly in 13.7% cases.^[14] According to study done by Zhang M *et al.*, abnormal liver function test was the most common laboratory finding. Elevated aspartate aminotransferase (AST) and alanine aminotransferase (ALT) found in 75.0% and 80.3% of the patients,^[9] Lakshmi RMMV *et al.* concluded that markers of severe disease include elevated aspartate amino transferase (AST) and serum creatinine and were seen in 82.7%, and 20.6% patients, respectively.^[7]

In our study, acute kidney injury was observed in 12 (23.1%) patients who presented with history of decreased urine output. All such patients improved on treatment and conservative fluid therapy without requiring hemodialysis. Pathania M *et al.*,^[8] Subbalaxmi MVS *et al.*^[12] and Griffith M *et al.*^[15] also reported 12% to 22% of AKI in their studies. AKI was found in 18.7% cases in study done by Jayprakash V *et al.*^[10]

Twenty seven (48.1%) patients presented with features of acute encephalitis syndrome (AES) with mean Glasgow coma scale (GCS) of 12. Among these patients, signs of meningeal irritation (neck rigidity and/or kernig's sign) were present only in 8 patients (17.3%) [Table 1] [Figure 5]. So, the sensitivity of signs of meningeal irritation in Scrub typhus

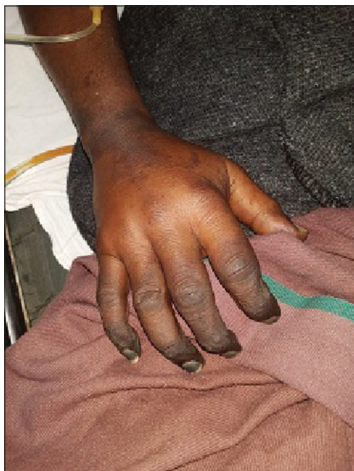

Figure 5: Gangrenous changes in digits of upper limb in patient of scrub typhus

meningo-encephalitis was low in contrast to previous studies done in patients of bacterial meningitis, where it was 46.1% for neck rigidity and 22.9% for Kernig's sign.^[16] In our study, lumbar puncture was performed in 16 cases. The findings of Cerebrospinal fluid (CSF) analysis is summarized in Table 3. CSF analysis revealed elevated protein (mean- 103.38 mg/dL) with lymphocytic predominance (mean cells-69) and mean ADA of 8.1IU/L. All CSF samples were negative for acid-fast bacilli (AFB), Gram and Indian ink stain. CT/MRI Brain imaging showed findings of either diffuse cerebral edema or meningitis/ meningo-encephalitis.

Our CNS findings are also supported by study done by Misra UK *et al.* where they found altered consciousness level (GCS score ≤ 14) in 31 (84%) cases and 6 (16%) were deeply comatose (GCS score <8).^[17] Neck rigidity was found in 18 (49%), limb weakness in 14 (38%) and hyporeflexia in 3 (8%) cases. Among patient presented with AES, one patient had lateral rectus palsy. This rare complication has been reported only thrice in the world previously.^[18-20] MRI finding revealed meningeal enhancement in 1/25 (4%) cases. In their study, CSF examination revealed lymphocytic pleocytosis (112 ± 182 cells/mm³) in 19 and raised protein (97.0 ± 48.3 mg/dL) in all patients.^[17]

During hospital stay, one patients sensorium deteriorated acutely. Repeated imaging of brain showed findings of left-sided intracerebral hemorrhage. The occurrence of hemorrhagic stroke in our patient might be due to either uremic platelet dysfunction or due to pre-existing cerebral aneurysms or hemorrhagic transformation of encephalitis.^[21,22]

In our study, 10 (19.2%) patients presented with acute respiratory distress presenting with breathlessness. Arterial blood gas analysis was performed in all such patients which revealed acute respiratory distress syndrome (Pao₂/FiO₂<300) in 4 (7.7%) patients. Chest radiograph PA view showed findings of pneumonitis in 6 (11.5%) and ARDS in 4 (7.7%) patients. Most of the patients required oxygen therapy and improved. Four (7.7%) patients were not maintaining arterial oxygen saturation even on oxygen therapy and thus required mechanical ventilatory support [Table 4]. Yang HJ *et al.* found abnormalities in Chest radiographs in 20.6% of patients.^[23] Study done by Allen AC *et al.* showed higher incidence of pneumonitis with 36% of scrub typhus patients with pneumonitis and further, 42% of the cases with pneumonitis led to ARDS.^[24] Similarly, study done by Wang CC *et al.* reported that scrub typhus is as a common etiology of pneumonitis in an endemic region. So, the respiratory impacts of scrub typhus includes bronchitis, interstitial pneumonitis to ARDS.^[25]

Laboratory findings which supports the diagnosis of Scrub typhus are anemia, thrombocytopenia (76.9%), leukocytosis (50%) and elevated transaminases with rise in AST (69.2%) more than ALT (57.7%). Study conducted by Misra UK *et al.* also reported 17% of cases with abnormal white blood cell (WBC) count, and 26.8% of cases with abnormal platelet count.

Thirty-five (95%) cases found to be anemic, 20 (54%) with thrombocytopenia, 8 (22%) with renal dysfunction, 12 (32%) with hyperbilirubinaemia, 33 (89%) with elevated serum transaminase and 13 (35%) with raised serum creatine kinase.^[17] Similarly, study conducted by Varghese *et al.*, showed a combination of raised transaminases, thrombocytopenia and leucocytosis confers 80% specificity and 80% positive predictive value for scrub typhus diagnosis.^[26]

Mean hospital stay of patients in our study was 9.57 days. Previous studies done by SS Premraj *et al.* and Varghese *et al.* also had mean duration of hospital stay of 7.7 ± 3.6 days.^[24] and 9.6 ± 4.8 day, respectively.^[26,27]

Despite our best efforts, three patients succumbed. All the three patients had features of multiorgan dysfunction with two patients had severe ARDS requiring mechanical ventilatory support and one patient developed hemorrhagic stroke. Expiries are attributable to late presentation, delay in diagnosis and presence of complications like as ARDS, renal failure and hepatic failure.

Keypoints

1. Scrub typhus should always be considered in the list of differential diagnosis of a young febrile patient of rural background.
2. Clinical clues supporting diagnosis of scrub typhus are presence of eschar, features of pneumonitis, acute encephalitis syndrome, oliguria and jaundice.
3. Laboratory findings suggestive of scrub typhus are anemia, leucocytosis, thrombocytopenia, elevation of transaminases (AST more than ALT), raised BUN and albuminuria.
4. Early diagnosis and appropriate treatment are the key components of effective management.

Acknowledgement

None

Declaration of patient consent

The authors certify that they have obtained all appropriate patient consent forms. In the form the patient (s) has/have given his/her/their consent for his/her/their images and other clinical information to be reported in the journal. The patients understand that their names and initials will not be published and due efforts will be made to conceal their identity, but anonymity cannot be guaranteed.

Financial support and sponsorship

Nil.

Conflicts of interest

There are no conflicts of interest.

References

1. Viswanathan S, Muthu V, Iqbal N, Remalayam B, George T. Scrub typhus meningitis in South India-A retrospective study. *PLoS One* 2013;8:e66595.
2. Chakraborty S, Sarma N. Scrub typhus: An emerging threat. *Indian J Dermatol* 2017;62:478-85.
3. Mittal V, Gupta N, Bhattacharya D, Kumar K, Ichhpujani RL, Singh S, *et al.* Serological evidence of rickettsial infections in Delhi. *Indian J Med Res* 2012;135:538-41.
4. Sood A, Chauhan S, Jarya SC. Rickettsial diseases: An urgent need to upgrade diagnostic facilities. *Int J Rec Tr Sci Tech* 2013;7:20-1.
5. Takhar RP, Bunkar ML, Arya S, Mirdha N. A scrub typhus: A prospective, observational study during an outbreak in Rajasthan, India. *Natl Med J India* 2017;30:69-72.
6. Mehta RL, Kellum JA, Shah SV, Molitoris BA, Ronco C, Warnock DG, *et al.* Acute kidney injury network: Report of an initiative to improve outcomes in acute kidney injury. *Crit Care* 2007;11:R31.
7. Lakshmi RMMV, Dharma TV, Sundharan S, Surya SMV, Emmadi R, Yadati SR, *et al.* Prevalence of scrub typhus in a tertiary care centre in Telangana, south India. *Iran J Microbiol* 2020;12:204-8.
8. Pathania M, Amisha, Malik P, Rathaur VK. Scrub typhus: Overview of demographic variables, clinical profile, and diagnostic issues in the sub-Himalayan region of India and its comparison to other Indian and Asian studies. *J Family Med Prim Care* 2019;8:1189-95.
9. Zhang M, Zhao ZT, Wang XJ, Li Z, Ding L, Ding SJ. Scrub typhus: Surveillance, clinical profile and diagnostic issues in Shandong, China. *Am J Trop Med Hyg* 2012;87:1099-104.
10. R2-Jayaprakash V, Vamsikrishna M, Indhumathi E, Jayakumar M. Scrub typhus-associated acute kidney injury: A study from a South Indian Tertiary Care Hospital. *Saudi J Kidney Dis Transplant* 2019;30:883.
11. Sivarajan S, Shivalli S, Bhuyan D, Mawlong M, Barman R. Clinical and paraclinical profile, and predictors of outcome in 90 cases of scrub typhus, Meghalaya, India. *Infect Dis Poverty* 2016;5:91.
12. Subbalaxmi MVS, Chandra N, Teja VD, Lakshmi V, Rao MN, Raju YSN. Scrub typhus - Experience from a South Indian tertiary care hospital. *BMC Infect Dis* 2012;12:77.
13. Elsom KA, Beebe GW, Sayen JJ, Scheie HG, Gammon GD, Wood FC. Scrub typhus: A follow-up study. *Ann Intern Med* 1961;55:785-95.
14. Narvencar KP, Rodrigues S, Nevrekar RP, Dias L, Dias A, Vaz M, *et al.* Scrub typhus in patients reporting with acute febrile illness at a tertiary health care institution in Goa. *Indian J Med Res* 2012;136:1020-4.
15. Griffith M, Peter JV, Karthik G, Ramakrishna K, Prakash JA, Kalki RC, *et al.* Profile of organ dysfunction and predictors of mortality in severe scrub typhus infection requiring intensive care admission. *Indian J Crit Care Med* 2014;18:497-502.
16. Akaishi T, Kobayashi J, Abe M, Ishizawa K, Nakashima I, Aoki M, *et al.* Sensitivity and specificity of meningeal signs in patients with meningitis. *J Gen Fam Med* 2019;20:193-8.
17. Misra UK, Kalita J, Mani VE. Neurological manifestations of scrub typhus. *J Neurol Neurosurg Psychiatry* 2015;86:761-6.
18. Bhardwaj B, Panda P, Revannasiddaiah S, Bhardwaj H. Abducens nerve palsy in a patient with scrub typhus: A case report. *Trop Biomed* 2013;30:706-9.

19. Lee YH, Yun YJ, Jeong SH. Isolated abducens nerve palsy in a patient with scrub typhus. *J AAPOS* 2010;14:460-1.
20. Ete T, Mishra J, Barman B, Mondal S, Sivam RKN. Scrub typhus presenting with bilateral lateral rectus palsy in a female. *J Clin Diagnostic Res* 2016;10:16-7.
21. Kim HC, Yoon KW, Yoo DS, Cho CS. Hemorrhagic transformation of scrub typhus encephalitis: A rare entity. *Clin Neuroradio* 2015;25:415-8.
22. Kotwal M, Vaish E, Gupta K K, Ozair A. Scrub typhus manifesting with intracerebral hemorrhage: Case report and review of literature. *J Family Med Prim Care* 2020;9:2535-7.
23. Yang HJ, Kim SM, Choi JS, Oh JH, Cho AY, Lee MS, *et al.* Clinical significance of abnormal chest radiographic findings for acute kidney injury in patients with scrub typhus. *Kidney Res Clin Pract* 2020;39:54-9.
24. Allen AC, Spitz S. A comparative study of the pathology of scrub typhus (tsutsugamushi disease) and other rickettsial disease. *Am J Pathol* 1945;21:602-81.
25. Wang CC, Liu SF, Liu JW, Chung YH, Su MC, Lin MC. Acute respiratory distress syndrome in scrub typhus. *Am J Trop Med Hyg* 2007;76:1148-52.
26. Varghese GM, Raj D, Francis MR, Sarkar R, Trowbridge P, Muliylil J. Epidemiology & risk factors of scrub typhus in south India. *Indian J Med Res* 2016;144:76-81.
27. Premraj SS, Mayilananthi K, Krishnan D, Padmanabhan K, Rajasekaran D. Clinical profile and risk factors associated with severe scrub typhus infection among non-ICU patients in semi-urban south India. *J Vector Borne Dis* 2018;55:47-51.