



# Cerebral perfusion changes in chronic dizziness: A single-photon emission computed tomography study

Ken Johkura<sup>a,\*</sup>, Koji Takahashi<sup>b</sup>, Yosuke Kudo<sup>a</sup>, Tsutomu Soma<sup>c,d</sup>, Shinobu Asakawa<sup>e</sup>, Nami Hasegawa<sup>e</sup>, Shizuho Imamichi<sup>e</sup>, Kiyokazu Kurihara<sup>e</sup>

<sup>a</sup> Department of Neurology, Yokohama Brain and Spine Center, Yokohama, Japan

<sup>b</sup> Department of Clinical Laboratory, Yokohama Brain and Spine Center, Yokohama, Japan

<sup>c</sup> RI Software Development Group, Quality Assurance Dept, Quality, Safety Management & Regulatory Affairs Div. FUJIFILM Toyama Chemical Co., Ltd., Japan

<sup>d</sup> Department of Nuclear Medicine and Medical Physics, International University of Health and Welfare School of Medicine, Japan.

<sup>e</sup> Department of Radiology, Yokohama Brain and Spine Center, Yokohama, Japan

## ARTICLE INFO

### Keywords:

Chronic dizziness  
Regional cerebral blood flow  
Single-photon emission computed tomography  
Persistent postural-perceptual dizziness  
Medullary infarction

## ABSTRACT

**Background and purpose:** Dizziness may persist even after the causative vestibular imbalance subsides. Although the precise mechanism of chronic dizziness is unknown, various cerebral activity changes associated with it have been reported. To understand its mechanism in the absence of the causative vestibular imbalance, we compared cerebral changes in chronic dizziness with and without persistent vestibular imbalance.

**Methods:** Between September 2014 and March 2020, we examined regional cerebral blood flow (rCBF) in 12 patients having chronic post-lateral medullary infarction dizziness with persistent brainstem vestibular imbalance and 23 patients having chronic dizziness without currently active vestibular imbalance using single-photon emission computed tomography (SPECT) with 99m Technetium-ethyl cysteinate dimer. Further, we analyzed the SPECT images using a voxel-based group comparison.

**Results:** We observed a decreased rCBF in the occipital lobe and increased rCBF in the medial and inferior parts of the temporal lobe in patients having chronic dizziness with and without active vestibular imbalance compared to healthy controls. However, only patients having chronic dizziness without active vestibular imbalance exhibited increased rCBF in the frontal lobe, including the orbitofrontal cortex.

**Conclusion:** This is the first study to highlight the difference in rCBF changes between patients having chronic dizziness with and without active vestibular imbalance. Decreased occipital lobe activity and increased medial and inferior temporal lobe activity may be related to keeping dizziness perception triggered regardless of the presence or absence of active vestibular imbalance, whereas increased frontal lobe activity may explain the dizziness background to persist after the disappearance of vestibular imbalance.

## 1. Introduction

Chronic sensory stimulation, such as pain and sound, may cause cerebral activity changes not only in the causative sensory perception pathway regions but also in other regions [1,2]. Some of these cerebral activity changes may in turn lead to chronicity. This can further trigger persistence of the sensory perception even when the original stimulus subsides [1,2]. Thus, cerebral changes in patients with chronic sensory symptoms can be both the result and the cause of the symptoms. Dizziness is one of the sensory stimuli that cause changes in cerebral activity [3].

A primary cause of acute stage dizziness or vertigo is an imbalance between the activities of the vestibular nuclei caused by peripheral vestibular disorders. In such disorders, the cerebellum is known to suppress the contralateral vestibular nucleus and corrects the brainstem vestibular imbalance (vestibular compensation) [4,5]. Therefore, dizziness due to peripheral vestibular disorders usually improves within a short period of time. However, dizziness may persist when the brainstem-cerebellar vestibular compensation mechanism collapses for some reasons like in the brainstem or cerebellar infarction. Lateral medullary infarction (LMI) involves around the vestibular nucleus. Consequently, dizziness perdures and is usually associated with other

\* Corresponding author at: Department of Neurology, Yokohama Brain and Spine Center, 1-2-1 Takigashira, Isogo-ku, Yokohama 235-0012, Japan.

E-mail address: [ke00-johkura@city.yokohama.jp](mailto:ke00-johkura@city.yokohama.jp) (K. Johkura).

<https://doi.org/10.1016/j.ensci.2021.100367>

Received 14 March 2021; Received in revised form 8 July 2021; Accepted 24 August 2021

Available online 27 August 2021

2405-6502/© 2021 The Authors.

Published by Elsevier B.V. This is an open access article under the CC BY-NC-ND license

(<http://creativecommons.org/licenses/by-nc-nd/4.0/>).

neurologic symptoms such as gait disturbance, dysphagia, hoarseness, and impaired facial and contralateral limb/body sensation (Wallenberg syndrome) in the acute stage [6,7]. The dizziness accompanying LMI can sometimes persist even after improvement of other neurologic symptoms and can lead to serious psychosocial sequelae [8–10]. One of the postulated mechanisms of dizziness persistence in LMI involves pathological disinhibition of the ipsilateral brainstem vestibular function from the cerebellum [9–11]. In such a case, instead of the usual brainstem-cerebellar vestibular compensation [12], an abnormal brainstem vestibular imbalance continues. This may be supported by the existence of persistent ipsilateral nystagmus in the chronic stage of LMI patients resulting in long-lasting dizziness [9]. Cerebral changes in patients having chronic post-LMI dizziness are thought to be the result of persistent vestibular imbalance signal inputs. These cerebral changes associated with chronic post-LMI dizziness may reflect a continuous dizziness recognition state, rather than the cause of chronic dizziness.

Dizziness may persist even after an abnormal vestibular imbalance subsides. Persistent postural-perceptual dizziness (PPPD) is a recently defined syndrome by the Bárány Society and included in the 11th edition of the International Statistical Classification of Disease and Related Health Problems (ICD-11) [13]. The primary features of PPPD are persistent dizziness, unsteadiness, and/or non-spinning vertigo that can interrupt daily life. PPPD is typically preceded by acute vestibular disorders, lasting for more than 3 months, and exacerbated by upright posture, active or passive motion without regard to direction or position, and/or exposure to moving visual stimuli or complex visual patterns [13]. Dizziness in PPPD persists beyond the course of the original acute vestibular disorder. The pathophysiological mechanism in PPPD is estimated to be mainly an abnormal adaptation of visual and/or somatosensory dependence; thus, PPPD may be a chronic dizziness due to cerebral activity changes for dizziness sensitization [3]. These cerebral changes in PPPD are thought to be the cause of chronic dizziness.

There have been no reports comparing cerebral changes in persistent dizziness due to prevailing brainstem vestibular imbalance (e.g., post-LMI dizziness) with that of dizziness pursuing even after the vestibular imbalance disappearance (e.g., PPPD). In the former case, cerebral changes accompanying dizziness are considered to correspond to the results of chronic abnormal vestibular inputs, whereas in the latter case, the changes are considered to contribute to the chronicity of dizziness symptoms. In this study, we aimed to compare the cerebral changes in patients having chronic post-LMI dizziness with persistent brainstem vestibular imbalance and those having chronic dizziness in absence of active vestibular imbalance. Single-photon emission computed tomography (SPECT) is generally employed to investigate cerebral condition changes in various cerebral diseases because altered neuronal activity involves corresponding changes in cerebral perfusion. Thus, we investigated the changes in regional cerebral blood flow (rCBF) in patients with chronic dizziness and compared their characteristics using SPECT.

## 2. Methods

We conducted a cross-sectional observational study in Yokohama Brain and Spine Center between the period from September 2014 to March 2020. This study was approved by the institutional review board (No. 141400701), and written informed consent was obtained from all participants before the study initiation. The data that support the findings of this study are available from the corresponding author upon reasonable request.

### 2.1. Chronic dizziness patients with persisting brainstem vestibular imbalance

The persistence of brainstem vestibular imbalance is reflected in continual of obvious ipsilateral nystagmus in post-LMI patients [9]. Thus, we recruited patients from a chronic stage of isolated LMI population with persisting dizziness (including unsteadiness and/or non-

spinning vertigo), displaying ipsilateral nystagmus in all spontaneous, head-shaking, and positional testing conditions [9,10]. The exclusion criteria for the study included patients under 20 years of age, having any peripheral vestibular disorder detected by quantifiable video-head impulse test (vHIT) or rotatory stimulation test, psychiatric disorder, or structural brain lesions (except LMI) detected by magnetic resonance imaging (MRI). Patients with limb weakness or ataxia were also excluded. Eventually, 12 patients with chronic post-LMI dizziness participated in this study as patients with chronic dizziness and persistent brainstem vestibular imbalance (medullary infarction group, MI group) (Table 1). In all patients in the MI group, the duration of dizziness was the same as the time from the onset of LMI. The degree of dizziness was rated using the Dizziness Handicap Inventory (DHI), which consisted of 25 questions representing the effects of dizziness on daily life in three domains: functional, emotional, and physical [14].

### 2.2. Chronic dizziness patients without currently active vestibular imbalance

Patients whose chief complaint was chronic dizziness (including unsteadiness and/or non-spinning vertigo) with a relatively clear onset time, which was easily worsened temporarily due to various self-stimuli (certain motion or posture) and perceptual stimuli (certain visual stimuli) [15–18] were only recruited. Patients were excluded if they were under 20 years of age, or if they showed any abnormalities in neuro-otologic vestibular tests, including nystagmus and eye movement tests as checked by a charge-coupled camera with infrared illumination built-in Frenzel goggles, quantifiable vHIT or rotatory stimulation test, and cervical and ocular vestibular evoked myogenic potential tests. Patients were also excluded if they had any abnormal neurologic manifestations such as dysarthria, weakness, sensory deficit, ataxia, psychiatric disorder, or structural brain lesions detected by MRI. Eventually, 23 patients with chronic dizziness without the currently active vestibular imbalance participated in this study as the chronic dizziness group (CD group) (Table 1). In addition to the duration and degree of chronic dizziness, preceding acute dizziness episodes in any of the patients in the group were evaluated, and the preceding vestibular disorders were investigated from the medical records of our or other hospitals. It should be noted that patients in the CD group could not be diagnosed with PPPD because the diagnostic criteria for PPPD were not determined at the beginning of this study, although most of them met the diagnostic criteria for PPPD [13].

### 2.3. Statistical analysis of patients' clinical characteristics

Differences in background characteristics between patient groups were analyzed using the Mann-Whitney *U* test (age), Pearson chi-square test (sex ratio), or Kruskal-Wallis test (duration of dizziness and DHI score). Statistical analyses were performed using SPSS statistical software (version 22, IBM, Armonk, NY), and statistical significance was set at  $p < 0.05$ .

**Table 1**  
Clinical characteristics of participated patients.

Characteristics	MI group (n = 12)	CD group (n = 23)	p value
Age (years)	53.0 ± 8.6	69.0 ± 9.8	< 0.001
Sex (female %)	33.3	60.9	0.16
Disease duration (months)	13.0 ± 11.9	15.4 ± 15.9	0.79
DHI score	51.3	50.4	0.67

Data are presented as mean ± SD.

MI, chronic post-lateral medullary infarction dizziness; CD, chronic dizziness without currently active vestibular imbalance; DHI, Dizziness Handicap Inventory.

## 2.4. SPECT imaging analysis

SPECT studies were performed on the two chronic dizziness patient groups using a dual-head gamma camera (Symbia E/4C, Canon Medical Systems, Otawara, Japan) with a low-energy, high-resolution collimator. Images were acquired for 21 min starting 10 min after intravenous injection of 600–740 MBq of Technetium-99m ethyl cysteinate dimer ( $^{99m}\text{Tc-ECD}$ ) while patients were lying down in the supine position with eyes closed in a dimly lit quiet room [19]. Projection data were collected in a  $128 \times 128$  matrix size with angular sampling of  $4^\circ$  (45 views per detector) and continuous mode acquisition (6 rotations and 210 s per rotation). The data were then reconstructed into transaxial images using filtered back-projection with Butterworth filtering (order 8, cut-off 0.34 cycles/cm). Attenuation correction was performed using Chang's method (attenuation coefficient,  $0.15 \text{ cm}^{-1}$ ). Thereafter, SPECT images of each patient group were compared to those with age-matched controls prepared in advance that consisted of 70 healthy subjects, including a middle-aged group (40–59 years of age, 19 men and 11 women) and an older age group (60–69 years of age, 18 men and 22 women) [19,20].

Voxel-based group comparisons of SPECT data between the patient and the control groups were performed using Statistical Parametric Mapping 8 (SPM8) (Wellcome Department of Cognitive Neurology, London, UK) (<http://www.fil.ion.ucl.ac.uk/spm/>) [21] and MATLAB version R2013a (MathWorks Inc., Natick, MA, USA). The patient SPECT images were spatially normalized using SPM8 to the  $^{99m}\text{Tc-ECD}$  template, which was included in the easy Z-score imaging system (eZIS; FUJIFILM Toyama Chemical Co., Ltd., Tokyo, Japan) [19,20,22] for analysis of brain perfusion SPECT images. The process was performed with a 12-parameter affine transformation and 16 nonlinear iteration algorithms. The normalized images were resliced onto the Montreal Neurological Institute (MNI) coordinates in  $2 \times 2 \times 2 \text{ mm}^3$  voxels, and then smoothed using a three-dimensional isotropic Gaussian kernel with a full width at half maximum (FWHM) of 12 mm, and the brain mask was applied as in the eZIS process. Student's t-map of the patient images compared with the control data (images of mean and standard deviation, spatially normalized using the same ECD template as the patients) attached in the eZIS program was computed with in-house MATLAB scripts. The effect of global differences in cerebral blood flow between images was removed by proportional scaling.

## 3. Results

### 3.1. Study patients and their characteristics

The clinical characteristics of the patients are summarized in Table 1. In 12 patients with post-LMI dizziness (MI group), right- and left-sided lesions were observed in five and seven patients, respectively. The mean age of the MI group patients was 53.0 years, and the percentage of women was 33.3%. The mean duration of dizziness in these patients was the same as the elapsed time from LMI onset and was 13.0 months. The mean DHI scores were 51.3. In contrast, among 23 patients with chronic dizziness without currently active vestibular imbalance (CD group), 19 patients had preceding episodes of acute vestibular disorders that triggered chronic dizziness; nine patients had preceding vestibular disorders having benign paroxysmal positional vertigo, eight displayed vestibular neuritis, one presented Ramsay Hunt syndrome, and another had Ménière's disease. The preceding vestibular disorders at the time of participation in the study were confirmed to have already improved without sequelae using neuro-otologic vestibular tests. The mean age of the CD group patients was 69.0 years, and the percentage of women was 60.9%. The mean duration of dizziness was 15.4 months, and the mean DHI scores were 50.4.

There was no significant difference in the sex ratio, duration (months), or degree (DHI score) of dizziness between the MI and CD groups. However, the mean age was significantly higher in the CD group

( $p < 0.001$ ) (Table 1).

### 3.2. Changes in regional cerebral blood flow in patients with chronic dizziness compared to healthy subjects

Compared with the age-matched healthy controls [19,20], patients in the MI group showed a significant relative decrease in rCBF in the occipital lobe, including the left lingual gyrus, inferior occipital gyrus, and cuneus, and right middle occipital gyrus and cuneus (Table 2, Fig. 1). Moreover, they showed a significant relative increase in rCBF in the insula and temporal lobe, including the right parahippocampal gyrus, superior temporal gyrus, and uncus, and left insula (Table 2, Fig. 1). According to a previous report [12], we also evaluated SPECT data of MI group of patients flipped to one particular side; to have all lesions on the same side; the data of patients with left-sided lesions were flipped before normalization to the right [12]. The pattern of rCBF changes in patients in the MI group with same-sided lesions (original right-sided lesion + left-sided lesion flipped to the right side) was similar to that in the original data (Supplement 1).

Patients in the CD group showed a significant relative decrease in rCBF in the occipital lobe, including the bilateral lingual gyrus and cuneus, compared with the healthy control database. In addition, rCBF in the right precuneus, and left superior temporal gyrus and insula was also decreased (Table 3, Fig. 2). Moreover, patients in the CD group showed a significant relative increase in rCBF in the temporal and frontal lobes, including the right parahippocampal gyrus, fusiform gyrus, middle temporal gyrus, and medial frontal gyrus, and left middle temporal gyrus and medial frontal gyrus. rCBF in the right deep cerebral gray matter, including the thalamus, lentiform nucleus, and caudate, was also increased (Table 3, Fig. 2).

When the differences were compared with healthy controls, decreased blood flow in the occipital cortex and increased blood flow in the medial and inferior parts of the temporal cortex were almost similar in the two groups. Interestingly, decreased rCBF in the perisylvian cortex and increased rCBF in the frontal cortex were only observed in patients in the CD group.

## 4. Discussion

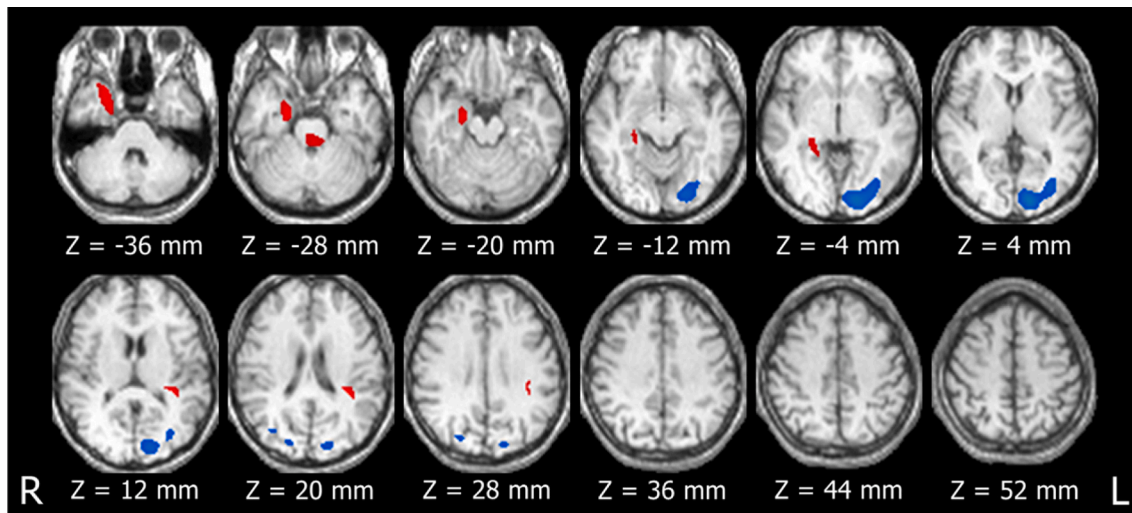
Our study is the first to show the difference between rCBF changes in patients having chronic dizziness due to persistent actual vestibular

**Table 2**

Location and peaks of significant changes in regional cerebral blood flow in chronic post-lateral medullary infarction dizziness patients compared to healthy controls.

rCBF changes	Cluster size (voxels)	t value	MNI-coordinates			Regions
			X	Y	Z	
MI < HC	1763	8.21	-14	-90	2	Left lingual gyrus
		6.51	-32	-80	-2	Left inferior occipital gyrus
	119	5.17	-16	-86	24	Left cuneus
		5.10	38	-72	24	Right middle occipital gyrus
MI > HC	742	5.04	26	-80	26	Right cuneus
		6.47	22	-10	-26	Right parahippocampal gyrus
	169	6.28	26	12	-40	Right superior temporal gyrus
		5.92	24	-2	-42	Right uncus
		6.24	-36	-40	18	Left insula
		135	5.27	26	-36	-6

rCBF, regional cerebral blood flow; MI, chronic post-lateral medullary infarction patients; HC, healthy controls.



**Fig. 1.** Decreased (blue) and increased (red) regional cerebral blood flow in patients with chronic post-lateral medullary infarction dizziness compared with healthy controls.

$T > 4.5$  (height  $p < 0.00001$  without correction of multiple comparison) areas are shown with an extent  $>100$  voxels. (For interpretation of the references to colour in this figure legend, the reader is referred to the web version of this article.)

**Table 3**

Location and peaks of significant changes in regional cerebral blood flow in chronic dizziness patients without currently active vestibular imbalance patients compared to healthy controls.

rCBF changes	Cluster size (voxels)	t value	MNI-coordinates			Regions
			X	Y	Z	
CD < HC	7031	8.62	-10	-86	4	Left lingual gyrus
			-22	-82	38	Left cuneus
			4	-102	-8	Right lingual gyrus
			22	-84	20	Right cuneus
			-50	-24	-4	Left superior temporal gyrus
161	6.50	-54	-32	22	Left insula	
					18	-56
CD > HC	277	7.77	-24	34	-22	Left medial frontal gyrus (orbitofrontal cortex)
						14
648	7.55	7.48	50	-4	-32	Right fusiform gyrus
						66
3012	7.28	6.53	24	-10	-26	Right parahippocampal gyrus
						7.13
3004	7.13	6.95	12	42	-26	Right medial frontal gyrus (orbitofrontal cortex)
						6.20
187	6.95	5.62	22	10	10	Right lentiform nucleus

rCBF, regional cerebral blood flow; CD, chronic dizziness patients without currently active vestibular imbalance; HC, healthy controls.

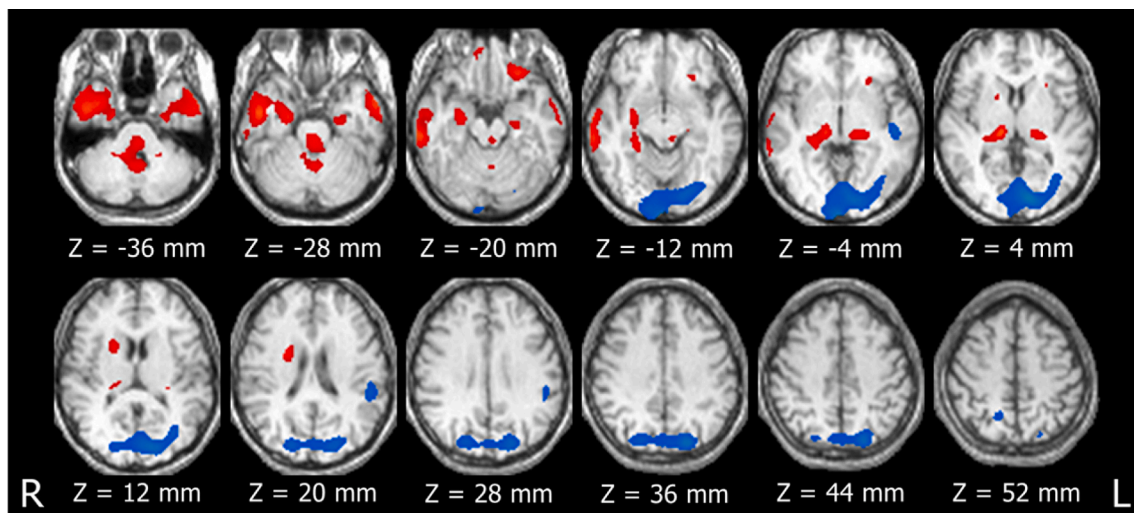
imbalance and those where chronic dizziness persisted without currently active vestibular imbalance. Decreased occipital lobe rCBF and increased medial and inferior temporal lobe rCBF were commonly seen in chronic dizziness patients in the presence or absence of vestibular imbalance. However, decreased perisylvian rCBF and increased frontal lobe rCBF were only observed in patients having chronic dizziness even in absence of causative vestibular imbalance.

#### 4.1. Chronic dizziness patients with persisting brainstem vestibular imbalance

In the acute stage of peripheral vestibular disorders, loss of unilateral vestibular input leads to brainstem vestibular nuclear imbalance. Brainstem vestibular imbalance is also produced during artificial unilateral vestibular stimulation. Such vestibular imbalance generates abnormal ascending vestibular signals to the cerebrum, resulting in increased activity in the perisylvian vestibular related cortices, including the parieto-insular vestibular cortex (PIVC), and decreased activity in the visual cortex [23,24]. These cerebral changes are explained by a reciprocal inhibitory visual-vestibular interaction that prevents potential intersensory mismatch [25].

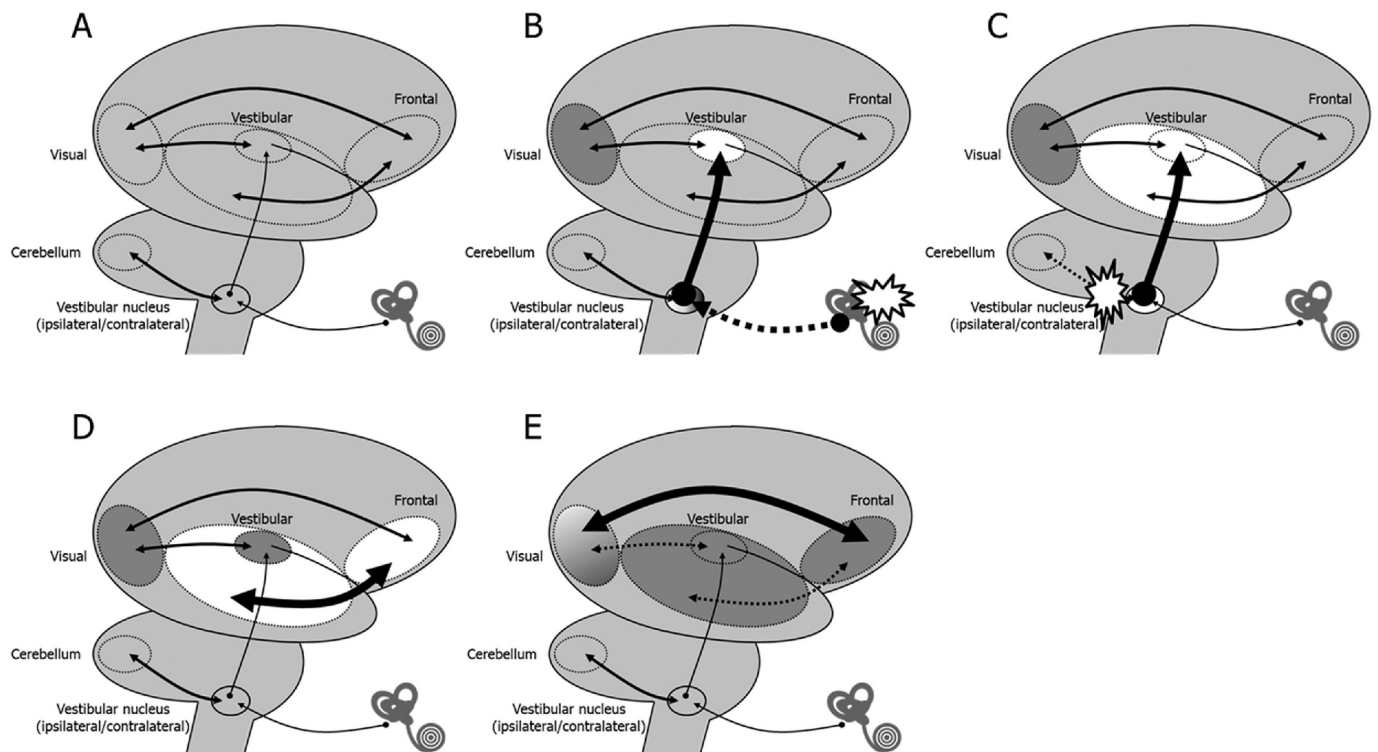
In this study, MI group patients had a brainstem vestibular imbalance in which the brainstem vestibular function on the affected side was abnormally amplified which could be due to disinhibition from the cerebellum [9,10]. Such brainstem vestibular imbalance can produce abnormal ascending vestibular signals to the cerebrum, unlike most other LMIs in which the abnormal ascending vestibular signals are relatively weak [12,26]. Furthermore, unlike peripheral vestibular disorders usually compensated immediately by the brainstem-cerebellar compensation mechanism [4,5], the abnormal ascending vestibular signals in the patients in the MI group in the present study had lasted for a prolonged time. The long-lasting abnormal vestibular signals were confirmed by the persisting characteristic nystagmus [9,10]. Thus, the decreased occipital lobe rCBF and increased insular rCBF in those patients were thought to be a result of long-lasting abnormal ascending vestibular inputs. This might explain the similarity of cerebral activity change pattern of increased rCBF in perisylvian vestibular related cortices and decreased rCBF in the visual cortex in the MI group patients to those in acute peripheral vestibular disorders or during artificial vestibular stimulation as reported previously [23,24] (Fig. 3).

In acute vestibular neuritis, increased activity of the perisylvian vestibular related cortices was observed mainly in the contralateral side [23]. However, despite the presence of slightly more left-sided lesions, increased rCBF in the insula was seen predominantly on the left side of the MI group patients' cortices. Although the dominance of the human vestibular cortex is suggested to be in the right (non-dominant) hemisphere [24], left-side dominant activity changes in vestibular related cortices were reported in patients with chronic dizziness [27,28]; however, in such cases, the activities were not increased but decreased.



**Fig. 2.** Decreased (blue) and increased (red) regional cerebral blood flow in patients with chronic dizziness without currently active vestibular imbalance compared with healthy controls.

$T > 4.5$  (height  $p < 0.00001$  without correction of multiple comparison) areas are shown with an extent  $>100$  voxels. (For interpretation of the references to colour in this figure legend, the reader is referred to the web version of this article.)



**Fig. 3.** Schematic diagrams of the cortex explaining hypothesis of changes in cerebral blood flow in chronic dizziness.

A) Normal state.

B) Acute peripheral vestibular disorders.

Ascending abnormal vestibular inputs increases the activity of the perisylvian vestibular related cortices, which leads to occipital lobe hypoactivity.

C) Chronic post-lateral medullary infarction dizziness.

Long-lasting abnormal vestibular inputs cause hyperactivity in the medial and inferior parts of the temporal lobe hyperactivity, which reflects persistent dizziness perception.

D) Chronic dizziness without currently active vestibular disorders.

Temporal lobe hyperactivity, similar to that in chronic post-lateral medullary infarction dizziness, occurs despite the absence of abnormal vestibular inputs. Frontal lobe hyperactivity may be a trigger or cause of temporal lobe hyperactivity and dizziness chronicity.

E) Persistent postural-perceptual dizziness.

Postural control, emotional control, and decision making to the perceived spatial orientation become unresponsive and stiffened over time, and frontal and temporal lobe activity decreases.

Vestibular signal processing in vestibular-related cortices seemed to occur on both sides.

In the MI group patients, increased rCBF was extended not only to the perisylvian vestibular related cortices, such as the PIVC, but also to the medial and inferior parts of the temporal lobe, including the parahippocampal gyrus. The parahippocampal gyrus plays an important role in spatial cognition and analysis [29]. As dizziness is the sensation of disturbed or impaired spatial orientation [30], the association between persistent dizziness and hyperactivity in such spatial processing areas might be rational (Fig. 3).

#### 4.2. Chronic dizziness patients without currently active vestibular imbalance

In the CD group, occipital lobe rCBF was found to decrease, like that of the MI group patients. Such a decrease in occipital lobe activity was similar to that observed in acute peripheral and central vestibular disorders [12,23]. Decreased occipital lobe activity may be a common characteristic in patients with dizziness, regardless of the duration of dizziness, and the presence of active vestibular imbalance. On the contrary, unlike the MI group, rCBF in the perisylvian vestibular related cortices, such as the PIVC, was decreased in the CD group (Fig. 3). A decrease in rCBF in vestibular-related cortices was also reported earlier in PPPD patients who had no active vestibular disorders [28]. Decreased activity in these vestibular-related cortices in chronic dizziness without currently active vestibular imbalance, such as PPPD, is thought to reflect an abnormal adaptation in which the priority shifts from vestibular information to other sensory information in processing spatial orientation information [3]. Patients with CD in our study might also have such abnormal adaptations.

rCBF in the patients in the CD group was found to increase in the medial and inferior parts of the temporal lobe, including the parahippocampal gyrus. Increased rCBF in these spatial processing areas was also observed in patients in the MI group who had persistent vestibular imbalance. Taken together, an increase in activity in these spatial processing areas might occur during the persistence of dizziness regardless of the presence of actual vestibular imbalance. Increased activity in the temporal lobe, including the parahippocampal gyrus, might be related to keeping dizziness perception triggered rather than the result of persistent vestibular imbalance because it occurred even in chronic dizziness without active vestibular imbalance (Fig. 3).

Increased rCBF was also seen in the frontal lobe, especially in the bilateral orbitofrontal cortex, in the CD group patients. The orbitofrontal cortex is a multifunctional area involved in sensory integration, mood control, decision making, and expectation. It links multimodal sensory information with emotions and decision making [31,32]. It cannot be denied that chronic dizziness, that is, distorted spatial information, might adversely affect emotions and decision-making. However, since frontal lobe rCBF did not increase in the patients in the MI group with chronic dizziness in presence of actual vestibular imbalance, the increase in the same in the patients in the CD group might be the cause of chronic dizziness rather than the result. Increased frontal lobe activity might distort spatial information and lead to medial and inferior temporal lobe hyperactivity, thereby, triggering dizziness perception (Fig. 3).

Although our CD group patients could not be diagnosed with PPPD, their characteristics were similar to those of PPPD in that they had chronic dizziness without currently active vestibular disorders. Actually, 78% of our CD group patients met the diagnostic criteria for PPPD, when retrospectively applied the criteria. In PPPD patients, frontal lobe rCBF has been reported to be decreased [28], in contrast to our findings where increased frontal lobe rCBF in patients with CD was observed. Decreased frontal lobe activity in chronic subjective dizziness whose clinical characteristics largely overlap with PPPD [13,17] has also been indicated by functional MRI [33]. The main difference in clinical features between these previously reported chronic dizziness patients and

patients in the CD group in our study was the duration of dizziness. The duration of dizziness in the previously reported patients was approximately 3 years, whereas that in the patients in the CD group in this study was about a year. Based on this duration difference, we assume that, when dizziness persists even after the disappearance of the causative vestibular disorder, the frontal lobe activity is increased in the early stage and decreased in the late stage. If frontal lobe hyperactivity is the cause or trigger rather than the result of persistent dizziness, our assumption of frontal lobe activity change might be probable. Increased activity in the frontal lobe, especially in the orbitofrontal cortex, is a characteristic of anxiety disorders [34,35], that may be a background factor in the development of dizziness persistence after improvement of the causative vestibular imbalance [15]. Increased activity in the frontal lobe was also reported to be observed in transient Mal de Debarquement syndrome, that is, self-motion sensation after passive movement exposure such as sea travel [36]. Frontal lobe activation in Mal de Debarquement syndrome may also be a trigger for dizziness persistence after disembarking.

It is unclear why frontal lobe activity decreases [28] in PPPD patients having a sufficient duration of dizziness. Unlike the CD patients in our study, the medial and inferior parts of the temporal lobe activity were also found to decrease despite increased frontal and occipital lobe connectivity in reported PPPD patients (Fig. 3) [27]. This decreased cerebral activity was thought to reflect the failure of postural control, emotional control, and decision-making to the perceived spatial orientation [3,28]. These factors might become unresponsive and stiffened over time. If so, the timing of the treatment for PPPD patients should be initiated earlier, before the cerebral activity might burn out.

#### 4.3. Limitations

This being a cross-sectional study, the causality between the cerebral perfusion changes and chronic dizziness could not be established. It was also limited by the small number of patients included in the study despite the long study period. One of the reasons for this was that patients who did not consent to the SPECT study were not included. Our CD group patients may be heterogeneous because the diagnostic criteria for PPPD were not established when the study was initiated. SPECT data of healthy controls were not simultaneously obtained, but the data was prepared in advance, the data usage was already established. Positron emission tomography (PET) measurements might be more suitable for the quantitative evaluation of regional neural activity. Functional MRI evaluations with better spatial resolutions should be included. Although psychological status might affect rCBF, we did not quantitatively assess the anxiety and depression symptoms of the patients.

#### 5. Conclusion

The results of our study not only showed the difference between rCBF changes in persisting dizziness with and without actual vestibular imbalance, but also indicated a potential pathophysiologic mechanism of chronic dizziness. Increased activity in medial and inferior parts of the temporal lobe may be related to keeping dizziness perception triggered, and increased activity in the frontal lobe may act as the background for dizziness to persist even after the disappearance of vestibular imbalance.

#### Funding

This research did not receive any specific grant from funding agencies in the public, commercial, or not-for-profit sectors.

#### Ethics approval

This study was approved by the ethics committee of the Yokohama Brain and Spine Center (No. 141400701).

## Contributors

KJ conceived and designed the study and drafted the manuscript. KT, YK, SA, NH, SI, and KK collected the data. KJ, KT, and TS analyzed and interpreted the data. All authors critically reviewed the manuscript for important intellectual content and approved the final version for submission.

## Credit author statement

Ken Johkura conceived and designed the study and drafted the manuscript. Koji Takahashi, Yosuke Kudo, Shinobu Asakawa, Nami Hasegawa, Shizuho Imamichi, and Kiyokazu Kurihara collected the data. Ken Johkura, Koji Takahashi, and Tsutomu Soma analyzed and interpreted the data. All authors critically reviewed the manuscript for important intellectual content and approved the final version for submission.

Double-headed arrows indicate estimated interactions.

## Declaration of Competing Interest

The authors have no conflicts of interest to disclose.

## Appendix A. Supplementary data

Supplementary data to this article can be found online at <https://doi.org/10.1016/j.ensci.2021.100367>.

## References

- [1] N.A. Roussel, J. Nijs, M. Meeus, V. Mylius, C. Fayt, R. Oostendorp, Central sensitization and altered central pain processing in chronic low back pain: fact or myth? *Clin. J. Pain* 29 (2013) 625–638.
- [2] B. Langguth, P.M. Kreuzer, T. Kleinjung, D. De Ridder, Tinnitus: causes and clinical management, *Lancet Neurol.* 12 (2013) 920–930.
- [3] S. Popkirov, J.P. Staab, J. Stone, Persistent postural-perceptual dizziness (PPPD): a common, characteristic and treatable cause of chronic dizziness, *Pract. Neurol.* 18 (2018) 5–13.
- [4] A. Deveze, L. Bernard-Demanze, F. Xavier, J.P. Lavieille, M. Elziere, Vestibular compensation and vestibular rehabilitation. Current concepts and new trends, *Neurophysiol. Clin.* 44 (2014) 49–57.
- [5] T. Kitahara, N. Takeda, T. Saika, T. Kubo, H. Kiyama, Role of the flocculus in the development of vestibular compensation: immunohistochemical studies with retrograde tracing and flocculectomy using Fos expression as a marker in the rat brainstem, *Neuroscience* 76 (1997) 571–580.
- [6] R.L. Sacco, L. Fredro, J.A. Bello, J.G. Odel, S.T. Onesti, J.P. Mohr, Wallenberg's lateral medullary syndrome. Clinical-magnetic resonance imaging correlations, *Arch. Neurol.* 50 (1993) 609–614.
- [7] J.S. Kim, Pure lateral medullary infarction: clinical-radiological correlation of 130 acute, consecutive patients, *Brain* 126 (2003) 1864–1872.
- [8] G. Nelles, K.A. Contois, S.L. Valente, et al., Recovery following lateral medullary infarction, *Neurology* 50 (1998) 1418–1422.
- [9] K. Amari, Y. Kudo, K. Watanabe, et al., Spontaneous, headshaking, and positional nystagmus in post-lateral medullary infarction dizziness, *J. Neurol. Sci.* 368 (2016) 249–253.
- [10] K. Johkura, Y. Kudo, E. Sugawara, K. Watanabe, T. Nakamizo, M. Yamamoto, K. Amari, K. Takahashi, O. Tanaka, Effects of cerebellar magnetic stimulation on chronic post-lateral medullary infarction dizziness: a proof-of-principle cohort study, *J. Neurol. Sci.* 392 (2018) 56–62.
- [11] K.D. Choi, S.Y. Oh, S.H. Park, J.H. Kim, J.W. Koo, J.S. Kim, Head-shaking nystagmus in lateral medullary infarction: patterns and possible mechanisms, *Neurology* 68 (2007) 1337–1344.
- [12] S. Becker-Bense, H.G. Buchholz, C. Best, M. Schreckenberger, P. Bartenstein, M. Dieterich, Vestibular compensation in acute unilateral medullary infarction: FDG-PET study, *Neurology* 80 (2013) 1103–1109.
- [13] J.P. Staab, A. Eckhardt-Henn, A. Horii, R. Jacob, M. Strupp, T. Brandt, A. Bronstein, Diagnostic criteria for persistent postural-perceptual dizziness (PPPD): consensus document of the committee for the classification of vestibular disorders of the Bárány society, *J. Vestib. Res.* 27 (2017) 191–208.
- [14] G.P. Jacobson, C.W. Newman, The development of the dizziness handicap inventory, *Arch. Otolaryngol. Head Neck Surg.* 116 (1990) 424–427.
- [15] T. Brandt, Phobic postural vertigo, *Neurology* 46 (1996) 1515–1519.
- [16] A.M. Bronstein, Visual vertigo syndrome: clinical and posturography findings, *J. Neurol. Neurosurg. Psychiatry* 59 (1996) 472–476.
- [17] J.P. Staab, M.J. Ruckenstein, J.D. Amsterdam, A prospective trial of sertraline for chronic subjective dizziness, *Laryngoscope* 114 (2004) 1637–1641.
- [18] R.G. Jacob, M.S. Redfern, J.M. Furman, Space and motion discomfort and abnormal balance control in patients with anxiety disorders, *J. Neurol. Neurosurg. Psychiatry* 80 (2009) 74–78.
- [19] H. Matsuda, S. Mizumura, T. Nagao, T. Ota, T. Iizuka, K. Nemoto, N. Takemura, H. Arai, A. Homma, Automated discrimination between very early Alzheimer disease and controls using an easy Z-score imaging system for multicenter brain perfusion single-photon emission tomography, *AJNR Am. J. Neuroradiol.* 28 (2007) 731–736.
- [20] S. Mizumura, S. Kumita, Stereotactic statistical imaging analysis of the brain using the easy Z-score imaging system for sharing a normal database, *Radiat. Med.* 24 (2006) 545–552.
- [21] K.J. Friston, Analyzing brain images: principles and overview, in: Frackowiak RSJ, K.J. Friston, C.D. Frith (Eds.), *Human Brain Function*. San Diego, Calif: Academic Press, 1997, pp. 25–41.
- [22] H. Kanetaka, H. Matsuda, T. Asada, T. Ohnishi, F. Yamashita, E. Imabayashi, F. Tanaka, S. Nakano, M. Takasaki, Effects of partial volume correction on discrimination between very early Alzheimer's dementia and controls using brain perfusion SPECT, *Eur. J. Nucl. Med. Mol. Imaging* 31 (2004) 975–980.
- [23] S. Bense, P. Bartenstein, M. Lochmann, P. Schindwein, T. Brandt, M. Dieterich, Metabolic changes in vestibular and visual cortices in acute vestibular neuritis, *Ann. Neurol.* 56 (2004) 624–630.
- [24] M. Dieterich, S. Bense, S. Lutz, A. Drzezga, T. Stephan, P. Bartenstein, T. Brandt, Dominance for vestibular cortical function in the non-dominant hemisphere, *Cereb. Cortex* 13 (2003) 994–1007.
- [25] T. Brandt, P. Bartenstein, A. Janek, M. Dieterich, Reciprocal inhibitory visual-vestibular interaction. Visual motion stimulation deactivates the parieto-insular vestibular cortex, *Brain* 121 (1998) 1749–1758.
- [26] M. Dieterich, T. Brandt, Functional brain imaging of peripheral and central vestibular disorders, *Brain* 131 (2008) 2538–2552.
- [27] J.O. Lee, E.S. Lee, J.S. Kim, Y.B. Lee, Y. Jeong, B.S. Choi, J.H. Kim, J.P. Staab, Altered brain function in persistent postural perceptual dizziness: a study on resting state functional connectivity, *Hum. Brain Mapp.* 39 (2018) 3340–3353.
- [28] S. Na, J.J. Im, H. Jeong, E.S. Lee, T.K. Lee, Y.A. Chung, I.U. Song, Cerebral perfusion abnormalities in patients with persistent postural-perceptual dizziness (PPPD): a SPECT study, *J. Neural Transm. (Vienna)* 126 (2019) 123–129.
- [29] R. Epstein, N. Kanwisher, A cortical representation of the local visual environment, *Nature* 392 (6676) (1998) 598–601.
- [30] A. Bisdorff, M. Von Brevern, T. Lempert, D.E. Newman-Toker, Classification of vestibular symptoms: towards an international classification of vestibular disorders, *J. Vestib. Res.* 19 (2009) 1–13.
- [31] M.L. Kringelbach, The human orbitofrontal cortex: linking reward to hedonic experience, *Nat. Rev. Neurosci.* 6 (2005) 691–702.
- [32] D. Ongür, J.L. Price, The organization of networks within the orbital and medial prefrontal cortex of rats, monkeys and humans, *Cereb. Cortex* 10 (2000) 206–219.
- [33] I. Indovina, R. Riccelli, G. Chiarella, C. Petrolo, A. Augimeri, L. Giofrè, F. Lacquaniti, J.P. Staab, L. Passamonti, Role of the insula and vestibular system in patients with chronic subjective dizziness: an fMRI study using sound-evoked vestibular stimulation, *Front. Behav. Neurosci.* 9 (2015) 334.
- [34] L.R. Baxter Jr., M.E. Phelps, J.C. Mazziotta, B.H. Guze, J.M. Schwartz, C.E. Selin, Local cerebral glucose metabolic rates in obsessive-compulsive disorder. A comparison with rates in unipolar depression and in normal controls, *Arch. Gen. Psychiatry* 44 (1987) 211–218.
- [35] A.V. Chavanne, O.J. Robinson, The overlapping neurobiology of induced and pathological anxiety: a Meta-analysis of functional neural activation, *Am. J. Psychiatry* 178 (2021) 156–164.
- [36] S.H. Jeon, Y.H. Park, S.Y. Oh, J.J. Kang, Y.H. Han, H.J. Jeong, J.M. Lee, M. Park, J. S. Kim, M. Dieterich, Neural correlates of transient mal de Debarquement syndrome: activation of prefrontal and deactivation of cerebellar networks correlate with neuropsychological assessment, *Front. Neurol.* 11 (2020) 585.