

# Tranexamic Acid Controlled Chronic Disseminated Intravascular Coagulation Associated with Aortic Dissection and Patent False Lumen for Three Years

Yodo Gatate, Nobuyuki Masaki, Atsushi Sato, Risako Yasuda, Takayuki Namba, Hiroataka Yada, Akio Kawamura and Takeshi Adachi

---

## Abstract

---

The management of chronic disseminated intravascular coagulation (DIC) caused by aortic dissection has not yet been established. Even in cases where surgical correction is performed, therapeutic control of systemic hemorrhaging is still required. We herein report the successful treatment of a case of aortic dissection with a patent false lumen using tranexamic acid for acute exacerbation of chronic DIC. Oral administration of 1,500 mg tranexamic acid per day stabilized the coagulative and fibrinolytic parameters and relieved bleeding tendencies with no side effects. Heparin was administered periodically for the management of hemodialysis. This favorable result continued for up to 3 years.

**Key words:** disseminated intravascular coagulation, aortic dissection, tranexamic acid

(Intern Med 56: 925-929, 2017)

(DOI: 10.2169/internalmedicine.56.7499)

---

## Introduction

---

Disseminated intravascular coagulation (DIC) of aortic dissection occurs due to the chronic expansion of the false lumen, leading to exposure of the sub-endothelial collagen tissue and stagnation of a high volume of blood in the false lumen. This activates extrinsic tissue factors and intrinsic coagulation factors, and a thrombus is formed in the false lumen. As a result, secondary fibrinolysis is induced, and numerous coagulation factors are continuously consumed in the lumen.

The management of patients becomes extremely difficult once this type of DIC has occurred. Closing the false lumen with open or endovascular surgery is a radical cure for this condition; however, a high risk of bleeding exists during surgery, and the necessity of appropriate control with drugs is inevitable regardless of the treatment of choice. Furthermore, surgery is not indicated for some patients with aortic dissection because of age, health condition, or disease background. There are three therapeutic strategies for aortic DIC: anti-coagulation therapy (1, 2), anti-fibrinolytic therapy

(3, 4), and combination therapy (5). The effects of these therapies are opposing-prevention of thrombus versus generating them-but the main purpose of these therapies is to stop the consumption of systemic coagulation factors, fibrinogen, and platelets and the development of further bleeding by blocking the cycle of thrombus formation and destruction. Thus far, however, there have been no definitive guidelines for therapy selection (6, 7).

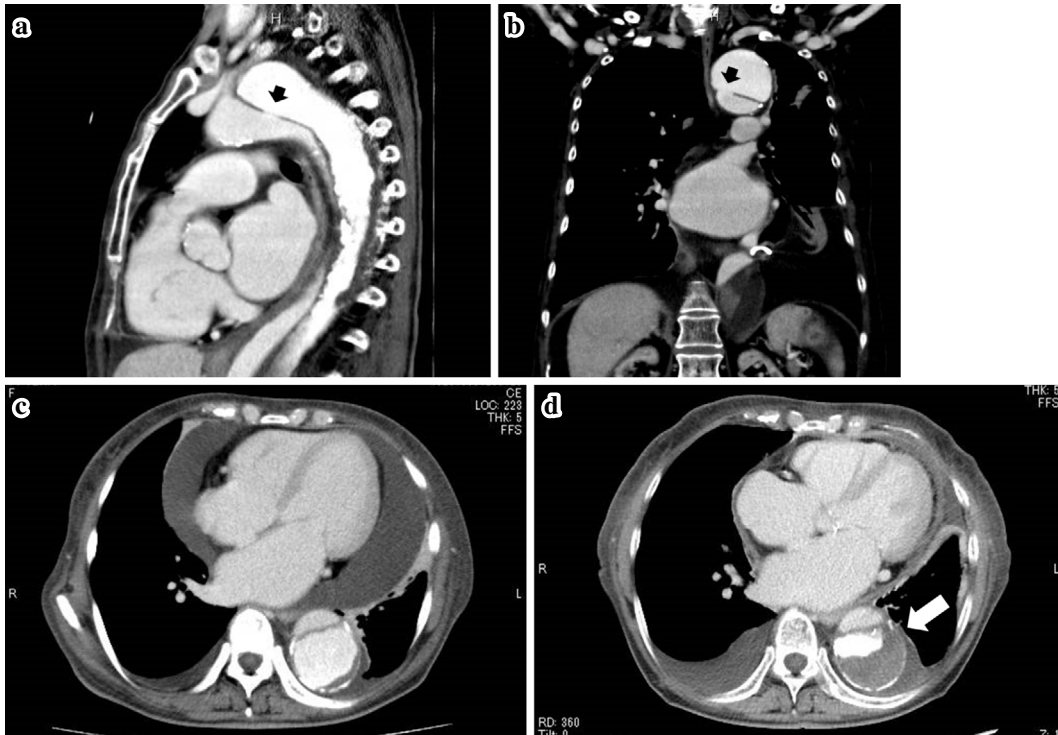
We herein report an inoperable case treated with anti-fibrinolytic therapy with tranexamic acid for up to three years. Although the usefulness of tranexamic acid for DIC caused by aortic dissection has been reported as an alternative treatment to surgical repair (4, 5) and for preoperative control of bleeding complications (8), few articles have discussed the long-term safety and outcomes with this regimen. Therefore, we believe this report will help further clarify potential treatments for this uncommon disorder.

---

## Case Report

---

A 71-year-old woman had developed (Stanford type B) aortic dissection with a patent false lumen extending from



**Figure 1.** Images of enhanced CT. Enhanced CT was taken before discharge (a-c) and one year later (d). The entry of the false lumen is indicated by black arrows (a, b). The distal re-entry is located at the bifurcation of the iliac arteries. Thrombus formation (white arrow) developed within 1 year, but the false lumen remained open (c, d). CT: Computed tomography

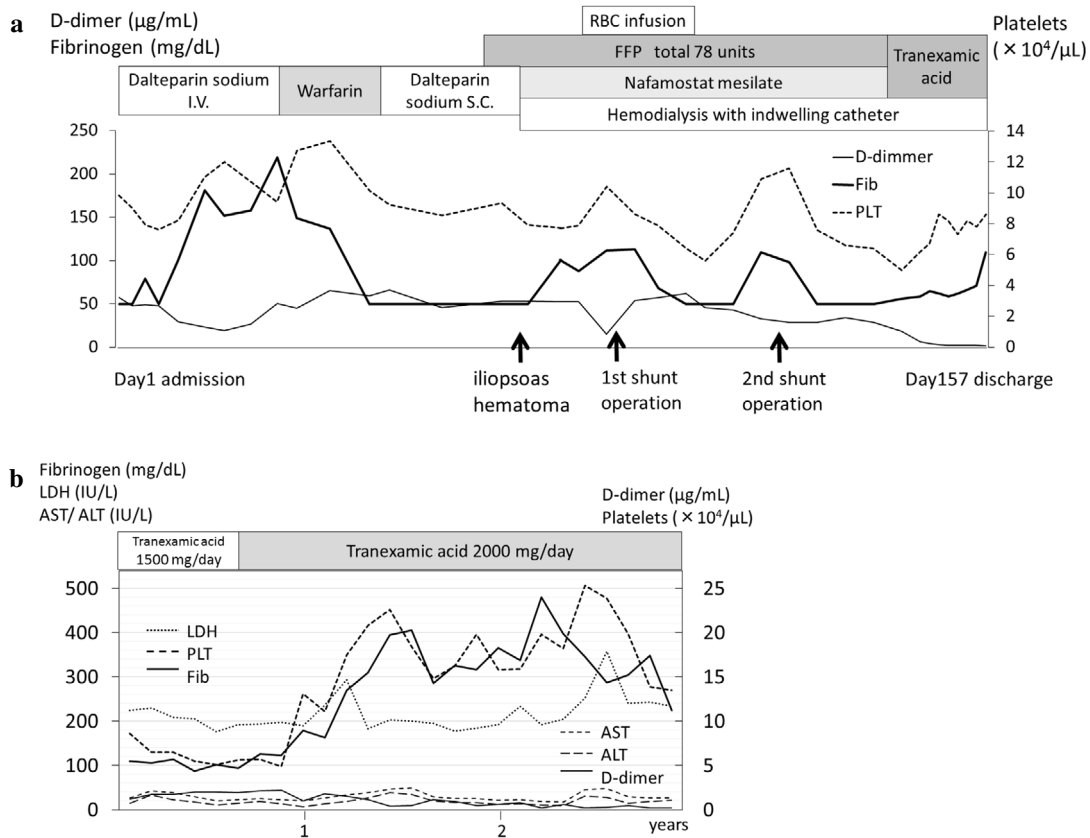
the left subclavian artery to the left and right femoral arteries 12 years prior and was being treated conservatively. She had a medical history of a cholecystectomy for cholelithiasis at age 56. In November 2012, she complained of recurrent oral hemorrhaging, purpura, malaise, and nausea. She was conscious and alert with a body temperature of 36.2 °C, heart rate of 64 beats/min, and blood pressure of 122/72 mmHg. A chest radiograph showed dilatation of the mediastinum and heart. A 12-lead electrocardiogram showed no specific changes. Computed tomography (CT) showed dilatation of the aortic false lumen with pleural effusion and a moderate amount of pericardial effusion (Fig. 1a-c). Laboratory measurements revealed a low platelet count and active secondary fibrinolysis [platelets 98,000/ $\mu$ L, D-dimer 57.6  $\mu$ g/mL, plasmin- $\alpha$ 2 plasmin inhibitor complex (PIC) 9.1  $\mu$ g/mL (normal range <0.8  $\mu$ g/mL), thrombin-antithrombin complex (TAT) 60.0 ng/dL (normal range <3.0 ng/dL)]. Her coagulation time was slightly prolonged. The international normalized ratio of prothrombin time (PT-INR) and activated partial thromboplastin time (APTT) were 1.37 and 33.0 s, respectively. The fibrinogen levels had decreased to  $\leq$  50 mg/dL, which is the lower limit of measurement. Additional tests, including a bone marrow examination and gastrointestinal and colon fiberoptic, demonstrated no evidence of hematologic disease, allergy, or malignancy, any of which could cause DIC.

We suspected that the hemorrhage might have resulted from the consumption of systemic coagulation factors after

activation of coagulation and fibrinolysis in the false lumen of the aorta. In addition to the above, she had terminal-stage renal failure, which was caused by severe atherosclerosis combined with the obstruction of the renal blood flow due to the aortic dissection. She had symptoms of hyperuricemia, such as malaise and nausea (serum creatinine level 5.41 mg/dL), and pericardial effusion caused by uremia, which required pericardiocentesis. Therefore, both medical problems had to be treated at the same time to improve her condition.

Intravenous infusion of low-molecular-weight heparin (LMWH), dalteparin sodium, at 5,000 units per day improved the DIC (Fig. 2a). Subsequently, we switched her to warfarin, considering the use of the medication after discharge. However, warfarin was not effective and worsened the DIC. We then tried subcutaneous administration of LMWH at 5,000 units twice a day. Her antithrombin level decreased to 58%, so antithrombin was transfused. Her APTT was controlled within 40 to 80 s, but she developed an iliopsoas muscle hematoma. T2-weighted magnetic resonance imaging (MRI) showed cerebral microbleeding. For these reasons, we exchanged LMWH for continuous infusion of nafamostat mesilate. The dose was gradually increased from 70 to 190 mg per day. At the same time, hemodialysis was initiated for progressive renal dysfunction using a temporary catheter.

On Day 72 after admission, the first shunt operation was performed in the patient's right forearm. Two units of



**Figure 2.** Time-course of treatment. Treatments (a) in the hospital and (b) at the outpatient clinic. The patient was successfully treated and discharged after 157 days of hospitalization. Briefly, the consumption of coagulation factors and fibrinogen could be not suppressed by anti-coagulation therapies except by continuous infusion of dalteparin. However, once bleeding occurred, it was difficult to resume infusion. The patient developed two hematomas after using FFP prior to shunt operations. Nevertheless, tranexamic acid quickly improved her condition. After discharge, her symptoms remain controlled with 2,000 mg of tranexamic acid per day. RBCs: red blood cells, Fib: fibrinogen, PLTs: platelets, FFP: freshly frozen plasma, I.V.: intravenous administration, S.C.: subcutaneous administration. AST: aspartate aminotransferase, ALT: alanine aminotransferase, LDH: lactate dehydrogenase

freshly frozen plasma (FFP) were infused in advance of the surgery. However, this caused persistent bleeding of the wound, and the shunt ultimately closed a few days after surgery because of compression from the hematoma. After the patient recovered from the hemorrhaging, the second surgery was performed on her left wrist on Day 120. In advance of surgery, we used FFP transfusion and intravenous administration of nafamostat mesilate 190 mg per day to maintain a sufficient level of platelets and plasma fibrinogen to prevent bleeding. Nevertheless, a new hematoma developed which again compressed the shunt flow and postponed its use for several months. Therefore, we had to implant an additional long-term indwelling catheter. She also simultaneously developed a retroperitoneal hematoma. Thus, her DIC became resistant to anticoagulation therapy, and she required a total of 78 units of FFP throughout hospitalization.

Although a radical cure could have been achieved by open surgery or an endovascular stent, we decided that this was not possible because of the high risk of bleeding. Be-

cause of the events described above, we decided to cease all anticoagulation therapy and FFP transfusion and instead started the patient on oral tranexamic acid 1,500 mg per day to inhibit fibrinolysis and promote thrombus formation in the false lumen. Five days later, the fibrin degradation product levels returned to the normal range, and the fibrinogen level improved. CT demonstrated that patency of the false lumen remained, but the speed of contrast enhancement was delayed. She recovered from DIC and was discharged in April 2013, 157 days after admission.

At our outpatient clinic, self-injection of heparin was very difficult for the patient. Unfractionated heparin 4,000 units was administered 3 times a week for 4 hours to manage her hemodialysis. The dose of tranexamic acid was increased to 2,000 mg per day (Fig. 2b). Contrast-enhanced CT after one year demonstrated a further delay of blood flow and an increase in the mural thrombus in the false lumen; however, the lumen remained open (Fig. 1d). She was also followed up by surgery department to determine the timing of tho-

racic endovascular aortic repair (TEVAR). The patient's laboratory measurements were relatively unchanged at 3 years after discharge (total bilirubin 1.2 mg/dL, aspartate aminotransferase 27 IU/L, alanine aminotransferase 21 IU/L, lactate dehydrogenase 234 IU/L, gamma-glutamyl transpeptidase 28 IU/L, platelets 135,000/ $\mu$ L, D-dimer 0.2  $\mu$ g/mL, PIC 0.6  $\mu$ g/mL, TAT 4.7 ng/dL, PT-INR 1.21, APTT 30 s). She died at 1,285 days after discharge due to a bacterial infection of a wound in her lower extremities.

## Discussion

In general, DIC can be categorized into one of three types: suppressed-fibrinolytic-type, balanced-fibrinolytic-type, and enhanced-fibrinolytic-type (9). The suppressed-fibrinolytic-type DIC is characterized by widespread activation of coagulation, which results in intravascular formation of fibrin and eventually thrombotic occlusion of small- and medium-sized vessels. In this type of DIC, the inhibition of intrinsic fibrinolysis triggers systemic micro-embolisms, which are extremely harmful. In contrast, the enhanced-fibrinolytic-type DIC is characterized by enhancement of secondary fibrinolysis rather than coagulation. This type of DIC is reported in acute promyelocytic leukemia and Kasabach-Merritt syndrome. However, the combined use of all-trans retinoic acid and tranexamic acid increased the mortality rate in cases of DIC among acute promyelocytic leukemia patients (10).

DIC caused by aortic dissection is often classified as enhanced-fibrinolytic type. In cases of aortic dissection, thromboses are basically limited to the false lumen and are not seen elsewhere in the body. Therefore, the inhibition of fibrinolysis might be a reasonable step to take, because it is advantageous to achieve closure of the false lumen containing a thrombus unless organ perfusion is disturbed. However, excessive tissue factor generated from agglutinated platelets, leukocytes, and damaged tissues may circulate in the blood (11). In an experimental model of enhanced-fibrinolytic-type DIC using infusion of tissue factor, tranexamic acid provoked organ failure by generating intravascular microthrombi (12). In such cases, anti-fibrinolytic therapy can produce microembolisms systemically, regardless of the original location of hypercoagulation (13, 14). Therefore, combination treatment with anti-coagulation therapy should incorporate tranexamic acid (9).

In the present case, sole subcutaneous LMWH administration was unable to control the DIC (Fig. 2a). We believe that anti-coagulation therapy cannot completely suppress the dynamic hypercoagulability that arises in the aortic false lumen if it has too great a volume with incessant flow. If systemic coagulation factors cannot be increased, continuation of high-dose heparin is dangerous and may cause bleeding complications elsewhere with aortic enlargement in the long term. Previously, hemorrhagic diathesis due to inadequate effect (15) and cerebral hemorrhaging (5) were reported during LMWH therapy for aortic DIC. Additionally, self-

injection of LMWH was difficult for the patient to continue in the long term. For these reasons, the patient received low-dose heparin only for hemodialysis, which was insufficient to control the aortic DIC. There were no adverse effects of tranexamic acid such as liver dysfunction or tremor, which occur particularly frequently in patients treated with hemodialysis. The progression of renal dysfunction (13, 14) could not be evaluated because she already had terminal-stage renal failure. Therefore, further investigations are necessary to assess the safety of our management technique.

Several therapeutic targets have been suggested. Fibrinogen was the most sensitive and reliable indicator for monitoring DIC, which quickly responded to changes in drugs (Fig. 2a). Fibrinogen levels were promptly recovered by tranexamic acid. Platelets were depleted following the reduction in fibrinogen. Nafamostat mesilate acts independently from antithrombin and is more effective in treating enhanced-fibrinolytic-type DIC than gabexate mesilate (16). Nevertheless, the effect was insufficient in our case. Warfarin was thought to increase the risk of bleeding by suppressing vitamin K-dependent coagulation factors without improving the DIC.

An ideal treatment regimen would involve direct inhibition of thrombin and activated factor X (Xa). Accordingly, Xa inhibitor has recently been suggested as an alternative to subcutaneous heparin administration for aortic DIC if renal function is retained (17-19). TEVAR is a radical way of curing the symptoms of DIC (20) and also reduces the aortic-specific mortality in the chronic phase (21). However, it could not be performed in the present patient due to the high operative risk.

Solo use of tranexamic acid is contraindicated for DIC associated with aortic dissection. However, our experience suggested that tranexamic acid combined with the minimal amount of heparin necessary for hemodialysis could be an optional treatment in patients unable to undergo an operation for aortic dissection and who also have end-stage renal failure but cannot continue subcutaneous self-injection of LMWH.

**The authors state that they have no Conflict of Interest (COI).**

## References

- Miyahara S, Yasu T, Yamada Y, Kobayashi N, Saito M, Momomura S. Subcutaneous injection of heparin calcium controls chronic disseminated intravascular coagulation associated with inoperable dissecting aortic aneurysm in an outpatient clinic. *Intern Med* **46**: 727-732, 2007.
- Togami K, Nagai Y, Arima H, et al. Successful treatment of chronic disseminated intravascular coagulation syndrome with continuous subcutaneous infusion of heparin using a mobile infusion pump: report of 2 cases. *Rinsho Ketsueki* **50**: 1700-1705, 2009 (in Japanese, Abstract in English).
- Mamiya S, Endo Y, Miura AB, Kanazawa T, Kuwayama A, Nishimura S. Disseminated intravascular coagulation accompanying thoracic and abdominal aortic aneurysm; report of three cases. *Jpn J Med* **27**: 91-95, 1988.

4. Tsuji T, Morikawa K, Hirano T, Yamasaki H, Tsuda H. Effective treatment with tranexamic acid for chronic disseminated intravascular coagulation associated with aortic dissection. *Rinsho Ket-sueki* **54**: 769-771, 2013 (in Japanese, Abstract in English).
5. Kimura S, Odawara J, Aoki T, et al. Use of tranexamic acid for disseminated intravascular coagulation with excessive fibrinolysis associated with aortic dissection in a patient with chronic renal failure. *Int J Hematol* **89**: 549-552, 2009.
6. Hiratzka LF, Bakris GL, Beckman JA, et al. 2010ACCF/AHA/AATS/ACR/ASA/SCA/SCAI/SIR/STS/SVM Guidelines for the diagnosis and management of patients with thoracic aortic disease. *J Am Coll Cardiol* **55**: e27-e129, 2010.
7. Levi M, Toh CH, Thachil J, Watson HG. Guidelines for the diagnosis and management of disseminated intravascular coagulation. British Committee for Standards in Haematology. *Br J Haematol* **145**: 24-33, 2009.
8. Casati V, Sandrelli L, Speziali G, Calori G, Grasso MA, Spagnolo S. Hemostatic effects of tranexamic acid in elective thoracic aortic surgery: a prospective, randomized, double-blind, placebo-controlled study. *J Thorac Cardiovasc Surg* **123**: 1084-1091, 2002.
9. Asakura H. Classifying types of disseminated intravascular coagulation: clinical and animal models. *J Intensive Care* **2**: 20, 2014.
10. Hashimoto S, Koike T, Tatewaki W, et al. Fatal thromboembolism in acute promyelocytic leukemia during all-trans retinoic acid therapy combined with antifibrinolytic therapy for prophylaxis of hemorrhage. *Leukemia* **8**: 1113-1115, 1994.
11. Rapaport SI. Blood coagulation and its alterations in hemorrhagic and thrombotic disorders. *West J Med* **158**: 153-161, 1993.
12. Asakura H, Sano Y, Yamazaki M, Morishita E, Miyamoto K, Nakao S. Role of fibrinolysis in tissue-factor-induced disseminated intravascular coagulation in rats - an effect of tranexamic acid. *Haematologica* **89**: 757-758, 2004.
13. Naeye RL. Thrombotic state after a hemorrhagic diathesis, a possible complication of therapy with epsilon-aminocaproic acid. *Blood* **19**: 694-701, 1962.
14. Charytan C, Purtilo D. Glomerular capillary thrombosis and acute renal failure after epsilon-amino caproic acid therapy. *N Engl J Med* **280**: 1102-1104, 1969.
15. Ontachi Y, Asakura H, Arahata M, et al. Effect of combined therapy of danaparoid sodium and tranexamic acid on chronic disseminated intravascular coagulation associated with abdominal aortic aneurysm. *Circ J* **69**: 1150-1153, 2005.
16. Yamamoto K, Ito H, Hiraiwa T, Tanaka K. Effects of nafamostat mesilate on coagulopathy with chronic aortic dissection. *Ann Thorac Surg* **88**: 1331-1333, 2009.
17. Hayashi T, Nakagawa N, Kadohira Y, Morishita E, Asakura H. Rivaroxaban in a patient with disseminated intravascular coagulation associated with an aortic aneurysm: a case report. *Ann Intern Med* **161**: 158-159, 2014.
18. Wagenhäuser MU, Ertas N, Sagban TA, et al. A 61-year-old man with disseminated intravascular coagulation: a case report. *Ann Vasc Surg* **28**: 1566.e17-1566.e22, 2014.
19. Kawano H, Hata T, Uda A, Maemura K. Use of rivaroxaban for the effective management of disseminated intravascular coagulation associated with abdominal aortic aneurysm. *Intern Med* **54**: 2625-2628, 2015.
20. Sakamoto I, Matsuyama N, Fukushima A, et al. Chronic aortic dissection complicated by disseminated intravascular coagulation: successful treatment with endovascular stent-grafting. *J Endovasc Ther* **10**: 953-957, 2003.
21. Luebke T, Brunkwall J. Type B aortic dissection: a review of prognostic factors and meta-analysis of treatment options. *Aorta (Stamford)* **2**: 265-278, 2014.

The Internal Medicine is an Open Access article distributed under the Creative Commons Attribution-NonCommercial-NoDerivatives 4.0 International License. To view the details of this license, please visit (<https://creativecommons.org/licenses/by-nc-nd/4.0/>).