



# Sprematic vein abscess after varicocele embolization – A case presentation

Binyamin B. Neeman<sup>a,\*</sup>, Anthony Verstandig<sup>b</sup>, Alaeddin Natsheh<sup>a</sup>, Boris Chertin<sup>a</sup>

<sup>a</sup> From the Department of Urology, Shaare Zedek Medical Center, Jerusalem, Faculty of Medical Science, Hebrew University, Jerusalem, Israel

<sup>b</sup> From the Angiography Unit, Dept. of Radiology, Shaare Zedek Medical Center, Jerusalem, Faculty of Medical Science, Hebrew University, Jerusalem, Israel

## ARTICLE INFO

### Keywords:

Varicocele  
Laparoscopic-surgery  
Embolization  
Complications

## ABSTRACT

Testicular varicocele is a dilatation of the pampiniform plexus. It is a common clinical problem affecting 15% of adolescents and adults that may be associated with pain and discomfort, and can affect fertility. Varicocele treatment is associated with a significant improvement in sperm parameters, and pregnancy rate. For endovascular treatment Fibered embolization coils are commonly utilized. Complications associated with coil insertion are rare, but can have serious consequences.

Here, we presenting the first reported case of a retroperitoneal abscess following testicular vein coil embolization. The patient underwent successful laparoscopic removal the infected coil followed by full recovery.

## 1. Introduction

Testicular varicocele is a dilatation of the pampiniform plexus, which is a part of the gonadal vein. It is a common clinical problem affecting 15% of adolescents and adults that may be associated with pain and discomfort, and can affect fertility.<sup>1</sup>

Varicocele treatment is associated with a significant improvement in sperm concentration, motility, morphology, and pregnancy rate. There are several surgical options for the repair of varicocele, either by retroperitoneal approach (open or laparoscopic), or by microsurgical technique (inguinal or subinguinal). Percutaneous varicocele embolization (VE) has gained acceptance over the past two decades as an effective alternative to surgery. VE has the advantage of being a minimally invasive procedure with a faster return to normal activities and a considerably lower cost. The commonest technique utilizes a combination of thrombogenic fibered metal coils and a liquid sclerosant to ensure occlusion of both large and small veins. However, other materials such as biological glues and vascular plugs might also be utilized. Coils are the most commonly used embolization agent due to their safe features, easy handling and low cost. Complications associated with coil insertion such as migration to the heart or pulmonary arteries and infection are rare, but potentially serious.

We present the first reported case of VE, resulting in retroperitoneal abscess formation.

## 2. Case report

A 34 years old otherwise healthy male with infertility, severe oligoastheno-teratozoospermia and bilateral clinical varicoceles underwent bilateral VE.

VE embolization was performed in a dedicated angiography suite with standard sterile procedure. Antibiotic prophylaxis was not administered. Under ultrasound guidance a 4 Fr access sheath was inserted into the right jugular vein. Both of the testicular veins were selectively catheterized and moderate left and small to moderate right varicoceles were occluded with fibered metal coils (Cook inc. Bloomington In) and a total of 3 ml of sodium tetradecyl sulphate (fibroven STD inc. Hereford, England) foamed with an equivalent volume of room air. On the left side, coils were placed at the level of the inguinal ligament and at the iliac crest extending into a connecting retroperitoneal vein. The patient was discharged 1 h after the procedure in good condition.

Ten days later, he was admitted with fever, rigors and severe left abdominal pain. His laboratory tests demonstrated leukocytosis and elevated C-reactive protein. CT scan of the abdomen demonstrated 6.9 × 2.3 cm collection involving the left testicular vein and containing the upper metallic coil lying anterior to the left psoas muscle (Fig. 1). The patient was admitted for intravenous antibiotics treatment and drainage.

Under CT guidance the abscess was drained and staphylococcus aureus cultured from the pus.

Repeat CT demonstrated resolution of the fluid collection, but

\* Corresponding author. Departments of Urology & Pediatric Urology, Shaare Zedek Medical Center, Faculty of Medicine, Hebrew University, Jerusalem, 91031, P.O.B 3235, Israel.

E-mail address: [neemanbenny@gmail.com](mailto:neemanbenny@gmail.com) (B.B. Neeman).

<https://doi.org/10.1016/j.eucr.2021.101907>

Received 24 September 2021; Received in revised form 16 October 2021; Accepted 19 October 2021

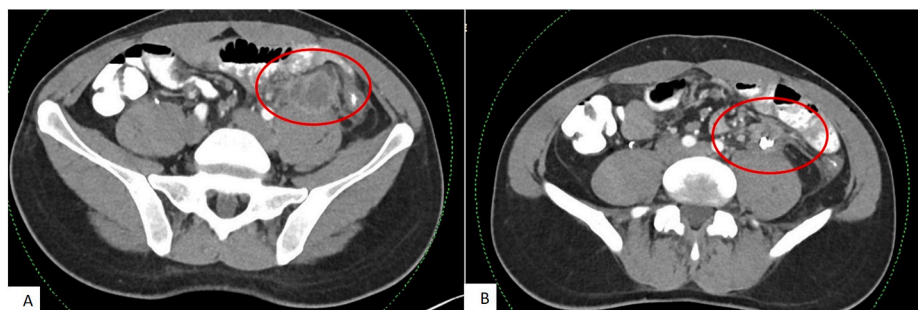
Available online 22 October 2021

2214-4420/© 2021 The Authors.

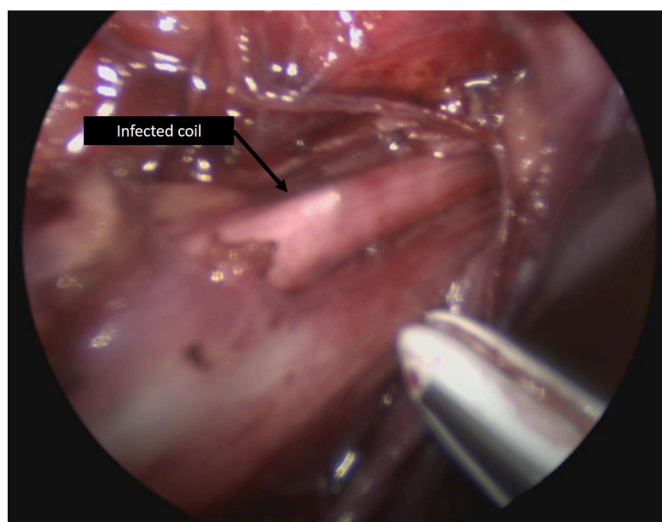
Published by Elsevier Inc.

This is an open access article under the CC BY-NC-ND license

(<http://creativecommons.org/licenses/by-nc-nd/4.0/>).



**Fig. 1.** A - collection involving the left testicular vein  
B - metallic coil lying anterior to the left psoas muscle.



**Fig. 2.** The inflamed segment of the gonadal vein including the coil.

significant inflammatory changes of the surrounding tissues. There was only partial resolution of symptoms and these findings were attributed to the continued presence of an infected foreign body. The decision was made to proceed with the surgical removal of the infected coil.

The patient was placed in the supine position with elevated left flank. Three 5 mm Medtronic trocar ports were placed (Two on the mid line and one in the left abdomen). The inflammatory mass was exposed through a small left peritoneal window. Careful and meticulous exploration was made extending to the left inguinal ring. The inflamed segment of the gonadal vein including the coil was excised entirely utilizing LigaSure sealing device (Medtronic) (Fig. 2).

The patient was discharged on the following day.

### 3. Discussion

There are several options for the treatment of varicocele, including surgical repair either by open or microsurgical approach, laparoscopy, or through percutaneous embolization of the internal spermatic vein. The ultimate goal of varicocele treatment relies on the occlusion of the dilated veins that drain the testis. Percutaneous embolization offers a rapid recovery and can be successfully accomplished in approximately 90% of attempts. However, the technique demands interventional radiologic expertise and has potential serious complications, including vascular perforation, coil migration, and thrombosis of pampiniform plexus.<sup>2</sup>

Complications of VE are unusual, occurring in less than 2% of cases and are mostly self-limiting.<sup>3</sup> As described above, coil migration is a rare although considered as a major complication after embolization of

the spermatic vein. Karia et al describe a rare case of migration of a varicocele coil to the right heart more than a decade after the procedure.

Recently, Doolittle et al. reported a patient with intractable pain post VE with coils which was successfully treated by robotic resection of the coil containing gonadal vein segment.<sup>4</sup> The authors advocated robotic surgery due to the high magnification and easier manipulation using the robotic arms and pointed out that the coils were easily seen through the wall of the vessel helping with orientation inside the inflammatory retroperitoneal process.

Although the robotic approach is superior in terms of magnification and ease of manipulation, the robotic platform is not available in all departments and also the cost of the robotic surgery could not be brushed aside. In spite of the fact that XI Da Vinci robotic platform is available in our services and we have had extensive experience in robotic surgery in adult and pediatric population,<sup>5</sup> we have decided to go on with the use of conventional laparoscopic approach due to high cost of robotic system. As we have shown in our video conventional laparoscopy is not inferior to robotic approach for these cases, and has the advantages of more widespread availability and less dependence on advanced skills.

### 4. Conclusions

To the best of our knowledge, this is the first reported case of an infectious complication after VE. Persistent post procedural pain and fever after VE should be investigated with computerized tomography. In the case of retroperitoneal abscess, if antibiotic treatment and drainage are not enough, laparoscopic surgery to remove the coil is safe, feasible and reproducible.

### Appendix A. Supplementary data

Supplementary data to this article can be found online at <https://doi.org/10.1016/j.eucr.2021.101907>.

### References

1. Akbay E, Cayan S, Doruk E, Duce MN, Bozlu M. The prevalence of varicocele and varicocele-related testicular atrophy in Turkish children and adolescents. *BJU Int.* 2000 Sep;86(4):490–493.
2. Bittles MA, Hoffer EK. Gonadal vein embolization: treatment of varicocele and pelvic congestion syndrome. *Semin Intervent Radiol.* 2008;25(3):261–270. <https://doi.org/10.1055/s-0028-1085927>.
3. Makris GC, Efthymiou E, Little M, et al. Safety and effectiveness of the different types of embolic materials for the treatment of testicular varicoceles: a systematic review. *Br J Radiol.* 2018 Jul;1088:91.
4. Doolittle J, Maniar V, Dietrich P, Sandlow J, Johnson S, Kansal J. Resolution of abdominal pain after coil embolization of varicocele with robotic resection of gonadal vein. *J Endourol Case Rep.* 2020 Dec 29;6(4):533–535.
5. Chertin L, Neeman BB, Stav K, et al. Robotic versus laparoscopic ipsilateral uretero-ureterostomy for upper urinary tract duplications in the pediatric population: a multi-institutional review of outcomes and complications. *J Pediatr Surg.* 2021 Jan 7;(21): S0022–S3468, 00004-X.